

Hyperperfusion syndrome after aneurysm surgery: a case report

Tomomichi Kayahara¹ · Ririko Takeda¹ · Yuichiro Kikkawa¹ · Yushiro Take¹ · Hiroki Kurita¹

Received: 11 August 2015 / Accepted: 20 August 2015 / Published online: 3 September 2015
© Springer-Verlag Wien 2015

Abstract A 74-year-old woman exhibited sensory aphasia with abrupt blood pressure elevation 3 h after clipping of an unruptured large left middle cerebral artery aneurysm. Perfusion computed tomography and single-photon emission computed tomography demonstrated hyperperfusion in one of the distal parent artery areas. She gradually improved and was discharged without neurological deficits. Increased distal blood flow after occlusion of the large cerebral aneurysm and postischemic reperfusion after temporary occlusion of the parent artery during surgery presumably played an important role in the occurrence of this fairly rare condition associated with aneurysm surgery.

Keywords Hyperperfusion · Large cerebral aneurysm · Clipping · Postischemic reperfusion

Introduction

Hyperperfusion is a known complication of neurovascular interventions including carotid endarterectomy, percutaneous transluminal angioplasty, and extracranial-intracranial bypass surgery [5]. However, the development of hyperperfusion syndrome in association with aneurysm surgery is extremely rare [2, 4, 6]. We herein describe a case of hyperperfusion syndrome after clipping of an unruptured large middle

cerebral artery (MCA) aneurysm. The mechanism of this fairly rare condition is discussed.

Case report

A 74-year-old woman was admitted to our institution for repair of an incidentally found large left MCA bifurcation aneurysm. She had no history of stroke or other vascular risk factors except for mild hyperlipidemia. Neurological examination results were normal. Digital subtraction angiography (DSA) and three-dimensional computed tomography angiography (3D-CTA) revealed a large MCA bifurcation aneurysm with a maximum diameter of 20 mm (Fig. 1a and b). Magnetic resonance (MR) angiography showed the lesion with attenuation of the M2 inferior trunk (Fig. 1c, arrowheads).

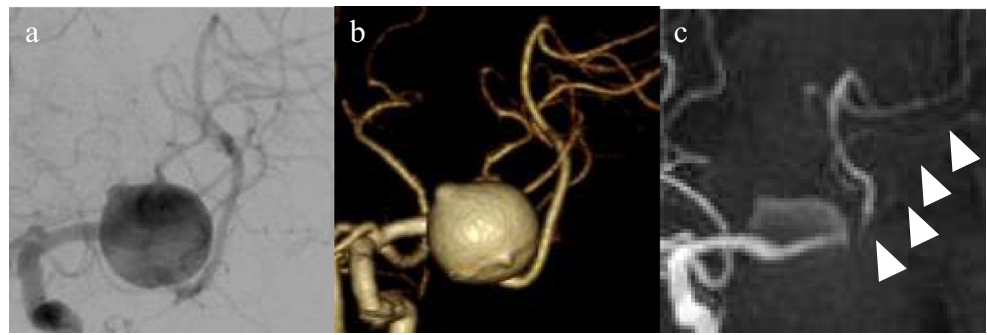
The patient underwent left frontotemporal craniotomy, and the aneurysm was totally exposed via the transsylvian approach without damage to the venous system. Multiple clips were placed to obliterate the lesion during temporary proximal MCA occlusion for a total of 10 min in three sessions. The MCA was preserved without stenosis, and intraoperative monitoring of motor-evoked potentials and somatosensory evoked potentials showed no change. Intraoperative Doppler ultrasound flowmetry (DVM-4500; Hadeco, Inc., Kanagawa, Japan) revealed that the blood flow of the M2 segments distal to the aneurysm before and after clipping were 75 and 50 ml/min (superior trunk) and 22 and 48 ml/min (inferior trunk), respectively.

The patient showed no neurological deficits soon after surgery, but sensory aphasia with abrupt elevation of the blood pressure was observed 3 h later. She received edaravone, hydroxyethyl starch, and fosphenytoin sodium, and her blood pressure was strictly controlled. 3D-CTA and perfusion CT on postoperative day (POD) 1 demonstrated complete obliteration

✉ Tomomichi Kayahara
goyanorasetu@gmail.com

¹ Department of Cerebrovascular Surgery, International Medical Center, Saitama Medical University, 1397-1 Yamane, Hidaka, Saitama 350-1298, Japan

Fig. 1 Preoperative images. **a** Preoperative DSA and **b** 3D-CTA showing a large aneurysm of the left MCA bifurcation. **c** MRA demonstrating the lesion with attenuation of the M2 inferior trunk (*arrowheads*)



of the aneurysm, a patent MCA without stenosis (Fig. 2a). We also observed increased cerebral blood flow (CBF) (Fig. 2b), increased cerebral blood volume, and a shortened mean transit time.

On POD 2, the patient's blood pressure stabilized and her sensory aphasia gradually improved. An MR image obtained on POD 4 showed no abnormality on fluid-attenuated inversion recovery imaging (Fig. 2c) or diffusion-weighted imaging, but MR angiography demonstrated higher intensity of the inferior trunk than shown on the preoperative image (Fig. 2d, arrowheads). The results of the Standard Language Test of Aphasia on POD 10 were normal, but single-photon emission computed tomography (SPECT) showed a persistent increase in the CBF in the left temporoparietal lobe (right vs. left angular area, 47.42 vs. 54.16 ml/100 g/min, respectively; right

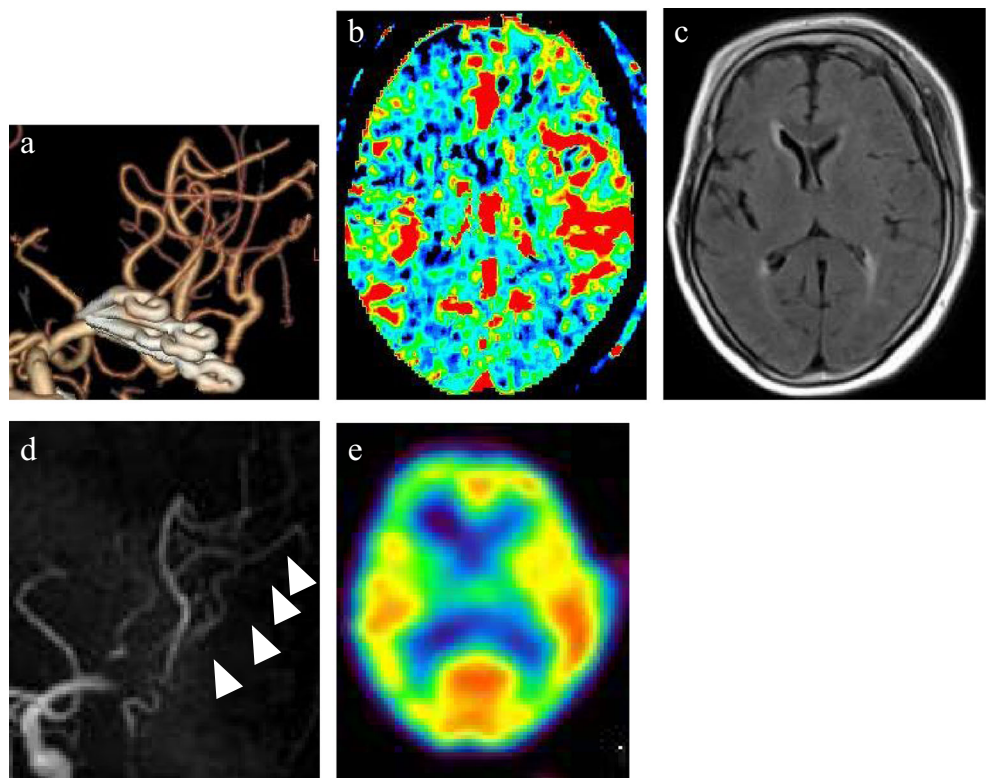
vs. left temporal area, 43.65 vs. 46.95 ml/100 g/min, respectively) (Fig. 2e). She was clinically well 3 months after surgery, and SPECT demonstrated no laterality in the CBF.

Discussion

Hyperperfusion is thought to be caused by an acute, excessive increase in CBF into a chronically hypoperfused area, where microvessels are pathologically dilated to restore CBF with dysautoregulation [2].

The association of this syndrome with aneurysm surgery is extremely rare. A review of the literature revealed only four previously reported cases (unruptured aneurysm cases) [2, 4, 6]. Although the small number of cases precludes statistical

Fig. 2 Postoperative image. **a** 3D-CTA on POD 1 showing complete obliteration of the aneurysm and a patent MCA without stenosis. **b** Perfusion CT on the same day demonstrating increased CBF in the left MCA territory. **c** FLAIR-MR image obtained on POD 4 showing no abnormal findings. **d** MRA of the same day demonstrating higher intensity of the inferior trunk than on the preoperative image (*arrowheads*). **e** SPECT image on POD 10 showing slightly increased CBF in the left temporoparietal lobe



analysis, accumulated clinical data suggest that the causative factors include increased distal blood flow after clipping of a large or giant aneurysm [3, 4], postischemic reperfusion after temporary occlusion of the parent artery [1, 2], and disturbed venous return by brain compression with a spatula or injury to the intracranial veins [6].

Large or giant aneurysms are known to cause decreased systolic blood flow through the distal parent artery due to the retained blood in the lesion during diastole [4]. Consequently, neck clipping of the aneurysm may cause an exponentially increased systolic velocity of the artery that the dilated microvessels cannot regulate, leading to hyperperfusion. The present case supports this notion for three reasons: preoperative MRA suggested decreased flow velocity of the inferior trunk of the MCA, increased blood flow of the affected artery due to clipping was confirmed intraoperatively by Doppler ultrasound flowmetry, and postoperative MRA revealed higher intensity of the artery compared with the preoperative image with a patent MCA without stenosis. The calculated increase in the velocity of the M2 inferior trunk in this case was not particularly high (26 ml/min), but it may have been sufficient for capillary breakthrough.

Postischemic reperfusion after temporary occlusion also might have contributed to the circulatory disturbance. Several authors have reported that the total duration and maximum single duration of temporary occlusion during clipping are significant risk factors for hyperperfusion, especially in cases involving a total duration exceeding 20 min [1, 3]. Although the duration was only about 10 min in three sessions in this case, efforts should be made to shorten the time of temporal occlusion of the parent artery, especially during surgical repair of large to giant aneurysms.

The symptoms of hyperperfusion are similar to those of brain ischemia, but the treatments differ. The pathophysiology is usually not visualized by routine postoperative CT or MRI. Physicians must be aware of this rare but potentially disabling condition following aneurysm surgery.

Acknowledgments This study was supported in part by JSPS KAKENHI, grant numbers 25462235 and 26461278.

Patient consent The patient/next of kin/guardian has consented to the submission of the case report for submission to the journal.

Conflict of interest All authors certify that they have no affiliations with or involvement in any organization or entity with any financial

interest (such as honoraria; educational grants; participation in speakers' bureaus; membership, employment, consultancies, stock ownership, or other equity interest; and expert testimony or patent-licensing arrangements), or non-financial interest (such as personal or professional relationships, affiliations, knowledge or beliefs) in the subject matter or materials discussed in this manuscript.

References

1. Araki Y, Andoh H, Yamada M, Nakatani K, Andoh T, Sakai N (1999) Permissible arterial occlusion time in aneurysm surgery. Postoperative hyperperfusion caused by temporary clipping. *Neurol Med Chir (Tokyo)* 39:901–907
2. Kuroki K, Taguchi H, Yukawa O (2006) Hyperperfusion syndrome after clipping of an unruptured aneurysm. *Neurol Med Chir (Tokyo)* 46:248–250
3. Maruya J, Nishimaki K, Minakawa T (2011) Hyperperfusion syndrome after neck clipping of a ruptured aneurysm on a dolichoectatic middle cerebral artery. *J Stroke Cerebrovasc Dis* 20:260–263
4. Murakami H, Ibata M, Nakamura A, Ushioda T (2002) Ipsilateral hyperperfusion after neck clipping of a giant internal carotid artery aneurysm. *J Neurosurg* 97:1233–1236
5. Schoser BGH, Heesen C, Eckert B, Thie A (1997) Cerebral hyperperfusion injury after percutaneous transluminal angioplasty of extracranial arteries. *J Neurol* 244:101–104
6. Sugino T, Ohtaki M, Wanibuchi M, Kin S, Houkin K (2010) Hyperperfusion syndrome after clipping an unruptured cerebral aneurysm. *Neurol Med Chir (Tokyo)* 50:306–309

Comments

Very well written case report describing a case with transient hyperperfusion syndrome after elective surgery for a large MCA bifurcation aneurysm. The authors describe the possible mechanisms, including temporary occlusion of 10 min in total divided into three rounds, but their main hypothesis is that aneurysm occlusion led to an increase in flow through the inferior M2 trunk and hence a hyper perfusion syndrome in the angular area. This is substantiated by their intro flow measurements. Intraoperative Doppler ultrasound flowmetry revealed that the blood flow of the M2 segments distal to the aneurysm before and after clipping were 75 and 50 ml/min (superior trunk) and 22 and 48 ml/min (inferior trunk), respectively. In my personal experience, I have had similar cases, but never performed this thorough intro and post investigations, something I commend the authors for. I use temporary clipping in the vast majority of aneurysm cases and have never seen hyperperfusion syndrome postop unless there was a large or giant aneurysm, so I believe that the hyper perfusion is secondary to clipping of the aneurysm, thereby leading to reduced attenuation of flow in the M2 branches.

Torstein Meling
Oslo, Norway