



## Clinical letter

## COL4A1 gene mutation – beyond a vascular syndrome

Seby John<sup>a</sup>, Lara Jehi<sup>b</sup>, Edward M. Manno<sup>a</sup>, Devon S. Conway<sup>c</sup>, Ken Uchino<sup>a,\*</sup><sup>a</sup> Cerebrovascular Center, Cleveland Clinic, Cleveland, OH, United States<sup>b</sup> Epilepsy Center, Cleveland Clinic, Cleveland, OH, United States<sup>c</sup> Mellen Center, Cleveland Clinic, Cleveland, OH, United States

## ARTICLE INFO

## Article history:

Received 30 March 2015

Received in revised form 12 June 2015

Accepted 25 June 2015

## 1. Introduction

COL4A1 mutations have been associated with a variety of vascular abnormalities and disease manifestations, including porencephaly, infantile hemiparesis, intracerebral hemorrhage in neonates and children, intracerebral hemorrhage and cerebral small vessel disease in adulthood, intracranial aneurysms, and retinal arteriolar tortuosities [1]. The gene encodes for type IV collagen  $\alpha 1$  that forms the vascular basement membrane in heterotrimer triple helix collagen. Seizures have been described with COL4A1 mutation, the reasons for which are unknown. We present a patient with COL4A1 mutation who developed status epilepticus, and offer a hypothesis generating explanation for seizures in this monogenic cerebral small vessel disease.

## 2. Case report

A 61-year old woman was admitted to our hospital for management of ongoing seizures. Her past medical history included hypertension, hyperlipidemia, depression and chronic kidney disease. Her neurologic history included migraine with visual aura, recurrent ischemic stroke and transient ischemic attacks starting at age 26, and recurrent intracerebral hemorrhage starting at age 59. She was of European-American descent without family history of cerebrovascular disease. Diagnostic evaluation revealed severe diffuse cerebral leukoencephalopathy, multiple subcortical lacunar infarcts and subcortical micro-hemorrhages on magnetic resonance imaging (MRI) (Fig. 1). The first available MRI brain was performed 5-years prior to our initial evaluation and was

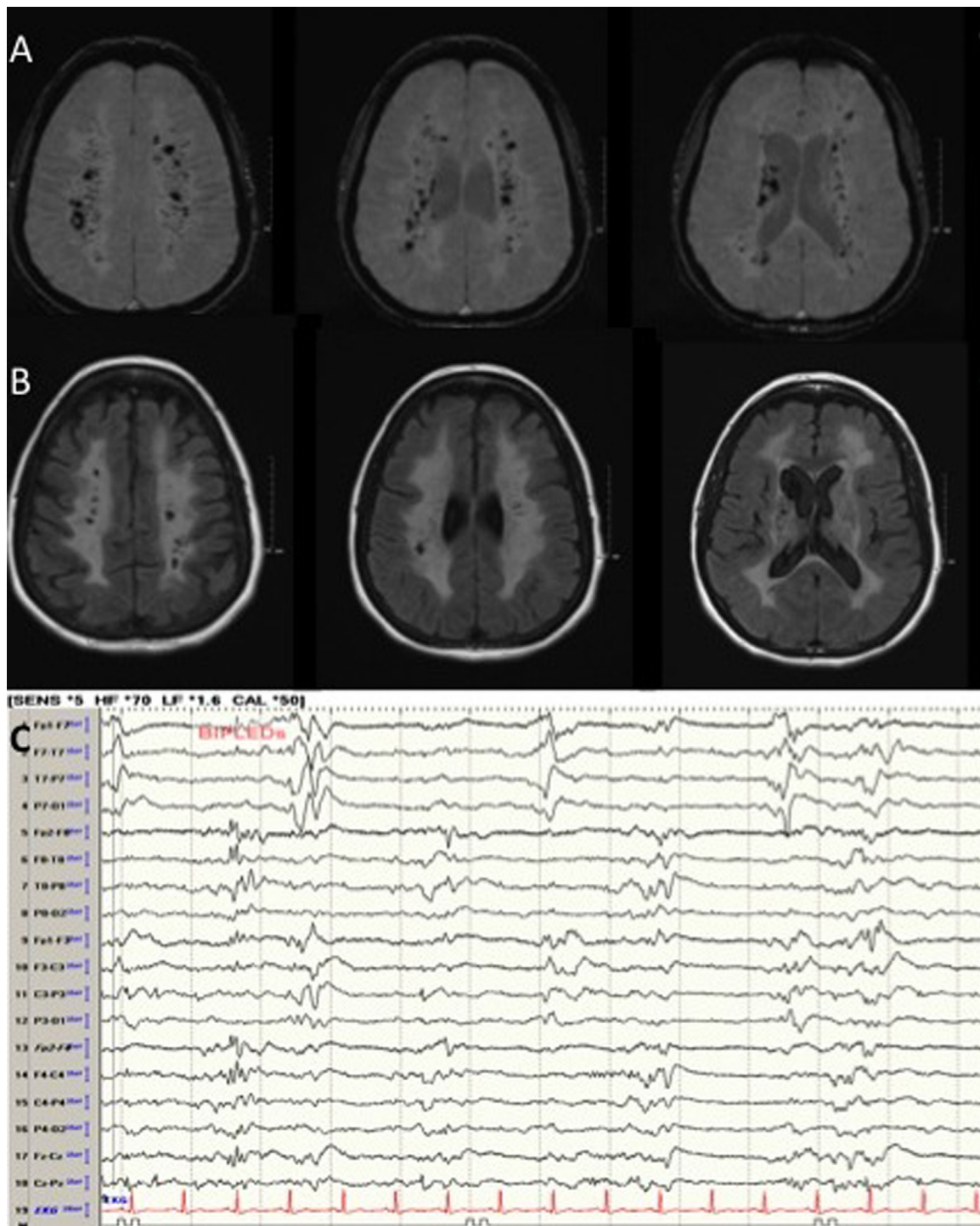
striking for diffuse cerebral white matter disease. Serial MRI's in the interval time period showed marked accumulation of subcortical lacunar infarcts and micro-hemorrhages. The micro-hemorrhages were numerous and were in a distribution that closely paralleled the white matter hyperintensities. There was no suggestion of cognitive or neuromuscular involvement. Given the clinic-radiologic presentation, genetic testing for Cerebral autosomal dominant arteriopathy with subcortical infarcts and leukoencephalopathy (CADASIL) was performed but was negative.

Additional evaluation included ophthalmologic testing that revealed normal retinal vasculature. Review of records revealed evidence of stage III chronic kidney disease for approximately 10-years prior to initial evaluation (baseline creatinine 1.4 mg/dl) with an atrophic left kidney, and a normal sized right kidney with a cyst. There was no evidence of calcification on renal arteries to suggest advanced atherosclerosis or renal artery stenosis on abdominal computed tomography (CT) scanning. Urine analysis was positive for 1+ microscopic hematuria. Based on the constellation of systemic findings, she was tested and found positive for the COL4A1 mutation (c.2086G>A;p.Gly696Ser) one year prior to admission. Genetic testing and counseling was offered to family members. She had one daughter who was deceased from “cancer”. Here parents were also deceased and one living biological brother was unavailable for testing.

This hospitalization was prompted when she developed acute onset of right arm tonic posturing and right gaze preference, followed by a generalized tonic clonic seizure lasting 30 min. She was intubated at an outside emergency room, administered anti-epileptics including intravenous lorazepam, phenobarbital and fosphenytoin sodium, and subsequently admitted to the neurological intensive care unit. Initial evaluation included CT of the head that was unremarkable for an acute process. Continuous electroencephalographic monitoring revealed bilateral periodic lateralized epileptiform discharges (BIPLEDs) on a background of generalized, continuous slow waves (Fig. 1). Subsequent work up included an MRI of the brain, which did not reveal any acute infarct but showed stable, extensive T2/FLAIR leukoencephalopathy and extensive susceptibility artifact on susceptibility-weighted imaging. There was increased T2/FLAIR signal in the left hippocampal body without gadolinium enhancement (Fig. 1), which was thought to represent transient postictal hippocampal edema given the location and its reversibility on follow up MRI. A lumbar puncture was performed and cerebrospinal fluid analysis revealed

\* Corresponding author at: Cleveland Clinic, 9500 Euclid Ave, S80, Cleveland, OH 44195, United States. Tel.: +216 445 4073.

E-mail address: [uchinok@ccf.org](mailto:uchinok@ccf.org) (K. Uchino).



**Fig. 1.** Axial susceptibility weighted images (Panel A) showing numerous micro-hemorrhages in the subcortical white matter, along with diffuse white matter hyperintensity and numerous lacunar infarcts on axial FLAIR images (Panel B). A 10 s epoch of the electroencephalogram (Panel C) showing bi-hemispheric, high amplitude, sharp waves that are asynchronous, representative of BIPLEDs.

6 white blood cells composed of 6% neutrophils, 79% lymphocytes, 12% monocytes and 1% eosinophils. Protein and glucose levels were 38 and 71 mg/dl respectively. Herpes Simplex Virus detection by polymerase chain reaction testing was negative.

She was treated for status epilepticus with fosphenytoin sodium, levetiracetam, lacosamide and midazolam intravenous infusions. She initially continued to have right lateralizing seizures arising from a background of burst suppression. Thereafter, BIPLEDs persisted along with runs of a periodic pattern in the bifrontal lobes without evidence of seizures. We did not have an

earlier electroencephalogram for comparison since she did not have a history of seizures, and an electroencephalogram was never performed prior to this admission. She underwent a tracheostomy 18 days after admission, and was discharged to a long-term acute care facility a month after admission.

### 3. Discussion

We present a patient with COL4A1 mutation who presented with new onset seizure and status epilepticus with prior ischemic

and hemorrhagic brain lesions. The c.2086G>A;p.Gly696Ser is a novel DNA sequence variant with no known published research on it. Although this variant is of unknown clinical significance, both SIFT (Sorting Intolerant From Tolerant) and PolyPhen-2.2.2 programs predicted that this variant is more likely pathogenic than benign. This patient had typical clinical and imaging phenotype of COL4A1 mutation including leukoencephalopathy, subcortical lacunar infarcts, and subcortical micro-hemorrhages. As such, it could be argued that the seizures were likely secondary to accumulation of structural brain lesions. However, the presence of persistent BIPLEDs in the absence of acute or chronic cortical lesions, infection or metabolic disturbances suggests that the seizures cannot be explained entirely by local structural changes alone, but may represent a more diffuse electrophysiological process. We hypothesize that COL4A1 disease manifestations may not be solely secondary to vascular compromise, but may have an electrophysiological substrate. Although conjectural, this may be secondary to yet undiscovered altered neurotransmission in the cerebral cortex that causes decreasing inhibition and/or increasing excitatory neurotransmission. This results in convergence of disparate oscillations by coupling, until there is emergence of one dominant oscillation.

COL4A1 mutation causes a systemic vascular basement membrane disease. Its manifestations are widespread and variable, involving the brain, eye and kidneys [1]. Similar to COL4A1 mutation, CADASIL is a monogenic cause of cerebral small vessel disease caused by a mutation in the Notch3 gene. An interesting feature of CADASIL is that patients experience migraine with aura at five times the frequency of the general population [2]. This is also the first clinical manifestation, which may occur in the absence of neuroimaging abnormalities. Studies on transgenic mice that develop age-dependent Notch3 ECD and GOM deposits without brain lesions demonstrated that they have much lower threshold for cortical spreading depression as well as a higher speed of propagation [3]. This susceptibility was unchanged in a mouse model of chronic forebrain hypoperfusion arguing against the involvement of hypoperfusion.

Epileptic seizures have been described with COL4A1 mutation [4]. Akin to migraine in CADASIL, COL4A1 mutations may lead to disturbances in normal cortical electrophysiologic function resulting in a pathologically low threshold for activation of cortical hyperexcitability.

#### 4. Conclusion

This report is hypothesis generating. Seizures are part of the clinical spectrum of COL4A1 mutation, and may be related to electrophysiological processes altering the threshold potentials for seizure generation.

#### Author contributions

Dr. Seby John, Dr. Lara Jehi and Dr. Devon Conway performed the study concept and design, acquisition of data, analysis and interpretation, critical revision of the manuscript for important intellectual content. Dr. Edward Manno and Dr. Ken Uchino performed the study concept and design, analysis and interpretation, critical revision of the manuscript for important intellectual content.

#### Disclosures

Dr. Lara Jehi served on an advisory scientific committee for Lundbeck, received consulting fees from Novartis, received research support from UCB and from the National Center for Advancing Translational Science (NCATS). She serves on the editorial board of *Epilepsia* and is a contributing editor to *Epilepsy Currents*.

#### Conflict of interest

None declared.

#### References

- [1] Vahedi K, Alamowitch S. Clinical spectrum of type IV collagen (COL4A1) mutations: a novel genetic multisystem disease. *Curr Opin Neuro*. 2011; 24.1:63–8.
- [2] Chabriat H, et al. Cadasil. *Lancet Neurol* 2009;8.7:643–53.
- [3] Katharina E-H, et al. Cerebral autosomal dominant arteriopathy with subcortical infarcts and leukoencephalopathy syndrome mutations increase susceptibility to spreading depression. *Ann Neurol* 2011;69.2:413–8.
- [4] Leung M, et al. COL4A1 mutation in a pediatric patient presenting with post-ictal hemiparesis. *Can J Neurol Sci* 2012;39.5:654–7.