

# Detection of Cerebral Vasospasm Following Aneurysmal Subarachnoid Hemorrhage Using Motor Evoked Potentials

Stefan Grossauer, MD, MBA\*‡

Katharina Koeck, MD, MBA\*‡

Jakob Kraschl, MD‡

Oliver Olipitz, BAS

Klaus A. Hausegger, MD,

PhD¶

Giles H. Vince, MD, PhD‡

‡Department of Neurosurgery, General Hospital of Klagenfurt, Klagenfurt, Austria; §Institute of Human Biology, Karl-Franzens University Graz, Graz, Austria; ¶Department of Interventional and Diagnostic Radiology, General Hospital of Klagenfurt, Klagenfurt, Austria

\*These authors contributed equally to this article.

## Correspondence:

Stefan Grossauer, MD, MBA,  
Department of Neurological Surgery,  
Helen Diller Cancer Research Building,  
University of California San Francisco,  
1450 Third St,  
Box 0520,  
Rm HD482 (4th floor),  
San Francisco, CA 94158-2197.  
E-mail: stefan.grossauer@ucsf.edu

Received, March 21, 2015.

Accepted, August 20, 2015.

Published Online, September 29, 2015.

Copyright © 2015 by the  
Congress of Neurological Surgeons.

**BACKGROUND:** Early detection of vasospasm (VS) following aneurysmal subarachnoid hemorrhage (aSAH) is vital to trigger therapy and to prevent infarction and subsequent permanent neurological deficit. Although motor evoked potentials (MEPs) are a well-established method for intraoperative detection of cerebral VS and cerebral ischemia during aneurysm surgery, there are no studies investigating the diagnostic value of MEPs for detecting delayed VS following aSAH in an intensive care unit.

**OBJECTIVE:** A prospective study was conceived to assess the diagnostic accuracy of MEPs in comparison with digital subtraction angiography.

**METHODS:** MEP threshold changes were determined in patients both with and without angiographic VS following high-grade aSAHs. Sensitivity, specificity, and the positive and negative predictive values of significant MEP threshold increases, which indicate angiographic VS, were calculated.

**RESULTS:** In all patients experiencing VS of the arteries supplying cerebral motor areas, a minimal MEP threshold increase of 50 mA (mean 66.25 mA) was observed, whereas a maximum MEP threshold increase of 30 mA was observed in patients without VS. Therefore, an increase from a baseline of  $\geq 50$  mA was considered significant and resulted in a sensitivity of 0.83, a specificity of 0.92, a positive predictive value of 0.83, and a negative predictive value of 0.92.

**CONCLUSION:** VS following aSAH can be detected accurately by using MEPs. MEPs are a feasible bedside tool for online VS detection in an intensive care unit and, therefore, may complement existing diagnostic tools.

**KEY WORDS:** Intracranial aneurysm, Motor evoked potentials, Neurophysiological monitoring, Subarachnoid hemorrhage, Vasospasm

Neurosurgery 78:265–273, 2016

DOI: 10.1227/NEU.0000000000001040

www.neurosurgery-online.com

Vasospasm (VS) following aneurysmal subarachnoid hemorrhage (aSAH) is a severe condition associated with high morbidity and mortality. Early detection is vital to trigger therapy and to prevent infarction and subsequent permanent neurological deficit.<sup>1</sup> Many methods, including neurological examination, digital subtraction angiography (DSA), perfusion computed tomography (PCT), and transcranial Doppler (TCD) sonography,<sup>2–7</sup> are used to

detect VS. Although neurological examination has proven to be a simple bedside method with high diagnostic sensitivity, many patients are not amenable to this examination because they require anesthesia.<sup>8</sup> Unfortunately, this subgroup often exhibits pronounced aSAH and, therefore, carries the highest risk for sustaining delayed cerebral VS.<sup>9</sup> Although cerebral angiography is considered the gold standard, TCD remains the best-established and most widely used bedside method for anesthetized patients. Unfortunately, this method offers only comparatively low sensitivity and specificity in detecting angiographic VS.<sup>8</sup>

Although electrophysiological methods are routinely used at intensive care units (ICUs) on severely brain-injured patients,<sup>10–14</sup> no study yet

**ABBREVIATIONS:** aSAH, aneurysmal subarachnoid hemorrhage; DSA, digital subtraction angiography; ICU, intensive care unit; MEP, motor evoked potential; PCT, perfusion computed tomography; TCD, transcranial Doppler; VS, vasospasm

**TABLE 1. Inclusion and Exclusion Criteria<sup>a</sup>**

Inclusion Criteria	Exclusion Criteria
aSAH Fisher grade III and IV	Conscious patients
Intracranial aneurysm verified by cerebral angiography	Intracranial pressure $\geq 20$ mm Hg as verified with ICP probe
Clinical condition requires deep anesthesia at the time of baseline and control MEP recording	Other clinical condition that does not allow MEP recording as decided by the responsible neurosurgeon (eg, increased arterial blood pressure or increased heart rate following transcranial electric stimulation)
Absence of vasospasm at the time of baseline MEP recording as demonstrated on cerebral angiography	Contradictory evaluation results of cerebral angiography by the vascular neurosurgeon and neuroradiologist
Time window $\leq 4$ h between angiography and start of MEP recording	Patient requiring barbiturates for anesthesia (eg, sodium pentothal)
Presence or absence of vasospasm verified by cerebral angiography at the time of control MEP recording	
Age $\geq 18$ y	

<sup>a</sup>aSAH, aneurysmal subarachnoid hemorrhage; ICP, intracranial pressure; MEP, motor evoked potentials.

has evaluated the diagnostic accuracy and feasibility of motor evoked potentials (MEPs) in detecting cerebral VS. The fact that the motor cortex is the cerebral structure most sensitive to cerebral ischemia can be exploited when using MEPs to detect impending cerebral ischemia when it is still potentially reversible. Therefore, MEPs represent a well-established method for intraoperative detection of cerebral VS and cerebral ischemia during aneurysm surgery, and the literature demonstrates that MEPs are a reliable tool for online, minimally invasive detection of cerebral ischemia and VS during aneurysm surgery.<sup>15-26</sup> Diagnostic accuracy of transcranial magnetic MEPs was investigated in a rabbit VS model in which VS following aSAH resulted in a significant increase of MEP latencies. Therefore, it was concluded that MEPs might be valuable in VS diagnostics.<sup>27</sup> To the authors' knowledge, there are no studies investigating the diagnostic accuracy and feasibility of MEPs in detecting delayed cerebral VS following aSAH in humans. Accordingly, we designed a prospective study investigating the diagnostic accuracy of MEPs in detecting angiographic cerebral VS in humans and evaluating its feasibility in an ICU.

## METHODS

### Selecting Patients

The study included all patients admitted to the neurosurgical ICU of the academic hospital of Klagenfurt for aSAH from April 1 to July 30, 2014, whose clinical parameters were consistent with all inclusion criteria and who had no exclusion criteria. The local institutional review board approved the study. Table 1 summarizes the inclusion and exclusion criteria. In brief, those included were adult patients sustaining high-grade aSAHs as demonstrated by computed tomography (Fisher grade III-IV), whose clinical condition required deep anesthesia at the time of baseline and control MEP recordings, and who had undergone DSA at least twice. The study excluded conscious patients and those exhibiting increased intracranial pressure verified by an intracranial pressure probe.

### Recording MEPs

All MEP recordings were performed by 2 neurosurgeons with extensive experience and training in electroneurophysiology (S.G., J.K.). Baseline MEPs were recorded on the day of admission and aneurysm rupture. On the same day, a baseline DSA was performed to rule out VS at the time of recording baseline MEPs. According to DSA results, all patients underwent occlusion of the ruptured aneurysm by endovascular coiling or microsurgical clipping within 48 hours after admission. In addition, control MEPs were recorded within 4 hours before a second DSA was performed, 1 to 17 days after baseline DSA. Reasons for cerebral control angiography included suspected VS as indicated by TCD and postclipping or postcoiling routine angiography. Throughout the MEP recording procedure, the analog-sedation required by patients' clinical condition was maintained with a customized combination of propofol, remifentanyl, midazolam, piritramide, and esketamine hydrochloride. Needle electrodes were inserted subdermally into the target muscles and connected to the amplifiers of the head box unit of the intraoperative electrophysiology device. Corkscrew electrodes were placed subcutaneously on the scalp over the stimulating sites according to the international 10-20 system and connected to the stimulation unit. Table 2 lists stimulation and recording parameters.

Then, the biosignal window was checked for artifacts. If artifacts were encountered, recording conditions were improved by ensuring proper needle placement or, in the case of electrical interference, relocating electrical devices. For tracheal tube safety, an oropharyngeal tube was placed in each patient. Transcranial stimulation began at an intensity of 30 mA and increased in 5-mA steps until stable MEPs could be elicited in all recording muscles of the upper and lower extremities bilaterally, or until the maximum stimulus intensity of 220 mA was reached. Initially, the stimulation sites were 1 electrode placed at C3 as the anode and 1 at C4 as the cathode. The threshold required for each muscle was noted in a prepared case report form. Threshold was defined as the lowest stimulus intensity required for each target muscle to elicit clearly identifiable, repeatable MEP signals on the device screen at a display sensitivity of 200  $\mu$ V. Then, the polarity of the stimulation electrodes was switched and the procedure repeated with anodal stimulation over C4 and cathodal stimulation over C3. If MEPs could not be elicited with stimulation electrodes placed in either of these arrangements,

**TABLE 2. Summary of Stimulation and Recording Parameters<sup>a</sup>**

Parameter	Value
Stimulation sites	C3/4; C4/3; Cz/Fz
Number and form of stimuli	Train of five
Stimulus lengths	500 $\mu$ s
Stimulus intensity	30-220 mA
Interstimulus interval	4 ms
Recording muscles	ABP bilateral, forearm extensors bilateral, TA bilateral, ABH bilateral
Stimulus frequency	0.5 Hz
Display sensitivity	200 $\mu$ V
Number of averaged signals	2
Low pass filter	50 Hz
High pass filter	3000 Hz

<sup>a</sup>ABH, abductor hallucis muscle; ABP, abductor pollicis brevis muscle; TA, tibialis anterior muscle.

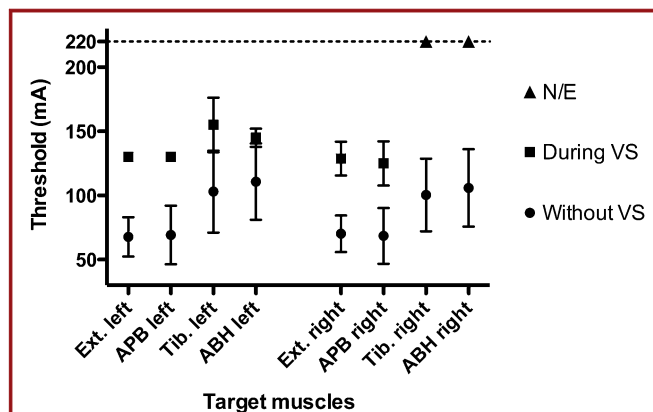
electrode placement was changed to provide anodal stimulation at Cz and cathodal stimulation at Fz and the recording procedure repeated as described above.

### Defining Vasospasm and Evaluating Cerebral Angiography

All patients included in the study underwent DSA at least twice: once on the day of baseline MEP recording and again on the day of control MEP recording. Reasons to forward patients to DSA included initial diagnostic evaluation, flow velocity of TCD that indicated cerebral VS, and postclipping or postcoiling control. Angiographic VS was defined as more than 30% narrowing of the diameter of a vessel trunk on 2-dimensional DSA and a significant subsequent delay of contrast flow distal to the spastic segment. DSA images were stored digitally for post hoc analysis and were reviewed and evaluated for the presence or absence of cerebral VS independently by a neuroradiologist and a vascular neurosurgeon unaware of MEP recording results. If VS could be demonstrated on DSA, the spastic artery or arteries were named in the case report form. In the case of contradictory DSA evaluation results by the neuroradiologist and neurosurgeon, the patient was excluded from analysis.

### Evaluating MEP Results and Proposing Diagnostic Criteria

As shown by intraoperative MEP studies, either the MEP threshold increases significantly or MEPs cannot be elicited at all in muscles innervated by vasospastic and/or ischemic motor cortex.<sup>22,24</sup> Therefore, it is to be expected that VS of the medial cerebral artery results in an increased MEP threshold of the contralateral upper extremity muscles, whereas VS of the anterior cerebral artery results in a MEP threshold increase in the contralateral lower extremity muscles. VS of the vertebral arteries or of the basilar artery may result in a threshold increase of lower and/or upper extremity muscles, owing to their vascular supply of the brainstem, whereas VS of the posterior cerebral artery may result in no threshold increase at all, owing to supplying nonmotor areas of the brain.



**FIGURE 1.** Graph showing the mean motor evoked potential (MEP) thresholds and its standard deviations for extremity muscles in patients with aneurysmal subarachnoid hemorrhage. Black dots represent the mean MEP thresholds in absence of angiographic vasospasm. Black squares represent the mean MEP thresholds during angiographic vasospasm. Black triangles represent MEPs that could not be elicited during angiographic vasospasm with a maximum intensity of 220 mA. ABH, abductor hallucis muscle; APB, abductor pollicis muscle; Ext., extensor; N/E, MEPs could not be elicited at all with maximum intensity of 220 mA; Tib., tibialis anterior muscle; VS, vasospasm.

To establish suitable diagnostic criteria to indicate VS, the study calculated and compared mean MEP thresholds and their standard deviations of muscles innervated by vasospastic and nonvasospastic cerebral motor areas. These results defined a significant threshold increase and tested it for its diagnostic accuracy by calculating sensitivity, specificity, and positive and negative predictive values.

### RESULTS

Baseline and control MEP recordings were performed on 17 patients. One patient was excluded from further analysis because of pronounced movement artifacts at the time of the control MEP recording. In the remaining 16 patients, MEP recordings were uneventful and took between 16 and 31 minutes. Five of 16 patients exhibited angiographic VS on days 6 to 17 following aSAH, whereas, 1 to 17 days following aSAH, VS was ruled out by DSA in 11 patients. At baseline recording, mean thresholds for left-sided extremity muscles were 67.6 mA for extensor digitorum muscle, 69.2 mA for abductor pollicis brevis muscle, 103.0 mA for tibialis anterior muscle, and 110.8 mA for abductor hallucis muscle. Mean threshold values for right-sided muscles were 70.2 mA for extensor digitorum muscle, 68.5 mA for abductor pollicis brevis muscle, 100.4 mA for tibialis anterior muscle, and 105.9 mA for abductor hallucis muscle. Figure 1 lists these results. Table 3 shows MEP thresholds for 5 patients before and during angiographically verified VS. In all patients exhibiting VS of arteries that supply cerebral motor areas (cases 1-4), a minimum threshold increase of 50 mA and a mean increase of 66.25 mA were observed. In cases 2 and 3, MEPs could not be elicited in some contralateral muscles at the time of VS. Case 5, with VS

**TABLE 3. Motor Evoked Potential Thresholds of 5 Patients in Absence and During Angiographically Verified Vasospasm<sup>a</sup>**

Case Number	Vasospastic Artery	Maximum Narrowing of Vessel Diameter (%)	Muscle	Stim. Site	MEP Threshold at Baseline (mA)	MEP Threshold During Vasospasm (mA)	
1	ACM right	60	Ext. left	C3/4	50	130	
				C4/3	80	130	
			ABP left	C3/4	50	130	
				C4/3	75	130	
2	ACA right	40	TA left	C3/4	170	N/E	
				C4/3	140	N/E	
			ABH left	Cz/Fz	N/A	N/E	
				C3/4	140	N/E	
				C4/3	150	N/E	
3	ICA left	70	Ext. right	C3/4	60	140	
				C4/3	70	140	
			ABP right	C3/4	60	120	
				C4/3	70	150	
				Cz/Fz	N/A	N/E	
			TA right	C3/4	110	N/E	
				C4/3	100	N/E	
				ABH right	C3/4	100	N/E
					C4/3	100	N/E
				Cz/Fz	N/A	N/E	
4	ACM left	80	Ext. right	C3/4	60	120	
				C4/3	65	115	
			ABP right	C3/4	50	110	
				C4/3	50	120	
5	PCA right	60	Ext. left	C3/4	60	90	
				C4/3	65	95	
				Cz/Fz	N/A	N/A	
			ABP left	C3/4	60	90	
				C4/3	65	95	
				Cz/Fz	N/A	N/A	
			TA left	C3/4	90	125	
				C4/3	100	135	
				Cz/Fz	N/A	N/A	
			ABH left	C3/4	130	120	
				C4/3	130	120	
				Cz/Fz	N/A	N/A	
			Ext. right	C3/4	70	80	
				C4/3	65	80	
				Cz/Fz	N/A	N/A	
ABP right	C3/4	60	80				
	C4/3	65	85				
	Cz/Fz	N/A	N/A				
TA right	C3/4	90	110				
	C4/3	100	110				
	Cz/Fz	N/A	N/A				
ABH right	C3/4	130	110				
	C4/3	120	125				
	Cz/Fz	N/A	N/A				

<sup>a</sup>ABP, abductor pollicis muscle; ABH, abductor hallucis muscle; ACA, anterior cerebral artery; ACM, medial cerebral artery; Ext., forearm extensor muscle; ICA, internal carotid artery; N/A, not applicable; N/E, MEPs could not be elicited with a maximum intensity of 220 mA; PCA, posterior cerebral artery; Stim., Site Stimulation site; TA, tibialis anterior muscle.

restricted to the right posterior cerebral artery, exhibited a maximum threshold increase of 35 mA and a mean increase of 15.63 mA. A mean threshold increase of 14.47 mA (range 0–30 mA) from baseline to control was calculated for 11 patients without VS. Therefore, an increase in MEP threshold of  $\geq 50$  mA (“50 or more rule”) from baseline to control was defined as

suggestive of VS and, accordingly, tested for diagnostic accuracy by comparing maximum threshold increase from baseline to control in each patient. There were 5 true-positive, 11 true-negative, 1 false-positive, and 1 false-negative results. Sensitivity, specificity, and positive and negative predictive values of the “50 or more rule” were calculated and are summarized in Tables 4 and 5.

**TABLE 4. Contingency Table Illustrating the MEP Test Results of the Applied "50 or More Rule"<sup>a</sup>**

Test Result	True: Vasospasm	False: No Vasospasm	Total
Positive	4	1	5
Negative	1	10	11
Total	5	11	16

<sup>a</sup>MEP, motor evoked potentials.

One false-positive result was obtained in a patient whose posterior communicating artery aneurysm was clipped and in whom an inadvertent occlusion of the anterior choroidal artery led to an infarction in the early postoperative period. In this patient, significant threshold increases were encountered for all contralateral upper and lower extremity muscles. Because an inadvertent operative occlusion rather than VS led to significant threshold increases in this patient, the test result was considered to be a false positive. One false-negative result was obtained in a patient with VS restricted to the right posterior cerebral artery. In this case, a maximum increase in threshold of only 35 mA was observed and, therefore, considered to be a false negative.

## ILLUSTRATIVE CASE

A 53-year-old woman was admitted to our service after the sudden onset of severe headaches, nuchal rigidity, and confusion 3 hours earlier. A cranial computed tomography revealed a basal subarachnoid hemorrhage and intraventricular blood with mild hydrocephalus. Computed tomography angiography (CTA) revealed a large saccular aneurysm originating from the anterior communicating artery. The patient was transferred to the ICU, anesthesia was induced, and external ventricular drainage placed. Then, the patient was forwarded to the angiography operating room to obtain a DSA (Figure 2B). An interventional radiologist and a vascular neurosurgeon reviewed the DSA images and decided to obliterate the aneurysm by endovascular coiling, which was done on the same day without complications (Figure 2D). During the entire angiography and coiling procedure, no VS was encountered at any time, so the patient underwent baseline MEP recording, as described above, immediately after returning to the ICU. Table 6 lists baseline MEP thresholds.

On day 9 after aSAH, TCD flow velocities for the right-sided anterior and medial cerebral arteries showed a considerable increase of 55 cm/s over values on the day before. MEP thresholds were obtained, as shown in Table 6, and the patient was forwarded to DSA, which revealed a significant spasm of the right-sided M1 (Figure 2B) compared with the initial DSA (Figure 2A) and no spasm of any other artery. Chemical spasmolysis was performed immediately by using intra-arterial administration of nimodipine, which led to a complete normalization of the diameter and blood flow in the M1.

**TABLE 5. The Diagnostic Accuracy of MEPs in Detection of VS Following aSAH Compared With DSA<sup>a</sup>**

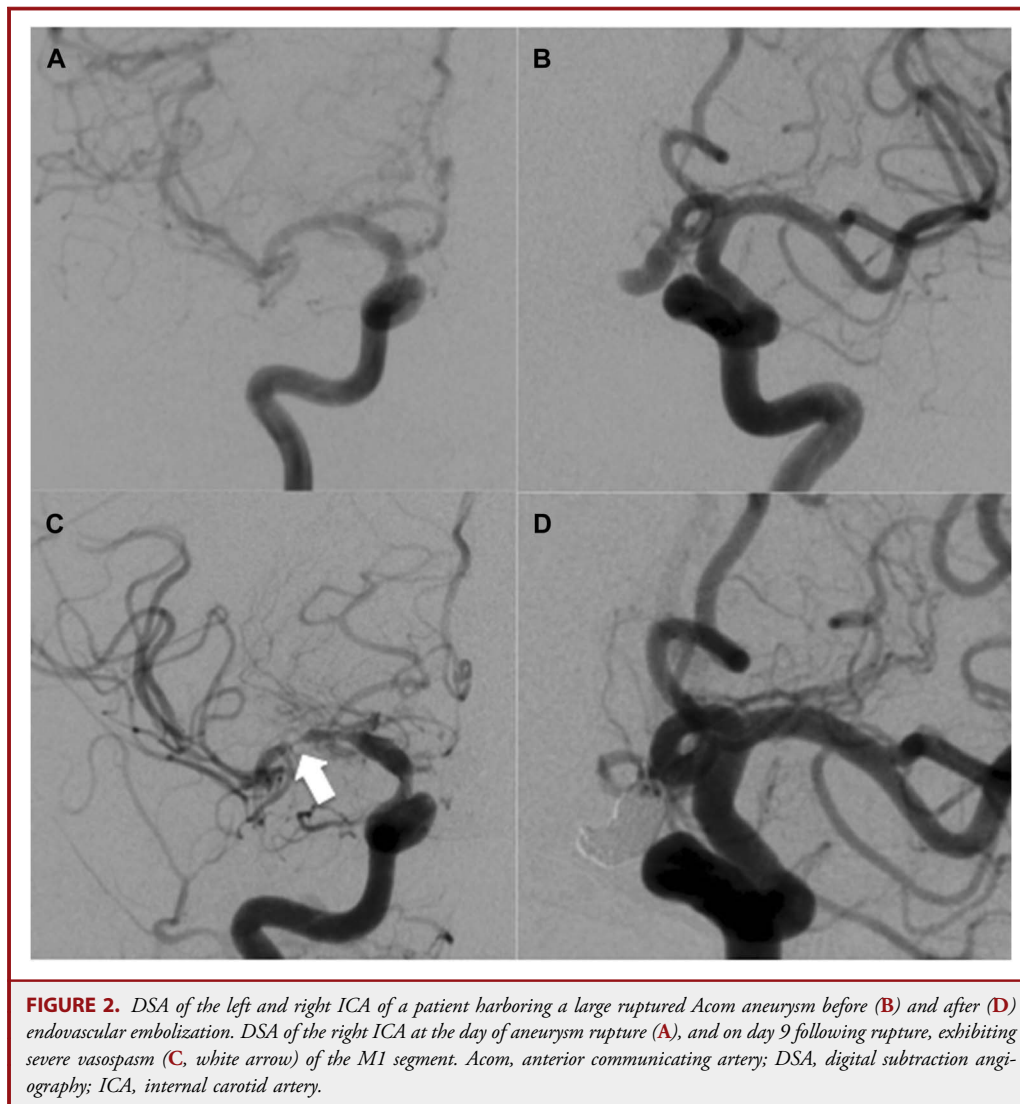
Parameter	Value (in %)
Sensitivity	83.0
Specificity	92.0
Positive predictive value	83.0
Negative predictive value	92.0

<sup>a</sup>aSAH, aneurysmal subarachnoid hemorrhage; DSA, digital subtraction angiography; MEP, motor evoked potential; VS, vasospasm.

## DISCUSSION

### VS Diagnostics

A variety of methods are well established in daily neurosurgical practice, including TCD, CTA, DSA, and PCT.<sup>2,4-6,8,28-30</sup> Neurological assessment at frequent intervals has been found to be the most sensitive, specific parameter for cerebral VS detection,<sup>8</sup> but patients requiring anesthesia or those with impaired conscious states may not be amenable to detailed neurological assessment. Unfortunately, this subgroup often harbors pronounced aSAH and, therefore, carries the highest risk of sustaining VS.<sup>9</sup> TCD is a commonly used, noninvasive, inexpensive bedside method in daily ICU practice that yields high specificity but comparatively low sensitivity in detecting VS. In addition, TCD results are highly operator dependent and have been shown to predict secondary infarction poorly compared with DSA. Furthermore, measurement of TCD is limited by the presence of an appropriate "ultrasound window," which must be permeable to ultrasound waves. In TCD, a variety of factors not attributable to vessel diameter can contribute to elevating flow velocities, and only large-vessel spasms, not peripheral VSs, can be detected.<sup>3,4</sup> CTA and PCT have been proven to detect VS with high sensitivity and specificity and, therefore, can be used as monitoring tools by performing scans regularly in addition to daily TCD.<sup>8</sup> The significance of CTAs is limited by beam-hardening artifacts from clips and coils and in evaluating posterior fossa arteries. As with nearly all imaging methods, CTA and PCT require the patient to be transferred to the imaging unit, which is costly and has been shown to put patients at increased medical risk.<sup>31</sup> Because of these limitations and the exposure of patients to radiation, CTA and PCT are unlikely to be used daily, therefore, increasing the chance that VS is missed or detected too late to prevent delayed ischemic neurological deficit. DSA is considered the gold standard for VS detection because of its ability to demonstrate cerebral VS anatomically with high accuracy and because it offers the opportunity to perform balloon angioplasty and chemical spasmolysis immediately. Often, DSA is performed when clinical VS is suspected. Studies have reported nearly 100% sensitivity and specificity for 2-dimensional DSA in VS detection.<sup>6</sup> Nevertheless, DSA carries considerable risk of neurological complications<sup>32,33</sup> and exposes patients to comparatively high doses of radiation and contrast medium.<sup>29,30</sup>



### MEP and Detecting Cerebral Ischemia

The present study was inspired by the idea that the ideal method for detecting VS would be a minimally invasive, bedside, inexpensive method providing high diagnostic accuracy, repeatable anytime, and yielding information early enough to provide adequate therapy and prevent cerebral infarction. Many studies have proven that this is the case when using MEPs to detect impending cerebral ischemia during aneurysm surgery.<sup>15,16,19,20,22-26,34,35</sup> Because various surgical maneuvers, including VS, temporary clipping, retraction, dissection, and vessel occlusion, may disturb focal circulation, a sensitive, specific method is needed to alert surgeons in a timely way during surgery. Therefore, transcranial or direct cortical stimulation of the primary motor cortex is used to produce depolarized action potentials that can be recorded at short intervals from muscles during aneurysm surgery.<sup>15</sup> Given that, it seemed worthwhile to

adopt this approach and evaluate MEPs for their diagnostic accuracy in detecting delayed VS following aSAH. For their use in an ICU, we slightly modified MEP recording parameters compared with parameters used to monitor intraoperatively during aneurysm surgery. To minimize movement artifacts, we used the threshold technique, gradually increasing stimulus intensity in 5-mA steps, starting as low as 30 mA. With that technique, we were able to determine the minimal stimulus intensity needed to elicit MEPs for each target muscle separately, which is defined as its threshold. Conversely, for intraoperative monitoring, a stimulus intensity strong enough to elicit MEPs in all target muscles is selected, and, therefore, MEP amplitudes and, to a lesser extent, MEP latencies are evaluated for significant changes. Clearly, this is a less time-consuming approach compared with the threshold method described above, and time is of paramount importance in intraoperative monitoring, which

**TABLE 6. MEP Thresholds of a Patient at Day of Aneurysm Rupture and on the Day of Exhibiting Angiographic VS of the Right M1<sup>a</sup>**

Muscle	Stimulation Site	MEP	
		Threshold at Baseline	MEP Threshold during Right MCA Vasospasm
Ext. left	C3/C4	50	130
	C4/C3	80	130
ABP left	C3/C4	50	130
	C4/C3	75	130
TA left	C3/C4	55	75
	C4/C3	65	80
ABH	C3/C4	50	70
	C4/C3	130	130
Ext. right	C3/C4	50	60
	C4/C3	65	75
ABP right	C3/C4	50	80
	C4/C3	50	80
TA right	C3/C4	50	60
	C4/C3	130	160
ABH right	C3/C4	50	75
	C4/C3	70	75

<sup>a</sup>ABH, abductor hallucis muscle; ABP, abductor pollicis muscle; Ext., forearm extensor muscle; MCA, medial cerebral artery; MEP, Motor evoked potentials; TA, tibialis anterior muscle; VS, Vasospasm.

must interfere as little as possible with surgery. We demonstrated that MEP recording with the threshold technique could be completed bedside in 16 to 31 minutes in an ICU, which compares favorably to all methods requiring intrahospital patient transport.

### Limitations

This method and the present study have several limitations. From the methodological perspective, MEPs have limited diagnostic value because they enable detection of VS only in vascular territories that supply the motor cortex or the corticospinal tracts, missing any VS restricted to nonmotor areas. Although the most important cerebrovascular territories may be covered by MEP monitoring, 1 patient in the study exhibited VS limited to the

**TABLE 7. Diagnostic Accuracy of Different Methods Compared With Digital Subtraction Angiography<sup>a,b</sup>**

Method	Sensitivity	Specificity	PPV	NPV
Neurological assessment	1.00	0.33	0.69	1.00
TCD	0.77	0.44	0.73	0.62
Perfusion CT	0.93	0.27	0.71	0.67
MEPs	0.80	0.91	0.80	0.91

<sup>a</sup>MEP, motor evoked potentials; NPV, negative predictive value; Perfusion CT, perfusion computed tomography; PPV, positive predictive value; TCD, transcranial Doppler sonography.

<sup>b</sup>Adapted from Kunze et al.<sup>8</sup>

posterior cerebral artery, which insignificantly affected MEP thresholds. Accordingly, relying on MEPs alone would have missed VS in this patient. Another limitation is that MEP recordings as presented here can be used only in anesthetized patients, because conscious patients could not tolerate the needle electrodes and high stimulus intensities. In contrast, it is likely that conscious patients are amenable to neurological assessment, which has been proven to detect VS with supreme sensitivity.<sup>8</sup> Given that, these patients do not require another, more invasive bedside method. Table 7 summarizes the results of a study by Kunze et al<sup>8</sup> in which the authors prospectively evaluated the diagnostic accuracy of neurological assessment, TCD, and PCT in VS detection compared with DSA. As Table 7 shows, when MEPs were compared with TCD, it provided at least comparable sensitivity and superior specificity. Because of the limitations of both MEPs and TCD, they may complement each other to reduce the overall rate of false-negative results.

### CONCLUSION

MEPs can detect VS following aSAH with high accuracy, are a feasible bedside tool for online VS detection in an ICU, and, therefore, may complement existing diagnostic tools. MEPs may contribute to a decreased rate of cerebral ischemia following VS. Future technical refinement may include increasing the practicality of MEP recording for this indication. Further studies seem warranted to address the input of this technique on clinical outcomes in patients sustaining aSAH.

### Disclosure

The authors have no personal, financial, or institutional interest in any of the drugs, materials, or devices described in this article.

### REFERENCES

- Steiner T, Juvela S, Unterberg A, et al. European stroke organization guidelines for the management of intracranial aneurysms and subarachnoid haemorrhage. *Cerebrovasc Dis.* 2013;35(2):93-112.
- Lad SP, Guzman R, Kelly ME, et al. Cerebral perfusion imaging in vasospasm. *Neurosurg Focus.* 2006;21(3):E7.
- Halsey JH. Effect of emitted power on waveform intensity in transcranial Doppler. *Stroke.* 1990;21(11):1573-1578.
- Wang HS, Kuo MF. Supraorbital approach of the anterior cerebral artery: a new window for transcranial Doppler sonography. *J Ultrasound Med.* 1995;14(4):259-261.
- Bathala L, Mehndiratta MM, Sharma VK. Transcranial doppler: technique and common findings (Part 1). *Ann Indian Acad Neurol.* 2013;16(2):174-179.
- Mills JN, Mehta V, Russin J, Amar AP, Rajamohan A, Mack WJ. Advanced imaging modalities in the detection of cerebral vasospasm. *Neurol Res Int.* 2013;2013:415960.
- Gollwitzer S, Groemer T, Rampp S, et al. Early prediction of delayed cerebral ischemia in subarachnoid hemorrhage based on quantitative EEG: a prospective study in adults. *Clin Neurophysiol.* 2015;126(8):1514-1523.
- Kunze E, Pham M, Raslan F, et al. Value of perfusion CT, transcranial doppler sonography, and neurological examination to detect delayed vasospasm after aneurysmal subarachnoid hemorrhage. *Radiol Res Pract.* 2012;2012:231206.
- Fisher CM, Kistler JP, Davis JM. Relation of cerebral vasospasm to subarachnoid hemorrhage visualized by computerized tomographic scanning. *Neurosurgery.* 1980;6(1):1-9.

10. White CP, Cooke RW. Somatosensory evoked potentials following posterior tibial nerve stimulation predict later motor outcome. *Dev Med Child Neurol.* 1994;36(1):34-40.
11. Chen R, Bolton CF, Young B. Prediction of outcome in patients with anoxic coma: a clinical and electrophysiologic study. *Crit Care Med.* 1996;24(4):672-678.
12. Mazzini L, Pisano F, Zaccala M, Miscio G, Gareri F, Galante M. Somatosensory and motor evoked potentials at different stages of recovery from severe traumatic brain injury. *Arch Phys Med Rehabil.* 1999;80(1):33-39.
13. Carter BG, Butt W. A prospective study of outcome predictors after severe brain injury in children. *Intensive Care Med.* 2005;31(6):840-845.
14. Carter BG, Butt W. Are somatosensory evoked potentials the best predictor of outcome after severe brain injury? A systematic review. *Intensive Care Med.* 2005;31(6):765-775.
15. Yue Q, Zhu W, Gu Y, et al. Motor evoked potential monitoring during surgery of middle cerebral artery aneurysms: a cohort study. *World Neurosurg.* 2014;82(6):1091-1099.
16. Suzuki K, Mikami T, Sugino T, et al. Discrepancy between voluntary movement and motor-evoked potentials in evaluation of motor function during clipping of anterior circulation aneurysms. *World Neurosurg.* 2014;82(6):e739-e745.
17. Kang D, Yao P, Wu Z, Yu L. Ischemia changes and tolerance ratio of evoked potential monitoring in intracranial aneurysm surgery. *Clin Neurol Neurosurg.* 2013;115(5):552-556.
18. Shi C, Zhou Q, Zhang M, Jiang Y. Assessment of intraoperative motor-evoked potentials for predicting postoperative motor function during the surgical clipping of intracranial aneurysms [in Chinese]. *Zhong Nan Da Xue Xue Bao Yi Xue Ban.* 2012;37(3):244-249.
19. Motoyama Y, Kawaguchi M, Yamada S, et al. Evaluation of combined use of transcranial and direct cortical motor evoked potential monitoring during unruptured aneurysm surgery. *Neurol Med Chir (Tokyo).* 2011;51(1):15-22.
20. Guo L, Gelb AW. The use of motor evoked potential monitoring during cerebral aneurysm surgery to predict pure motor deficits due to subcortical ischemia. *Clin Neurophysiol.* 2011;122(4):648-655.
21. Lopez JR. Neurophysiologic intraoperative monitoring of pediatric cerebrovascular surgery. *J Clin Neurophysiol.* 2009;26(2):85-94.
22. Szelenyi A, Langer D, Kothbauer K, De Camargo AB, Flamm ES, Deletis V. Monitoring of muscle motor evoked potentials during cerebral aneurysm surgery: intraoperative changes and postoperative outcome. *J Neurosurg.* 2006;105(5):675-681.
23. Quinones-Hinojosa A, Alam M, Lyon R, Yingling CD, Lawton MT. Transcranial motor evoked potentials during basilar artery aneurysm surgery: technique application for 30 consecutive patients. *Neurosurgery.* 2004;54(4):916-924; discussion 924.
24. Neuloh G, Schramm J. Monitoring of motor evoked potentials compared with somatosensory evoked potentials and microvascular Doppler ultrasonography in cerebral aneurysm surgery. *J Neurosurg.* 2004;100(3):389-399.
25. Szelenyi A, Bueno de Camargo A, Flamm E, Deletis V. Neurophysiological criteria for intraoperative prediction of pure motor hemiplegia during aneurysm surgery. Case report. *J Neurosurg.* 2003;99(3):575-578.
26. Kaga A, Fujiki M, Hori S, Nakano T, Isono M. Motor evoked potentials following transcranial magnetic stimulation after middle cerebral artery and/or basilar artery occlusions in rats. *J Clin Neurosci.* 2003;10(4):470-475.
27. Goksel HM, Akgun M, Topalkara K, Solak O, Topaktas S. Evaluation of cerebral vasospasm with transcranial magnetic stimulation: an experimental study. *Clin Exp Med.* 2001;1(1):43-49.
28. Lee Y, Zuckerman SL, Mocco J. Current controversies in the prediction, diagnosis, and management of cerebral vasospasm: where do we stand? *Neurol Res Int.* 2013;2013:373458.
29. Yao GE, Li Q, Jiang XJ, et al. Vasospasm after subarachnoid hemorrhage: a 3D rotational angiography study. *Acta Neurochir Suppl.* 2011;110(pt 2):221-225.
30. Chaudhary SR, Ko N, Dillon WP, et al. Prospective evaluation of multidetector-row CT angiography for the diagnosis of vasospasm following subarachnoid hemorrhage: a comparison with digital subtraction angiography. *Cerebrovasc Dis.* 2008;25(1-2):144-150.
31. Picetti E, Antonini MV, Lucchetti MC, et al. Intra-hospital transport of brain-injured patients: a prospective, observational study. *Neurocrit Care.* 2013;18(3):298-304.
32. Komiyama M, Yamanaka K, Nishikawa M, Izumi T. Prospective analysis of complications of catheter cerebral angiography in the digital subtraction angiography and magnetic resonance era. *Neurol Med Chir.* 1998;38(9):534-539; discussion 539-540.
33. Warnock NG, Gandhi MR, Bergvall U, Powell T. Complications of intraarterial digital subtraction angiography in patients investigated for cerebral vascular disease. *Br J Radiol.* 1993;66(790):855-858.
34. Horiuchi K, Suzuki K, Sasaki T, et al. Intraoperative monitoring of blood flow insufficiency during surgery of middle cerebral artery aneurysms. *J Neurosurg.* 2005;103(2):275-283.
35. Deletis V. What does intraoperative monitoring of motor evoked potentials bring to the neurosurgeon? *Acta Neurochir (Wien).* 2005;147(10):1015-1017.

## COMMENT

Vasospasm (VS) and its deleterious effects following aneurysmal subarachnoid hemorrhage (SAH) have been extensively documented.<sup>1</sup> Given the delayed onset of vasospasm and the perception that it is a secondary event following SAH, immense effort has been made into studying the risk factors and predictors of VS. The majority of these studies continue to reinforce the observation that (a) the occurrence and (b) the severity of cerebral vasospasm relate to the quantum of blood in the subarachnoid spaces.<sup>2-4</sup> The gold standard for diagnosis of cerebral vasospasm has been digital subtraction angiography. The burden of clot is most evident on CT imaging and traditionally has been sufficient to raise the alarm as to which patients tend to have the potential for vasospasm.

The issue however gets more complicated from there on. Not all patients with angiographic vasospasm are clinically symptomatic from it, while at the same time clinical symptoms that reverse with the increase in cerebral perfusion from raising systemic blood pressure is sufficient to diagnose vasospasm without imaging (other causes being ruled out). Therefore, a prudent management strategy would incorporate a stance between aggressive angiography “for all” and reliance on clinical examination only, to effectively predict and diagnose vasospasm and decide further on treatment. At a practical level, present modalities are either directed toward imaging definition of spasm (transcranial Doppler [TCD], CT angiography [CTA], digital subtraction angiography [DSA]) or the pathological effects of spasm on brain function (electroencephalogram [EEG], somatosensory evoked potential [SSEP], brain tissue oxygen tension, cerebrospinal fluid [CSF] markers of inflammation).

In the present study, the authors describe an interesting prospectively designed study in patients with high-grade SAH in which they noted the extent of correlation of changes in motor evoked potentials (MEPs) with angiographic vasospasm. They mention that MEP variations in the form of increase in threshold values and/or decrease in amplitudes correlate with angiographic spasm with very high sensitivity, specificity, and predictive values. The pathophysiology behind the observation is intuitive and the authors are successful in corroborating a downstream physiological effect of cortical ischemia to the causative factor, namely cerebral vasospasm. However, the exclusion of conscious patients (irrespective of the burden of subarachnoid blood on the admission CT scan) is a missed opportunity of studying how these individuals are different from patients with similar clot burden. Indeed, there is the obvious difficulty of subjecting a conscious patient to this rather painful procedure, especially in the context of a study. The other drawback of the study is the lack of demonstration of consistent improvement of MEPs with vasodilator therapy. The inability to detect distal small-vessel spasm is a significant limitation, too. The data are ultimately not robust enough to convince vascular neurosurgeons to supplant or supplement established diagnostic modalities that most commonly involve vascular imaging.



Changes in MEP parameters may indeed be correlated with VS, but this technique still needs substantial investment in terms of time and personnel. In addition, very much like TCD, recording MEPs is an intentionally triggered event in contrast to detecting seizure activity by continuous EEG monitoring, for example. The practical day-to-day utility of MEP monitoring for physicians who manage patients with SAH is uncertain. An apt analogy of a reliable and proven monitoring technique in acute vascular care is the combination of electrocardiographic telemetry monitoring and repeated cardiac enzyme levels in patients with acute coronary syndromes.<sup>5</sup> The neurovascular community is in desperate need of a similar protocol for managing vasospasm in SAH.

**Mithun G. Sattur**  
**Tariq K. Halasa**  
**Bernard R. Bendok**  
*Phoenix, Arizona*

1. Findlay JM, Nisar J, Darsaut T. Cerebral vasospasm: a review. *Can J Neurol Sci.* 2015;1–18.
2. Harrod CG, Bendok BR, Batjer HH. Prediction of cerebral vasospasm in patients presenting with aneurysmal subarachnoid hemorrhage: a review. *Neurosurgery.* 2005;56(4):633–654.
3. Abba AA, Wilson DA, Williamson RW, et al. The relationship between ruptured aneurysm location, subarachnoid hemorrhage clot thickness, and incidence of radiographic or symptomatic vasospasm in patients enrolled in a prospective randomized controlled trial. *J Neurosurg.* 2014;120(2):391–397.
4. Yin L, Ma CY, Li ZK, Wang DD, Bai CM. Predictors analysis of symptomatic cerebral vasospasm after subarachnoid hemorrhage. *Acta Neurochir Suppl.* 2011;110 (pt 2):175–178.
5. Antman EM, Anbe DT, Armstrong PW, et al; American College of Cardiology; American Heart Association; Canadian Cardiovascular Society. ACC/AHA guidelines for the management of patients with ST-elevation myocardial infarction—executive summary. A report of the American College of Cardiology/American Heart Association Task Force on Practice Guidelines (Writing Committee to revise the 1999 guidelines for the management of patients with acute myocardial infarction). *J Am Coll Cardiol.* 2004;44(3):671–719.

### Research Reporting Guidelines

*Neurosurgery*<sup>®</sup> endorses several major reporting guidelines and requires authors to submit their articles in accordance with the guidelines relevant to the research design used. Completed checklists and flow diagrams must be included with submissions, and are available to reviewers and editors during peer-review.

Reporting Guidelines endorsed by *Neurosurgery*<sup>®</sup> include:

**CONSORT** (Consolidated Standards of Reporting Trials)  
<http://www.consort-statement.org>

**PRISMA** (Preferred Reporting Items for Systematic Reviews and Meta-Analyses)  
<http://www.prisma-statement.org>

**MOOSE** (Meta-Analysis of Observational Studies in Epidemiology)  
<http://www.equator-network.org>

**STARD** (Standards for the Reporting of Diagnostic Accuracy Studies)  
<http://www.stard-statement.org>

**STROBE** (Strengthening the Reporting of Observational Studies in Epidemiology)  
<http://www.strobe-statement.org>

*Neurosurgery*<sup>®</sup> supports the **EQUATOR Network**, and invites authors to consult their web site (<http://www.equator-network.org>), which maintains a useful, up-to-date list of guidelines as they are published, with links to the articles and checklists.

For more information, please see the journal's Instructions for Authors at <http://journals.lww.com/neurosurgery/Pages/InformationforAuthors.aspx>.

**NEUROSURGERY**