

Case Studies

A Case of Recurrent Ischemic Stroke Involving Subacute, Progressive Intracranial Cerebral Arterial Sclerosis Prior to Diagnosis with *JAK2*-mutated Polycythemia Vera

Tomohisa Nezu, MD, PhD,* Shiro Aoki, MD, PhD,* Kazuhide Ochi, MD, PhD,*
Sayaka Sugihara, MD, PhD,† Tetsuya Takahashi, MD, PhD,*
Naohisa Hosomi, MD, PhD,* Hirofumi Maruyama, MD, PhD,* and
Masayasu Matsumoto, MD, PhD*

Case Report: A 58-year-old man presenting with no vascular risk factors visited our hospital with right hemiparesis and total aphasia. Diffusion-weighted magnetic resonance imaging of the brain showed multiple hyperintensities in watershed distributions in the left hemisphere. Magnetic resonance angiography (MRA) revealed stenosis of the middle cerebral artery, despite normal MRA findings 2 months prior. One year after the first stroke, the patient experienced a recurrent ischemic stroke involving the left anterior choroidal artery, pulmonary embolism, and deep venous thrombosis. After the recurrent stroke event, hemoglobin levels increased gradually. Two years after the first stroke, a *JAK2V-617F* mutation was detected. *Conclusion:* Our report suggests that progressive intracranial arterial sclerosis and venous thrombosis of undetermined etiologies could be several initial symptoms of polycythemia vera. **Key Words:** *JAK2V-617F* mutation—polycythemia vera—ischemic stroke—intracranial artery stenosis.

© 2015 National Stroke Association. Published by Elsevier Inc. All rights reserved.

From the *Department of Clinical Neuroscience and Therapeutics, Hiroshima University Graduate School of Biomedical and Health Sciences, Hiroshima, Japan; and †Division of Radiation Information Registry, Research Institute for Radiation Biology and Medicine, Hiroshima University, Hiroshima, Japan.

Received July 21, 2015; revision received August 20, 2015; accepted August 28, 2015.

Grant support: This study was supported in part by a research grant from the Japan Heart Foundation.

Conflict of interest: None.

Address correspondence to Tomohisa Nezu, Department of Clinical Neuroscience and Therapeutics, Hiroshima University Graduate School of Biomedical Sciences, 1-2-3 Kasumi, Minami-ku, Hiroshima 734-8551, Japan. E-mail: tomonezu@hiroshima-u.ac.jp.

1052-3057/\$ - see front matter

© 2015 National Stroke Association. Published by Elsevier Inc. All rights reserved.

<http://dx.doi.org/10.1016/j.jstrokecerebrovasdis.2015.08.040>

Introduction

Polycythemia vera (PV) is a myeloproliferative disorder characterized by excessive erythrocytosis, leukocytosis, and bone marrow hypercellularity. In a large prospective study of 1638 patients with PV, the cumulative rate of cerebrovascular events is 5.5 events per 100 persons per year.¹ Therefore, preventing cerebrovascular events in PV patients is very important. Some studies have shown that thrombosis events, especially in the splanchnic major veins, may underlie a latent myeloproliferative disorder without increased whole blood counts and precede its definitive diagnosis by 1-2 years.^{2,3} However, patients with a latent myeloproliferative disorder experiencing an ischemic stroke are rare. Here, we present a report of an ischemic stroke patient with progressive intracranial arterial sclerosis and venous thrombosis prior to diagnosis with *JAK2*-mutated PV.

Case Report

A 58-year-old man presenting with no vascular risk factors visited our hospital with right hemiparesis and total aphasia. The patient experienced a slow progressive cognitive disturbance as well as several episodes of right arm weakness over the previous 3 months despite normal magnetic resonance imaging findings, including magnetic resonance angiography, from 2 months prior. Upon admission, diffusion-weighted magnetic resonance imaging showed hyperintensities on the border between the left middle cerebral artery and the posterior cerebral artery (Fig 1, A). Magnetic resonance angiography and left internal carotid angiography revealed middle cerebral artery stenosis (Fig 1, B,C). Although the patient received antithrombotic therapy combined with argatroban, clopidogrel, and cilostazol, the ischemic lesions increased, and the left middle cerebral artery became occluded (Fig 1, D-F). Upon admission, laboratory testing indicated a leukocyte count of $18.5 \times 10^3/\mu\text{L}$, a hemoglobin level of 14.3 g/dL, and a platelet count of $267 \times 10^3/\mu\text{L}$. Other laboratory findings, including inflammation, coagulation, and the presence of autoantibodies, were normal. One year after the first stroke, the patient experienced a recurrent ischemic stroke in the left anterior choroidal artery (Fig 1, G,H), pulmonary embolism, and deep venous thrombosis. Transesophageal echocardiography to detect a right to left shunt was not performed. Anticoagulation therapy with warfarin was combined with antiplatelet therapy (cilostazol). The patient's laboratory values were slightly elevated and included a leukocyte count of $13.0 \times 10^3/\mu\text{L}$, a hemoglobin level of 15.6 g/dL, and a

platelet count of $403 \times 10^3/\mu\text{L}$. After the recurrent stroke event, the patient's leukocyte and hemoglobin values gradually increased. Two years after the first stroke, the patient presented with proximal occlusion of the internal carotid artery (Fig 1, I), a leukocyte count of $16.6 \times 10^3/\mu\text{L}$, a hemoglobin level of 18.1 g/dL, and a platelet count of $287 \times 10^3/\mu\text{L}$. In addition, the intima-media thickness (IMT) of the right common carotid artery increased (max IMT, 2.8 mm), although the right common carotid IMT was normal 2 years ago. A *JAK2-V617F* mutation was detected, although the erythropoietin levels of the patient were normal. Based on these results, the patient was diagnosed with PV. Phlebotomy began in combination with anticoagulation and antiplatelet therapy. At 1 year postcombination therapy, no recurrence was evident.

Discussion

JAK2-V617F mutations occur in 95% of PV cases and in 50%-60% of other myeloproliferative neoplasms, such as essential thrombocythemia and idiopathic myelofibrosis.^{4,5} *JAK2-V617F* mutations are associated with a significantly increased thrombosis risk.⁶ Although the exact mechanisms for the association between *JAK2-V617F* mutations and thrombosis remain unclear, many factors, such as cellular interactions between leukocytes, platelets, and endothelial cells, could contribute to the hypercoagulability.^{7,8} In the present case, the white blood cell count was increasing at the first thrombotic events, despite normal hemoglobin levels. Some studies have indicated that leukocytosis might promote a hypercoagulability state and

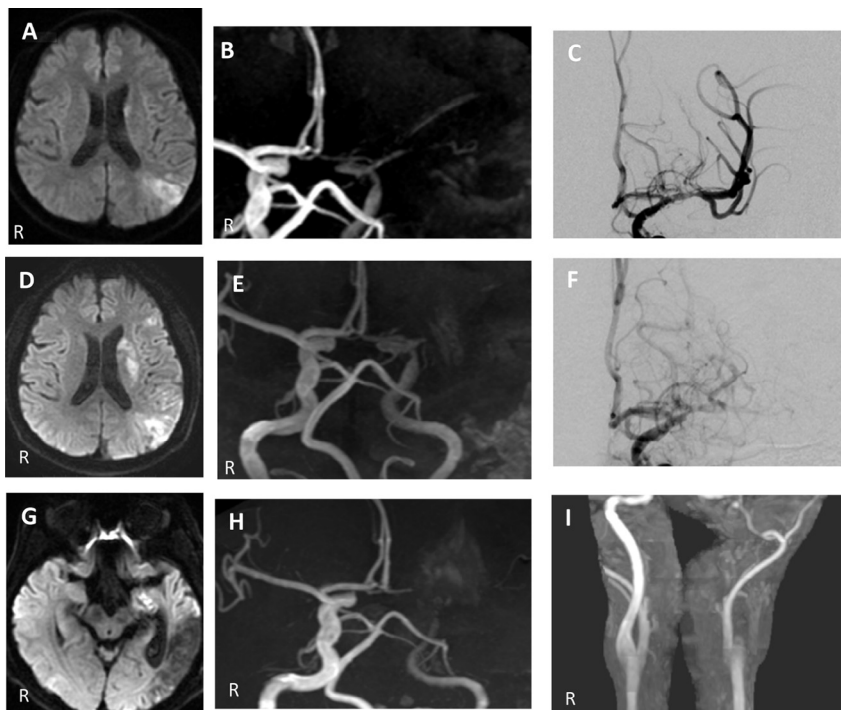


Figure 1. (A) Diffusion-weighted MRI (DWI) at the first admission. (B) MRA at the first admission. (C) Anteroposterior (AP) view of the left internal carotid angiograph showing middle cerebral artery stenosis 1 day after the onset of the first stroke. (D) DWI on day 7 after the first stroke. (E) MRA on day 7 after the first stroke. (F) AP view of the left internal carotid angiograph showing middle cerebral artery occlusion on day 7 after the first stroke. (G) DWI at the second admission. (H) MRA at the second admission. (I) MRA 2 years after the first stroke. Abbreviations: DWI, diffusion-weighted imaging; MRA, magnetic resonance angiography; MRI, magnetic resonance imaging.

endothelial damage in patients with *JAK2-V617F* mutations.^{7,9}

In the present case, the patient suffered from both progressive intracranial arterial stenosis and venous thrombosis. The etiologies of ischemic stroke caused by *JAK2-V617F* mutations reveal different patterns, such as microvascular disturbances, large vessel thrombosis, and arterial dissection.¹⁰⁻¹² In the present case, the first stroke event was attributed to thrombosis secondary to progressive intracranial arterial stenosis. However, the recurrent stroke event was attributed to various etiologies, including atherothrombosis and hemodynamic disturbance. Although we did not perform transesophageal echocardiography to detect a right-to-left shunt, it is also important to consider paradoxical embolism as a potential cause of stroke. Additionally, the patient's right common carotid artery IMT increased over a period of 2 years, although the patients had no traditional vascular risk factors. Therefore, *JAK2-V617F* mutations may influence systematic arteries and veins. Although antiplatelet therapy has been significantly associated with a lower risk of cardiovascular events, venous thrombosis also occurs frequently in some large PV studies (more than 1000 patients).^{1,13} Therefore, anticoagulation therapy could be considered in those cases. Additionally, cytoreductive therapy in combination with antiplatelet therapy could be useful to reduce future thrombotic events.¹⁴

This patient presented with a unique case of *JAK2-V617F*-mutated PV, with normal hemoglobin and platelet levels when the first stroke occurred. Interestingly, *JAK2-V617F* mutations have been detected in patients with cerebral venous thrombosis, despite normal whole blood counts.¹⁵ Additionally, several studies have shown that portal vein thrombosis and intra-abdominal thrombosis might underlie latent myeloproliferative neoplasm.^{2,3} Physicians should consider *JAK2-V617F* mutations as a potential cause of ischemic stroke with an undetermined etiology, especially in patients with leukocytosis and venous thrombosis, even if the patient does not meet the clinical criteria for myeloproliferative diseases.

References

1. Marchioli R, Finazzi G, Landolfi R, et al. Vascular and neoplastic risk in a large cohort of patients with polycythemia vera. *J Clin Oncol* 2005;23:2224-2232.
2. Michiels JJ, Commandeur S, Hoogenboom GJ, et al. *JAK2(V617F)* positive early stage myeloproliferative disease (essential thrombocythemia) as the cause of portal vein thrombosis in two middle-aged women: therapeutic implications in view of the literature. *Ann Hematol* 2007;86:793-800.
3. Brière JB. Budd-Chiari syndrome and portal vein thrombosis associated with myeloproliferative disorders: diagnosis and management. *Semin Thromb Hemost* 2006;32:208-218.
4. James C, Ugo V, Le Couédic JP, et al. A unique clonal *JAK2* mutation leading to constitutive signalling causes polycythaemia vera. *Nature* 2005;434:1144-1148.
5. Kilpivaara O, Levine RL. *JAK2* and *MPL* mutations in myeloproliferative neoplasms: discovery and science. *Leukemia* 2008;22:1813-1817.
6. Passamonti F, Elena C, Schnittger S, et al. Molecular and clinical features of the myeloproliferative neoplasm associated with *JAK2* exon 12 mutations. *Blood* 2011;117:2813-2816.
7. Falanga A, Marchetti M, Evangelista V, et al. Polymorphonuclear leukocyte activation and hemostasis in patients with essential thrombocythemia and polycythemia vera. *Blood* 2000;96:4261-4266.
8. Falanga A, Marchetti M, Vignoli A, et al. Leukocyte-platelet interaction in patients with essential thrombocythemia and polycythemia vera. *Exp Hematol* 2005;33:523-530.
9. Passamonti F, Rumi E, Pascutto C, et al. Increase in leukocyte count over time predicts thrombosis in patients with low-risk essential thrombocythemia. *J Thromb Haemost* 2009;7:1587-1589.
10. Billakota S, El Hussein N. Pearls & oysters: polycythemia vera presenting with ischemic strokes in multiple arterial territories. *Neurology* 2014;82:e168-e170.
11. Naganuma M, Isoda K, Nishi S, et al. Repeated episodes of ischemic stroke over a short period in a patient with essential thrombocythemia on anticoagulant therapy. *J Stroke Cerebrovasc Dis* 2014;23:166-168.
12. Richard S, Perrin J, Baillot PA, et al. Ischaemic stroke and essential thrombocythemia: a series of 14 cases. *Eur J Neurol* 2011;18:995-998.
13. Polycythemia vera: the natural history of 1213 patients followed for 20 years. Gruppo Italiano Studio Policitemia. *Ann Intern Med* 1995;123:656-664.
14. Landolfi R, Marchioli R, Kutti J, et al. Efficacy and safety of low-dose aspirin in polycythemia vera. *N Engl J Med* 2004;350:114-124.
15. Passamonti SM, Biguzzi E, Cazzola M, et al. The *JAK2 V617F* mutation in patients with cerebral venous thrombosis. *J Thromb Haemost* 2012;10:998-1003.