

Misconnections in the Critically Ill: Injection of High-Dose Gadolinium into an External Ventricular Drain

Sumit Singh, MD,* Sepehr Rejai, MD,* Zarah Antongiorgi, MD,* Nestor Gonzalez, MD, FAANS, FAHA,† and Matthias Stelzner, MD, FACS‡

We report an unfortunate case of accidental administration of intrathecal gadolinium through an external ventricular drain in a postcraniotomy patient during magnetic resonance imaging of the brain. The incident occurred after the venous contrast line was connected mistakenly to the ventricular drainage catheter. The patient subsequently developed confusion, aphasia, and right facial droop with new computed tomography evidence of diffuse cerebral edema and stroke. Review of the magnetic resonance image revealed the inappropriate presence of subarachnoid gadolinium. Despite all interventions, the patient developed irreversible neurologic disability. We address the clinical sequelae, management strategies, and factors contributing to the catheter misconnection that led to this event. (A&A Case Reports. 2016;6:121–3.)

Within the practice of anesthesiology and perioperative medicine, there has been a historical commitment to minimizing the potential for errors and improving patient safety. Despite our specialty's success in eliminating preventable adverse patient outcomes in many areas, we continue to witness reports of wrong-route administration of medications involving epidural and intrathecal catheters with devastating consequences to the patient.

Patient care within the operating room or intensive care unit (ICU) requires a complex combination of vascular access lines, invasive hemodynamic monitors, and therapeutic catheters and drains. The tubing and syringes designed to link devices to each other and to patients may be joined erroneously via the ubiquitous Luer connector. Although its compatibility with a vast range of medical tubing gives the Luer connector versatility, it is a point of weakness in the perfect storm of environmental and operator-dependent conditions. Our case details a previously unreported wrong-route injection of IV gadolinium dye into the external ventricular drain (EVD) of a patient in the ICU.

In 2012, Birnbach and Vincent¹ made a passionate appeal for systems improvement involving spinal and epidural catheters. Three years have passed since this publication, and we appear no closer to a reliable remedy to this iatrogenic problem. Although technological innovations have continued during these years and clinical practice has evolved positively with emerging outcomes data, our patient's story offers a necessary reminder of a disconcerting outcome and a source of motivation for urgent change.

CONSENT FOR PUBLICATION

We have made multiple attempts to contact the patient's legal designee but have not been successful. We thus sought approval from our local IRB, who determined that approval is not required.

CASE DESCRIPTION

A 59-year-old man was transferred to our facility for neurosurgical management after evaluation of headaches and syncope revealed a right tentorial meningioma. The initial examination by the neurosurgery service and laboratory tests were all within normal range.

Before the planned surgical resection, the patient underwent cerebral angiography and coil embolization of the distal right middle meningeal artery to reduce tumor blood flow. Two days later, he underwent an uncomplicated right temporal craniotomy, tentorial meningioma resection, cranioplasty with titanium mesh, and EVD placement. The patient was extubated tracheally in the postanesthesia care unit, with no change in his neurologic status from baseline. The EVD was connected to a closed system and left open to drain at 10 cm H₂O.

The first 2 postoperative days were uneventful. Head computed tomography on day 1 showed the expected postoperative changes. Intracranial pressure (ICP) readings and cerebrospinal fluid (CSF) drain output also were within normal range. On day 3, the patient went to the radiology suite for a routine postoperative magnetic resonance imaging (MRI) before and after administration of 10 mL of IV gadolinium contrast.

Upon returning from the MRI suite, the patient initially complained of nausea and then during the next hour became acutely hypertensive. The EVD was draining clear CSF at 0 to 5 mL/h with ICP reading 3 to 9 mm Hg. On examination, he was anxious but alert to person, place, time, and purpose. His speech was fluent. He denied visual changes, muscle weakness, or sensory changes. This constellation of symptoms was attributed to early benzodiazepine withdrawal or undertreated general anxiety. His symptoms resolved with lorazepam and restoril, and he slept through the night.

The next morning, the patient's status had notably declined. He developed rapidly progressing aphasia, right facial droop, and delirium. For comparison, the MRI from

From the *Department of Anesthesiology and Perioperative Medicine, †Neurosurgery, and ‡VA Greater Los Angeles Health Care System, UCLA Medical Center, Los Angeles, California.

Accepted for publication May 31, 2015.

Funding: None.

The authors declare no conflicts of interest.

Drs. Rejai and Antongiorgi are second coauthors of this manuscript.

Address correspondence to Sumit Singh, MD, Department of Anesthesiology and Perioperative Medicine, University of California, Los Angeles, 757 Westwood Plaza, Los Angeles, CA 90024. Address e-mail to SPSingh@mednet.ucla.edu.

Copyright © 2015 International Anesthesia Research Society
DOI: 10.1213/XAA.0000000000000230

the night before was reviewed by the neurosurgery service and demonstrated extensive intrathecal gadolinium on the postcontrast MRI. This was then confirmed by obtaining an MRI of the EVD reservoir bag, which was positive for gadolinium.

The ventriculostomy catheter was immediately left open to facilitate evacuation of the gadolinium. A lumbar drain was not placed because of the level of edema in the posterior fossa and risk of herniation. The patient was electively tracheally intubated for airway protection. Treatment of cerebral edema included hyperventilation, monitoring serial arterial blood gases with a goal $Paco_2$ of 30 and 35 mm Hg, administration of IV dexamethasone, and infusion of hypertonic saline. Antiseizure prophylaxis also was initiated. Given the evidence of a left posterior cerebral artery ischemic infarct, a norepinephrine infusion was started to maintain cerebral perfusion pressure >70 mm Hg and mean arterial blood pressure between 90 and 100 mm Hg. A fentanyl infusion was titrated for sedation. Neurologic examinations were performed hourly.

On postoperative day 5, the patient's neurologic examination further deteriorated. Continuous electroencephalography revealed nonconvulsive status epilepticus. The patient received 4 mg of IV lorazepam with immediate improvement. IV phenytoin was added to levetiracetam at 1000 mg every 12 hours. A lumbar drain was placed after his head computed tomography demonstrated decreased cerebral edema.

During the course of the next 2 months, the patient remained comatose with intermittent resurgence of seizures requiring escalating doses and adjustments to his antiepileptic regimen. Because of his impaired neurologic status, he received a tracheostomy and a gastrostomy to provide means for respiratory and nutritional support. The patient was discharged to a skilled nursing facility 2 months after admission. On 2-year follow-up, he continues to reside in a long-term facility, awake but not interactive or communicative with his environment.

DISCUSSION

Although catastrophic tubing misconnections in neuraxial anesthesia are reported widely in the literature, we present the first documented intrathecal gadolinium injection in a postoperative craniotomy patient resulting in long-term, irreversible disability.^{2,3} An error of this nature is reported elsewhere in patients with healthy brains, one in a near-miss injection of anesthetic drugs into the ventricular shunt of a pediatric patient and the other in the injection of induction drugs into the ventriculostomy drain of an ICU patient during rapid sequence induction.^{4,5}

Gadolinium diethylenetriamine pentaacetic acid encephalopathy is a known but rarely documented entity. Studies in animals suggest that gadolinium neurotoxicity in the neocortex is mediated by direct mitochondrial dysfunction leading to increased oxidative stress and apoptosis.⁶ Any additional information on the neurotoxicity of gadolinium in humans has been gathered through reports of accidental intrathecal administration or intravascular diffusion of gadolinium into the CSF.⁷⁻¹⁰ In these reports, patients developed acute neurologic symptoms, such as confusion, ataxia, seizures, and coma.

Although intrathecal gadolinium diethylenetriamine pentaacetic acid is not approved by the Food and Drug Administration, several studies have documented its safe use for magnetic resonance cisternography and myelography.^{11,12} In our case, the administered dose was undiluted, 50 to 100 times the maximum recommended dose (0.5 to 1.0 mL), and given under pressure as an IV push. A case report of overdosage of intrathecal gadolinium in 2008 documents gadolinium-induced vasoconstriction, which may explain the posterior cerebral artery stroke in our patient.¹³ Remarkably, despite radiographic evidence of cerebral edema, ICP readings in our patient were within normal range. We attribute this to early CSF drainage as soon as the complication was identified.

The effort to understand, deconstruct, and redesign the processes that lead to medical errors has been at the heart of anesthesiologists' commitment to patient safety.

Indeed, human factors such as operator fallibility, fatigue, and lack of experience, as well as systems errors such as lack of communication and fragmentation of care in the handoff process, are all culprits in medical mistakes. However, anesthesiologists know from direct experience that decoupling the hardware that permits misconnections (i.e., the pin key-index safety system on anesthesia vaporizers and the interlocks on gas cylinders) completely eliminates reliance on operator attention and memory and does not burden the hospital staff with additional safety checks. The ubiquitous Luer connector lies at the heart of this error.

Luer taper connectors are in the form of male and female Luer-slip or Luer-lock adapters, allowing for a secure but detachable connection among syringes, needles, and tubing (Fig. 1). This connector is internationally standardized and almost universally used. Hundreds of Luer misconnections between medically incompatible devices have been reported since 1972, resulting in preventable patient harm and even death. In 2006, the Joint Commission published a sentinel event alert citing misconnections as causative in 8 preventable and fatal accidents such as pressurized air lines or epidural infusions mistakenly connected to IV

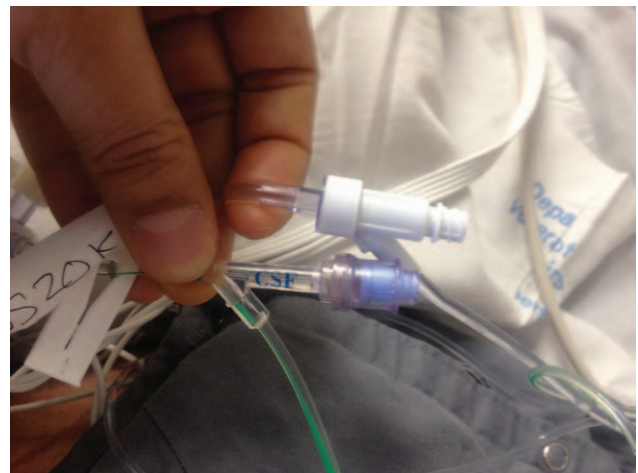


Figure 1. A side-by-side comparison of the Luer connector and ventriculostomy drain. Note that although broader strategies to prevent tubing misconnections are being developed, simple measures such as bright warning labels can prove very effective.

lines.¹⁴ A review done by US Pharmacopeia reports other life-threatening Luer connector errors such as enteral nutrition connected to central venous catheters, IV infusions connected to epidural lines, and injection of gastrointestinal contrast into central venous catheters.^a

Addressing the issue of medical tubing misconnections has become a global imperative. The World Health Organization's World Alliance for Patient Safety campaign placed this issue among the top Patient Safety Solutions in 2007. In 2009, the California State Senate and Assembly passed legislation prohibiting the use of connection-compatible IV, epidural, or enteral feeding devices that was supposed to take effect in 2013 but has been delayed because manufacturers have been unable to deliver new products.^b The Global Enteral Device Supplier Association was created to help introduce international standards for health care tubing connectors to manufacturers, distributors, and suppliers worldwide. In March 2013, the Centers for Medicare and Medicaid Services released a memo to all quality surveyors alerting them to investigate and report Luer misconnections. Also, Baxter and the Institute for Safe Medicine Practices teamed up to create a guidebook for health care facilities to tackle the tubing misconnection problem.

It is apparent that despite legislative and educational campaigns, wrong-route injections into intrathecal and epidural catheters continue. Although these campaigns represent necessary efforts on the political and legal front, the chasm between bureaucratic inertia and bedside practice has proven too wide to cross. There is a known factor of human fallibility in any endeavor, which is embodied in Seneca's "To err is human." However, persistent error in an era of unprecedented resources, technological advancement, and ease of collaboration undermines our commitment to patient safety.

It has now been 3 years since an editorial published in *Anesthesia & Analgesia* urged the anesthesia community to act.¹ Yet, substantial action has not occurred. As reports of epidural and spinal catheter misconnections continue, so does our responsibility if we are to remain at the forefront of patient safety. Implementing an alternative non-Luer

system requires a widespread sense of urgency among the anesthesiology community, regulatory bodies, and relevant industry partners. It is our hope that this report will reiterate the call to action by Birnbach and Vincent: a collaborative effort to attack the chain of events leading to tubing misconnections most efficiently and at its most vulnerable link. ■■

REFERENCES

1. Birnbach DJ, Vincent CA. A matter of conscience: a call to action for system improvements involving epidural and spinal catheters. *Anesth Analg* 2012;114:494–6
2. Kasaba T, Uehara K, Katsuki H, Ono Y, Takasaki M. Analysis of inadvertent epidural injection of drugs [in Japanese]. *Masui* 2000;49:1391–4
3. Mohseni K, Jafari A, Nobahar MR, Arami A. Polymyoclonus seizure resulting from accidental injection of tranexamic acid in spinal anesthesia. *Anesth Analg* 2009;108:1984–6
4. Drake JM, Crawford MW. Near-miss injection of an anesthetic agent into a cerebrospinal fluid external ventricular drain: special report. *Neurosurgery* 2005;56:E1161
5. Howell S, Driver RP Jr. Unintentional intracerebroventricular administration of etomidate and rocuronium. *Anesth Analg* 2008;106:520–2
6. Feng X, Xia Q, Yuan L, Yang X, Wang K. Impaired mitochondrial function and oxidative stress in rat cortical neurons: implications for gadolinium-induced neurotoxicity. *Neurotoxicology* 2010;31:391–8
7. Maramattom BV, Manno EM, Wijdicks EF, Lindell EP. Gadolinium encephalopathy in a patient with renal failure. *Neurology* 2005;64:1276–8
8. Arlt S, Cepek L, Rustenbeck HH, Prange H, Reimers CD. Gadolinium encephalopathy due to accidental intrathecal administration of gadopentetate dimeglumine. *J Neurol* 2007;254:810–2
9. Kapoor R, Liu J, Devasenapathy A, Gordin V. Gadolinium encephalopathy after intrathecal gadolinium injection. *Pain Physician* 2010;13:E321–6
10. Park KW, Im SB, Kim BT, Hwang SC, Park JS, Shin WH. Neurotoxic manifestations of an overdose intrathecal injection of gadopentetate dimeglumine. *J Korean Med Sci* 2010;25:505–8
11. Tali ET, Ercan N, Krumina G, Rudwan M, Mironov A, Zeng QY, Jinkins JR. Intrathecal gadolinium (gadopentetate dimeglumine) enhanced magnetic resonance myelography and cisternography: results of a multicenter study. *Invest Radiol* 2002;37:152–9
12. Algin O, Turkbey B. Intrathecal gadolinium-enhanced MR cisternography: a comprehensive review. *AJNR Am J Neuroradiol* 2013;34:14–22
13. Li L, Gao FQ, Zhang B, Luo BN, Yang ZY, Zhao J. Overdosage of intrathecal gadolinium and neurological response. *Clin Radiol* 2008;63:1063–8
14. Joint Commission on Accreditation of Healthcare Organizations, USA. Tubing misconnections—a persistent and potentially deadly occurrence. *Sentinel Event Alert* 2006;36:1–3

^aTubing Misconnections Self-Assessment for Health Care Facilities. Available at: <http://www.ismp.org/selfassessments/tubingMisconnections>. Accessed December 27, 2013.

^bCalifornia Assembly Bill (AB) 818 (Hernandez, Chapter 476, Statutes of 2009). Available at: <http://www.cdph.ca.gov/certlic/facilities/Documents/LNC-AFL-09-41.pdf>. Accessed December 27, 2013.