



# Successful Preoperative Endovascular Embolization of an Extreme Hypervascular Glioblastoma Mimicking an Arteriovenous Malformation

Tasuku Imai, Tomotaka Ohshima, Toshihisa Nishizawa, Shinji Shimato, Kyoze Kato

## Key words

- Arteriovenous malformation
- Embolization
- Glioblastoma
- *N*-butyl cyanoacrylate

## Abbreviations and Acronyms

**AVM:** Arteriovenous malformation

**MCA:** Middle cerebral artery

**NBCA:** *N*-butyl cyanoacrylate

Department of Neurosurgery, Kariya Toyota General Hospital, Kariya, Japan

To whom correspondence should be addressed:

Tomotaka Ohshima, M.D., Ph.D.

[E-mail: [tomotaka.ohshima@toyota-kai.or.jp](mailto:tomotaka.ohshima@toyota-kai.or.jp)]

Citation: *World Neurosurg.* (2016) 86:512.e1–512.e4.

<http://dx.doi.org/10.1016/j.wneu.2015.10.006>

Journal homepage: [www.WORLDNEUROSURGERY.org](http://www.WORLDNEUROSURGERY.org)

Available online: [www.sciencedirect.com](http://www.sciencedirect.com)

1878-8750/\$ - see front matter © 2016 Elsevier Inc.

All rights reserved.

## INTRODUCTION

Glioblastoma is the most common intracranial neoplasm of all primary central nervous system tumors.<sup>1,2</sup> Despite advances in microsurgical techniques, removal of hypervascular glioblastomas remains difficult for neurosurgeons. Preoperative endovascular embolization of extraaxial tumors, such as meningiomas, was previously established as an effective adjunct in decreasing intraoperative blood loss, softening the tumor, and facilitating surgery.<sup>3,4</sup> However, preoperative endovascular embolization of hypervascular glioblastomas has not been established. We report the case of an extreme hypervascular glioblastoma mimicking an arteriovenous malformation (AVM) that was successfully treated with preoperative embolization and subsequent removal. To the best of our knowledge, this is the first reported case of a glioblastoma treated with refined preoperative endovascular embolization.

## CASE REPORT

A 66-year-old man presented 4 weeks after the onset of right hemiparesis, apraxia, and

**BACKGROUND:** Preoperative endovascular embolization as a treatment for hypervascular glioblastomas has not been established. We report the case of an extreme hypervascular glioblastoma mimicking an arteriovenous malformation that was successfully treated with preoperative embolization and subsequent removal.

**CASE DESCRIPTION:** A 66-year-old man presented with progressive right hemiparesis and sensory aphasia. Cranial computed tomography and magnetic resonance imaging revealed a left parietooccipital tumor with ring enhancement. Digital subtraction angiography revealed an extreme high-flow arteriovenous shunt. The patient underwent presurgical endovascular embolization using *N*-butyl cyanoacrylate in a manner similar to embolization for arteriovenous malformations. Subsequent tumor removal was achieved with minimal blood loss.

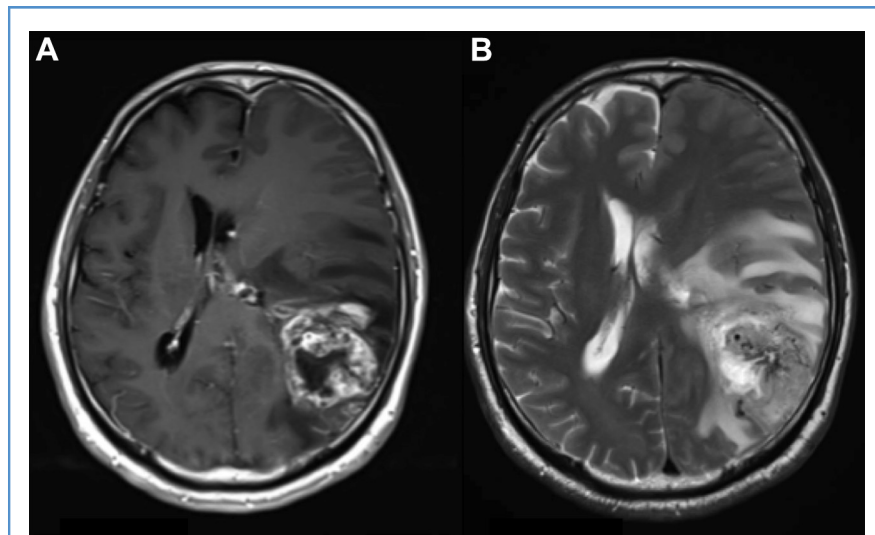
**CONCLUSIONS:** This is the first reported case of presurgical embolization of a glioblastoma with a high-flow shunt. Embolization of a malignant tumor with a high-flow shunt, in a manner similar to embolization of arteriovenous malformations, is feasible and effective.

sensory aphasia. Initial cranial magnetic resonance imaging showed a ring-enhanced 5.6-cm left parietooccipital mass with vasogenic edema and flow voids (Figure 1). Diagnostic cerebral catheter angiography showed a high-flow arteriovenous shunt, similar to an AVM (Figure 2), which was supplied by dilated branches of the left middle cerebral artery (MCA) (Figure 3A). We discussed whether a subemergency radical tumor removal or radiation therapy before surgery was required. Because the patient's status was deteriorating, we decided on early removal. In an attempt to reduce intraoperative blood loss, percutaneous transarterial embolization was scheduled just before the open surgery.

### Endovascular Procedure

The endovascular strategy followed the normal procedure for embolization of AVMs. Under general anesthesia, an 8F OPTIMO balloon guiding catheter (Tokai Medical Products, Inc., Aichi, Japan) was placed in the left internal carotid artery. A Headway 17 microcatheter (Terumo,

Tokyo, Japan) was navigated with an ASAHI CHIKAI 14 micro-guide wire (Asahi Intecc, Aichi, Japan) into the superior feeder of the left MCA insular division. Using pure *N*-butyl cyanoacrylate (NBCA; Histoacryl; B. Braun Melsungen AG, Melsungen, Germany) and ethiodized oil (Lipiodol Ultra-Fluide; Guerbet, Roissy, France), 20% NBCA was prepared in a 1:4 ratio. Using digital subtraction angiography for guidance, 20% NBCA was injected. The microcatheter was withdrawn once the reflux had covered its tip. Next, another Headway 17 microcatheter was navigated through the inferior feeder. Because this feeder was actually high-flow, a bare platinum coil (VFC 3–6 × 6; Terumo, Tokyo, Japan) was inserted into the dilatation and tortuous feeder of the left MCA inferior trunk to reduce flow before injection of the NBCA. Next, 20% NBCA was administered. Finally, the other feeder branch from proximal to inferior feeder was also occluded with 20% NBCA. Cerebral angiography performed after the procedure revealed the total resolution of the shunting vessels (Figure 3B).

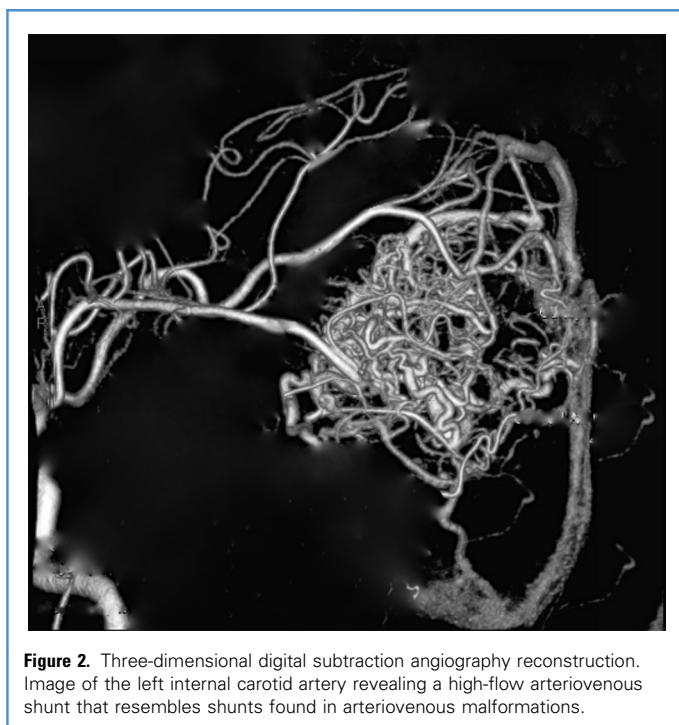

**Figure 1.** (A) Contrast magnetic resonance imaging. T1-weighted image revealing a ringlike and heterogeneous enhanced 56 mm × 53 mm mass lesion in the left parietooccipital lobe, with a midline shift from left to right. (B) Magnetic resonance imaging fluid attenuation inversion recovery. Image revealing perilesional vasogenic edema and dilated flow void.

### Surgical Procedure and Course

After embolization, the patient was immediately transferred to the operating room, and tumor resection was performed via a left parietooccipital craniotomy. The tumor was

soft and dark reddish in color. Although several tiny feeders were confirmed, there was no active bleeding during resection. Thrombosed deep drainers were also confirmed. Because the intraoperative rapid



**Figure 2.** Three-dimensional digital subtraction angiography reconstruction. Image of the left internal carotid artery revealing a high-flow arteriovenous shunt that resembles shunts found in arteriovenous malformations.

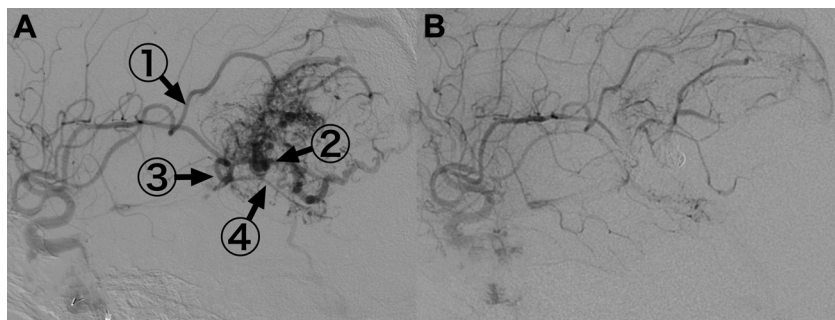
histologic examination indicated a high-grade glioma, carmustine wafer implantations were applied along the resected cavity. Total blood loss during the surgery was only 60 mL. After the surgery, the patient exhibited no further neurologic deterioration. The patient was discharged with very mild right hemiparesis and sensory aphasia 63 days later after chemotherapy (temozolomide 75 mg/m<sup>2</sup>/day) and radiotherapy (extended focal irradiation, total 60 Gy = 2 Gy × 30 days). After 4 months, cranial magnetic resonance imaging revealed no recurrence.

### Pathologic Examination

Pathologic examination revealed that the tumor was composed of neoplastic astrocytic cells with an increased number of blood capillaries, forming a pseudopalisading necrosis (Figure 4A). Immunohistochemical staining revealed that the tumor was positive for glial fibrillary acidic protein; weakly positive for p53; and negative for neurofilament protein, synaptophysin, and CD34. The MIB-1 index was ~40%. The findings were compatible with the diagnosis of glioblastoma multiforme, World Health Organization grade IV. Within the tumor, there were vascular abnormalities such as wall thickness and lumen dilatation, and there was an observation of transit from artery to vein (Figure 4B and C), which suggested this tumor contained an arteriovenous shunt.

### DISCUSSION

Glioblastomas are the most common intracranial neoplasm, accounting for 9.1%–15.4% of all primary central nervous system tumors.<sup>1,2</sup> They have a varying vascular anatomy as a result of an extensive proliferation of intratumoral vessels. Vascular endothelial growth factor secreted from a brain tumor has been hypothesized to induce angiogenesis<sup>5,6</sup> and abnormal arteriovenous connections<sup>7</sup>; in particular, glioblastoma is associated with increased vascular endothelial growth factor expression resulting in highly angiogenic tumors causing abnormal vasculature.<sup>8</sup> In the present case, histologic examination revealed an arteriovenous direct shunt. There was no apparent formation of nidus, regardless of the angiographic findings similar to AVM; however, cases associated with AVM within a glioma



**Figure 3.** (A) Digital subtraction angiography of the left internal carotid artery before embolization demonstrating the high-flow arteriovenous shunt. (1) The distal branch of the light middle cerebral artery (MCA) superior trunk (20% *N*-butyl cyanoacrylate [NBCA] 0.4 mL). (2) The main dilatation and tortuous feeder of the left MCA inferior trunk (coiling). (3) Just proximal to the coiling lesion in the left MCA inferior trunk (20% NBCA 0.45 mL). (4) The other feeder from the left MCA inferior trunk (20% NBCA 0.5 mL). (B) Digital subtraction angiography of the left internal carotid image after embolization showing the absence of the high flow shunt.

have been reported.<sup>9-14</sup> Despite advances in microsurgical techniques, hypervascular brain tumors are a great challenge for neurosurgeons. Massive bleeding during tumor resection can be life-threatening. Preoperative embolization to facilitate surgery is generally accepted as helpful for extraaxial tumors, such as meningiomas.<sup>3</sup> This procedure has been established as an effective adjunct in decreasing intraoperative blood loss,<sup>3,4</sup> resulting in softening of the tumor. However, preoperative endovascular embolization of hypervascular glioblastomas has not been established. Preoperative embolization of intraaxial hypervascular brain tumors has

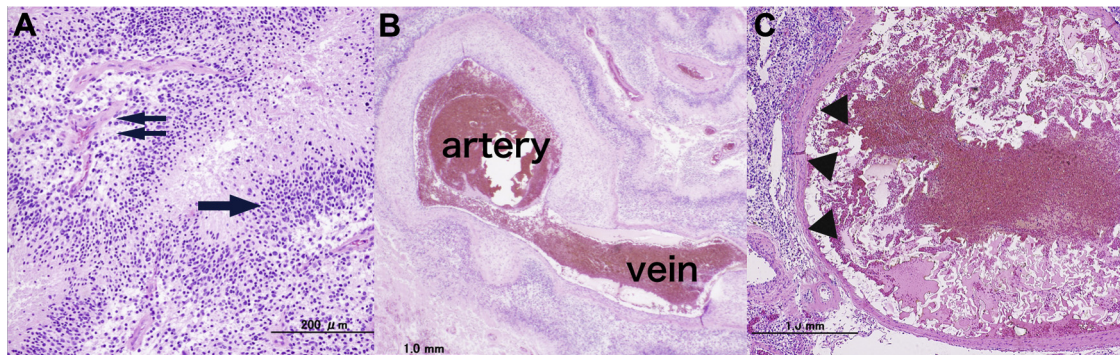
been much less evaluated because of its technical difficulties. Wang et al.<sup>14</sup> reported that the use of particles showed a higher rate of complications than liquid embolic materials such as NBCA for devascularization of the intraaxial tumor vessels. Moreover, they concluded that early surgical removal of tumor was recommended to reduce the risk of delayed tumor bleeding after embolization. Early successful surgical removal of tumor can also reduce the risk of repeated general anesthesia and reduce delayed peritumoral edema with herniation or obstructive hydrocephalus.

In the present case, preoperative embolization similar to that normally used for AVMs was used. The feeders were observed to be well divided from each other (using three-dimensional angiography) and not distributed into the cortex of the tumor. They could be successfully superselected using microcatheters distally. A relatively low concentration of NBCA (20%) was used to prevent catheter adhesion to the vessels. Embolization was performed of the high-flow fistulous feeder along with the dilatation and tortuous feeder using a detachable coil before the penetration of a low concentration of NBCA to prevent notable venous migration.

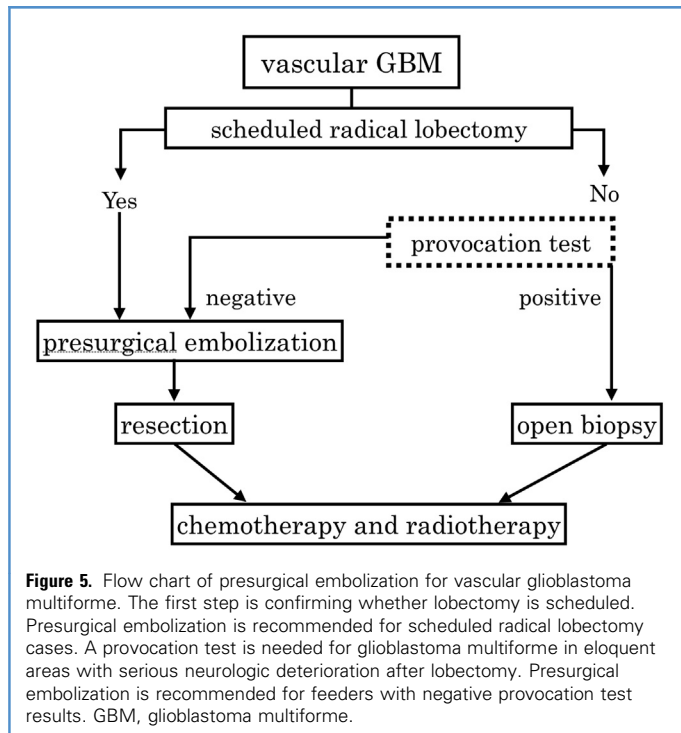
The surgical strategy used in this case was lobectomy; therefore, we performed a presurgical embolization. Presurgical embolization was considered an indication for patients who had been scheduled for radical lobectomy. In cases of glioblastoma multiforme with eloquent areas and high risk during radical lobectomy, provocation testing is needed before embolization. **Figure 5** shows a proposed flow chart that is based on this case report; however, accumulation of further data on successful vascular glioblastoma multiforme cases is required.

## CONCLUSIONS

To the best of our knowledge, this is the first reported case of a glioblastoma treated with refined preoperative endovascular embolization. Preoperative



**Figure 4.** (A) Photomicrograph of a tumor sample showing the highly cellular tumor tissue comprising neoplastic astrocytic cells and microvascular proliferation (*double arrow*) and pseudopalisading necrosis (*single arrow*) (H&E stain, magnification 100 $\times$ ). The finding is compatible with typical glioblastoma. (B) Photomicrograph of an arteriovenous shunt in the tumor (H&E stain, magnification 20 $\times$ ). The thick-walled and thin-walled vessels indicate arteries and veins that form the abnormal network of the arteriovenous shunt, respectively. (C) Photomicrograph of dilated neovessels of the tumor (H&E stain, magnification 20 $\times$ ). There are numerous enlarged vessels (>2 mm in diameter) with thin walls (*arrowheads*) containing embolization materials and thrombi. Hematoxylin-eosin staining was used for all photomicrographs.



embolization of extreme hypervascular malignant brain tumors, in a manner similar to embolization of AVMs, is feasible and effective.

## REFERENCES

- Committee of Brain Tumor Registry of Japan. Report of Brain Tumor Registry of Japan (1984-2000). *Neurol Med Chir (Tokyo)*. 2009;49:PS1-PS96.
- Ostrom QT, Gittleman H, Liao P, Rouse C, Chen Y, Dowling J, et al. CBTRUS statistical report: primary brain and central nervous system tumors diagnosed in the United States in 2007-2011. *Neuro Oncol*. 2014;16:iv1-iv63.
- Qureshi AI. Endovascular treatment of cerebrovascular diseases and intracranial neoplasms. *Lancet*. 2004;363:804-813.
- Ishihara H, Ishihara S, Niimi J, Neki H, Kakehi Y, Uemiya N, et al. The safety and efficacy of preoperative embolization of meningioma with N-butyl cyanoacrylate. *Interv Neuroradiol*. 2015;21:624-630.
- Samoto K, Ikezaki K, Ono M, Shono T, Kohno K, Kuwano M, et al. Expression of vascular endothelial growth factor and its possible relation with neovascularization in human brain tumors. *Cancer Res*. 1995;55:1189-1193.
- Schmidt NO, Westphal M, Hagel C, Ergün S, Stavrou D, Rosen EM, et al. Levels of vascular endothelial growth factor, hepatocyte growth factor/scatter factor and basic fibroblast growth factor in human gliomas and their relation to angiogenesis. *Int J Cancer*. 1999;84:10-18.
- Harris OA, Chang SD, Harris BT, Adler JR. Acquired cerebral arteriovenous malformation induced by an anaplastic astrocytoma: an interesting case. *Neurol Res*. 2000;22:473-477.
- Lu-Emerson C, Duda DG, Emblem KE, Taylor JW, Gerstner ER, Loeffler JS, et al. Lessons from anti-vascular endothelial growth factor and anti-vascular endothelial growth factor receptor trials in patients with glioblastoma. *J Clin Oncol*. 2015;33:1197-1213.
- Boikov AS, Schweitzer AD, Young RJ, Lavi E, Tsiouris AJ, Gupta A. Glioblastoma-arteriovenous fistula complex: imaging characteristics and treatment considerations. *Clin Imaging*. 2014;38:187-190.
- Soltanokotabi M, Schoeneman SE, Dipatri AJ, Hurley MC, Ansari SA, Rajaram V, et al. Juvenile pilocytic astrocytoma in association with arteriovenous malformation. *Interv Neuroradiol*. 2012;18:140-147.
- Cemil B, Tun K, Polat O, Ozen O, Kaptanoglu E. Glioblastoma multiforme mimicking arteriovenous malformation. *Turk Neurosurg*. 2009;19:433-436.
- Ziyal IM, Ece K, Bilginer B, Tezel GG, Ozcan OE. A glioma with an arteriovenous malformation: an association or a different entity? *Acta Neurochir (Wien)*. 2004;146:83-86.
- Mckinney JS, Steineke T, Nochlin D, Brisman JL. De novo formation of large arteriovenous shunting and a vascular nidus mimicking an arteriovenous malformation within an anaplastic oligodendroglioma: treatment with embolization and resection. *J Neurosurg*. 2008;109:1098-1102.
- Wang H-H, Luo C-B, Guo W-Y, Wu HM, Lirng J-F, Wong T-T, et al. Preoperative embolization of hypervascular pediatric brain tumors: evaluation of technical safety and outcome. *Childs Nerv Syst*. 2013;29:2043-2049.

*Conflict of interest statement:* The authors declare that the article content was composed in the absence of any commercial or financial relationships that could be construed as a potential conflict of interest.

Received 24 August 2015; accepted 5 October 2015

Citation: *World Neurosurg*. (2016) 86:512.e1-512.e4. <http://dx.doi.org/10.1016/j.wneu.2015.10.006>

Journal homepage: [www.WORLDNEUROSURGERY.org](http://www.WORLDNEUROSURGERY.org)

Available online: [www.sciencedirect.com](http://www.sciencedirect.com)

1878-8750/\$ - see front matter © 2016 Elsevier Inc. All rights reserved.