



Case Report

Bispectral index monitoring in subarachnoid hemorrhage–associated out-of hospital cardiac arrest^{☆,☆☆}

**Abstract**

Bispectral index (BIS) is a simple, noninvasive, and continuous electroencephalographic monitor that could reflect the level of consciousness. Initially, BIS was developed to measure the anesthetic depth during operation; now, BIS could be used as a predictor of neurologic outcome in postresuscitative care. We report a case that had out-of cardiac arrest due to subarachnoid hemorrhage, and we used BIS to monitor the patient's consciousness level. During observation, another episode of cardiac arrest occurred due to delayed cerebral ischemia–related cardiac depression. Low bispectral index and high suppression ratio represent decreasing brain activity suggestive hypoxic ischemic encephalopathy. This was confirmed by brain perfusion scan and standard electroencephalographic study. Using BIS, we can identify patients with poor neurologic outcome earlier, and treatment could be alleviated if prognosis is futile.

A 73-year-old woman who was previously healthy had cardiac arrest at home. After paramedics arrived, automated external defibrillator revealed that the initial rhythm was pulseless electrical activity (PEA). Cardiopulmonary resuscitation was started soon, and return of spontaneous circulation (ROSC) was achieved after 6 minutes. After arrival in the emergency department, the laboratory data did not show evidence of metabolic acidosis, hyperkalemia, or anemia. The 12-lead electrocardiography shows no evidence of acute coronary syndrome. The following brain computed tomography (CT) showed diffuse subarachnoid hemorrhage (SAH) which was suspected due to rupture of aneurysm (Fig. 1). She remained comatose, and she was admitted to the intensive care unit for further care.

Bispectral index (BIS) monitoring was placed over her left forehead to monitor the patient's consciousness. The initial BIS was around 70 to 90, and suppression ratio (SR) was 0. All values had good quality and were reliable for reading (signal quality index [SQI] >70%) (Fig. 2). Eight hours after admission in the intensive care unit, PEA developed along with sudden decrease of BIS and increase of SR (Fig. 2). Another resuscitation attempt was initiated; ROSC was achieved in 4 minutes. The following brain CT showed increasing hypodense change of brain and brainstem suggestive hypoxic ischemic encephalopathy.

The following electroencephalography (EEG) on day 9 confirmed no discernible cortical activity, and the brain perfusion scan performed also showed no definite tracer activity in the cerebral and cerebellar hemispheres (Fig. 3). After informing the family about the grave

prognosis for neurologic recovery, they decided “do not attempt resuscitation” policy and withdrawal of life-supporting treatment. The patient passed away on day 18.

Subarachnoid hemorrhage is one of the etiologies of out-of cardiac arrest and is the most common neurologic cause of cardiac arrest [1]. Most of the initial rhythms are nonshockable (asystole or PEA). High ROSC rate was observed; however, the survival to discharge rate and neurologic outcome are poor. The mechanism of SAH-related cardiac arrest is due to respiratory suppression by brainstem herniation and/or neurogenic myocardial stunning. In SAH-related cardiac arrest, continuous neurologic deficits such as delayed cerebral ischemia could occur. Delayed cerebral ischemia resulting from vasospasm is a major complication of SAH, which leads to brain hypoperfusion and increases morbidity and mortality. In poor-grade SAH, new infarction is often silent and easily missed. Early neuroprognostication is highly recommended.

Noninvasive monitoring such as transcranial Doppler ultrasound is used to measure the blood flow through the arteries, but ultrasound is an operator-dependent and noncontinuous tool. Continuous EEG monitoring is another useful noninvasive method for detecting delayed cerebral ischemia. Decreased α/δ ratio demonstrated strong association with delayed cerebral ischemia [2]. The

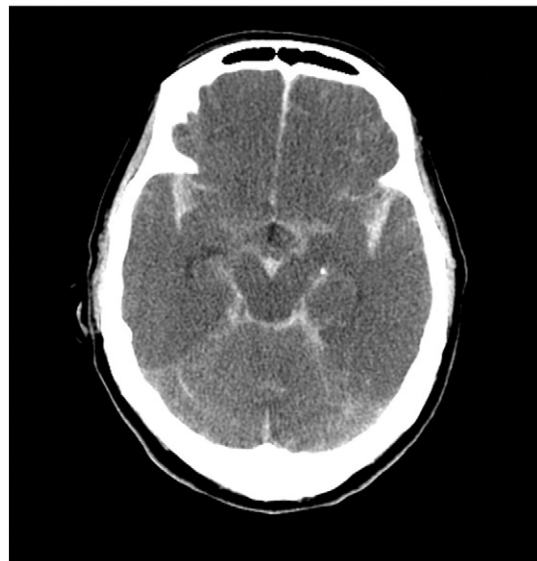

Fig. 1. Brain CT scan showed diffuse SAH.

[☆] Acknowledgments: None.

^{☆☆} Conflicts of interests: None.

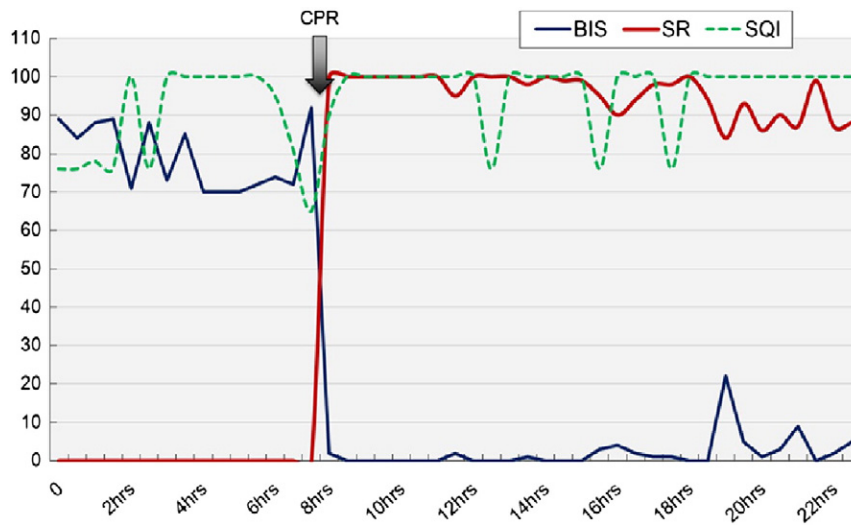


Fig. 2. Bispectral index and SR show inverse change after cardiac arrest due to SAH-related vasospasm. The SQI that is greater than 70 means good quality with reliable data. The patient eventually had poor neurologic outcome (cerebral performance categories, 5).

observed EEG changes seem to reflect early stages of ischemia that preceded CT. However, raw EEG is relatively difficult for inexperienced physicians to interpret.

The BIS is a quantitative EEG signal designed to monitor the depth of anesthesia ranging from 0 (flat, fully suppressed EEG) to 100 (awake patient) [3]. Values that range from 40 to 60 are adequate anesthesia level suitable for surgery. Suppression ratio means the proportion of burst suppression in EEG or isoelectric activity. Bispectral index monitoring had also been used in identification of neurologic outcome after cardiac arrest [4]. Combination of serum neurobiomarker

(S-100 β) and BIS has good predictive value (areas under the receiver operating characteristic curve, 0.95) for neurologic outcome [5]. During hypothermia treatment for postresuscitative care, high BIS level concomitant with higher sedative requirement is associated with good neurologic outcome [6]. Higher BIS level indicates more preserved neuronal activity; on the contrary, higher SR level hints more EEG suppression associated with worse neurologic outcome. Bispectral index is a simpler technology that nonneurologists can interpret the value easily. Furthermore, BIS could be used to adjust anesthesia dosages during therapeutic hypothermia treatment.

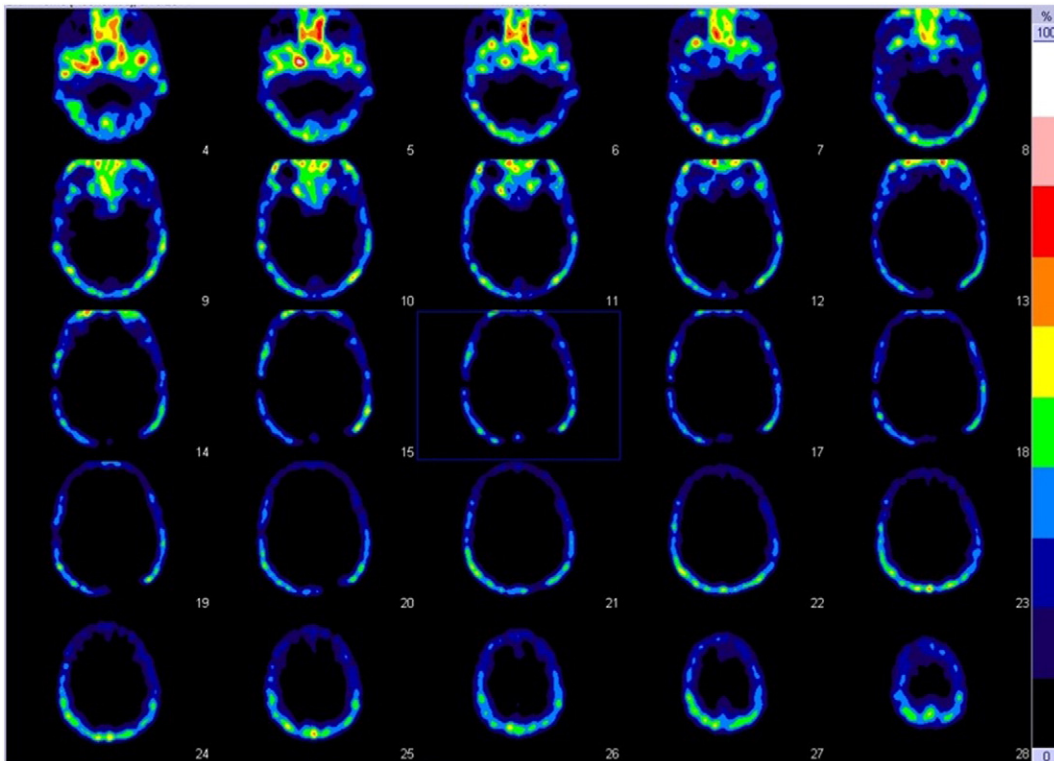


Fig. 3. Brain perfusion scan showed absent perfusion in both brain hemispheres, which is compatible with brain death.

In our care, continuous BIS monitoring documented sudden decline of brain electrical activity with inverse BIS and SR values (Fig. 2) after regaining pulse from second cardiac arrest event. Severe vasospasm with brain hypoxic ischemic change was documented by following brain CT scan and nuclear brain perfusion scan. Bispectral index could be a noninvasive tool that provides continuous real-time measurement of brain activity, which could be applied to postresuscitative care and neurosurgical patients. Persistent low BIS level hints grave neurologic prognosis. End-of-life care discussion and termination of life-supporting treatment could be initiated earlier.

An-Yi Wang, MD

*Department of Emergency Medicine
Taipei Medical University Hospital, Taipei City, Taiwan
Department of Emergency Medicine
National Taiwan University Hospital, Taipei City, Taiwan*

*Corresponding author. Department of Emergency Medicine, Taipei Medical University Hospital, No. 252, Wu Hsing Street, Taipei 100, Taiwan
E-mail address: anyimilk@gmail.com

Chien-Hua Huang, MD, PhD

Wei-Tien Chang, MD, PhD
*Department of Emergency Medicine
National Taiwan University Hospital, Taipei City, Taiwan*

Wen-Jone Chen, MD, PhD

*Department of Emergency Medicine
National Taiwan University Hospital, Taipei City, Taiwan
Department of Emergency Medicine
Lotung Poh-Ai Hospital, Yilan County, Taiwan*

<http://dx.doi.org/10.1016/j.ajem.2015.09.025>

References

- [1] Mitsuma W, Ito M, Kodama M, Takano H, Tomita M, Saito N, et al. Clinical and cardiac features of patients with subarachnoid haemorrhage presenting with out-of-hospital cardiac arrest. *Resuscitation* 2011;82:1294–7.
- [2] Claassen J, Hirsch LJ, Kreiter KT, Du EY, Connolly ES, Emerson RG, et al. Quantitative continuous EEG for detecting delayed cerebral ischemia in patients with poor-grade subarachnoid hemorrhage. *Clin Neurophysiol* 2004;115:2699–710.
- [3] Rosow C, Manberg PJ. Bispectral index monitoring. *Anesthesiol Clin North America* 2001;19:947–66.
- [4] Seder DB, Fraser GL, Robbins T, Libby L, Riker RR. The bispectral index and suppression ratio are very early predictors of neurological outcome during therapeutic hypothermia after cardiac arrest. *Intensive Care Med* 2010;36:281–8.
- [5] Stammel P, Wagner DR, Gilson G, Devaux Y. Modeling serum level of s100beta and bispectral index to predict outcome after cardiac arrest. *J Am Coll Cardiol* 2013;62:851–8.
- [6] Burjek NE, Wagner CE, Hollenbeck RD, Wang L, Yu C, McPherson JA, et al. Early bispectral index and sedation requirements during therapeutic hypothermia predict neurologic recovery following cardiac arrest. *Crit Care Med* 2014;42:1204–12.