

Lower Risk of Intracranial Arteriovenous Malformation Hemorrhage in Patients With Hereditary Hemorrhagic Telangiectasia

Wuyang Yang, MD*
 Ann Liu, BA‡
 Alice L. Hung, BA*
 Maria Braileanu, MD*
 Joanna Y. Wang, BA*
 Justin M. Caplan, MD*
 Geoffrey P. Colby, MD, PhD*
 Alexander L. Coon, MD*
 Rafael J. Tamargo, MD*
 Edward S. Ahn, MD*
 Judy Huang, MD*

*Department of Neurosurgery, Johns Hopkins University School of Medicine, Baltimore, Maryland; ‡Wake Forest University School of Medicine, Winston-Salem, North Carolina

Correspondence:

Judy Huang, MD,
 Johns Hopkins Hospital,
 Zayed Tower, Suite 6115F,
 1800 Orleans Street,
 Baltimore, MD 21287.
 E-mail: jhuang24@jhmi.edu

Received, May 20, 2015.

Accepted, September 14, 2015.

Published Online, November 3, 2015.

Copyright © 2015 by the
 Congress of Neurological Surgeons.

BACKGROUND: Patients diagnosed with hereditary hemorrhagic telangiectasia (HHT) are at risk of developing intracranial arteriovenous malformations (AVM). However, the clinical manifestations and natural history of HHT-related AVMs remain unclear due to the rarity of these lesions.

OBJECTIVE: To clarify the clinical characteristics and hemorrhagic risk in HHT-related AVMs.

METHODS: We performed a retrospective review of all patients diagnosed with both HHT and intracranial AVMs who were evaluated at our institution from 1990 to 2013. Patients with missing data or lost to follow-up were excluded. Baseline characteristics and subsequent hemorrhagic risk were evaluated.

RESULTS: In an AVM database of 531 patients with 542 AVMs, a total of 12 HHT patients (2.3%) with 23 AVMs were found. Mean age at diagnosis was 36.5 years, with 41.7% male. Compared to patients with sporadic AVMs, patients with HHT were less likely to present with ruptured AVM ($P = .04$), headaches ($P = .02$), and seizures ($P = .02$), and presented with better modified Rankin scores ($P < .01$). HHT-related AVMs were smaller in size ($P < .01$), of lower Spetzler-Martin grade ($P = .01$), and had less temporal lobe involvement ($P = .02$) compared to sporadic AVMs. Six HHT patients (50.0%) were found with multiple intracranial AVMs. One hemorrhage was found during an observation period of 149.6 patient-years and 297.5 lesion-years, translating to 1.3% per patient per year or 0.7% per AVM per year.

CONCLUSION: HHT-related AVMs are smaller in size with lower Spetzler-Martin grade and less temporal lobe involvement than sporadic AVMs. Patients with HHT frequently present with multiple intracranial AVMs. Conservative management is generally recommended due to lesion multiplicity and relatively low hemorrhagic risk.

KEY WORDS: Arteriovenous malformation, Hereditary hemorrhagic telangiectasia, Intracranial hemorrhage, Natural history

Neurosurgery 78:684–693, 2016

DOI: 10.1227/NEU.0000000000001103

www.neurosurgery-online.com

Hereditary hemorrhagic telangiectasia (HHT) is a rare autosomal dominant disease characterized by epistaxis on presentation, frequent occurrence of mucocutaneous telangiectases, and multisystem arteriovenous malformations (AVMs).^{1–6} The prevalence of HHT varies by geographical location and is estimated to be 2.6 to 42.5 out of 100 000 patients.^{1,7} The clinical presentation of HHT varies and is usually

dependent on the underlying vascular abnormalities.^{1,8,9} According to Guttmacher et al,¹ the presenting symptoms of HHT can be divided into 5 major categories: nose, skin, lung, brain, and gastrointestinal tract. The most common clinical manifestation was reported to be recurrent epistaxis (70%–90%), followed by mucocutaneous telangiectases (60%–89%), gastrointestinal tract bleeding (16%–40%), and pulmonary AVM-related symptoms (30%–59%). Although neurological symptoms are present in 11% of all HHT cases,^{2,10} two-thirds of these cases are manifested by underlying pulmonary vascular malformations such as pulmonary AVMs or

ABBREVIATIONS: AVM, arteriovenous malformations; HHT, hereditary hemorrhagic telangiectasia; ICH, intracranial hemorrhages

arteriovenous fistulas, which causes paradoxical emboli or cerebral ischemia as a result of direct pulmonary right-to-left shunting.^{1,3,11} Cerebral vascular malformations are directly related to the neurological symptoms for the remaining third of these patients.

Patients with a diagnosis of HHT are generally recommended to undergo brain imaging screening, as they are at significant risk of developing cerebral vascular malformations. Previous studies have reported the prevalence of intracranial vascular malformations to be 3.7% to 18.6%, with 48.7% to 91.7% of these malformations being AVMs.^{3,5,7} Few studies have described in detail the clinical manifestations of HHT-related AVMs due to its rarity. The majority of presenting symptoms are reported to be non-neurologic, and the most common presentation of intracranial AVMs is either incidental discovery or atypical headaches.^{3,5,7} Angiographic features of these AVMs are considered to be distinctly different from sporadic AVMs, as they demonstrate a tendency of having multiple nodi, smaller size, and more cortical locations with superficial drainage.^{3,5-8} Although the hemorrhagic risk of HHT-related AVMs is generally perceived to be relatively low, the actual rate is significantly underreported in current literature. To our knowledge, there are only 2 studies that reported annualized risk for HHT-related AVMs. The most recent study conducted by Kim et al¹² revealed the subsequent hemorrhagic rate of HHT-related AVMs after diagnosis to be 1.02% per patient per year, which is almost twice the risk compared to the previously reported annualized rate of 0.41% to 0.72% per patient per year by Willemse et al in 2000.³ The real hemorrhagic risk associated with HHT-related AVMs remains unclear and warrants further investigation to provide guidance for appropriate selection of management strategy. In this study, we report clinical and angiographic features of patients diagnosed with HHT and intracranial AVM in order to clarify the clinical manifestations and hemorrhagic risk associated with this disease.

METHODS

Data Collection and Definition of Variables

We performed a search of all patients diagnosed with HHT in an institutional database of intracranial AVMs from January 1990 to December 2013. Patient data in the database were both retrospectively chart reviewed and prospectively collected. All patients had a confirmed diagnosis of intracranial AVMs by digital subtraction angiography. The diagnosis of HHT in our institution was well documented, and we further confirmed the diagnosis using the criteria introduced by Shovlin et al in 2000.¹³ We excluded patients with missing critical baseline clinical or angiographic data, or if they were lost to follow-up. Demographic, clinical, and angiographic data were collected and retrieved from the institutional database for both sporadic AVM patients and patients with HHT-related AVMs. Age of patients was defined as age at diagnosis of the AVM. All demographic and clinical parameters were compared between patients with sporadic AVMs and patients with HHT-related AVMs. For angiographic data, lesion-related features were compared between the 2 groups on a per-lesion basis.

Calculation of Hemorrhagic Risk

Annualized hemorrhagic risk was calculated as the number of intracranial hemorrhages (ICH) divided by total patient-years or lesion-years during observation period of the AVM. The observation period for an untreated AVM was defined as the interval between the date of AVM diagnosis to the date of last follow-up. For patients who underwent treatment of an AVM, the observation period was defined as the interval between AVM diagnosis and the first treatment targeted at the intracranial AVM. The hemorrhagic risk was presented as both per-patient risk and per-lesion risk.

Statistical Analysis

Student's *t* test was used for continuous variables where the distribution was Gaussian, whereas Wilcoxon rank-sum test was used if the distribution was non-Gaussian. Uncorrected χ^2 test or Fisher's exact test was used where appropriate depending on individual cell sample size. Hemorrhagic risk was tested using Poisson rate ratio test. All *P* values were reported as 2 sided, defined as significant if *P* < .05, and all statistical analyses were performed using R Statistical Software (Version 3.1.1, 2013; Vienna, Austria).

RESULTS

Study Cohort

A total of 531 patients diagnosed with intracranial AVM with complete baseline and follow-up information were retrieved from an AVM database of 696 patients. Of the 531 AVM patients, 12 patients (2.3%) were clinically diagnosed with HHT and were found to have a total of 23 AVMs. All other patients (*n* = 519) without diagnosis of HHT harbored a single intracranial AVM. Therefore, our finalized study cohort consisted of 531 patients with a total of 542 AVMs.

Baseline Characteristics

The average age of all patients was 36.5 years, with an average age of 23.3 ± 16.9 years in the HHT group and 36.8 ± 17.5 years in the non-HHT group (*P* = .02). No significant difference was found in sex (*P* = .82) and race (*P* = .13) between the 2 groups. Patients with sporadic AVMs were more likely to present with hemorrhage as compared to patients with HHT-related AVMs (*P* = .04). Mean modified Rankin scale (mRS) was significantly lower (*P* < .01) in the HHT group as a result of milder presenting symptoms. Patients with HHT-related AVMs were also less likely to present with seizure and headaches as compared to patients with sporadic AVMs. A detailed description of the comparison is depicted in Table 1.

Clinical presentation and lesion characteristics of all 12 patients with HHT-related AVMs are illustrated in Table 2. All patients in the HHT group presented with at least one non-neurological symptom, and 41.7% (*n* = 5) had neurological symptoms. The only patient with a ruptured presentation was a 6-month old pediatric patient (Patient 10) diagnosed with HHT and an extremely diffuse multi-compartment intracranial AVM with the maximum diameter measuring 8 cm. Multiple AVMs were found in 6 patients (50.0%), with 2 patients each having 4 intracranial AVMs, 1 patient having 3 AVMs, and 3 patients each having 2

TABLE 1. Baseline Characteristics of All Patients With AVMs^a

Characteristics	All Patients (N = 531)	Patients Without HHT (N = 519)	Patients With HHT (N = 12)	P Value
Age, mean (SD), y	36.5 (17.6)	36.8 (17.5)	23.3 (16.9)	.02 ^b
Male, n (%)	238 (44.8)	233 (44.9)	5 (41.7)	.82
Race, n (%)				.13
White	342 (64.4)	331 (63.8)	11 (91.2)	
Black	117 (22.0)	117 (22.5)	1 (8.3)	
Other	71 (13.4)	71 (13.7)	0 (0.0)	
Hemorrhage at presentation, n (%)	192 (36.2)	191 (36.8)	1 (8.3)	.04 ^b
Baseline mRS, mean (SD)	1.6 (1.1)	1.7 (1.1)	0.5 (1.0)	<.01 ^b
Presenting symptoms, n (%)				
Seizure	157 (29.6)	157 (30.3)	0 (0.0)	.02 ^b
Headache	309 (58.2)	306 (59.0)	3 (25.0)	.02 ^b
Speech disturbance	85 (16.0)	83 (16.0)	2 (16.7)	.94
Weakness	97 (18.3)	96 (18.5)	1 (8.3)	.37
Imbalance	51 (9.6)	51 (9.8)	0 (0.0)	.25

^aAVM, arteriovenous malformations; HHT, hereditary hemorrhagic telangiectasia; mRS, modified Rankin scale; SD, standard deviation.

^bStatistically significant ($P < .05$).

AVMs. A total of 23 AVMs were found in 12 patients with HHT, which is approximately 2 lesions per person. Ten patients (83.3%) were found to have extracranial AVMs, with all of them having pulmonary AVMs and one of them having multi-organ involvement. About half ($n = 7$, 58.3%) of all patients with HHT were asymptomatic or presented with non-neurological symptoms.

Angiographic Characteristics

Angiographic characteristics of all AVMs ($n = 542$) are described in detail in Table 3. The average AVM size in patients with HHT was 1.6 cm, which was significantly smaller than sporadic AVMs (3.1 cm) in our study cohort ($P < .01$). Furthermore, we also observed a trend towards significance for less deep venous drainage in HHT-related AVMs ($P = .06$). As a result, HHT-related AVMs had lower Spetzler-Martin grades compared to sporadic AVMs. There was no difference in location distribution of AVMs between the 2 groups except for less temporal lobe involvement ($P = .02$) in HHT-related AVMs.

Treatment and Follow-up

In the HHT group, only 2 patients (16.7%) were treated with surgical resection of the AVM with no residual or neurological deficits. Both patients presented with a single unruptured Spetzler-Martin grade 1 AVM, with one in the left frontal lobe and the other in the right temporal lobe. The only patient with a ruptured presentation in this cohort was conservatively managed considering his young age, the extensive size, and deep location of his AVM. No subsequent hemorrhages occurred at the last follow-up 9 years from his presentation. Detailed description of this patient is illustrated in Case Presentation 2. The majority of patients ($n = 433$, 83.4%) in the non-HHT group were treated, with treatment modalities as follows: surgery \pm embolization ($n = 123$, 23.7%), radiosurgery \pm embolization ($n = 270$, 52.0%),

surgery + radiosurgery \pm embolization ($n = 270$, 2.5%), embolization alone ($n = 270$, 5.0%), and conservative management ($n = 87$, 16.8%). Of note, 82.7% ($n = 158$) of ruptured patients and 85.5% of unruptured patients with seizures ($n = 106$) in the non-HHT group were treated. Patients with HHT-related AVMs were regularly followed for management of systemic diseases and were generally recommended to undergo annual brain MRAs. During the entire period of follow-up, no AVM progression or de novo AVM formation was observed.

Hemorrhagic Risk

The total observation period for calculating per-patient hemorrhagic risk is 1393.4 patient-years for the non-HHT group, and 149.6 patient-years for the HHT group (Table 4). One patient in the HHT group (8.3%) and 32 patients in the non-HHT group (6.2%) experienced at least one hemorrhage event during the observation period. Of note, 2 hemorrhages occurred in 1 patient in the HHT group, and 42 hemorrhages occurred in 32 patients in the non-HHT group. Although the annualized hemorrhagic risk was lower for the HHT group as compared to the non-HHT group (1.3% vs 3.0%, respectively), the difference was not found to be significant ($P = .37$). Interval to first subsequent hemorrhage after diagnosis was shorter in the non-HHT group with an average of 2.4 years compared to 10.8 years in the HHT group ($P < .01$). The observation period for HHT-related AVM on a per-lesion basis was 297.5 lesion-years, translating to an annualized hemorrhagic risk of 0.7% per AVM per year (Table 5). The difference in hemorrhagic risk was significantly different between HHT and non-HHT group on a per-lesion basis (0.7% vs 3.0%, respectively, $P = .02$).

Case Presentation 1

A nineteen-year-old female (Patient 5) presented with recurrent epistaxis, headaches, speech difficulty, light sensitivity, numbness

TABLE 2. Characteristics of All 12 Patients With AVM Combined With HHT^a

Patient Number	Clinical Presentation				Lesion Characteristics						
	Age/Sex	Race	Symptoms	Ruptured	AVM Size (cm)	Deep Drainage	Side	Location	Grade	Number of AVMs	AVMs in Other Locations
1	45/M	W	—	—	1.5/1.5/1.5	—/—/—	L/L/R	C/I/F	1/1/1	3	—
2	1/F	W	—	—	1.2	—	L	F	1	1	+
3	22/M	W	H/V	—	0.4	—	L	F	1	1	+
4	6/F	W	SE/WK/A	—	0.6/0.4	—/—	L	P/O	2/2	2	+
5	19/F	W	H/A/SE/WK/V	—	1.5/0.8/0.6/0.4	+ / + / + / +	L/R/L/R	BS/TB/CP/CH	3/3/3/2	4	+
6	19/F	B	H	—	6.0/2.2	—/—	R/R	SF/F	4/1	2	+
7	19/M	W	—	—	2	—	R	T	1	1	+
8	27/M	W	—	—	1.1/1.1/0.4/0.3	—/—/—/—	L/L/L/R	SF/SF/SF/O	2/2/2/2	4	+
9	52/F	W	—	—	1.0/1.0	—/—	R/R	SF/F	2/1	2	+
10	6 mo/M	W	H/L	+	8.0 ^b	+	LR	TB/BS/C	5	1	—
11	27/F	W	—	—	1.5	+	L	CH	2	1	+
12	43/F	W	—	—	2.5	—	R	P	2	1	+

^aA, aphasia or speech disturbance; AVM, arteriovenous malformations; B, Black; BS, brainstem; C, cerebellum; CC, corpus callosum; CH, choroidal; CP, cerebral peduncle; F, frontal; FAA, feeding artery aneurysm; H, headache; HHT, hereditary hemorrhagic telangiectasia; L, lethargy; O, occipital; P, parietal; SE, sensory disturbances; SF, Sylvian fissure; T, temporal; TB, Thalamus/Basal Ganglia; U, unrelated aneurysm; V, visual disturbance; WK, weakness; W, white.

^bThe AVM in this patient was determined to have multiple compartments instead of multiple AVMs because the nidus were joined together and the border could not be well delineated.

and weakness of extremities and was clinically diagnosed with HHT syndrome (recurrent spontaneous epistaxis, father with HHT, multiple cerebral AVMs). She was found to have 4 cerebral AVMs located on the left medial midbrain, bilateral thalamic, and right lateral ventricular choroidal region, measuring 1.5, 0.8, 0.6, and 0.4 cm, respectively. The lesions were well appreciated on both digital subtraction angiography and DynaCT (Siemens Medical Solutions USA, Inc., Malvern, Pennsylvania) (Figure 1). There were also sporadic mild telangiectasias on her face and tongue. Observation was recommended for her cerebral AVMs, as they were considered to have low bleeding risk. Eight years later at the age of 28, she was evaluated again for her brain AVMs, as she was planning to become pregnant. Her intracranial AVMs were found to be unchanged, but an incidental pulmonary AVM was found in her right lower lobe. The intracranial AVMs were not considered a contraindication for her pregnancy, but treatment of her pulmonary AVM was advised. The patient underwent successful embolization of her pulmonary AVM and subsequently had an uncomplicated pregnancy. The patient was neurologically intact on last follow-up.

Case Presentation 2

A 6-month-old male infant (Patient 10) with uncomplicated pregnancy and normal development experienced several days of lethargy and emesis. On presentation, the patient was found to be irritable with intermittent seizures and multiple telangiectases on the skin. Past medical history was notable for frequent episodes of spontaneous epistaxis. Head computed tomography demonstrated right caudate hemorrhage with intraventricular hemorrhage. Digital subtraction angiography showed a diffuse AVM located primarily in the bilateral basal ganglia and right cerebellum with at least 4 compartments (Figure 2), with a maximum diameter measuring 8 cm. The clinical diagnosis of HHT was confirmed based on his presentation (recurrent spontaneous epistaxis, multiple skin telangiectasias, intracranial AVMs). The patient was considered for radiosurgery for the right caudate compartment of the AVM, but ultimately deemed a poor candidate due to indistinct borders; therefore, no treatment was given. The patient recovered with a mild right hemiparesis, and he was maintained on seizure prophylaxis. At the age of 4 years, he was found to have developmental delay and strained cardiac function due to high output. By the time of last follow-up at 10 years-old, the patient had experienced intermittent episodes of complex partial seizures and epistaxis, but otherwise no additional intracranial hemorrhages.

DISCUSSION

Clinical Manifestations and Angiographic Characteristics

To our knowledge, this is the first study to compare the clinical and angiographic characteristics between sporadic AVMs and HHT-related AVMs. We found that patients with HHT-related AVMs generally presented at a younger age due to frequent onset

TABLE 3. Characteristics of All AVMs^a

Parameters	All AVMs (N = 542)	AVMs in Patients Without HHT (N = 519)	AVMs in Patients With HHT (N = 23)	P Value
Size, mean (SD), cm	3.0 (1.8)	3.1 (1.8)	1.6 (1.8)	<.01 ^b
Eloquence, n (%)	345 (64.0)	332 (64.0)	13 (56.5)	.47
Deep venous drainage, n (%)	245 (45.2)	239 (46.1)	6 (26.1)	.06
SM grade, n (%)				.01 ^b
1	73 (13.5)	65 (12.5)	8 (34.8)	
2	193 (35.6)	183 (35.3)	10 (43.4)	
3	164 (30.3)	161 (31.0)	3 (13.0)	
4	82 (15.1)	81 (15.6)	1 (4.3)	
5	30 (5.5)	29 (5.6)	1 (4.3)	
Location, n (%)				
Frontal	190 (35.1)	181 (34.9)	9 (39.1)	.66
Temporal	139 (25.6)	138 (26.6)	1 (4.3)	.02 ^b
Parietal	175 (32.3)	168 (32.3)	7 (30.4)	.85
Occipital	84 (15.5)	82 (15.8)	2 (8.7)	.36
Brainstem	30 (5.5)	28 (5.4)	2 (8.7)	.50
Cerebellum	56 (10.3)	55 (10.6)	1 (4.3)	.34
Basal ganglia/thalamus	43 (7.9)	42 (7.9)	2 (8.7)	.89

^aAVM, arteriovenous malformations; HHT, hereditary hemorrhagic telangiectasia; SD, standard deviation; SM, Spetzler-Martin.

^bStatistically significant ($P < .05$).

of non-neurological symptoms such as recurrent epistaxis or skin telangiectasias, which prompted further screening of HHT-related lesions, and eventually leading to the earlier detection of intracranial AVMs. More than half of our patients with HHT-related AVMs ($n = 7$, 58.3%) had an asymptomatic or non-neurological presentation, which was consistent with previous studies where asymptomatic presentation was reported to be 45.8% to 61%.^{3,12} In regards to neurologic manifestations, we observed a lower risk of rupture in patients with HHT; for patients with unruptured AVMs, most presented with headaches instead of seizures. These findings were concordant with current literature.^{3,12}

Angiographic features of HHT-related AVMs were considered to be distinctly different from sporadic AVMs. Existing studies found that HHT-related AVMs were smaller in size and more frequently located in non-eloquent areas with superficial drainage.^{3,7} Patients with HHT were also noted to have an increased

risk of developing multiple intracranial AVMs. Our current study confirmed the smaller size (1.6 cm, $P < .01$) and multiplicity of AVMs (50.0%). We observed a tendency towards less frequent deep venous drainage ($P = .06$), but failed to observe a difference for eloquent location ($P = .47$). Of note, the proportion of HHT-related AVMs with deep venous drainage (26.1%) and eloquence (56.5%) in our study was comparable to the reported proportion in current literature.^{3,5,7} The non-significance was most likely a result of the small sample size in the HHT group. Therefore, whether HHT-related AVMs are truly more likely to be non-eloquent with superficial drainage remains unclear, and needs to be further investigated in a larger cohort.

Hemorrhagic Risk

Our current study demonstrated a significantly lower risk of ruptured presentation ($P = .04$) in HHT patients, with only 8.3%

TABLE 4. Hemorrhage Events for All Patients^a

	All Patients (N = 531)	Patients Without HHT (N = 519)	Patients With HHT (N = 12)
Observation period, mean (SD), y	2.9 (7.2)	2.7 (6.7)	12.5 (15.8)
Observation period, patient-years	1543.0	1393.4	149.5
Total number of hemorrhages, n	44	42	2
Interval to first hemorrhage, mean (SD), y	2.6 (6.4)	2.4 (6.0)	10.8 (14.6)
Annual rate, %	2.9	3.0	1.3

^aHHT, hereditary hemorrhagic telangiectasia; SD, standard deviation.

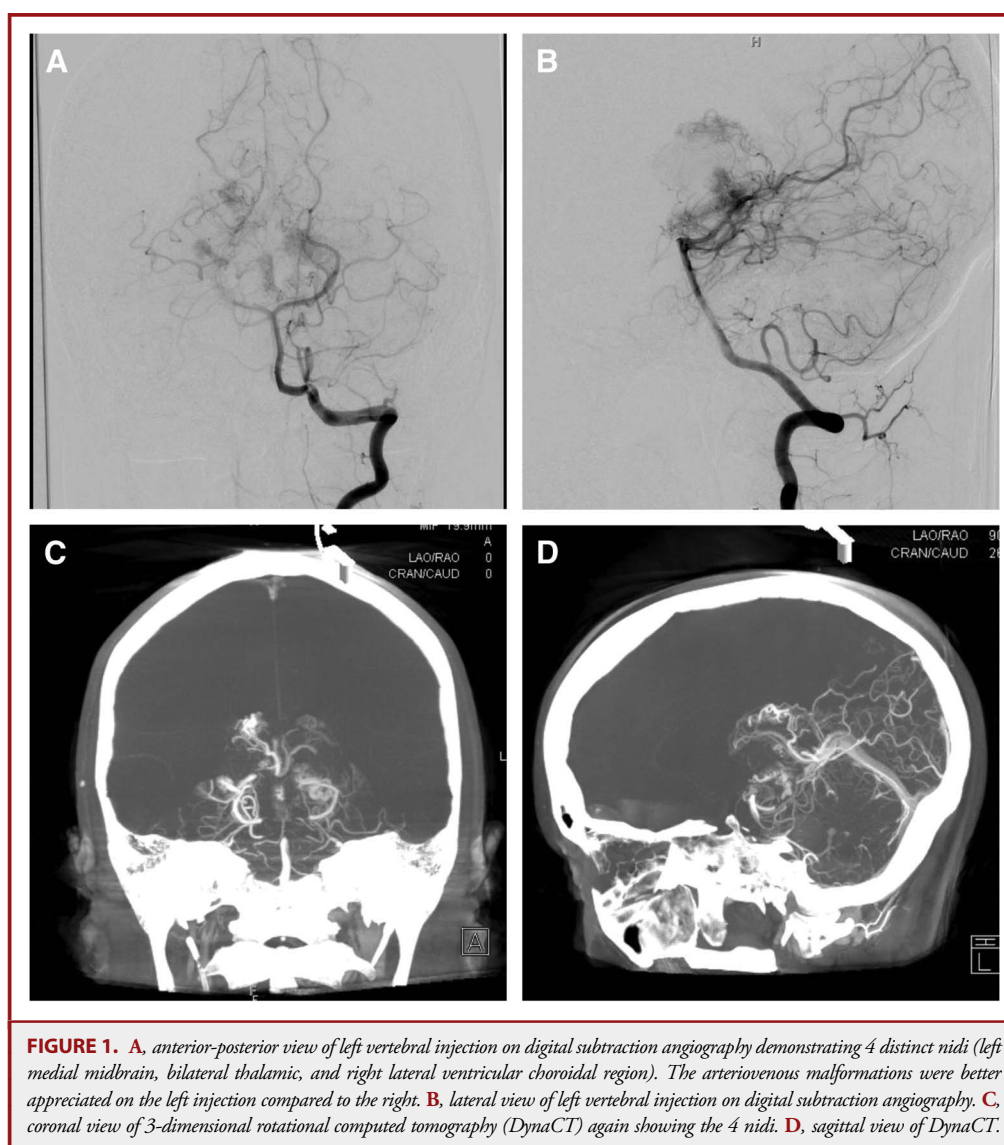
TABLE 5. Hemorrhage Events for All AVMs^a

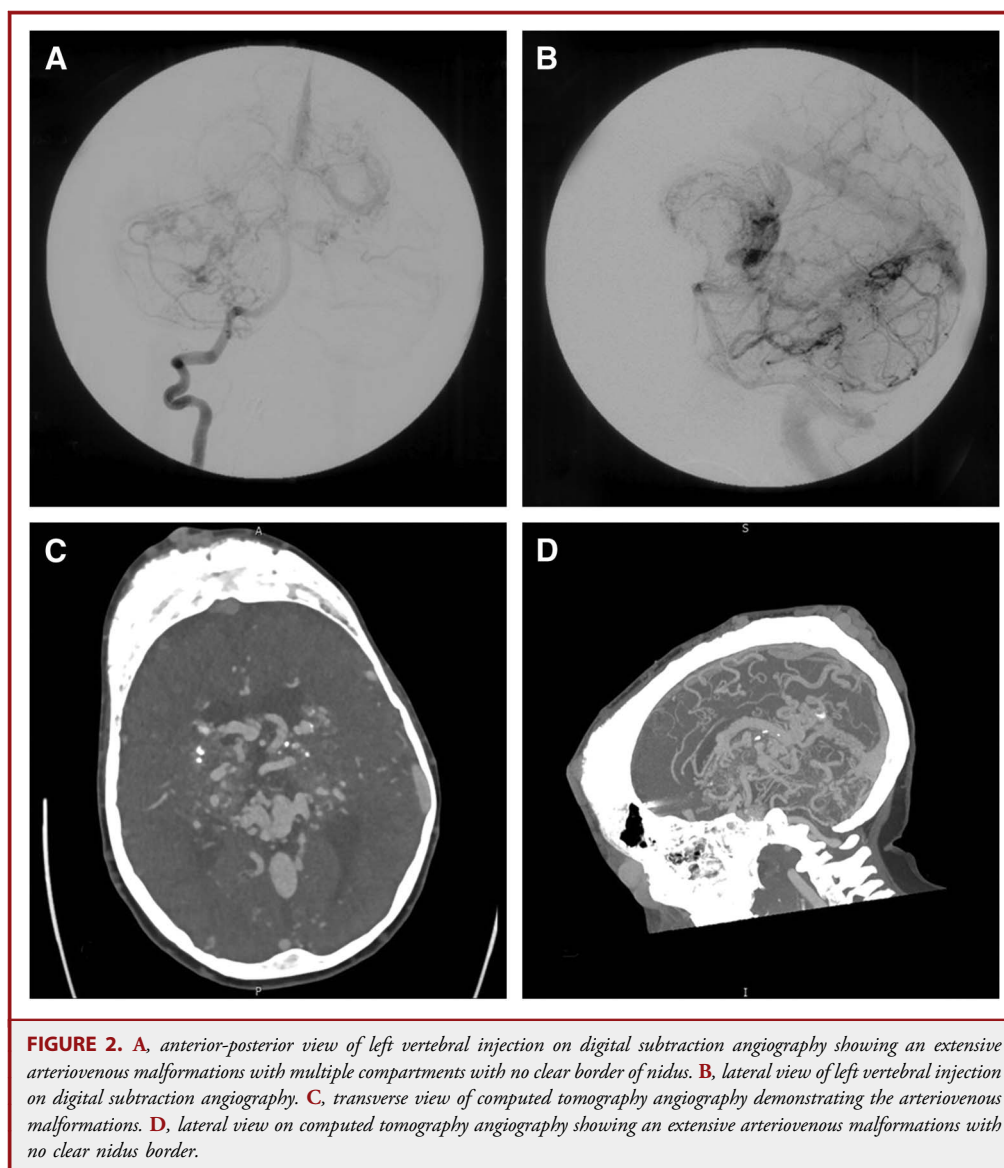
	All AVMs (N = 542)	AVMs in Patients Without HHT (N = 519)	AVMs in Patients With HHT (N = 23)
Observation period, mean (SD), y	3.1 (7.5)	2.7 (6.7)	12.9 (14.8)
Observation period, lesion-years	1690.9	1393.4	297.5
Total number of hemorrhages, n	44	42	2
Interval to first hemorrhage, mean (SD), y	2.8 (6.8)	2.4 (6.0)	12.1 (14.2)
Annual rate, %	2.6	3.0	0.7

^aAVM, arteriovenous malformations; HHT, hereditary hemorrhagic telangiectasia; SD, standard deviation.

of all HHT-related AVM patients presenting with an ICH as compared to 36.8% in the non-HHT group. Although HHT-related AVMs were generally considered to have a more benign

natural history, conflicting rates of hemorrhagic presentation have been presented in previous studies, and the risk of hemorrhagic presentation varied largely among different studies.





In contrast to the hemorrhagic presentation risk of 30% to 82% in sporadic AVMs,¹⁴⁻¹⁹ the risk for HHT-related AVM patients in a previous study conducted by Willemse et al³ was only reported to be 12.5%. This finding was further confirmed by Kim et al¹² who noted the risk to be 14% in the Brain Vascular Malformation Consortium (BVMC) study. On the contrary, Maher et al⁵ reported a 50% ICH presentation rate in their cohort of 10 HHT-related AVM patients. Similarly, in a case series of 11 pediatric HHT-related AVMs reported by Saleh et al,⁸ the hemorrhagic presentation risk was reported to be 36.4%. The presentation of AVM was subject to variations in the detection, as early onset of HHT-related symptoms leading to suspicion of potential presence of intracranial AVMs may result in early detection of AVMs in its unruptured form. Therefore,

differences in screening protocols for intracranial AVMs in HHT patients would influence the hemorrhagic presentation risk.

Another method to evaluate hemorrhagic risk is to quantify the risk of subsequent hemorrhage after detection of AVMs in HHT patients. Including our current study, there are only 3 studies that quantified the risk of subsequent hemorrhage after detection of AVMs in HHT patients. Willemse et al³ were the first to calculate an annualized hemorrhagic risk for HHT-related AVM patients. In their cohort of 196 HHT patients, 22 patients were found to have a total of 28 intracranial AVMs with an annualized hemorrhagic risk of 0.41%-0.72% per patient and 0.36%-0.56% per AVM. In a more recent study by Kim et al¹² in 2015, the hemorrhagic risk was reported at a higher rate of 1.02% (CI = [0.42-2.44]) per patient per year, with ruptured cases having

a risk as high as 10.07% per patient per year. Our current study features the first to directly compare baseline characteristics and hemorrhagic risks between sporadic AVMs and HHT-related AVMs. Although we failed to observe an association between rupture presentation and subsequent hemorrhage in HHT-related AVMs, our overall estimated annualized hemorrhagic risk of 1.3% per patient for HHT-related AVMs and 3.0% per patient for sporadic AVMs was compatible with the previously reported rates.

The hemorrhage risks presented in these studies need to be interpreted with caution. The rarity of subsequent ICH has greatly limited the ability to generate reliable annualized hemorrhagic risks for these studies. In a combined cohort of 187 patients (current study, Willemse et al,³ and Kim et al¹²), only 6 patients (3.2%) experienced a subsequent hemorrhage after diagnosis of intracranial AVMs. Willemse et al³ did not observe any hemorrhagic event during an average observation period of 6 years; therefore, they calculated the upper limit of hemorrhagic risk by adding a hypothetical hemorrhage in their follow-up period. Of note, the lower end of the estimated risk in their study was calculated using the interval from birthdate to last follow-up under the assumption that these AVMs were congenital, which significantly elongated the follow-up period. Using the same methodology, our estimated hemorrhagic risk would be 0.7% per patient per year, which was comparable to the described risk. However, given increasing evidence in current literature describing de novo AVMs,²⁰⁻²⁵ the actual risk of hemorrhage was potentially underestimated, as HHT-related AVMs might be acquired instead of congenital. On the other hand, the hemorrhagic event in the study by Kim et al¹² was defined as the first ICH event after detection of AVM. The authors did not report how many ICHs occurred during the entire follow-up period. Therefore, the hemorrhagic risk in this study might also be underestimated, as all subsequent ICH after the first ICH were excluded from the calculation.

Frequent presentation of multiple intracranial AVMs also complicated the analysis process. To overcome these difficulties, a per-lesion risk was reported along with per-patient risk. Although both our study and the study by Willemse et al³ were able to generate a per-lesion risk, the calculation and interpretation of per-lesion risk remained a challenge. Determination of the causal lesion for hemorrhage might not be possible if all AVMs were anatomically proximal to each other. Furthermore, on some occasions, it was difficult to angiographically distinguish between multiple AVMs and a single AVM with multiple compartments. It was also unclear whether the rupture of one AVM was an independent event without involvement of the other AVMs. Therefore, without further evidence, simply adding per-lesion hemorrhagic rate together for a patient with multiple intracranial AVMs might not be representative of the true hemorrhagic risk in this patient.

Management Strategy

Selection of management strategy for patients with HHT-related AVMs seemed to be less controversial. Although a signif-

icant proportion of HHT-related AVMs present as accessible and low risk lesions that may be deemed favorable to treat when assessed using similar criteria for treatment of sporadic AVMs, the pathophysiology between these 2 groups of lesions is different, and the determination of treatment should be considered from different perspectives. First, the assessment of the risk associated with treatment might be complicated by presentation of multiple lesions. Secondly, given the more dynamic nature of these lesions provided by numerous reports on lesion growth or regression,²⁶⁻²⁸ the determination of prognosis might be further complicated by frequently changing angiographic parameters. In addition, under most circumstances, the most compelling presenting symptoms were usually non-neurologic; therefore, the priority of treatment should be directed to other HHT-related lesions instead of intracranial AVMs. Finally, the hemorrhagic risk of the intracranial component had been reported to be significantly lower than sporadic AVMs. Although we did not observe a statistical significance in difference between per-patient risk between the 2 groups, it should be noted that the non-HHT group still conferred a 2.5-fold higher risk than HHT-related AVMs, and the per-lesion risk demonstrated significant difference between the 2 groups. In addition, the severity of ICH seemed to be milder in HHT-related AVMs. Compared to the reported mortality rate of 5.6% to 53.6% after ICH in sporadic AVMs,^{17-19,29-32} no mortality was associated with hemorrhagic presentation or subsequent hemorrhage in our current study or the existing literature. Considering the risk-to-benefit ratio of treatment, HHT patients generally benefit from close follow-up without aggressive pursuit for obliteration of intracranial HHT-related AVMs. However, in light of the successful surgical resection of the 2 cases in our series, along with existing reports of successful treatment of HHT-related AVMs,^{6,33} definitive treatment of these lesions may still be warranted for controlling hemorrhagic risk and intractable seizures for patients with low grade and accessible HHT-related AVMs, provided that the treatment risk profile is favorable.

Limitations

Our study has several limitations and need to be addressed for accurate interpretation of the results. Most data in this study were retrospectively acquired and might have observation bias and attrition bias. Although bias and loss of information was inevitable in this kind of study, we rigorously minimized these shortcomings by comparing and extracting data from different sources of information including medical records, image studies, and patient-order-entry documents. In our database of 696 AVM patients, data attrition was found in 23.7% of all our patients, resulting in a study cohort of 531 AVM patients. Nevertheless, despite some attrition in our study cohort, we managed to perform analysis on the majority (76.3%) of our patients, and no patients in the HHT group were excluded despite data attrition. The early detection of HHT-related AVMs might elongate the observation period and potentially underestimates the risk of hemorrhage.

However, some of the differences in the observation period between the 2 groups are also related to the calculation method we utilized. The observation period for treated patients, which was defined as the interval between diagnosis and treatment, is generally short. Because most patients in sporadic AVMs were treated, a significantly shorter period was observed. Compared to only 16.7% treated patients in the HHT group, 83.4% of the patients (n = 433) in the non-HHT group were treated. The average observation interval in the treated sporadic AVM group was 1.67 years; in contrast, for conservatively managed sporadic AVM patients, the average observation time was 7.80 years. Another limitation that was associated with this study was the small sample size of the HHT group. Similar to the other 2 studies describing hemorrhagic risk of HHT-related AVM, the rare occurrence of subsequent ICH might result in a wide variance in our reported hemorrhagic risk, and limited our capacity of stratifying the risk by potential confounding factors. In addition, the large difference of sample size between the HHT group and non-HHT group may introduce additional statistical biases. However, our current study still adds one more patient with subsequent hemorrhage to a very small cohort, and the results of our study should provide valuable information for further investigation of true hemorrhagic risk in this population.

CONCLUSION

Patients with HHT-related intracranial AVMs present at a younger age with milder presenting symptoms and more often harbor multiple intracranial AVMs. These AVMs are smaller in size, with lower Spetzler-Martin grades, and less frequent temporal lobe involvement. Under most circumstances, conservative management should be recommended given the multiplicity and relatively lower risk of hemorrhage. Definitive treatment of HHT-related AVMs may be warranted for symptomatic and accessible lesions.

Disclosure

The authors have no personal, financial, or institutional interest in any of the drugs, materials, or devices described in this article.

REFERENCES

- Guttmacher AE, Marchuk DA, White RI. Hereditary hemorrhagic telangiectasia. *N Engl J Med*. 1995;333(14):918-924.
- Fuchizaki U, Miyamori H, Kitagawa S, Kaneko S, Kobayashi K. Hereditary haemorrhagic telangiectasia (Rendu-Osler-Weber disease). *Lancet*. 2003;362(9394):1490-1494.
- Willemse RB, Mager JJ, Westermann CJ, Overtom TT, Mauser H, Wolbers JG. Bleeding risk of cerebrovascular malformations in hereditary hemorrhagic telangiectasia. *J Neurosurg*. 2000;92(5):779-784.
- Bharatha A, Faughnan ME, Kim H, et al. Brain arteriovenous malformation multiplicity predicts the diagnosis of hereditary hemorrhagic telangiectasia: quantitative assessment. *Stroke*. 2012;43(1):72-78.
- Maher CO, Piegras DG, Brown RD, Friedman JA, Pollock BE. Cerebrovascular manifestations in 321 cases of hereditary hemorrhagic telangiectasia. *Stroke*. 2001;32(4):877-882.
- Maarouf M, Runge M, Kocher M, Zähringer M, Treuer H, Sturm V. Radio-surgery for cerebral arteriovenous malformations in hereditary hemorrhagic telangiectasia. *Neurology*. 2004;63(2):367-369.
- Woodall MN, McGettigan M, Figueroa R, Gossage JR, Alleyne CH. Cerebral vascular malformations in hereditary hemorrhagic telangiectasia. *J Neurosurg*. 2014;120(1):87-92.
- Saleh M, Carter MT, Latino GA, Dirks P, Ratjen F. Brain arteriovenous malformations in patients with hereditary hemorrhagic telangiectasia: clinical presentation and anatomical distribution. *Pediatr Neurol*. 2013;49(6):445-450.
- Devlin HL, Hosman AE, Shovlin CL. Antiplatelet and anticoagulant agents in hereditary hemorrhagic telangiectasia. *N Engl J Med*. 2013;368(9):876-878.
- Salaria M, Taylor J, Bogwitz M, Winship I. Hereditary haemorrhagic telangiectasia, an Australian cohort: clinical and investigative features. *Intern Med J*. 2014;44(7):639-644.
- McDonald MJ, Brophy BP, Kneebone C. Rendu-Osler-Weber syndrome: a current perspective on cerebral manifestations. *J Clin Neurosci*. 1998;5(3):345-350.
- Kim H, Nelson J, Krings T, et al. Hemorrhage rates from brain arteriovenous malformation in patients with hereditary hemorrhagic telangiectasia. *Stroke*. 2015;46(5):1362-1364.
- Shovlin CL, Guttmacher AE, Buscarini E, et al. Diagnostic criteria for hereditary hemorrhagic telangiectasia (Rendu-Osler-Weber syndrome). *Am J Med Genet*. 2000;91(1):66-67.
- da Costa L, Wallace MC, Brugge Ter KG, O'Kelly C, Willinsky RA, Tymianski M. The natural history and predictive features of hemorrhage from brain arteriovenous malformations. *Stroke*. 2009;40(1):100-105.
- Gross BA, Du R. Natural history of cerebral arteriovenous malformations: a meta-analysis. *J Neurosurg*. 2013;118(2):437-443.
- Hernesniemi JA, Dashti R, Juvela S, Väärt K, Niemelä M, Laakso A. Natural history of brain arteriovenous malformations: a long-term follow-up study of risk of hemorrhage in 238 patients. *Neurosurgery*. 2008;63(5):823-829; discussion 829-831.
- Crawford PM, West CR, Chadwick DW, Shaw MD. Arteriovenous malformations of the brain: natural history in unoperated patients. *J Neurol Neurosurg Psychiatr*. 1986;49(1):1-10.
- Graf CJ, Perret GE, Torner JC. Bleeding from cerebral arteriovenous malformations as part of their natural history. *J Neurosurg*. 1983;58(3):331-337.
- Ondra SL, Troupp H, George ED, Schwab K. The natural history of symptomatic arteriovenous malformations of the brain: a 24-year follow-up assessment. *J Neurosurg*. 1990;73(3):387-391.
- Neil JA, Li D, Stiefel MF, Hu YC. Symptomatic de novo arteriovenous malformation in an adult: case report and review of the literature. *Surg Neurol Int*. 2014;5(1):148.
- Miller BA, Bass DI, Chern JJ. De novo AVM formation. *Childs Nerv Syst*. 2015;31(7):1023.
- Gonzalez LF, Bristol RE, Porter RW, Spetzler RF. De novo presentation of an arteriovenous malformation. Case report and review of the literature. *J Neurosurg*. 2005;102(4):726-729.
- Kilbourn KJ, Spiegel G, Killory BD, Kureshi I. Case report of a de novo brainstem arteriovenous malformation in an 18-year-old male and review of the literature. *Neurosurg Rev*. 2014;37(4):685-691.
- Yeo JYY, Low SY, Seow WT, Low DCY. Pediatric de novo cerebral AVM: report of two cases and review of literature. *Childs Nerv Syst*. 2015;31(4):609-614.
- Morales-Valero SF, Bortolotti C, Sturiale CL, Lanzino G. Are parenchymal AVMs congenital lesions? *Neurosurg Focus*. 2014;37(3):E2.
- Cloft HJ. Spontaneous regression of cerebral arteriovenous malformation in hereditary hemorrhagic telangiectasia. *AJNR Am J Neuroradiol*. 2002;23(6):1049-1050.
- Leung KM, Agid R, terBrugge K. Spontaneous regression of a cerebral arteriovenous malformation in a child with hereditary hemorrhagic telangiectasia. Case report. *J Neurosurg*. 2006;105(5 suppl):428-431.
- Du R, Hashimoto T, Tihan T, Young WL, Perry V, Lawton MT. Growth and regression of arteriovenous malformations in a patient with hereditary hemorrhagic telangiectasia. Case report. *J Neurosurg*. 2007;106(3):470-477.
- Fults D, Kelly DL. Natural history of arteriovenous malformations of the brain: a clinical study. *Neurosurgery*. 1984;15(5):658-662.
- Choi JH, Mast H, Sciacca RR, et al. Clinical outcome after first and recurrent hemorrhage in patients with untreated brain arteriovenous malformation. *Stroke*. 2006;37(5):1243-1247.
- Fleetwood IG, Steinberg GK. Arteriovenous malformations. *Lancet*. 2002;359(9309):863-873.
- Brown RD, Wiebers DO, Forbes G, et al. The natural history of unruptured intracranial arteriovenous malformations. *J Neurosurg*. 1988;68(3):352-357.

33. Kuo Y-H, Santoreneos S, Roos D, Brophy BP. Treatment of multiple arteriovenous malformations in pediatric patients with hereditary hemorrhagic telangiectasia and spontaneous hemorrhage. Report of two cases. *J Neurosurg*. 2007;107(6 suppl):489-494.

COMMENTS

The authors investigated clinical behaviors and angiographic features of brain arteriovenous malformations (bAVMs) among patients with baseline hereditary hemorrhagic telangiectasia (HHT) by analyzing a large retrospective cohort database. They concluded that HHT patients with bAVMs were diagnosed of AVM at younger age, with multiple bAVMs, and those AVMs were likely smaller, with lesser deep venous drainage, and had less intracranial hemorrhage events. Based on their observation, they proposed to treat HHT-associated bAVMs more conservatively.

This is a valuable study and can provide some insights in managing those rare HHT patients with bAVMs, albeit its retrospective limitation. I agree with the demographic and angiographic observation of these patients and lesions. However, I find significant selection bias in reaching the hemorrhagic risk conclusion. The authors had adopted a conservative management paradigm in treating HHT patients with bAVMs through the study period from 1990 to 2013. Most of these lesions were observed for a long period of time without hemorrhagic events or intervention. On the contrary, they treated more than 80% of non-HHT bAVMs with typically much shorter observation. Not surprisingly, a benign clinical course was concluded for HHT-associated bAVMs. Hopefully, with the implementation of the NeuroVascular Quality Initiative and other national and international collaborative efforts among neurovascular specialists, we can accumulate substantial prospective data on rare conditions like HHT-associated bAVMs, so that we can reach a more accurate understanding of these diseases and offer our patients improved treatment.

Y. Jonathan Zhang
Houston, Texas

The authors present a retrospective review of a prospectively collected database of patients presenting to their institution with brain arteriovenous malformations (AVM) between 1990 and 2013. Adequate clinical information was available for 531 patients with 542 AVMs, 12 of which were diagnosed with hereditary hemorrhagic telangiectasia (HHT). They found that patients with HHT were less likely to be symptomatic from their AVM, less likely to present with AVM rupture, and less likely to present with seizure than non-HHT AVM patients. HHT AVMs were smaller in size and had a lower Spetzler-Martin grade when compared to sporadic AVMs. Hemorrhage risk was calculated and was found to be

1.3% per year in the HHT group and 3.0% per year in the non-HHT group; a difference that was not statistically significant. They go on to argue that HHT AVMs generally have a more benign course (no deaths in the present study) than sporadic AVMs, and therefore conservative management of HHT brain AVMs is recommended.

This article is one of a very few to attempt to estimate hemorrhage risk for HHT AVMs, and therefore is valuable. The data, however, must be interpreted with caution. Hemorrhage risk was calculated as (number of intracranial hemorrhages)/(total patient years). The observation period for untreated AVMs was the interval between the time the AVM diagnosis was made until either (1) hemorrhage or (2) last follow-up visit. The observation period for treated AVMs was the interval between the time of diagnosis and the date of the first treatment of the AVM. Patients diagnosed with HHT are generally screened for brain vascular malformations at the time an HHT diagnosis is made. This is reflected by the younger age (23.3 vs 36.8 years) in the HHT group, which reached statistical significance. This difference also translated into an average observation period of 12.5 years in the HHT group, compared to a 2.7 year observation period in the non-HHT group. Screening of HHT patients is very likely to skew this sort of analysis toward a lower hemorrhage risk for HHT patients, as they will necessarily have a longer observation period than patients with sporadic AVMs.

The authors cite a low hemorrhage rate in their series (1 of 12 HHT patients experienced AVM rupture), but although the annualized hemorrhagic risk was lower for the HHT group as compared to the non-HHT group (1.3% vs 3.0%, respectively), the difference was not statistically significant ($P = .37$). The difference in hemorrhagic risk between HHT and non-HHT group only reached statistical significance when considered on a per-lesion basis. They presuppose that AVM multiplicity in HHT would increase procedure risk. On these grounds they conclude that HHT AVMs should be managed conservatively (because of a lower rupture risk, more benign course at the time of rupture, and increased theoretical procedure risk). The authors present no data, however, on procedure risk in HHT. Also, the percentage of AVMs treated in the HHT and non-HHT groups are not presented in the data. This information would be helpful.

The authors present interesting data that adds to the current understanding of the natural history of HHT AVMs; however, we think their conclusions (ie, HHT AVMs should be managed conservatively) are not supported by the data in this article.

M. Neil Woodall
Cargill H. Alleyne Jr
Augusta, Georgia