

## Case Reports

# Progressing Ischemic Stroke in a Homozygote With Variant Antithrombin III

Hidetsugu Ueyama, MD, Yoichiro Hashimoto, MD, Makoto Uchino, MD,  
Yasuto Sasaki, MD, Eiichiro Uyama, MD, Kenji Okajima, MD, and Shukuro Araki, MD

**A 31-year-old woman developed disturbance of consciousness and left hemiparesis. Cerebral computed tomograms showed a low-density area in the right temporal lobe that extended to the right parietal and left frontal lobes as her clinical symptoms worsened. The diagnosis of familial variant of antithrombin III (AT-III) was based on decreased biologic activity and a normal immunologic level of AT-III in this patient and in her family members. Transfusion of normal AT-III concentrate led to a striking clinical recovery. Blood coagulation studies revealed that nine of 13 family members had decreased biologic AT-III activity and that the patient herself was the only homozygote with variant AT-III. We conclude that variant AT-III, especially in a homozygote, seems to be one cause of ischemic stroke in young adults and that simultaneous measurement of both the biologic and immunologic activities of AT-III is necessary to detect it. (*Stroke* 1989;20:815–818)**

**S**ince cardiogenic, hematologic, or inflammatory diseases often predispose to thromboembolic stroke in young adults, both early diagnosis and early therapy of the predisposing disease are important, especially during the acute phase.<sup>1-3</sup> We examined a young woman with progressing ischemic stroke associated with a familial variant of antithrombin III (AT-III). Cerebral thrombosis associated with AT-III deficiency is extremely rare, although some patients with cerebral venous thrombosis have been reported.

### Case Report

A 31-year-old woman had a history of two transient ischemic attacks at ages 17 and 29 years and three episodes of deep-vein thrombosis of the extremities at ages 23 and 29 years. She had been given ticlopidine and pentoxifylline since she was 29 years old. On November 24, 1987, she caught cold, and the next day she developed weakness of her left upper extremity that lasted for 20 minutes. On November 27, she became aware of numbness of her right palm and transient blurred vision of her right eye. She developed headache, nausea, and vomiting and subsequently discontinued her ticlopidine and pentoxi-

fylline. On admission the next day, she was alert and had normal physical findings except for numbness of her right palm and an ulcer of her right leg due to an old case of thrombophlebitis.

Routine laboratory examinations revealed normal values except for iron-deficiency anemia, elevated lactate dehydrogenase concentration, and presence of rheumatoid factor. Tests for coagulation and fibrinolysis showed prominent acceleration of fibrinolysis, such as E fraction of fibrinogen degradation product 2026 (normal 8.1–70) ng/ml, fibrin monomer test 2+, and D-dimer 2000 (normal <200) ng/ml. The biologic activity of AT-III was as low as 42% of control (heparin cofactor activity, incubation time 5 minutes; normal 81–121%), while its immunologic activity was as high as 37.1 (single radial immunodiffusion method; normal 27–33) mg/dl. The dissociation of the biologic and immunologic activities of AT-III in her plasma suggested the presence of a variant form of AT-III. The biologic activity of heparin cofactor-II was also as low as 48.5% (normal 70–150%).<sup>4</sup> Bleeding, prothrombin, and activated partial prothrombin times and fibrinogen,  $\alpha_2$ -plasmin inhibitor, protein C, protein S,  $\alpha_1$ -antitrypsin, and  $\alpha_2$ -macroglobulin concentrations were all normal. Electroencephalography revealed delta rhythmic activity, predominantly in the right temporal area. Chest x-ray film, electrocardiogram, and echocardiogram were all normal.

On December 1 (Day 1), her nausea and headache increased and her level of consciousness gradually fell. That morning, transient generalized convulsions occurred. Neurologically, she was somnolent,

From the First Department of Internal Medicine (H.U., Y.H., M.U., Y.S., E.U., S.A.) and the Department of Laboratory Medicine (K.O.), Kumamoto University Medical School, Kumamoto, Japan.

Address for reprints: Hidetsugu Ueyama, MD, First Department of Internal Medicine, Kumamoto University Medical School, Honjo 1-1-1, Kumamoto 860, Japan.

Received September 15, 1988; accepted November 23, 1988.

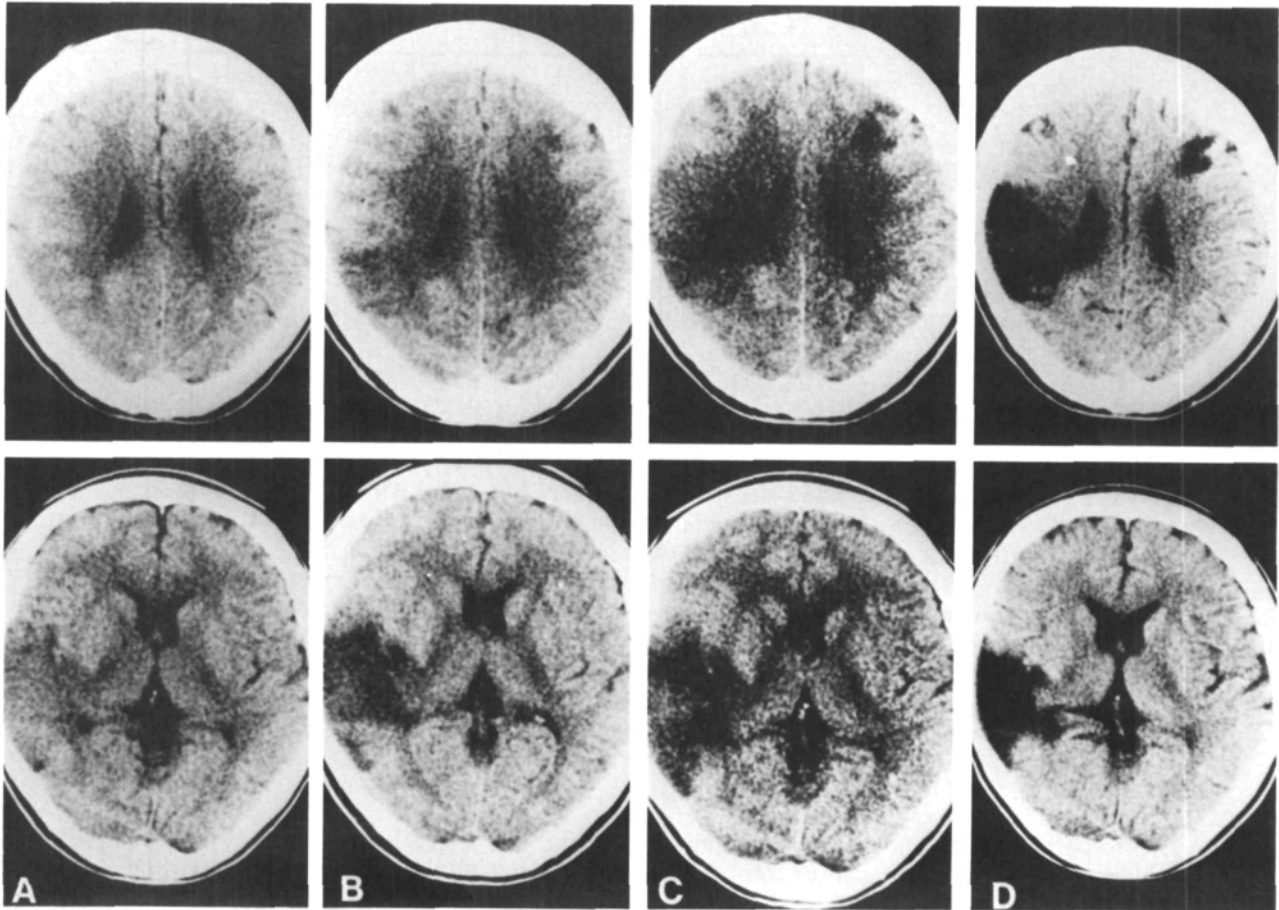


FIGURE 1. Cerebral computed tomograms showed low-density area in right temporal lobe on Day 1 (A). By Day 2, low-density area had extended to right parietal lobe (B). By Day 3, low-density area had appeared in left frontal lobe (C). On Day 54, clear low-density area remained in right parietotemporal and left frontal lobes (D).

her eyes showed horizontal roving movements, and there was hemiparesis with hemifacial paresis on her left side (upper limb dominant only detected by Barré's sign). We diagnosed ischemic stroke based on a low-density area in the right temporal lobe on a cerebral computed tomogram (CT scan) (Figure 1A). On Day 2, she became stuporous and her weakness worsened. The low-density area extended to the right parietal lobe (Figure 1B). On enhanced CT scan, there were neither enhanced lesions nor empty delta signs. On Day 3, she developed a semicomatose state with left complete hemiplegia and transient Cheyne-Stokes respiration. A new low-density area appeared in the left frontal lobe (Figure 1C). At this time we found that her biologic AT-III activity was quite low, and we determined that her family members' activity was also depressed. Thus, we diagnosed familial AT-III deficiency.<sup>5,6</sup> On Day 3, we started daily intravenous transfusions of normal AT-III concentrate (1500 units/day). As this treatment raised the biologic AT-III activity, her level of consciousness gradually improved to normal on Day 9 and her strength began to return. The low-density area stopped spreading. On Day 15, treatment with warfarin gave sufficient control to prevent thrombosis.

By Day 54, her mentation, memory, and gait had recovered to normal and no new stroke was found on CT scan (Figure 1D).

Carotid angiography performed on Day 14 revealed branch occlusions of the right middle cerebral artery (Figure 2). There was neither atherosclerotic change of the cerebral arteries nor cerebral venous thrombosis.

On hematologic examination of 13 members of her family, eight (including her parents) had decreased biologic activity and normal immunologic activity of AT-III, while one member showed a decrease in both. Thus, we diagnosed a familial variant of AT-III.<sup>5,6</sup> The mode of inheritance is suspected to be autosomal dominant. On crossed immunoelectrophoresis and affinity chromatography of their plasma, the patient was found to be a homozygote and the others (including her parents) were found to be heterozygotes.<sup>7,8</sup>

#### Discussion

Familial AT-III deficiency is divided into two groups: quantitative AT-III deficiency and dysfunctional AT-III (variant of AT-III).<sup>8-11</sup> Although familial variant of AT-III is an extremely rare disorder, about 20 families have been reported.<sup>5,6,12-14</sup> In

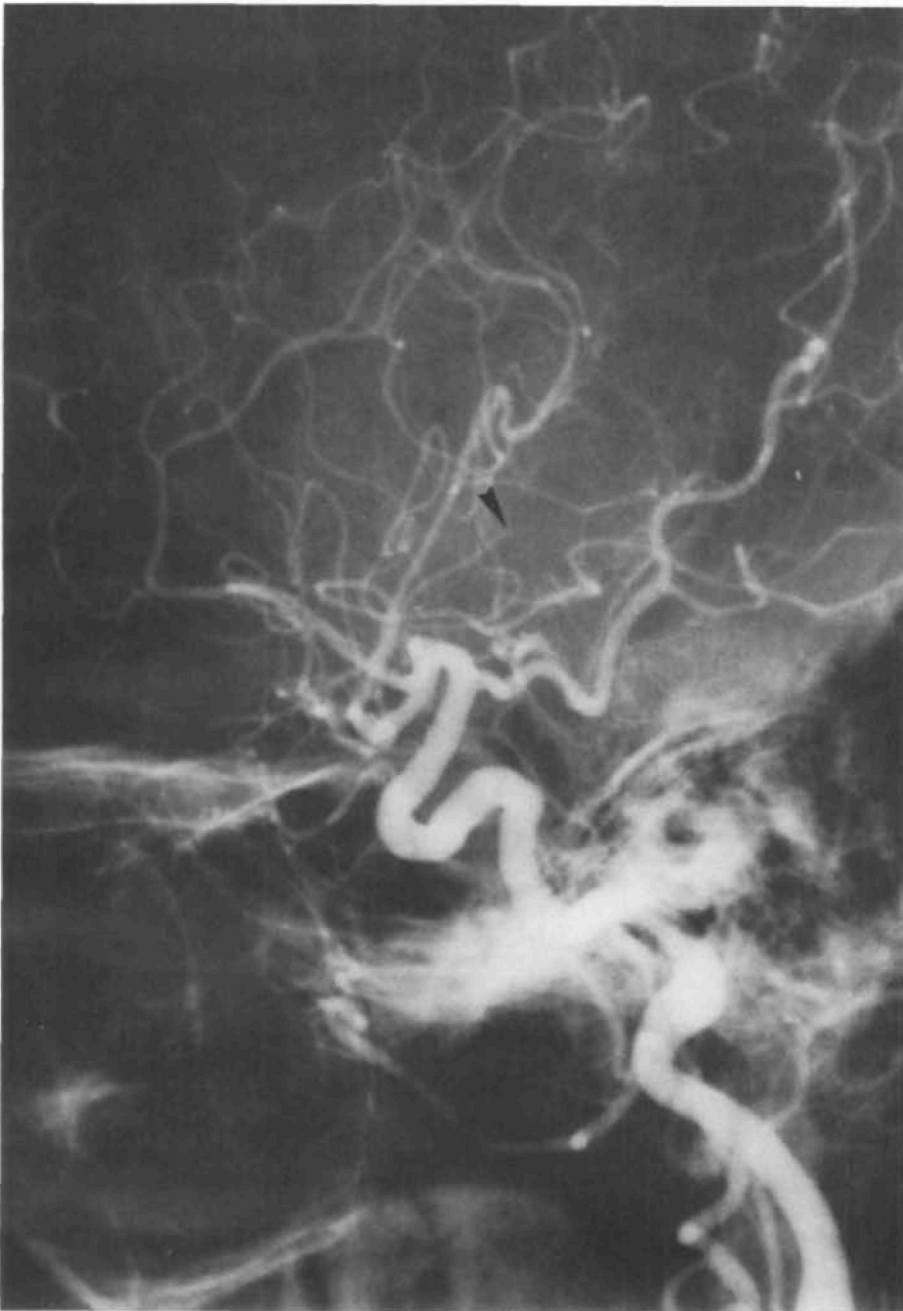


FIGURE 2. Lateral view of left internal carotid angiogram revealed branch occlusions of right middle cerebral artery (arrow).

these families, a variant molecule of AT-III, immunologically detectable but biologically abnormal, is apparently produced. Although reduced AT-III activity occasionally produces venous thrombosis, reports of arterial thrombosis are rare.<sup>6,7,10,15-17</sup>

The clinical features of our case represented a progressing ischemic stroke,<sup>18</sup> progression of clinical symptoms and extension of the low-density area for 3 days. At first we speculated a cerebral sinus thrombosis because of her severe headache and nausea, but this was later ruled out due to the absence of empty delta signs on the enhanced CT scan and good venous filling on the carotid angiogram.<sup>19</sup> Whether she had developed a cerebral thrombosis or an embolism is a difficult clinical

question. We speculated thrombosis because of the gradual onset, spread over several days, and absence of paradoxical embolism.

The most important clinical point of our case is that we successfully diagnosed her as having a familial variant of AT-III during the acute period of her stroke and that concentrated AT-III infusion produced a striking clinical improvement.<sup>20,21</sup> Heparin by itself may be ineffective since its action largely depends on the presence of normal AT-III.<sup>22</sup>

It is still controversial whether reduced AT-III activity is the predisposing factor of stroke.<sup>23-26</sup> Only six other cases of cerebral thrombosis associated with familial AT-III deficiency have been reported (Table 1).<sup>10,12,15-17</sup> Their common clinical

TABLE 1. Reports of Ischemic Stroke Associated With Familial Antithrombin III Deficiency

Case	Author	Age	Sex	Ob- structed artery	Antithrombin III	
					Biologic activity	Antigen level
1	Nagy et al <sup>10</sup>	39	M	R MCA	28%	Decreased
2	Nagy et al <sup>10</sup>	21	M	L ICA	30%	Decreased
3	Hirasawa et al <sup>15</sup>	51	M	L MCA	54%	Decreased
4*	Horie et al <sup>16</sup>	23	F	R MCA	26%	Increased
5*	Girolami et al <sup>12</sup>	38	F	R MCA	50%	Normal
6	Shinmyozu et al <sup>17</sup>	38	M	L ICA	49%	Decreased
7*	Current report	31	F	R MCA	42%	Increased

M, male; F, female; R, right; L, left; MCA, middle cerebral artery; ICA, internal carotid artery.

\*Variant of antithrombin III (dysfunctional AT-III).

features were the occurrence in young adults and occlusion of the truncal arteries rather than the perforating arteries. Three of the seven cases (including ours) had a familial variant of AT-III, and two of the three were homozygotes. Since a homozygote is in a more hypercoagulable state than a heterozygote, arterial thrombosis is thought to be more frequent. Indeed, among her family, only our patient had recurrent thrombotic episodes.

We conclude that variant AT-III, especially in the case of a homozygote, seems to be a cause of ischemic stroke even in young adults. Simultaneous measurement of both biologic and immunologic activities of AT-III is necessary for diagnosis of this disease.

### References

- Natowicz M, Kelley RI: Mendelian etiologies of stroke. *Ann Neurol* 1987;22:175-192
- Hart RG, Miller VT: Cerebral infarction in young adults: A practical approach. *Stroke* 1983;14:110-114
- Hilton-Jones D, Warlow CP: The causes of stroke in the young. *J Neurol* 1985;232:137-143
- Tollefsen DM, Majerus DW, Blank MK: Heparin cofactor II. Purification and properties of a heparin dependent inhibitor of thrombin in human plasma. *J Biol Chem* 1982; 257:2162-2169
- Sas G, Blaskó G, Bánhegyi D, Jákó J, Pálos LÁ: Abnormal antithrombin III (antithrombin III 'Budapest') as a cause of a familial thrombophilia. *Thromb Diath Haemorrh* (Stuttg) 1974;32:105-115
- Sakuragawa N, Takahashi K, Kondo S, Koide T: Antithrombin III Toyama: A hereditary abnormal antithrombin III of a patient with recurrent thrombophlebitis. *Thromb Res* 1983; 31:305-317
- Sas G, Pepper DS, Cash JD: Plasma and serum antithrombin-III: Differentiation by crossed immunoelectrophoresis. *Thromb Res* 1975;6:87-91
- Sas G, Pető I, Bánhegyi D, Blaskó G, Domján G: Heterogeneity of the "classical" antithrombin III deficiency. *Thromb Haemost* 1980;43:133-136
- Egeberg O: Inherited antithrombin deficiency causing thrombophilia. *Thromb Diath Haemorrh* 1965;13:516-530
- Nagy I, Losonczy H, Szaksz I, Temesi C, Hergert K: An analysis of clinical and laboratory data in patients with congenital antithrombin III (AT-III) deficiency. *Acta Med Acad Sci Hung* 1979;36:53-60
- Cosgriff TM, Bishop DT, Hershgold EJ, Skolnick MH, Martin BA, Baty BJ, Carlson KS: Familial antithrombin III deficiency: Its natural history, genetics, diagnosis and treatment. *Medicine* 1983;62:209-220
- Girolami A, Marafioti F, Rubertelli M, Vicarioto MA, Cappellato G, Mazzuccato M: Antithrombin III Trento. A 'new' congenital AT III abnormality with a peculiar crossed-immunoelectrophoretic pattern in the absence of heparin. *Acta Haematol* 1984;72:73-82
- Boyer C, Wolf M, Vedrenne J, Meyer D, Larrieu MJ: Homozygous variant of antithrombin III: AT III Fontainebleau. *Thromb Haemost* 1986;56:18-22
- Fischer AM, Cornu P, Sternberg C, Mériane F, Dautzenberg MD, Chafa O, Beguin S, Desnos M: Antithrombin III Alger: A new homozygous AT III variant. *Thromb Haemost* 1986; 55:218-221
- Hirasawa Y, Hayashi M, Nagaoka T, Kuto F, Tokuhiko H: Three families with hereditary antithrombin III deficiency: The use of antithrombin III concentrate in one of the patients through the course of mastectomy. *Nippon Ketsueki Gakkai Zasshi* 1981;44:683-689
- Horie Y, Kosu K, Endo S, Takaku A, Takahashi K, Sakuragawa N, Tomikawa M: A case of the occlusion of the right middle cerebral artery due to congenital antithrombin III (AT III) deficiency. *Neurosurgery* (Tokyo) 1982; 10:177-183
- Shinmyozu K, Ohkatsu Y, Maruyama Y, Osame M, Igata A: A case of congenital antithrombin III deficiency complicated by an internal carotid artery occlusion. *Rinsho Shinkeigaku* 1986;26:162-165
- Price TR: Progressing ischemic stroke, in Barnett HJM, Mohr JP, Stein BM, Yatsu FM (eds): *Stroke: Pathophysiology, Diagnosis, and Management*. Philadelphia, Churchill Livingstone Inc, 1986, vol 2, pp 1059-1068
- Kalbag RM, Woolf AL: Thrombosis and thrombophlebitis of cerebral veins and dural sinuses, in Vinken PJ, Bruyn GW (eds): *Handbook of Clinical Neurology*. Amsterdam, North-Holland, 1972, pp 422-446
- Winter JH, Fenech A, Bennett B, Douglas AS: Transfusion studies in patients with familial antithrombin III (AT III) deficiency: Half-disappearance time of infused AT III and influence of such infusion on platelet life-span. *Br J Haematol* 1981;49:449-453
- Mannucci PM, Boyer C, Wolf M, Tripodi A, Larrieu MJ: Treatment of congenital antithrombin III deficiency with concentrates. *Br J Haematol* 1982;50:531-535
- Marciniak E, Gockerman JP: Heparin-induced decrease in circulating antithrombin-III. *Lancet* 1977;17:581-584
- Fletcher AP, Alkjaersig N, Davies A, Lewis M, Brooks J, Hardin W, Landau W, Raichle ME: Blood coagulation and plasma fibrinolytic enzyme system pathophysiology in stroke. *Stroke* 1976;7:337-348
- Panicucci F, Sagripanti A, Conte B, Pinori E, Vispi M, Lecchini L: Antithrombin III, heparin cofactor and antifactor Xa in relation to age, sex and pathological condition. *Haemostasis* 1980;9:297-302
- Tengborn L, Larsson SA, Hedner U, Nilsson IM: Coagulation studies in children and young adults with cerebral ischemic episodes. *Acta Neurol Scand* 1981;63:351-361
- Yamaguchi S, Kobayashi S, Tsunematsu T: The timecourse of antithrombin III (AT III) level in the ischemic cerebrovascular disease. *Jpn J Stroke* 1983;5:111-116

KEY WORDS • young adults • cerebrovascular disorders • antithrombin III

**Progressing ischemic stroke in a homozygote with variant antithrombin III.**  
H Ueyama, Y Hashimoto, M Uchino, Y Sasaki, E Uyama, K Okajima and S Araki

*Stroke*. 1989;20:815-818

doi: 10.1161/01.STR.20.6.815

*Stroke* is published by the American Heart Association, 7272 Greenville Avenue, Dallas, TX 75231

Copyright © 1989 American Heart Association, Inc. All rights reserved.

Print ISSN: 0039-2499. Online ISSN: 1524-4628

The online version of this article, along with updated information and services, is located on the  
World Wide Web at:

<http://stroke.ahajournals.org/content/20/6/815>

**Permissions:** Requests for permissions to reproduce figures, tables, or portions of articles originally published in *Stroke* can be obtained via RightsLink, a service of the Copyright Clearance Center, not the Editorial Office. Once the online version of the published article for which permission is being requested is located, click Request Permissions in the middle column of the Web page under Services. Further information about this process is available in the [Permissions and Rights Question and Answer](#) document.

**Reprints:** Information about reprints can be found online at:  
<http://www.lww.com/reprints>

**Subscriptions:** Information about subscribing to *Stroke* is online at:  
<http://stroke.ahajournals.org/subscriptions/>