



Case Report

Transient widespread cortical and splenial lesions in acute encephalitis/encephalopathy associated with primary Epstein–Barr virus infection

Shuo Zhang^a, Juan Feng^{a,*}, Yifang Shi^b^a Department of Neurology, Shengjing Hospital of China Medical University, 36 Sanhao Street, Heping District, Shenyang, Liaoning, 110004, China^b Department of Pediatrics, Shenyang Children's Hospital, Shenyang, Liaoning, China

ARTICLE INFO

Article history:

Received 28 August 2015

Received in revised form 7 November 2015

Accepted 12 November 2015

Corresponding Editor: Eskild Petersen, Aarhus, Denmark

Keywords:

Epstein–Barr virus encephalitis

Encephalopathy

Reversible splenial lesion

Magnetic resonance imaging

Acute disseminated encephalomyelitis

SUMMARY

Infection with Epstein–Barr virus (EBV) is very common and usually occurs in childhood or early adulthood. Encephalitis/encephalopathy is an uncommon but serious neurological complication of EBV. A case of EBV-associated encephalitis/encephalopathy with involvement of reversible widespread cortical and splenial lesions is presented herein. An 8-year-old Chinese girl who presented with fever and headache, followed by seizures and drowsiness, was admitted to the hospital. Magnetic resonance imaging revealed high signal intensities on diffusion-weighted imaging in widespread cortical and splenial lesions. The clinical and laboratory examination results together with the unusual radiology findings suggested acute encephalitis/encephalopathy due to primary EBV infection. After methylprednisolone pulse therapy together with ganciclovir, the patient made a full recovery without any brain lesions. The hallmark clinical–radiological features of this patient included severe encephalitis/encephalopathy at onset, the prompt and complete recovery, and rapidly reversible widespread involvement of the cortex and splenium. Patients with EBV encephalitis/encephalopathy who have multiple lesions, even with the widespread involvement of cortex and splenium of the corpus callosum, may have a favorable outcome with complete disappearance of all brain lesions.

© 2015 The Authors. Published by Elsevier Ltd on behalf of International Society for Infectious Diseases. This is an open access article under the CC BY-NC-ND license (<http://creativecommons.org/licenses/by-nc-nd/4.0/>).

1. Introduction

Epstein–Barr virus (EBV), also called human herpes virus 4, is a member of the herpes virus family. Ninety percent of Chinese people become infected within the first few years of life.¹ Worldwide, EBV infection usually occurs during childhood and does not generally cause clinically symptomatic diseases. However, if primary infection is delayed until adolescence or beyond, it is associated with the clinical syndrome of acute infectious mononucleosis in approximately 25–50% of cases.² Moreover, EBV infection is associated with some malignant neoplasms in adults.^{3–5} EBV can also result in various neurological complications, especially in immunocompromised patients.

The neurological manifestations of EBV infection were first noted by Epstein and Johansen.^{6,7} The occurrence of neurological complications mainly depends on the individual's state of

immunocompetence and age, and the forms of complications include encephalitis/encephalopathy, meningitis, cerebellitis, optic neuritis, peripheral neuropathy, cranial nerve palsy, Alice-in-Wonderland syndrome, post-infectious autoimmune disorders including Guillain–Barré syndrome, acute disseminated encephalomyelitis (ADEM), and transverse myelitis.⁸ Encephalitis/encephalopathy is an uncommon but serious central nervous system (CNS) complication of EBV,⁹ and is sometimes fatal in children.¹⁰

A case of encephalitis/encephalopathy due to primary EBV infection, in which follow-up magnetic resonance imaging (MRI) showed multiple reversible lesions occurring in the bilateral frontoparietal and occipital lobes, along with a complete clinical recovery within a few weeks, is reported herein. Different magnetic resonance images of viral encephalitis/encephalopathy with transient callosal lesions have been described previously, such as clinically mild encephalitis/encephalopathy with a reversible splenial lesion (MERS), but to the authors' knowledge no such widespread cortex involvement has been reported as is described in the present case.^{10,11}

* Corresponding author.

E-mail address: snow78@yeah.net (J. Feng).

2. Case presentation

An 8-year-old Chinese girl was admitted to the hospital from a nearby primary hospital with generalized tonic–clonic seizures and mental deterioration following 1 day of prodromal symptoms consisting of severe headache with vomiting and a high fever (40.0 °C). The patient had previously been healthy and had no past history of infectious mononucleosis. An initial cranial computed tomography scan in the primary hospital was unrevealing. Before admission, she had received acetaminophen as an antipyretic and had been treated with diazepam for epilepsy.

On admission, her Glasgow score (GCS) was 11 (E2, V4, C5) and her vital signs were normal except for a temperature of 38.2 °C. She was drowsy, but did not show any focal neurological signs and was without lymphadenopathy. She had recurrent seizures without regaining consciousness and had to be intubated. Anticonvulsive treatment with midazolam was initiated. Blood laboratory results suggested a marginal leukocytosis (93.4% neutrophil and 3.1% monocytes), but marked atypical lymphocytes were not detected; creatine kinase was elevated (MM 1195 U/l, MB 41 U/l, and BB 56 U/l), but there was no other abnormality. Heterophile antibody testing and EBV capsid antigen antibodies (IgM and IgG) were positive; IgG antibodies against nuclear antigen (EBNA) were negative. Serology for other pathogens including herpes simplex virus (HSV 1 and 2), varicella zoster virus (VZV), *Chlamydia pneumoniae*, *Mycoplasma pneumoniae*, cytomegalovirus (CMV), mumps virus, Japanese encephalitis virus (JEV), measles virus, and ECHO virus showed negative IgM. Cerebrospinal fluid (CSF) analysis showed an abnormal cell count (125×10^6 white cells/l, 75% lymphocytes), protein of 11 mg/dl (reference range 0–40 mg/dl for children aged 6 months to 10 years), glucose of 4.38 mmol/l (corresponding to blood sugar of 6.12 mmol/l), and chloride of 128.3 mmol/l (reference range 120–132 mmol/l), with a pressure

Table 1
MRI sequence parameters

	T1WI	T2WI	DWI	FLAIR
TR, ms	2205	3540	6500	8000
TE, ms	22.5	98	90	169
FOV, mm	240	240	240	240
Matrix	512 × 512	512 × 512	256 × 256	256 × 256
Thickness, mm	7.5	7.5	7.5	7.5
b, s/mm ²	-	-	1000	-

MRI, magnetic resonance imaging; WI, weighted imaging; DWI, diffusion-weighted imaging; FLAIR, fluid-attenuated inversion recovery; TR, repetition time; TE, echo time; FOV, field of view.

of 190 mmH₂O. CSF viral capsid antigen IgM was positive. A quantitative real-time EBV PCR assay for CSF was positive and quite high (26 400 copies/ml).¹² Results of the CSF analysis showed the absence of nucleic acid of HSV (1 and 2), CMV, VZV, and *M. pneumoniae*. No conclusive evidence of autoimmune rheumatic disorders was found.

A brain MRI scan was initially performed with a 3.0-T unit (Signa HDxt; GE Health) including T1-weighted (T1W), T2-weighted (T2W), fluid-attenuated inversion recovery (FLAIR), and diffusion-weighted imaging (DWI) sequences. The parameters of the MRI protocol are reported in Table 1. The images showed widespread DWI signal intensity hyperintensities in different cortical areas, especially the bilateral and symmetrical parieto-occipital areas, which were most marked in the splenium of the corpus callosum, with involvement of the white matter of the left posterior horn. The T1W, T2W, and FLAIR sequences did not show obvious signal abnormalities except slight T1W hypointensity and T2W hyperintensity in the splenium (Figure 1). Therefore, the MRI findings suggested a cytotoxic edema.

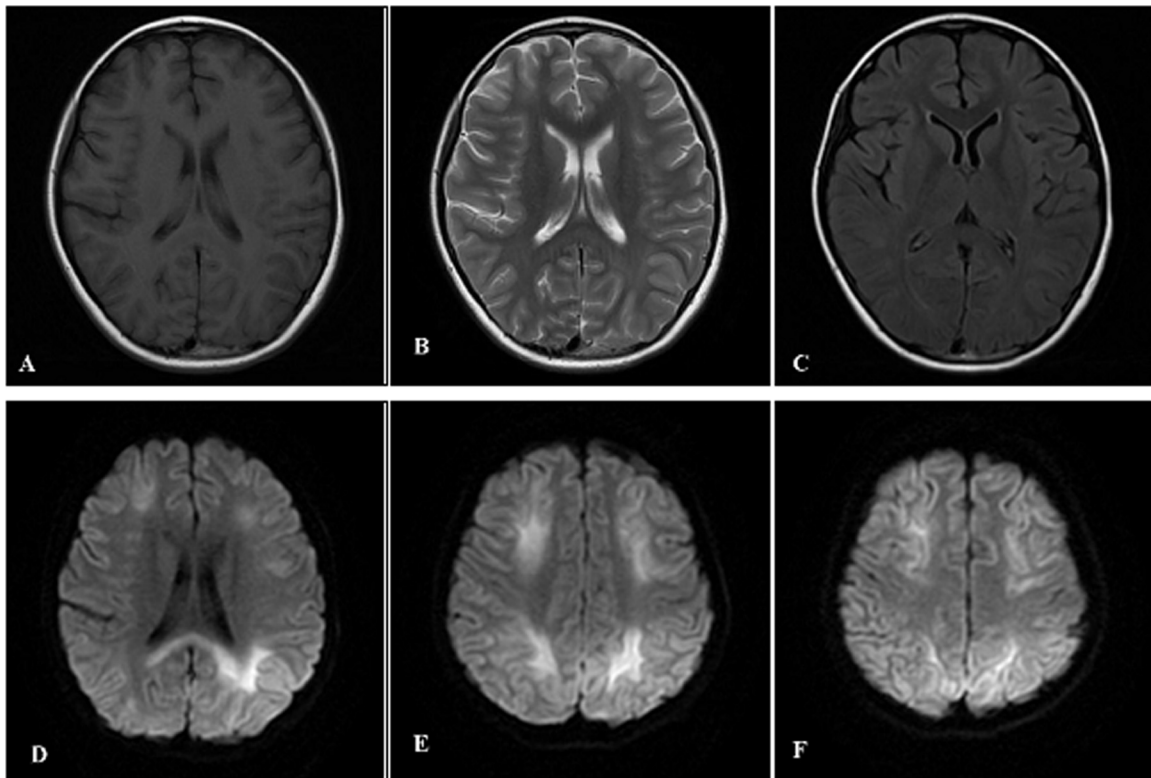


Figure 1. T1W (A), T2W (B), and FLAIR (C) sequences of the initial 3.0-T MRI did not show obvious signal abnormalities, except slight T1W hypointensity (A) and T2W hyperintensity (B) in the splenium. However, widespread DWI signal intensity hyperintensities were shown in different cortical areas, especially bilateral and symmetrical parieto-occipital areas (E and F), and were most marked in the splenium of the corpus callosum (D), with involvement of the white matter of the left posterior horn.

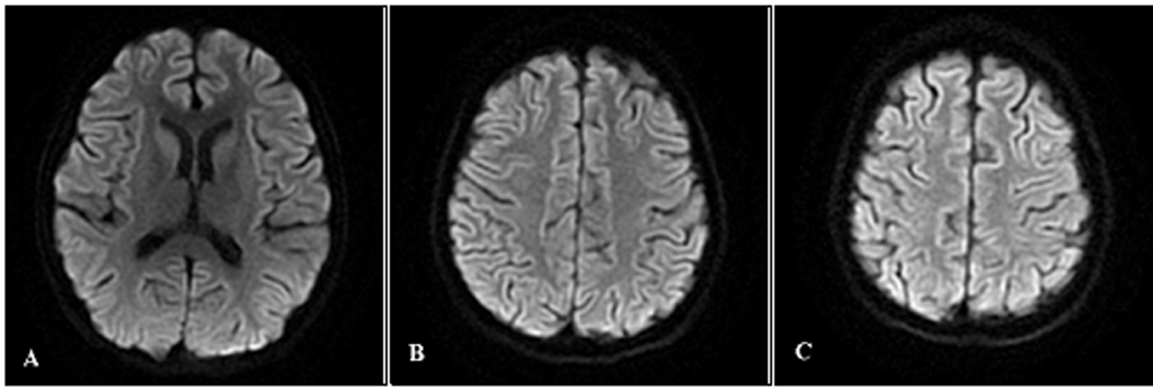


Figure 2. Follow-up 3.0-T MRI about 3 weeks later indicated that the DWI signal hyperintensities had disappeared completely in the splenial (A) and cortical lesions (B and C).

The clinical and serological results together with the radiological findings formed the basis of the diagnosis of acute encephalitis/encephalopathy due to primary EBV infection.¹⁰ High-dose methylprednisolone (30 mg/kg/day once daily for 5 days), followed by oral prednisolone in a rapidly tapering dose and ganciclovir (5 mg/kg/day twice daily for 2 weeks) were given. The treatment was successful. On day 6 after admission to the hospital, the patient started breathing spontaneously and midazolam was withdrawn. She subsequently made gradual improvements over the next 2 weeks, with no focal neurological signs, and was discharged on day 15. Follow-up MRI on day 28 revealed complete resolution of the DWI hyperintensities (Figure 2) and she had made a complete recovery without any symptoms.

This study was approved by the Ethics Committee of Shengjing Hospital, China Medical University.

3. Discussion

Despite the lack of typical manifestations of infectious mononucleosis such as fever, pharyngitis, and adenopathy, the presence of heterophile antibodies, increased capsid antigen antibodies (IgM and IgG), absence of IgG anti-EBNA, and high viral load in the CSF disclosed that this patient was suffering from a primary rather than a reactivated EBV infection.

The MRI findings described with EBV encephalitis/encephalopathy are non-specific and frequently haphazard. The regions affected, as reported by neuroimaging, include the cerebral hemisphere, thalamus, basal ganglia, brain stem, cerebellum, the limbic system, and corpus callosum. The MRI findings in about 40% of patients with EBV encephalitis/encephalopathy can show normal parenchyma without signal abnormality, leptomeningeal enhancement, and gyral edema of the cortical and deep gray matter.¹¹ There may also be white matter involvement, but rarely are both the gray matter and corpus callosum simultaneously involved.¹³ Patients with reversible diffusion restriction in the splenium of the corpus callosum have been described, and the entity has been defined as reversible splenium lesion syndrome (RESLES). RESLES has been reported secondary to several disorders, including other viral encephalitis, autoimmune encephalopathy, antiepileptic drug toxicity or withdrawal, and hypoglycemia in adults and children.¹⁴ Most of the conditions mentioned above were excluded in the patient described herein.

Although the cases of two EBV encephalitis/encephalopathy patients who also had reversible splenial lesions accompanied by extracallosal lesions have been reported by Takanashi et al.¹⁵ and Hagemann et al.,¹³ the MRI findings in the present case were not completely the same as those of these previous cases. Specifically, the extracallosal lesion in the patient reported by Takanashi et al. was located in the peripheral frontoparietal white matter rather

than the cortices.¹⁵ Furthermore, Hagemann et al. reported that their patient's lesions were located in the splenium of the corpus callosum and the cortical lesions were focal and distributed in both posterior hemispheres.¹³ However, widespread bilateral cortex involvement (frontoparietal and occipital lobes) was found only in the case reported here.

The imaging results of the present case patient may have both pathogenetic and prognostic implications. It has been proposed that involvement of the cortex gray matter corresponds to a classical encephalitis/encephalopathy with perivascular infiltrates, neuronophagia, and glial nodules. While splenium with subcortical white matter involvement may correlate with post-infectious inflammatory demyelination of the type seen in ADEM, the specific affinity of EBV antigens or induced antibodies to the splenial axonal receptors may be responsible for the splenial involvement in EBV-associated encephalitis/encephalopathy. Moreover, those patients with EBV encephalitis/encephalopathy who have had brainstem and thalamic but not basal ganglia lesions have tended to have poor outcomes.¹¹ The favorable outcome in the present patient may have been the result in part of the splenial and cortical involvement alone.

Although ADEM lesions typically involve multiple, asymmetrical white matter, basal ganglia, and thalamus, which were not seen in the present case, an EBV-induced ADEM or other post-infectious autoimmune encephalitis/encephalopathy cannot be fully ruled out because of the favorable curative effects of high-dose steroids and the lack of specificity for EBV PCR in the CSF.

The role of antiviral drugs in the treatment of EBV-related CNS infections has not been well established. Despite the definite pathogenesis of the neurological complications due to EBV infection being unknown, ganciclovir has been recommended for broad-spectrum anti-DNA virus therapy, which has no specific activity against EBV. Ganciclovir can suppress DNA virus replication, which has been shown to have favorable efficacy in treating EBV primary infection.¹⁰ There are a few reports of successful treatment of EBV-related neurological complications in transplant or other immunocompromised patients,^{9,16,17} however the role of ganciclovir in a disease whose natural history has not been completely elucidated is unknown. Moreover, no study has directly compared other nucleoside analogs, including valganciclovir and acyclovir, in the treatment of EBV-related CNS infections.

It is generally believed that high-dose methylprednisolone therapy may be an effective treatment for severe EBV encephalitis, possibly associated with autoimmune mechanisms. However, there have been few high-quality clinical trials using methylprednisolone for the treatment of EBV encephalitis/encephalopathy, and there is some debate surrounding the use of corticosteroid therapy. So far there has been no randomized controlled trial of the combination use of corticosteroids and ganciclovir for the

treatment of any of the neurological complications of EBV, but it seems to be a reasonable option when EBV post-infectious ADEM is suspected, as suggested by the favorable outcome of the patient presented here.

In conclusion, the case of a patient with the involvement of transient widespread cortical and splenial lesions due to primary EBV infection is described. This report shows that patients with EBV-associated encephalitis/encephalopathy who have widespread and multiple lesions may still make a full recovery. Further studies should be performed to clarify whether patients with EBV-related CNS infections had resolution of the viral load in CSF or not during follow-up.

Consent: Written informed consent was obtained from the patient's parents for publication of this case report and any accompanying images.

Conflict of interest: The authors declare that they have no competing interests.

References

- Huang Y, Wei C, Zheng K, Zhao D. The impact of serological features in Chinese children with primary or past Epstein–Barr virus infections. *Virology* 2013;**10**:55.
- Vetsika EK, Callan M. Infectious mononucleosis and Epstein–Barr virus. *Expert Rev Mol Med* 2004;**6**:1–16.
- Chen H, Chi P, Wang W, Li L, Luo Y, Fu J, et al. Evaluation of a semi-quantitative ELISA for IgA antibody against Epstein–Barr virus capsid antigen in the serological diagnosis of nasopharyngeal carcinoma. *Int J Infect Dis* 2014;**25**:110–5.
- Chen XZ, Chen H, Castro FA, Hu JK, Brenner H. Epstein–Barr virus infection and gastric cancer: a systematic review. *Medicine (Baltimore)* 2015;**94**:e792.
- Zhang W, Chen Y, Chen L, Guo R, Zhou G, Tang L, et al. The clinical utility of plasma Epstein–Barr virus DNA assays in nasopharyngeal carcinoma: the dawn of a new era?. A systematic review and meta-analysis of 7836 cases. *Medicine (Baltimore)* 2015;**94**:e845.
- Epstein S, Dameshek W. Involvement of the central nervous system in a case of glandular fever. *N Engl J Med* 1931;**205**:1238–41.
- Johansen AH. Serous meningitis and infectious mononucleosis. *Acta Med Scand* 1931;**76**:269–72.
- Tselis AC. Epstein–Barr virus infections of the nervous system. *Handb Clin Neurol* 2014;**123**:285–305.
- Babik JM, Katrak S, Miller S, Shah M, Chin-Hong P. Epstein–Barr virus encephalitis in a renal transplant recipient manifesting as hemorrhagic, ring-enhancing mass lesions. *Transpl Infect Dis* 2015;**17**:744–750.
- Doja A, Bitnun A, Ford Jones EL, Richardson S, Tellier R, Petric M, et al. Pediatric Epstein–Barr virus-associated encephalitis: 10-year review. *J Child Neurol* 2006;**21**:384–91.
- Abul-Kasim K, Palm L, Maly P, Sundgren PC. The neuroanatomic localization of Epstein–Barr virus encephalitis may be a predictive factor for its clinical outcome: a case report and review of 100 cases in 28 reports. *J Child Neurol* 2009;**24**:720–6.
- Martelius T, Lappalainen M, Palomaki M, Anttila VJ. Clinical characteristics of patients with Epstein Barr virus in cerebrospinal fluid. *BMC Infect Dis* 2011;**11**:281.
- Hagemann G, Mentzel HJ, Weisser H, Kunze A, Terborg C. Multiple reversible MR signal changes caused by Epstein–Barr virus encephalitis. *AJNR Am J Neuroradiol* 2006;**27**:1447–9.
- Zhang S, Ma Y, Feng J. Clinicoradiological spectrum of reversible splenial lesion syndrome (RESLES) in adults: a retrospective study of a rare entity. *Medicine (Baltimore)* 2015;**94**:e512.
- Takanashi J, Barkovich AJ, Shiihara T, Tada H, Kawatani M, Tsukahara H, et al. Widening spectrum of a reversible splenial lesion with transiently reduced diffusion. *AJNR Am J Neuroradiol* 2006;**27**:836–8.
- Hocker B, Bohm S, Fickenscher H, Kusters U, Schnitzler P, Pohl M, et al. (Val-)Ganciclovir prophylaxis reduces Epstein–Barr virus primary infection in pediatric renal transplantation. *Transpl Int* 2012;**25**:723–31.
- Khalil M, Enzinger C, Wallner-Blazek M, Scarpatetti M, Barth A, Horn S, et al. Epstein–Barr virus encephalitis presenting with a tumor-like lesion in an immunosuppressed transplant recipient. *J Neurovirol* 2008;**14**:574–8.