

Subdural hematoma in a patient taking imatinib for GIST: a case report and discussion of risk with other chemotherapeutics

Christian B. Theodotou^a, Ashish H. Shah^b, Michael E. Ivan^b and Ricardo J. Komotar^b

Although anticancer drugs have existed for over 50 years, targeted drugs have only recently been marketed, and their side effects may not be completely understood. The patient is a 56-year-old woman with a gastrointestinal stromal tumor who presented with headache, nausea, and vomiting lasting 2 weeks. An MRI to rule out brain metastasis found a large right-hemispheric subdural hematoma without metastases. She denied trauma, seizures, or alcohol abuse. Laboratory test results were normal. Eight months prior, she had begun a dose escalation of imatinib, which became the suspected cause of her hemorrhage. The literature was reviewed for reports of intracranial hemorrhage with targeted chemotherapeutics excluding metastases, anticoagulation, and trauma. Multiple events have been documented but only one for imatinib with gastrointestinal stromal tumor. Imatinib is believed to cause platelet dysfunction (missed by standard testing), leading to

intracranial hemorrhage. Intracranial hemorrhage risk may be under-reported and neurosurgical consultation for immediate treatment and oncology for reinitiation of chemotherapy are recommended. *Anti-Cancer Drugs* 27:259–263 Copyright © 2016 Wolters Kluwer Health, Inc. All rights reserved.

Anti-Cancer Drugs 2016, 27:259–263

Keywords: chemotherapy, gastrointestinal stromal tumor, imatinib, intracranial hemorrhage, subdural hematoma

Departments of ^aSurgery and ^bNeurological Surgery, University of Miami Miller School of Medicine, Miami, Florida, USA

Correspondence to Ricardo J. Komotar, MD, Department of Neurological Surgery, University of Miami Miller School of Medicine, 1321 NW 14th Street West Building Suite 306 Miami, FL 33125, USA
Tel: + 1 305 243 2427; fax: + 1 305 689 3320; e-mail: rkomotar@med.miami.edu

Received 8 October 2015 Revised form accepted 5 November 2015

Introduction

Dose-dependent hemotoxicity from chemotherapeutic agents was discovered early after their introduction to the market in the 1940s [1]. In these early trials of therapy, patients would routinely suffer from profound anemia, leukopenia, and thrombocytopenia; however, these barriers to treatment were countered to a certain extent by the development of platelet transfusion in the 1960s and granulocyte colony stimulating factors in the 1990s [1–4]. Nevertheless, to avoid these systemic hematopoietic toxicities of traditional chemotherapeutics, targeted therapies began to emerge such as imatinib, erlotinib, and bevacizumab [1]. Although deemed generally safe, these targeted molecular therapeutics may pose additional risks that are not fully understood by clinicians. The following case report concerns a patient who received one of these agents – imatinib – for a gastrointestinal stromal tumor (GIST) and subsequently suffered from an unprovoked acute subdural hematoma (SDH).

Case report

The patient is a 56-year-old woman who was diagnosed with GIST in 2007 after presenting with fatigue, anemia, and early satiety. Because of the size and location of the tumor, neoadjuvant chemotherapy with imatinib was administered at a dose of 400 mg daily, after which

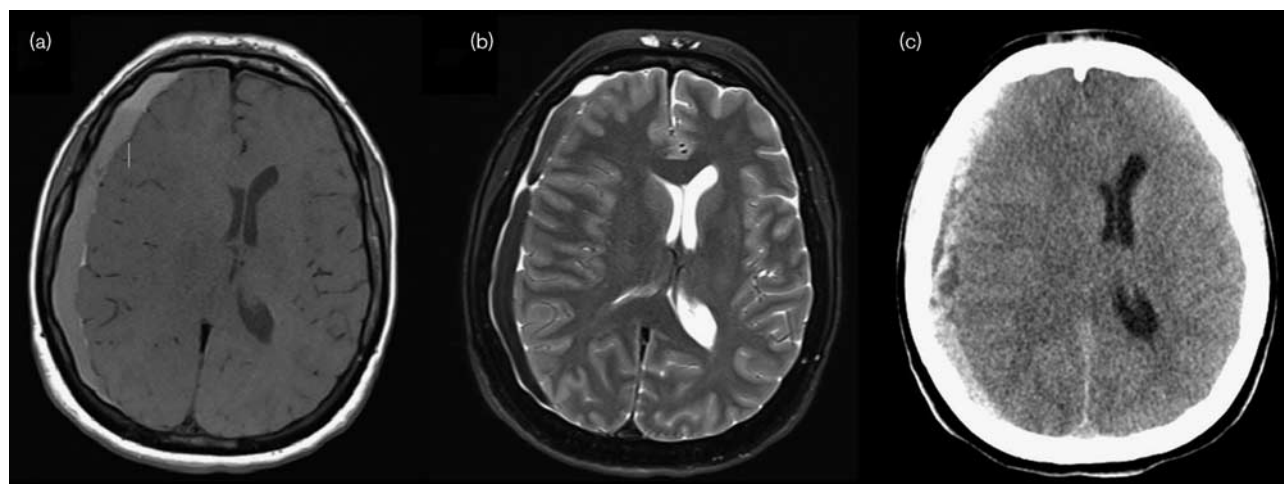
resection was attempted. Over the next 7 years, the tumor progressed, and the patient continued on higher dosages of imatinib.

Because of worsening headaches and intermittent nausea and vomiting over 2 weeks, the patient underwent an MRI (Fig. 1a and b), which showed a right-hemispheric acute SDH. The patient remained neurologically intact without any sign of any focal neurological deficit. The patient denied any history of recent trauma or seizures, and the patient was not taking any antiplatelet medication or anticoagulant. Platelet count, coagulation, and liver function studies were normal on admission. Imatinib was stopped and the patient did not have any further progression of SDH (computed tomography; Fig. 1c). A right frontotemporal craniotomy was performed to evacuate the SDH and its associated membranes. The patient tolerated the procedure well and was discharged home in a stable condition.

Discussion

Acute nontraumatic SDHs in nonelderly/noncoagulopathy patients are rare events and should be investigated thoroughly for a proposed etiology. In this case, the SDH did not appear to have an obvious cause such as recent head trauma, thrombocytopenia, or therapeutic anticoagulation. Given the patient's age (56 years, without a

Fig. 1



(a) T1-weighted and (b) T2-weighted MRI of the brain showing a right-hemispheric subdural hematoma with midline shift and impending uncus herniation. (c) Computed tomography scan of the brain showing holohemispheric acute on subacute subdural hematoma with midline shift, subfalcine herniation, and impending uncus herniation.

history of alcohol abuse), the likelihood of an unprovoked acute SDH remains low. After review of the patient's current medication side-effect profiles, there was some clinical suspicion that the SDH may have been related to imatinib, which has previously been described to increase the risk for central nervous system hemorrhage [5].

Because of this, we conducted a search of the literature to identify whether other clinicians had reported similar events with imatinib. A clinical trial by Demetri *et al.* [6] that tested two dosages of imatinib in 147 patients with GIST found no instance of SDH or cerebral hemorrhage. To our knowledge, there has only been one prior reported case of a GIST patient treated with imatinib subsequently suffering an SDH [7]. In their case, Feki *et al.* [7] reported a similar situation in which a 44-year-old imatinib-treated GIST patient with no history of trauma or anticoagulation medication administration developed an SDH and subsequently died. With many novel chemotherapeutic agents on the market, identification of severe adverse events such as SDH is essential. We identify and discuss below multiple reports of targeted chemotherapeutics with possible associations with SDH (Table 1).

Imatinib

Imatinib mesylate (Gleevec; Novartis, Basel, Switzerland) is a tyrosine kinase (TK) inhibitor that has been indicated for the treatment of Philadelphia chromosome positive (Ph+) chronic myelogenous leukemia (CML), GISTs, and Ph+ acute lymphoblastic leukemia (ALL) [11,18]. Tyrosine kinase inhibitors interrupt the normal cellular signaling processes involved in growth and maintenance of the cell by blocking ATP-binding sites on TKs.

Imatinib specifically targets the TKs often found in CML (*BCR-ABL*) and GIST (*c-KIT*, platelet-derived growth factor receptor- α) cells [18]. A long-term study of CML patients receiving imatinib found complete cytogenetic response in 87% of patients and an overall survival rate of 89% at 5 years [19]. In GIST, a median overall survival of 57 months has been reported in patients receiving imatinib [20].

Multiple studies have reported SDHs as adverse events in patients receiving imatinib. Daniels *et al.* [11] conducted a clinical trial with 119 patients with idiopathic pulmonary fibrosis using imatinib for its blocking action on PDGFR, which would inhibit proliferation of fibroblasts, theoretically the cause of idiopathic pulmonary fibrosis [11]. The researchers in this investigation noted two patients with nontraumatic SDHs but did not discuss whether intervention was indicated or conducted [11]. Hoepfer *et al.* [12] also investigated imatinib as a treatment for pulmonary arterial hypertension through a randomized placebo-controlled trial with 202 patients. They observed SDHs in eight of their patients who were anticoagulated, but as with the previous study, no interventions were discussed [12].

Song *et al.* [5] carried out a retrospective analysis of CML patients who were treated with imatinib and found that seven of 121 patients suffered an SDH, four of whom required surgical intervention. None of the patients with SDHs were anticoagulated or thrombocytopenic, and the authors point to an unknown mechanism separate from the currently accepted theory that thrombocytopenia from imatinib leads to SDH.

Table 1 Chemotherapy agents noted with intracranial hemorrhage events

References	Chemotherapeutic	Type	Indication	Total patients	ICH patients	Type	Surgical treatment	Non-surgical treatment	Suspected cause of SDH	Notes
Takahashi et al. [8]	Bevacizumab	Case report	Colon cancer	1	1	SDH	Burr hole, endoscopy-assisted reoperation	NS	NS	SDH size related to bevacizumab administration
Wong et al. [9]	Bevacizumab (1) Sunitinib (1)	Case report	Metastatic breast cancer (2)	2	2	SDH	Burr hole, craniectomy, subdural drain (1)	WBRT (metastases; 1)	Rebound angiogenic state after stopping agent (2)	SDH occurred after stopping sunitinib and bevacizumab
Egion et al. [10]	Dasatinib, sorafenib, imatinib, erlotinib, sunitinib, dasatinib, lapatinib, nilotinib, everolimus	Retrospective analysis	Multiple (AML in SDH case)	271	1 (Dasatinib)	SDH	None	NS	Thrombocytopenia with no dose adjustment	
Daniels et al. [11]	Imatinib	Clinical trial	Idiopathic pulmonary fibrosis	119 (59 in treatment arm)	2	SDH	NS	NS	NS	
Hooper et al. [12]	Imatinib	Clinical trial	Pulmonary arterial hypertension	202 (103 treatment arm), 144 in extension	2/103, 6/144	SDH	NS	NS	Study reports unknown	All patients on anticoagulation
Kim et al. [13]	Imatinib	Case report	CML	1	1	SDH	None	Imatinib discontinued x 2 days then dose lowered	Decreased plasmin inhibitor, platelet dysfunction	Patient non-thrombocytopenic, no coagulopathy
Patel et al. [14]	Imatinib	Case report	Ph+ ALL	3	3	SDH	None (1), Burr hole (2)	Corticosteroid, AEDs, platelet transfusion (2)	Platelet dysfunction	10 patients receiving regimen, 0/22 patients with Ph-ALL/no imatinib had SDH
Song et al. [5]	Imatinib	Retrospective analysis	CML	123	7	SDH	Evacuation (4)	NS	Unknown	2/3 SDH patients died; these patients were taking antiplatelet agents
Aichberger et al. [15]	Nilotinib	Retrospective analysis	Imatinib-resistant CML	24	1	SDH	NS	Discontinuation of nilotinib (1)	Thrombocytopenia	
Feki et al. [7]	Imatinib	Case report	GIST	1	1	SDH	Evacuation (1)	NS	Imatinib	
Mustafa Ali et al. [16]	Dasatinib	Case report	Ph+ ALL	1	1	SDH	Burr holes, subdural drain	Mannitol, switched to nilotinib	Possible platelet dysfunction	
Ichihara et al. [17]	Gefitinib + bevacizumab	Clinical trial	NSCLC	42	1	NS	NS	Discontinuation of treatment	NS	

AED, antiepileptic drug; ALL, acute lymphoblastic leukemia; CML, chronic myelogenous leukemia; GIST, gastrointestinal stromal tumor; ICH, intracranial hemorrhage; NS, not specified; NSCLC, non-small-cell lung cancer; Ph, Philadelphia chromosome; RCT, randomized controlled trial; SDH, subdural hematoma; WBRT, whole-brain radiation therapy.

Kim *et al.* [13] reported a case of CML treated with imatinib, in which the patient subsequently developed SDH without thrombocytopenia or coagulopathy. The authors suggest a possible platelet aggregation abnormality as a cause [13]. In addition, Patel *et al.* [14] reported on three patients with imatinib-treated Ph+ ALL, all of whom experienced an SDH. These patients were all thrombocytopenic, had been receiving additional agents, and had undergone multiple lumbar punctures for intrathecal chemotherapy. However, as with the previous case report, the authors note that platelet dysfunction may still be involved. On the basis of the three multipatient studies using imatinib (Song *et al.* [5], Daniels *et al.* [11], and Hoepfer *et al.* [12]), the reported rate of intracranial hemorrhage with imatinib may be between 1.9% (two of 103 in the study by Hoepfer *et al.* [12]) and 5.7% (seven of 121 in the study by Song *et al.* [5]).

Dasatinib and other protein-kinase inhibitors

Dasatinib (Sprycel; Bristol-Myers Squibb, New York, New York, USA) is a TK inhibitor that is used for imatinib-resistant CML. Gratacap *et al.* [21] treated human platelets with dasatinib and then activated them with thrombin, adenosine diphosphate, or collagen and found that platelet aggregation was inhibited at low concentrations of thrombin and collagen, but adenosine diphosphate-induced aggregation was not significantly affected. Disruption of the platelet immunoreceptor tyrosine-based activation motif was noted as a possible mechanism by the authors and therefore could be associated with the cause of SDH [21].

Mustafa Ali and colleagues reported a case of a spontaneous SDH that occurred in a 29-year-old woman with Ph+ ALL who was treated with dasatinib. With no history of trauma, anticoagulation, or metastasis to the brain, the authors discussed the possibility of platelet dysfunction being the cause for the SDH [16].

Other protein-kinase inhibitors include chemotherapeutics such as nilotinib, sunitinib, and erlotinib [10]. Aichberger *et al.* [15] assessed the incidence of occlusive peripheral arterial disease in 24 patients receiving nilotinib for CML and observed one case of SDH. This patient was found to be thrombocytopenic, and further nilotinib was withheld [15]. Egron *et al.* [10] retrospectively analyzed all serious adverse events with the protein kinase inhibitors imatinib, sorafenib, erlotinib, sunitinib, dasatinib, lapatinib, nilotinib, and everolimus over a 2-year period and found one event of subdural hematoma (in a sample of 271 patients) in a patient receiving off-label treatment with dasatinib for acute myeloid leukemia.

Bevacizumab

Bevacizumab is a monoclonal antibody used in the treatment of certain cancer types because of its action on vascular endothelial growth factor [8]. Several links

between bevacizumab and central nervous system hemorrhage have been reported. Takahashi *et al.* [8] reported a case of a 78-year-old patient with colon cancer who was treated with an undescribed chemotherapeutic and bevacizumab and was found to have a chronic SDH on a follow-up PET scan. The patient underwent burr-hole drainage initially, but after the hematoma failed to drain, it was evacuated. There was no discussion on the causal mechanism [8]. Wong *et al.* [9] reported on two patients with metastatic breast cancer to the brain, one treated with bevacizumab and the other with sunitinib (a TK inhibitor that targets the vascular endothelial growth factor receptor). In both cases, the SDHs did not occur during therapy but after the discontinuation of therapy. The authors postulated that cessation of the anti-angiogenic chemotherapy led to a compensatory pro-angiogenic state that resulted in leakage from the capillaries and subsequent subdural collection [9].

Intracranial hemorrhage has also occurred with bevacizumab in combination with gefitinib, an epidermal growth factor receptor inhibitor. Ichihara *et al.* [17] reported that one of 42 patients receiving a regimen of bevacizumab and gefitinib for non-small-cell lung cancer developed an unspecified intracranial hemorrhage. Other than discontinuation of treatment, no other intervention was specified, and the cause was not discussed. As this time, the causal relationship between bevacizumab and intracranial hemorrhage has yet to be substantiated. However, clinicians should exercise caution when continuing bevacizumab in the presence of intracranial hemorrhage, just as initiation of bevacizumab is delayed after tumor resection because of the potentially increased risk for hemorrhage [22,23].

Conclusion

Multiple reports have identified isolated spontaneous SDHs and intracranial hemorrhages occurring after the use of newer targeted chemotherapeutic agents, particularly TKIs and imatinib. On the basis of multipatient studies in the existing literature, the rate of imatinib-related intracranial hemorrhage in the absence of other obvious causes may be between 1.9 and 5.7% [5,11,12]. Such bleeding has been observed to occur with its use under different disease settings, and the incidence of intracranial hemorrhage with its use may still be underreported. If these agents are the cause for SDH, as suspected, discontinuation of the chemotherapeutic is the reported course of action in the literature, with referral and evaluation by a neurosurgeon [13,15,17]. Our case highlights the importance of being vigilant for symptoms and signs of SDHs and intracranial hemorrhages when using these drugs. Because of the rapid introduction of these agents into the market, unfamiliarity may pose a significant challenge, and an oncologist and neurosurgeon should be consulted before restarting chemotherapy after a hemorrhage.

Acknowledgements

Conflicts of interest

There are no conflicts of interest.

References

- Chabner BA, Roberts TG Jr. Timeline: chemotherapy and the war on cancer. *Nat Rev Cancer* 2005; **5**:65–72.
- Freireich EJ, Schmidt PJ, Schneiderman MA, Frei E 3rd. A comparative study of the effect of transfusion of fresh and preserved whole blood on bleeding in patients with acute leukemia. *N Engl J Med* 1959; **260**:6–11.
- Lieschke GJ, Burgess AW. Granulocyte colony-stimulating factor and granulocyte-macrophage colony-stimulating factor (1). *N Engl J Med* 1992; **327**:28–35.
- Lieschke GJ, Burgess AW. Granulocyte colony-stimulating factor and granulocyte-macrophage colony-stimulating factor (2). *N Engl J Med* 1992; **327**:99–106.
- Song KW, Rifkind J, Al-Beirouti B, Yee K, McCrae J, Messner HA, *et al.* Subdural hematomas during CML therapy with imatinib mesylate. *Leuk Lymphoma* 2004; **45**:1633–1636.
- Demetri GD, von Mehren M, Blanke CD, Van den Abbeele AD, Eisenberg B, Roberts PJ, *et al.* Efficacy and safety of imatinib mesylate in advanced gastrointestinal stromal tumors. *N Engl J Med* 2002; **347**:472–480.
- Feki J, Marrekchi G, Boudawara T, Rezik N, Maatouq S, Boudawara Z, *et al.* Subdural hematoma during therapy of gastro-intestinal stromal tumor (GIST) with imatinib mesylate. *Gulf J Oncolog* 2015; **1**:92–95.
- Takahashi S, Yazaki T, Nitori N, Kano T, Yoshida K, Kawase T. Neuroendoscope-assisted removal of an organized chronic subdural hematoma in a patient on bevacizumab therapy – case report. *Neurol Med Chir (Tokyo)* 2011; **51**:515–518.
- Wong AL, Chou N, Lee KM, Ang BW, Cheng CL, Lee SC. Subdural collections arising from calvarial metastases following discontinuation of anti-angiogenic therapy. *Ann Oncol* 2009; **20**:1605–1606.
- Egron A, Olivier-Abbal P, Gouraud A, Babai S, Combret S, Montastruc JL, *et al.* Preventable and potentially preventable serious adverse reactions induced by oral protein kinase inhibitors through a database of adverse drug reaction reports. *Target Oncol* 2014; **10**:229–234.
- Daniels CE, Lasky JA, Limper AH, Mieras K, Gabor E, Schroeder DR. Imatinib treatment for idiopathic pulmonary fibrosis: Randomized placebo-controlled trial results. *Am J Respir Crit Care Med* 2010; **181**:604–610.
- Hoepfer MM, Barst RJ, Bourge RC, Feldman J, Frost AE, Galie N, *et al.* Imatinib mesylate as add-on therapy for pulmonary arterial hypertension: results of the randomized IMPRES study. *Circulation* 2013; **127**:1128–1138.
- Kim MS, Lee DH, Lee YR, Kim DK, Bae SH, Hwang JY, *et al.* A case of subdural hematoma in patient with chronic myeloid leukemia treated with high-dose imatinib mesylate. *Korean J Hematol* 2010; **45**:73–75.
- Patel SB, Gojo I, Tidwell ML, Sausville EA, Baer MR. Subdural hematomas in patients with Philadelphia chromosome-positive acute lymphoblastic leukemia receiving imatinib mesylate in conjunction with systemic and intrathecal chemotherapy. *Leuk Lymphoma* 2011; **52**:1211–1214.
- Aichberger KJ, Herndlhofer S, Scherthaner GH, Schillinger M, Mitterbauer-Hohendanner G, Sillaber C, *et al.* Progressive peripheral arterial occlusive disease and other vascular events during nilotinib therapy in CML. *Am J Hematol* 2011; **86**:533–539.
- Mustafa Ali MK, Sabha MM, Al-Rabi KH. Spontaneous subdural hematoma in a patient with Philadelphia chromosome-positive acute lymphoblastic leukemia with normal platelet count after dasatinib treatment. *Platelets* 2014. 1–4.
- Ichihara E, Hotta K, Nogami N, Kuyama S, Kishino D, Fujii M, *et al.* Phase II trial of gefitinib in combination with bevacizumab as first-line therapy for advanced non-small cell lung cancer with activating EGFR gene mutations: the Okayama Lung Cancer Study Group Trial 1001. *J Thorac Oncol* 2015; **10**:486–491.
- Iqbal N. Imatinib: a breakthrough of targeted therapy in cancer. *Chemother Res Pract* 2014; **2014**:357027.
- Druker BJ, Guilhot F, O'Brien SG, Gathmann I, Kantarjian H, Gattermann N, *et al.* Five-year follow-up of patients receiving imatinib for chronic myeloid leukemia. *N Engl J Med* 2006; **355**:2408–2417.
- Blanke CD, Demetri GD, von Mehren M, Heinrich MC, Eisenberg B, Fletcher JA, *et al.* Long-term results from a randomized phase II trial of standard- versus higher-dose imatinib mesylate for patients with unresectable or metastatic gastrointestinal stromal tumors expressing KIT. *J Clin Oncol* 2008; **26**:620–625.
- Gratacap MP, Martin V, Valera MC, Allart S, Garcia C, Sie P, *et al.* The new tyrosine-kinase inhibitor and anticancer drug dasatinib reversibly affects platelet activation in vitro and in vivo. *Blood* 2009; **114**:1884–1892.
- Lai A, Tran A, Nghiemphu PL, Pope WB, Solis OE, Selch M, *et al.* Phase II study of bevacizumab plus temozolomide during and after radiation therapy for patients with newly diagnosed glioblastoma multiforme. *J Clin Oncol* 2011; **29**:142–148.
- Abrams DA, Hanson JA, Brown JM, Hsu FP, Delashaw JB Jr., Bota DA. Timing of surgery and bevacizumab therapy in neurosurgical patients with recurrent high grade glioma. *J Clin Neurosci* 2015; **22**:35–39.