

Manoel J. Teixeira, MD,
PhD
Rubens Gisbert Cury,
MD, PhD
Ricardo Galhardoni, PhD
Victor Rossetto Barboza,
MD
André R. Brunoni, MD,
PhD
Eduardo Alho, MD, PhD
Guilherme Lepski, MD,
PhD
Daniel Ciampi de
Andrade, MD, PhD

DEEP BRAIN STIMULATION OF THE DENTATE NUCLEUS IMPROVES CEREBELLAR ATAXIA AFTER CEREBELLAR STROKE



The cerebrotocerebellum receives input from the cerebral cortex and projects to the motor and premotor cortices and the ventrolateral nucleus of the thalamus via the dentate nucleus (DN). Dentothalamocortical projections modulate the activity of the contralateral primary motor (M1) cortex and are involved in movement planning. Acute ischemic injury of the cerebellar nuclei leads to ataxia and a loss of physiologic excitatory inputs from the DN to the contralateral M1 cortex.¹ However, chronic cerebellar ischemic lesions have been associated with a reemerging decrease in intracortical inhibition (ICI) in the contralesional M1, leading to marked interhemispheric asymmetry in cortical excitability, which could account for the functional impairment observed after strokes.²

We report a case of unilateral cerebellar infarction leading to dystonia and ataxia treated by deep brain stimulation to the healthy DN (DN-DBS). Our rationale was to stimulate the healthy DN in order to balance the functional asymmetry observed between both M1 after chronic cerebellar strokes.²

This single observational study without controls provides Class IV evidence.

Case report. A 50-year-old right-handed woman underwent a resection of a right acoustic neuroma in 2006, which was complicated by an ischemic injury of the right cerebellar hemisphere (figure e-1 on the *Neurology*[®] Web site at Neurology.org). She developed severe ataxia, mostly right-sided, that significantly impaired her daily activities and mild bilateral hand and cervical dystonia. Her cerebellar tremor was treated with physical therapy, benzodiazepines, β -blockers, and primidone, but no satisfactory improvement was observed. Considering the refractoriness of her symptoms, we conducted a trial of 1 Hz, neuronavigated, repetitive, low-frequency transcranial magnetic stimulation (rTMS) on the left DN, with both patient and evaluator blinded to the treatment. Two (active or sham) stimulation sessions were randomly performed 4 weeks apart. The active stimulation resulted in significant improvement in ataxia that persisted for

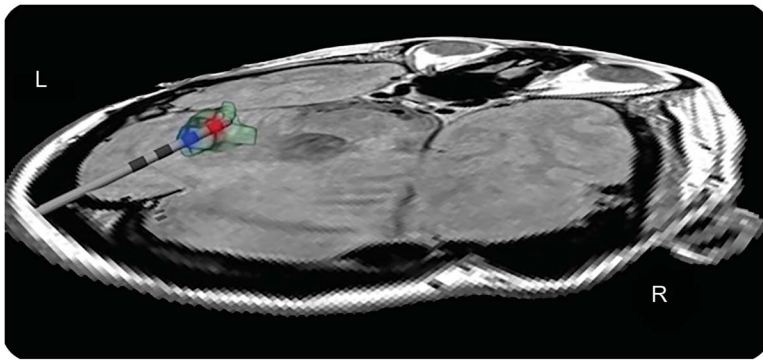
several days.³ Based on her good response to rTMS, the patient underwent DBS of her (healthy) left DN. The potential risks and benefits of TMS and DBS were addressed, and we obtained informed consent from the patient prior to both procedures. A blinded movement disorder specialist (with no further role in the study) performed the clinical assessment and videorecording using validated tools on 3 occasions: before surgery and after 1 year in the on- and off-DBS conditions. The left DN was stimulated (Medtronic, Minneapolis, MN, USA) in a bipolar setting (1.4 mA, 2.8 V, 60 μ s pulse width at 20 Hz, and 2031 Ω) (figure 1). We observed an improvement in tremor (Fahn, Tolosa, Marin Tremor Rating Scale from 38/144 to 24/144; a 37% reduction) and cerebellar ataxia (Scale for the Assessment and Rating of Ataxia [SARA] from 25.5/40 to 17/40) in the on-stimulation condition (video). The Patient Global Impression of Change (ranging from 1 [severe aggravations of symptoms] to 7 [major improvement of symptoms]) was 6 after the active session (moderately improved). There were no changes in dystonia after active treatment. The off-stimulation condition revealed no clinical improvement in specific scales (table e-1). As previously described,² ICI was decreased in the contralesional M1 (left) in the off-stimulation condition. In the on-stimulation condition, ICI was increased by a factor of 3.7 in the contralesional M1 (left hemisphere), while in the ipsilesional M1 (right hemisphere) intracortical facilitation was increased, restoring the asymmetry.

Discussion. It is known that TMS stimulation of the cerebellum performed before a TMS pulse is administered to the contralateral M1 leads to decreased MEP amplitudes,⁴ which are related to the sudden loss of facilitatory output from the DN to the contralateral M1. As a result, we hypothesized that DN-TMS³ (and DBS) could restore the altered cortical excitability asymmetry seen between both M1 after a chronic cerebellar stroke (figure e-2).

Reports of stimulation of thalamic nuclei for ataxia control have yielded inconsistent results.⁴ Recent studies^{5,6} suggest that DBS preferably acts through an activation of fiber tracts afferent to targeted nuclei as the dentate-rubro-thalamic tracts (DRTT). In this way, the stimulation of DN could modulate the

Supplemental data
at Neurology.org

Figure 1 Brain MRI



Three-dimensional reconstruction of the deep brain stimulation electrode in the left dentate nucleus (green). Note that in the 3D reconstruction, a posterior perspective of the head is presented. Under this view, the left dentate nucleus appears in the left side of the picture.

DRTT at their original point, leading to improvements in tremors and ataxia.

This study describes a novel target to DBS that aims to control ataxia and tremor. We showed that DN-DBS leads to increased contralateral cortical facilitation and substantial restoration of decreased ICI in the ipsilateral (contralesional, nonstimulated) M1, probably reflecting the interhemispheric inhibition. The use of TMS can be a valuable tool for predicting the surgical response, which should be further explored in future studies. Our study protocol was safe and well-tolerated; it lays the groundwork for larger studies using repetitive sessions of deep rTMS and DBS in this patient population.

From the University of São Paulo (M.J.T., R.G.C., R.G., V.R.B., A.R.B., E.A., G.L., D.C.d.A.); Instituto do Câncer do Estado de São Paulo Octavio Frias de Oliveira (R.G.C., D.C.d.A.), São Paulo, Brazil; and University of Tübingen (G.L.), Germany.

Author contributions: Manoel Jacobsen Teixeira: drafting/ revising the manuscript, study concept or design, analysis or interpretation of data, accepts responsibility for conduct of research and final approval, acquisition of data, study supervision. Rubens Gisbert Cury: drafting/ revising the manuscript, study concept or design,

accepts responsibility for conduct of research and final approval, acquisition of data, study supervision. Ricardo Galhardoni: drafting/ revising the manuscript, analysis or interpretation of data, accepts responsibility for conduct of research and final approval. Victor R. Barboza: analysis or interpretation of data, accepts responsibility for conduct of research and final approval, acquisition of data. André R. Brunoni: drafting/ revising the manuscript, accepts responsibility for conduct of research and final approval. Eduardo Alho: drafting/ revising the manuscript, analysis or interpretation of data, accepts responsibility for conduct of research and final approval. Guilherme Lepski: drafting/ revising the manuscript, study concept or design, analysis or interpretation of data, accepts responsibility for conduct of research and final approval, acquisition of data, participation in the surgical procedure. Daniel Ciampi de Andrade: drafting/ revising the manuscript, study concept or design, analysis or interpretation of data, accepts responsibility for conduct of research and final approval, study supervision.

Study funding: No targeted funding reported.

Disclosure: The authors report no disclosures relevant to the manuscript. Go to Neurology.org for full disclosures.

Received March 27, 2015. Accepted in final form August 4, 2015.

Correspondence to Dr. Ciampi de Andrade: ciampi@usp.br

© 2015 American Academy of Neurology

1. Holdefer RN, Miller LE, Chen LL, Houk JC. Functional connectivity between cerebellum and primary motor cortex in the awake monkey. *J Neurophysiol* 2000;84:585–590.
2. Farias da Guarda SN, Cohen LG, da Cunha Pinho M, et al. Interhemispheric asymmetry of corticomotor excitability after chronic cerebellar infarcts. *Cerebellum* 2010;9:398–404.
3. Cury RG, Teixeira MJ, Galhardoni R, et al. Neuronavigation-guided transcranial magnetic stimulation of the dentate nucleus improves cerebellar ataxia: a sham-controlled, double-blind n = 1 study. *Parkinsonism Relat Disord* 2015;21:999–1001.
4. Oyama G, Thompson A, Foote KD, et al. Deep brain stimulation for tremor associated with underlying ataxia syndromes: a case series and discussion of issues. *Tremor Hyperkinetic Mov* 2014;4:228.
5. Schlaier J, Anthofer J, Steib K, et al. Deep brain stimulation for essential tremor: targeting the dentato-rubro-thalamic tract? *Neuromodulation* 2015;18:105–112.
6. Coenen VA, Allert N, Mädler B. A role of diffusion tensor imaging fiber tracking in deep brain stimulation surgery: DBS of the dentato-rubro-thalamic tract (drt) for the treatment of therapy-refractory tremor. *Acta Neurochir* 2011; 153:1579–1585.

Chloé Laurencin, MD
Nathalie André-Obadia,
MD

Jean-Philippe
Camdessanché, MD,
PhD

François Mauguière, MD,
PhD

Elodie Ong, MD

PERIPHERAL SMALL FIBER DYSFUNCTION AND NEUROPATHIC PAIN IN PATIENTS WITH MORVAN SYNDROME

Morvan syndrome (MoS) is an autoimmune-mediated syndrome that is frequently associated with malignant thymoma and autoantibodies targeting contactin associated protein-like 2 (CASPR2-Abs). Neuropathic pain is a frequent clinical feature in MoS—encountered in 62% of patients¹—but the pain mechanisms are unknown. We studied 4 patients with MoS who had neuropathic pain and investigated whether this pain could be due to a selective involvement of small nerve fibers. Written consent was obtained from all patients, and the study was

approved by the institutional review board of the University Claude Bernard Lyon 1.

Results. All of the patients (table, and appendix e-1 on the *Neurology*[®] Web site at Neurology.org) had a history of malignant thymoma, and 3 also presented with myasthenia gravis. They underwent thymoma chemotherapy 1, 2, and 10 years before the development of neuromyotonia symptoms and MoS. All of them had severe insomnia, hyperhidrosis, and diffuse fasciculations, leading to the diagnosis of MoS. There was no areflexia. Patient 3 had symmetrical pain localized to only the feet, but patients 1, 2, and 4 had severe symmetrical

Neurology[®]

Deep brain stimulation of the dentate nucleus improves cerebellar ataxia after cerebellar stroke

Manoel J. Teixeira, Rubens Gisbert Cury, Ricardo Galhardoni, et al.

Neurology 2015;85;2075-2076

DOI 10.1212/WNL.0000000000002204

This information is current as of December 7, 2015

Updated Information & Services	including high resolution figures, can be found at: http://www.neurology.org/content/85/23/2075.full.html
Supplementary Material	Supplementary material can be found at: http://www.neurology.org/content/suppl/2015/12/05/WNL.0000000000002204.DC1.html http://www.neurology.org/content/suppl/2015/12/05/WNL.0000000000002204.DC2.html
References	This article cites 6 articles, 1 of which you can access for free at: http://www.neurology.org/content/85/23/2075.full.html##ref-list-1
Permissions & Licensing	Information about reproducing this article in parts (figures, tables) or in its entirety can be found online at: http://www.neurology.org/misc/about.xhtml#permissions
Reprints	Information about ordering reprints can be found online: http://www.neurology.org/misc/addir.xhtml#reprintsus

Neurology® is the official journal of the American Academy of Neurology. Published continuously since 1951, it is now a weekly with 48 issues per year. Copyright © 2015 American Academy of Neurology. All rights reserved. Print ISSN: 0028-3878. Online ISSN: 1526-632X.

