




Official Journal of the European Paediatric Neurology Society



## Case Study

# Infantile spasms and 15q11.2q13.1 chromosome duplication in two successive generations<sup>☆</sup>



Raili Sylvia Riikonen<sup>a,\*</sup>, Tiina Wallden<sup>b</sup>, Hannaleena Kokkonen<sup>c</sup>

<sup>a</sup> Children's Hospital and Science Service Center, University of Eastern Finland, Kuopio, Finland

<sup>b</sup> Central Hospital of Kymenlaakso, Kotka, Finland

<sup>c</sup> Northern Finland Laboratory Centre NordLab and Medical Research Centre, Oulu University Hospital and University of Oulu, Oulu, Finland

## ARTICLE INFO

## Article history:

Received 16 April 2015

Received in revised form

13 August 2015

Accepted 2 November 2015

## Keywords:

Infantile spasms in successive generations

15q11q13 chromosome duplication

## ABSTRACT

Familial cases of West syndrome have been reported only in Japan. In that study no chromosomal analyses were made. It has been suggested that microarray analysis should be included in the diagnostic evaluation of patients with infantile spasms and developmental delay, when an evaluation for structural brain lesions and metabolic disorders reveal no abnormal findings.

We report here the first case of infantile spasms and 15q11.2q13.1 chromosome duplication in two successive generations. The daughter and mother with infantile spasms, and the autistic son had the duplication. The clinical course of infantile spasms was very similar in the mother and daughter. The spasms were primarily considered to be of unknown aetiology.

Chromosomal microarray analysis revealed a 6.2 Mb size 15q11.2q13.1 duplication.

The duplication belongs to the 15q11q13 duplication syndrome (OMIM 608636) which when maternally derived is characterised by neuro-behavioural disorders like autism, hypotonia, cognitive deficit, language delay and epilepsy.

The proportion of patients with unknown aetiology for infantile spasms will decrease when more careful chromosomal studies are made. Our report expands the phenotype of chromosome 15q duplication syndrome and is the first report of this abnormality in two successive generations of infantile spasms.

© 2015 European Paediatric Neurology Society. Published by Elsevier Ltd. All rights reserved.

<sup>☆</sup> This work described is consistent with the Journal's guidelines for ethical publication.

\* Corresponding author. Tel.: +358 505174696; fax: +358 19 668418.

E-mail addresses: [raili.riikonen@kolumbus.fi](mailto:raili.riikonen@kolumbus.fi) (R.S. Riikonen), [Tiina.Wallden@careaf.fi](mailto:Tiina.Wallden@careaf.fi) (T. Wallden), [Hannaleena.Kokkonen@nordlab.fi](mailto:Hannaleena.Kokkonen@nordlab.fi) (H. Kokkonen).

<http://dx.doi.org/10.1016/j.ejpn.2015.11.005>

1090-3798/© 2015 European Paediatric Neurology Society. Published by Elsevier Ltd. All rights reserved.

## 1. Introduction

The development of genetic technologies has led to the identification of many copy number variations (CNVs) in the human genome. The number of genes and genetic regions associated with infantile spasms are rapidly increasing (ARX, CDKL5, FOXP, GRIN1, GRIN 2A, MAGI, MEF2C, SLC25A22, SPTANI, STXBP1 and 15q11q13).<sup>1</sup> Tuberous sclerosis is the most common genetic disease in infantile spasms. The phenotypic expression of 15q11-13 duplication has expanded recently.<sup>2</sup>

We report here a family in which members of two successive generations - a mother and daughter-had infantile spasms and were found to have a chromosomal duplication in the long arm of chromosome 15 as well as high-lighting the importance of chromosomal analysis in cases of infantile spasms with no identified aetiology. Our cases suggest that the phenotypic spectrum of 15q11q13 duplication syndrome may be wider than previously considered and may include infantile spasms.

## 2. Case study

We report here a family with infantile spasms and 15q11.2q13.1 chromosome duplication in two successive generations. There was no previous family history of mental retardation, epilepsy or psychiatric problems like schizophrenia. There is no consanguinity in the family.

### 2.1. Proband

The girl was born at 40 + 5 weeks' gestation after a normal pregnancy and delivery. The birth weight was 3882 g, height 53 cm and head circumference 35 cm. The Apgar scored 8 at 5 min. The child was the second birth of the 30 years old mother. The father was 35 years old. The mother had taken valproate (1500 mg/day and folic acid substitution) for her epilepsy during pregnancy. Early development was normal except of slight delay in early motor milestones.

At the age of 8 months she was referred to the paediatric neurology clinic of Central Hospital of Kymenlaakso, Finland, for repetitive movements. The diagnosis of infantile spasms was promptly made at the admission. EEG showed typical hypsarrhythmic pattern. At the time of referral, she had flexor spasms and was slightly hypotonic. The head circumference, height, and weight were at 50 percentile. A physical examination was rather unspecific.

Careful aetiological investigations were made: MRI of the brain, determination of urine organic acids, blood glucose, lactate, thyroid function, cytomegalic and toxoplasma antibodies, analysis of cerebrospinal fluid including leucocytes, protein and glucose, and karyotype testing. All the results were normal. Tuberous sclerosis was first suspected because she had three hypomelanotic macules in the lumbar region. The kidney and heart ultrasound were also normal. Fundi of the eyes did not show any hamartomas, signs of congenital

infections, or features of metabolic disease. Diagnosis of infantile spasms of unknown aetiology was made.<sup>3</sup>

Vigabatrin (up to 150 mg/kg/d) was started and given for five weeks without any response but ACTH (synthetic derivative) 0.5 mg had a rapid response. ACTH was given for 10 days and thereafter prednisolone 30 mg/d/5 days, 20 mg/5 days, 10 mg 5 days with a total dose of 300 mg. After that she started valproate medication.

At last visit at age of 17 months she maintained good eye contact. She had developmental delay. She was interested in toys and immediately put them in her mouth. She did not yet demonstrate any pincer grip. She did crawl and stood up with support. Muscle tone was low. The facial features of the baby and her mother were normal.

### 2.2. Mother

The mother was born after 41 + 6 weeks' gestation. Birth weight was 3260 g, height 50 cm, head circumference 34 cm. She scored 9 Apgar at 5 min. Early development was normal.

She had infantile spasms at the age of 9 months and typical hypsarrhythmia. She had a normal MRI. The etiological studies included careful clinical studies including eye fundi examinations, and laboratory studies: blood cell counts, vacuolated lymphocytes, urine metabolic screening. The CSF was studied for cell counts, glucose, protein, and immunoglobulin G (IgG) index. All were normal and she was thought to have infantile spasms of unknown aetiology. The response to ACTH was immediate.

Other than infantile spasms she was otherwise healthy and had no seizures until the age of 19 years when she developed partial and generalized seizures. Carbamazepine was started but it was not effective but valproate was effective. She used valproate during the both pregnancies.

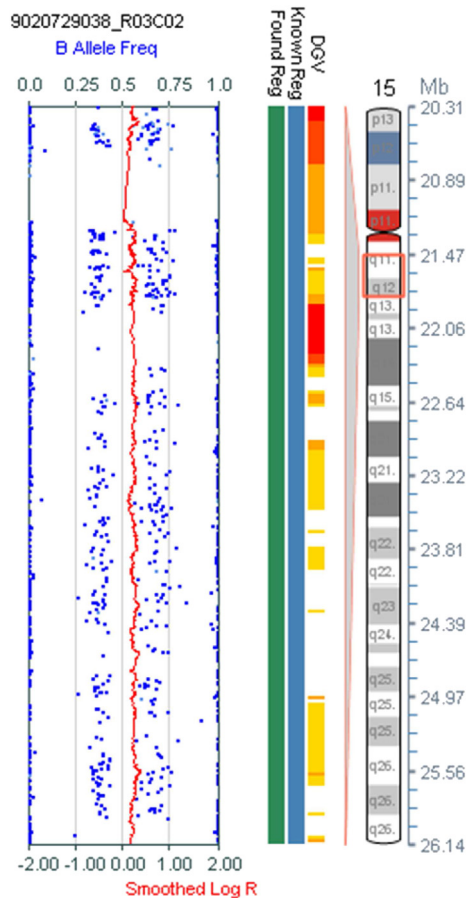
In school she had learning difficulties and was given a special education.

The clinical course of the girl and mother with infantile spasms were very similar.

### 2.3. The older male sibling of the proband

During pregnancy mother had taken valproate 900 mg/day. He was born at 40 + 1weeks' gestation with normal delivery. The birth weight was 3830 g, height 52 cm and head circumference 34 cm. He scored 9 Apgar at 5 min. He was referred to the paediatric neurology clinic of Central Hospital of Kymenlaakso because of developmental delay at the age of two years. He had some facial features which might be interpreted for valproate toxicity in *utero*: epicanthic folds and a low-lying nasal bridge. He started walk at the age of 20 months. He used some words at the age of two years. Now at age of five years he has a diagnosis of autism and learning disabilities.

Microarray analysis using HumanCytoSNP-12(v2.1)chip (Illumina) revealed the 6.2 Mb size 15q11.2q13.1 duplication in Prader–Willi/Angelman syndrome region, (arr 15q11.2q13.1(22,754,322–28,941,318)×3, Hg19) (Fig. 1) in the daughter, mother and autistic brother. The father did not have any chromosomal abnormality.



**Fig. 1 – A 6.2 Mb duplication at 15q11.2q13.1 (Chr15:22754322–28941318, hg19) found in the proband (daughter) of this family. The same duplication was also found in the mother and autistic brother.**

### 3. Discussion

We have demonstrated that patients with infantile spasms can have children with infantile spasms. We highlight the importance of chromosomal analysis in etiological evaluation of patients with unexplained infantile spasms. This will widen the phenotypic spectrum of 15q11q13 syndrome.

Familial cases account 4–5% of infantile spasms.<sup>4,5</sup> Affected family members with West syndrome in two generations are extremely rare. In Japan a mother and the child or children were involved in three families.<sup>6</sup> The cases were considered to have non-identified aetiology but no chromosomal testing was performed. Age of onset, seizure types, EEG abnormalities, early and long-term seizure prognosis were similar among the affected members in each family. Long-term seizure and developmental prognoses were far better than in infantile spasms in general. As far as we know this is the only report of this kind.

The clinical presentation of the present case consists of infantile spasms and mild developmental delay that might not be specific enough to suspect a chromosomal aberration syndrome. The chromosomal analysis played a crucial role in the genetic diagnosis of the case. The mother and the

daughter had very similar clinical symptoms. The child was, however, slightly delayed in her development which might be due to variable disease severity or detrimental effect on neurodevelopment caused by valproate during pregnancy.

The clinical findings associated with chromosome 15q11q13 duplication syndrome (OMIM 608636) manifest through a heterogeneous group of symptoms characterised by hypotonia, delay in motor skills and language development, cognitive and learning disabilities, autistic spectrum disorder,<sup>7</sup> generalised epilepsy,<sup>8</sup> and refractory epilepsy.<sup>9</sup> Not only autistic spectrum disorders, but also low normal intelligence and dyspraxia were seen in a large family with 12 carriers in three generations.<sup>2</sup> In that study the size of the duplicated area was around 6 Mb with breakpoints similar to our study.

Bingham et al. 1996<sup>10</sup> have reported a case of infantile spasms with proximal duplication of 15q. The mother had no epilepsy and no chromosomal study was performed. Tiwari et al. 2013<sup>11</sup> have reported a 4.8 Mb de novo duplication in the 15q11–13 region in one patient with refractory infantile spasms. The mutation was not present in the parents. Consequently, our patient seems to be first case reported with this mutation in two successive generations of infantile spasms.

Paternally inherited chromosome 15 duplication has little significance, in contrast of maternal duplication which is associated with clinical problems.<sup>2</sup>

The mechanisms by which micro-duplications mediate their pathogenic effects remain unknown.

The 15q11–q13 region contains a cluster of imprinted genes of which at least UBE3A is expressed only from the maternal allele in the brain. Through the regulation of the synaptic protein activity-regulated cytoskeleton-associated protein (Arc), which promotes the internalisation of AMPA receptors at excitatory synapses, UBE3A is linked to the regulation of glutamatergic signalling and synaptic development.<sup>12</sup> Overexpression of UBE3A is most probably a major contributing factor to the neurodevelopmental and neuropsychiatric phenotypes in 15q11–q13 duplication as shown by Noor et al. 2015.<sup>13</sup> In cases with 15q11–q13 triplications due to a supernumerary isodicentric chromosome 15 the frequency of seizures is increased noticeable<sup>14</sup> supporting dosage effect of 15q11–q13 region. Candidate to dosage sensitive genes and seizures are GABA receptor genes (GABRB3, GABRA5, GABRG3), which encode receptors that respond to the neurotransmitter gamma-aminobutyric acid (GABA), the major inhibitory neurotransmitter in mammalian brain and which are known to be associated with epilepsy as de novo mutations in GABRB3 is found in patients with epileptic encephalopathies.<sup>15</sup> Pacriowsky et al. 2014<sup>16</sup> have identified that several biologic pathways of infantile spasms were linked and involved forebrain GABAergic interneuron development, as well as GABAergic and other pathways of pre- and post-synaptic function, and suggested that abnormalities of forebrain synaptic growth and function form biologic mechanism underlying both infantile spasms and autism.

Whether the 15q11q13 duplication is the sole cause of infantile spasms because not all cases of the duplication have epileptic spasms—the male sibling of the proband being an example in this family pedigree, is not known. The proband and the mother might have had an independent other cause

or, more likely, 15q11q13 duplication may exhibit incomplete penetrance or some other genetic susceptibility that, in combination with the detected duplication, combined to cause infantile spasms.

#### 4. Conclusions

This is the first report of infantile spasms and 15q11.2q13.1 chromosome duplication in two successive generations. Without chromosomal study both patients would have remained classified as having infantile spasms of unknown aetiology. Chromosomal microarray analysis should be included in the diagnostic evaluation of patients with infantile spasms when an evaluation for structural brain lesions and metabolic disorders reveal no abnormal findings.

This report brings new light to the study of genetic causes of infantile spasms.

Our report is expanding the phenotype of chromosome 15q11q13 duplication syndrome.

#### Disclosure of conflicts

The corresponding author (RR) states “None of the authors has any conflict of interest to disclose.”

#### REFERENCES

- Paciorkowski A, Thio L, Dobyns W. Genetic and biologic classification of infantile spasms. *Pediatr Neurol* 2011;20:197–202.
- Piard J, Philippe C, Marvier M, Beneteau C, Roth V, Valduga M, et al. Clinical and molecular characterization of a large family with an interstitial 15q11q13 duplication. *Am J Med Genet* 2010;152A(8):1933–41.
- Berg AT, Berkovic SF, Brodie MJ, Buchhalter J, Cross JH, van Emde Boas W, et al. Revised terminology and concepts for organization of seizures and epilepsies, report of the ILEA commission on classification and terminology, 2005-2009. *Epilepsia* 2010;51:676–85.
- Riikonen R. Infantile spasms in siblings. *J Pediatr Neurosci* 1987;3:235–44.
- Dulac O, Feingold J, Plouin P, et al. Genetic reposing to west syndrome. *Epilepsia* 1993;34:732–7.
- Sugai K, Fukuyama Y, Yasuda K, Fujimoto S, Ohtsu M, Ohta H, et al. Clinical and pedigree study on familial cases of west syndrome in Japan. *Brain&Dev* 2001;23:558–64.
- Bolton P, Dennis N, Browne C, Thomas N, Veltman M, Thompson R, et al. The phenotypic manifestations of interstitial duplications of proximal 15q with special reference to the autistic spectrum disorders. *Am J Med Genet* 2001;105:675–85.
- De Kovel C, Trucks H, Helbig I, Mefford HC, Baker C, Leu C. Recurrent microdeletions at 15q11.2 and 16p13.11 predispose to idiopathic generalized epilepsies. *Brain* 2010;133:23–32.
- Michelson M, Eden A, Vinkler C, Leshinsky-Silver E, Kremer U, Lerman-Sagie T, et al. Familial partial trisomy 15q11-13 presenting as intractable epilepsy in the child and schizophrenia in the mother. *Eur J Pediatr Neurol* 2011;15(3):230–3. <http://dx.doi.org/10.1016/j.ejpn.2010.11.001>. Epub 2010 Dec 8.
- Bingham P, Spinner N, Sovinsky L, Zackai E, Chance P. Infantile spasms associate with proximal duplication of chromosome 15q. *Pediatr Neurol* 1996;15:163–5.
- Tiwari V, Sundaram S, Chugani H, Hug A. Infantile spasms associated with abnormal copy number variations. *J Child Neurol* 2013;28:1191–6. <http://dx.doi.org/10.1177/0883073812453496>. Epub 2012. Aug 21.
- Greer PL, Hanayama R, Bloodgood BL, Mardingly AR, Lipton DM, Flavell SW, et al. The angelman syndrome protein UBE3A regulates synapse development by ubiquitinating arc. *Mar 5 Cell* 2010;140(5):704–16. <http://dx.doi.org/10.1016/j.cell.2010.01.026>.
- Noor A, Dupuis L, Mittal K, Lionel A, Marshall C, Scherer W, et al. 15q11.2 duplication encompassing only UBE3A gene is associated with developmental delay and neuropsychiatric phenotypes. *Hum Mutat* 2015;36:689–93.
- Ageeli E, Drunat S, Delanoe C, Perrin L, Baumann C, Capri Y, et al. Duplication of the 15q11-q13 region: Clinical and genetic study of 30 new cases. *Eur J Med Genet* 2014;57:5–14.
- Epi4K Consortium: Epilepsy Phenome/Genome Project, Allen A, Berkovic S, Cossette P, Delanty N, Dlugos D, Eichler E, et al. De novo mutations in epileptic encephalopathies. *12 Nature* 2013;501(7468):217–21. <http://dx.doi.org/10.1038/nature12439>. Epub 2013 Aug 11.
- Paciorkowski AR, Thio LL, Rosenfeld JA, et al. Copy number variants and infantile spasms: evidence for abnormalities in ventral forebrain development and pathways of synaptic function. *Eur J Hum Genet* 2011;19:1238–45.