

8. Stamm C, Friehs I, Ho SY, Moran AM, Jonas RA, del Nido PJ. Congenital supravalvular aortic stenosis: a simple lesion? *Eur J Cardiothorac Surg* 2001;19:195–202.

## Cerebral Thromboembolism From Ligated Blalock-Taussig Shunt in an Adult Patient

Yaroslav B. Mykychak, MD,  
Lyubomyr Y. Bohuta, MD, PhD,  
Yaroslav Y. Ivanov, MD, PhD, Yulia V. Pozniak, MD,  
Valentyna A. Khanenova, MD,  
Oleksandr D. Babliak, MD, PhD, and  
Illya M. Yemets, MD, PhD

Departments of Cardiac Surgery and Cardiology, Ukrainian Children's Cardiac Center, Kyiv, Ukraine

A 26-year-old woman underwent tetralogy of Fallot repair and classic Blalock-Taussig shunt (BTS) ligation. On postoperative day 4 she developed severe left-sided hemiplegia due to cerebral infarction. Thrombi in the BTS stump, right brachiocephalic artery, and its branches were removed surgically and the BTS stump was resected. The patient gradually recovered from hemiplegia and is leading a normal life with moderate left hemiparesis and is in good functional status 4 years after the event. An aggressive approach in treating this complication was crucial to prevent further thrombosis and neurologic deficit progression in this patient. We recommend reducing the size of the BTS stump during definitive repair.

(Ann Thorac Surg 2016;101:361–3)

© 2016 by The Society of Thoracic Surgeons

In the modern era, survival after congenital heart surgery is excellent and the population of adults with congenital heart disease is steadily growing [1]. Significant incidence of early and late morbidities remains a serious issue, with neurologic complications possibly being the most severe and burdensome among them [2]. Thromboembolism from heart chambers is an important cause for adverse neurologic outcomes in pediatric cardiac surgery [2–4]. “Blind sacks” are a well-known source of thromboembolism from low-flow chambers and vessels [3, 4]. Presently, tetralogy of Fallot (ToF) repair in adulthood is rare [5]. Only 1 previous report describes classic Blalock-Taussig shunt (BTS) as the source of thromboembolism [3]. Numbers of patients with classic BTS are dwindling due to replacement by modified BTS. We present a rare case of cerebral infarction and its treatment after ToF repair and classic BTS ligation in an adult patient.

Accepted for publication March 18, 2015.

Address correspondence to Dr Mykychak, Ukrainian Children's Cardiac Center, Chornovola 28/1, Kyiv, 01135 Ukraine; email: [yaroslav.mykychak@cardio.org.ua](mailto:yaroslav.mykychak@cardio.org.ua).

A 26-year-old woman was admitted to our hospital with cyanosis, fatigue, and exercise intolerance. In 1989, at the age of 5 years she underwent a right-sided classic BTS procedure for ToF palliation. Her recovery was uneventful and after discharge she was lost to follow-up for 22 years. At the age of 24 years she gave birth to a healthy child.

At admission to our Center the patient was diagnosed with ToF (S,D,S); pulmonary valve pressure gradient was 60 mm Hg. Cardiac catheterization revealed a patent BTS grown to the size of 15 mm in diameter at the right subclavian artery (RSA) origin and 6 mm at the right pulmonary artery (Fig 1).

The patient underwent ToF repair with VSD patch closure, right ventriculotomy, right ventricle outflow tract obstruction resection, and transannular patch of glutaraldehyde treated autologous pericardium, sparing pulmonary valve leaflets. The BTS was doubly ligated near its insertion into the right pulmonary artery. Cardiopulmonary bypass duration was 89 minutes and aortic cross-clamp time was 61 minutes.

She was then transferred to the intensive care unit; ventilation time was 10 hours. Twenty-one hours after surgery 10 U/kg/h of heparin was administered as continuous infusion.

On the fourth day central venous and arterial lines were removed with heparinization still continuing when dizziness, drowsiness, and extreme weakness and loss of sense in the left side of the body acutely occurred, followed by loss of consciousness. Severe left-sided hemiplegia was diagnosed. Magnetic resonance imaging confirmed acute ischemic infarction involving the right basal ganglia with cerebral edema and lack of blood flow in the right internal carotid artery and medial cerebral artery. Additional and possibly unrelated finding was the vascular malformation in the middle upper part of the frontal bone squama. Transthoracic echocardiography found no signs of thrombi in the heart chambers.

Angiography revealed thrombi in ligated classic BTS (Fig 2A) and the right common carotid artery (RCCA) (Fig 2B). To prevent further thrombosis, 6 hours after symptoms onset we performed thrombectomy of the brachiocephalic artery, RCCA, right external (RECA), and internal carotid artery (RICA). A cervical incision was made parallel and anterior to the right sternocleidomastoid muscle extending to the jugular notch. After dissection we observed no pulsation of the RCCA. The BTS stump was resected and multiple fresh thrombi were removed from the brachiocephalic artery. After incising RCCA bifurcation, lumen of RCCA, RECA, and RICA also were freed from fresh thrombi. Incisions of the brachiocephalic artery and RCCA were closed with interrupted 7-0 polypropylene sutures. We confirmed an adequate pulsation of RCCA and its branches. The patient was transferred to the intensive care unit and treated with Fraxiparine (Glaxo Wellcome Production, Notre Dame de Bondeville, France), dexamethasone, citicoline, and piracetam, with following neurologic rehabilitation. Follow-up Doppler scanning of head and neck vessels showed hypoplasia and anomalous intracranial insertion of the right vertebral artery. She was discharged home 25 days after cerebral

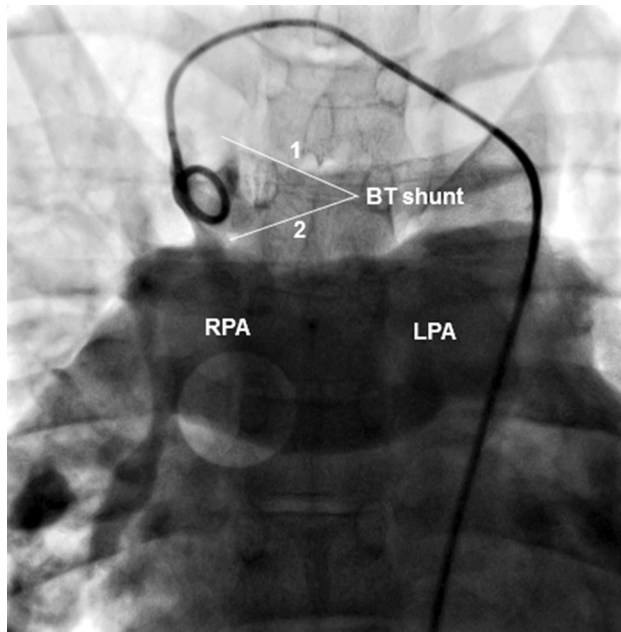


Fig 1. Patent classic Blalock-Taussig (BT) shunt. Number 1 is the right subclavian artery side, 15 mm in diameter; 2 is the right pulmonary artery (RPA) side, 5 mm in diameter. Note the resulting hourglass or funnel shape of the shunt. (LPA = left pulmonary artery.)

infarction with partially improved neurologic symptoms and continued rehabilitation.

At the last follow-up the patient was in good functional status, with satisfactory right ventricle contractility and pressure 25 mm Hg; the gradient across the pulmonary valve was 14 mm Hg with mild regurgitation; left atrium and right ventricle mildly dilated. She gradually recovered from hemiplegia to moderate left hemiparesis and is leading a normal life taking care of her child 4 years after the event.

### Comment

We describe a rare case of cerebral infarction and its treatment after ToF repair and BTS ligation in an adult

patient. Cerebral thromboembolism is an important cause of morbidity in adults with congenital heart disease. Although its incidence and mortality may be relatively low, residual disabilities are severe and often devastating [2].

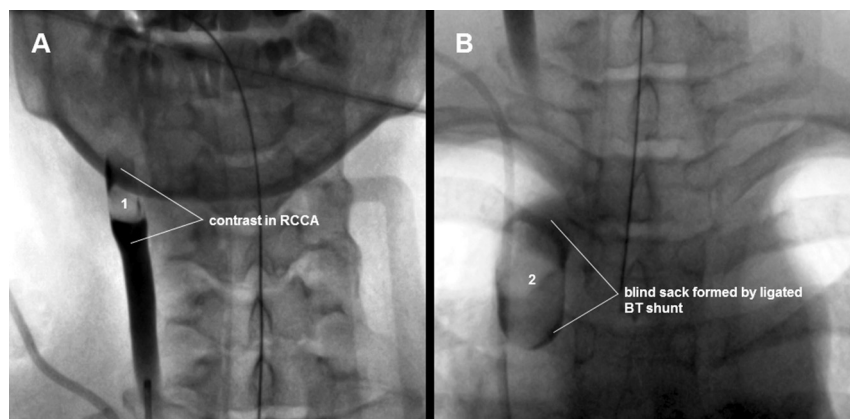
Lee and colleagues [4] reviewed 5 cases after Fontan, where thrombi formed in the pulmonary artery stump or blind ventricle, underscoring that blind sacks are a potential risk factor for thromboembolism. The authors [4] advocate surgical techniques to avoid blood stasis or eliminate blind pouches with aggressive thrombectomy to prevent cerebral complications.

Yoshimura and colleagues [3] described 3 patients that developed cerebral infarction after classic BTS ligation. Thrombi formed in the BTS stumps and were not removed. All patients recovered from hemiplegia after medical treatment. The authors recommend adequate postoperative anticoagulation and stump size reduction to prevent thromboembolism in such cases [3].

Hörer and colleagues [5] showed that correction of ToF and of pulmonary atresia with ventricular septal defect in adults is associated with high early mortality, but still recommended it because of considerable functional improvement. In this series, 20 out of 52 patients had prior shunt operations. Shunts were patent and ligated in 11 patients without associated complications. A total of 15 previous classic Blalock-Taussig shunt operations were performed in this group.

Classic BTS stump is a rare source of thromboembolism but important due to its proximity to cerebral arteries. In our case, BTS funnel-shape configuration and the size of the leftover stump may have played the role. After morbidity review we concluded that the size and the length of the anastomosis were underestimated as potential cause for thrombosis; despite adequate anticoagulation this blind sack promoted thrombi formation and should have been resected. Also, thrombectomy had to be performed earlier. It is unclear whether the vascular malformation in the frontal bone and described right vertebral artery anomaly are in any way related to this complication. We believe that an aggressive approach in treating this complication prevented further thrombosis, neurologic deficit progression and potentially lethal outcome.

Fig 2. (A) Thrombus (1) in the right common carotid artery (RCCA) and (B) thrombus (2) in a classic Blalock-Taussig shunt (BTS) stump revealed by angiography.



During the last 2 decades the numbers of patients with classic BTS are steadily decreasing, which may lower concern toward such a major complication. In our opinion, a grown classic Blalock-Taussig shunt should be ligated as proximally as possible, resected or reduced in size in other possible ways during definitive repair to prevent thromboembolic events.

## References

1. Engelfriet P, Boersma E, Oechslin E, et al. The spectrum of adult congenital heart disease in Europe: morbidity and mortality in a 5 year follow-up period. *The Euro Heart Survey on adult congenital heart disease.* *Eur Heart J* 2005;26:2325–33.
2. Hoffmann A, Chockalingam P, Balint OH, et al. Cerebrovascular accidents in adult patients with congenital heart disease. *Heart* 2010;96:1223–6.
3. Yoshimura N, Yamaguchi M, Oshima Y, Oka S, Ootaki Y, Tei T. Cerebral infarction in children due to thromboembolism from ligated Blalock-Taussig shunt. *J Thorac Cardiovasc Surg* 2000;120:185–6.
4. Lee SY, Baek JS, Kim GB, et al. Clinical significance of thrombosis in an intracardiac blind pouch after a Fontan operation. *Pediatr Cardiol* 2012;33:42–8.
5. Hörer J, Friebe J, Schreiber C, et al. Correction of tetralogy of Fallot and of pulmonary atresia with ventricular septal defect in adults. *Ann Thorac Surg* 2005;80:2285–91.

## Coronary Artery Reconstruction Using a Bioengineered Patch and Epicardial Tunnel

Muhammad S. Khan, MD, Matthew R. Yeager, MBA, Roosevelt Bryant, III, MD, Angela Lorts, MD, and David L. S. Morales, MD

Cardiothoracic Surgery and Pediatric Cardiology, Cincinnati Children's Hospital Medical Center, Cincinnati, Ohio

An infant girl presented within a month after undergoing repair of the anomalous left coronary artery (LCA) from pulmonary artery by reimplantation technique with long-segment LCA occlusion and no flow to the bifurcation. She was severely symptomatic and referred for cardiac transplant evaluation. CorMatrix small-intestinal submucosa-extracellular matrix (CorMatrix Cardiovascular, Roswell, GA) was selected for the construction of LCA by creation of an epicardial tunnel to the LCA bifurcation. At 18 months after the operation, the patient was asymptomatic with normal growth and development, an unobstructed LCA system, and normal left ventricular size and function. With myocardial remodeling, this child has normal systolic function and has avoided cardiac transplantation.

(*Ann Thorac Surg* 2016;101:363–5)

© 2016 by The Society of Thoracic Surgeons

Accepted for publication March 16, 2015.

Address correspondence to Dr Morales, Pediatric Cardiothoracic Surgery, Cincinnati Children's Hospital Medical Center, The University of Cincinnati College of Medicine, 3333 Burnet Ave, MLC 2004, Cincinnati, OH 45229; email: david.morales@cchmc.org.

CorMatrix small intestinal submucosa-extracellular matrix (SIS-ECM) technology (CorMatrix Cardiovascular, Roswell, GA) is Food and Drug Administration-approved as a patch material for intracardiac and extracardiac applications in the United States [1, 2]. Since its introduction, the use of this patch has diversified [2]. SIS-ECM technology has been documented for pericardial reconstruction, septal repair, aortic annular/root enlargement, valve leaflet augmentation, vena cava reconstruction, and a host of repairs in congenital heart operations [2]. In this case, the material was selected for the construction of the left main coronary artery (LCA) by creation of an epicardial tunnel to the LCA bifurcation.

A 7-month-old girl underwent repair of the anomalous left coronary artery (LCA) from the pulmonary artery by reimplantation technique at the age of 3 months at another institution. Cardiac catheterization 3 weeks after the operation showed a long segment LCA occlusion with no flow to the bifurcation (Fig 1) and extremely small distal vessels, along with a severely dilated, poorly functioning left ventricle (LV). Cardiac transplantation was recommended at the other institution, at which point the patient's family consulted our team.

She presented to us with increased fatigue, irritability, diaphoresis during feeding, periorbital edema, and intermittent irritability. After detailed analysis and discussions, it was determined that creation of a two-coronary system would provide the best chance for long-term patient survival. This decision was reinforced by a positron emission tomography scan that suggested large areas of reversible ischemia (possibly hibernating myocardium) in the area of the left anterior descending and left circumflex artery.

After use of standard techniques for repeat sternotomy and placement on cardiopulmonary bypass, the main pulmonary artery was transected at the prior area of incision. The aorta was incised at the previous incision site, and the proximal end of the LCA was identified. This fibrous tract was followed to the bifurcation, which opened into the left anterior descending and the left circumflex artery, each being 1 to 1.5 mm in size. None of the main LCA was patent.

A large epicardial tunnel was created from the bifurcation to the previous incision on the aorta, following the fibrous tract. The tunnel was not sewn to the orifices at the bifurcation but around the orifices with many very small adventitial bites to ensure the orifices were not distorted and to ensure hemostasis. The orifices of the left anterior descending and left circumflex artery were buried in scar tissue, so it was felt best not to disturb the collateral blood supply to them by skeletonizing them and that if we could get a hemostatic seal around the open orifices that we did not need to sew to the individual orifices of the bifurcation.

Dr Morales discloses a financial relationship with CorMatrix.