

# Hearing One's Voice in Your Speech: An Unusual Case of Palinacousis Due to Acute Intracerebral Hemorrhage

Daniel Rosenberg, MD\* and Julius G.S. Latorre, MD, MPH†

**Introduction:** Palinacousis or auditory perseveration is a form of acquired auditory perceptual disorder that occurs rarely due to an acute intracranial process. The condition mimics psychotic hallucination, seizure, or other behavioral disorders, potentially causing management delay. We describe an unusual form of palinacousis resulting from acute lobar intracerebral hemorrhage.

**Case Report:** A 70-year-old right-handed white man with history of hypertension, ischemic cardiomyopathy, and atrial fibrillation on anticoagulation developed a rare form of palinacousis, on which he hears the previous speaker's voice on the current speaker's speech due to right parietal intracranial hemorrhage. Cranial imaging revealed right parietal intracranial hemorrhage likely secondary to cerebral amyloid angiopathy or hypertension. Extensive workup and thorough clinical examination ruled out dementia, psychosis, seizure, or other behavioral disorders. The condition gradually improved without any specific intervention.

**Conclusions:** Abnormality in auditory processing due to intracranial lesions affecting auditory cortical projections causes a variety of symptoms that mimic other conditions such as psychotic hallucinations, and ictal and postictal behavioral changes. Thorough characterization with detailed examination and workup may help in distinguishing one from the other. A rare form of palinacousis may occur after unilateral nondominant parietal lesion. The condition is self-limiting and requires no specific management. Ruling out seizure disorder or psychiatric condition may prevent unnecessary workup and treatment.

**Key Words:** acute stroke, intracranial hemorrhage, cerebral amyloid angiopathy, palinacousis, behavioral neurology

(*The Neurologist* 2016;21:13–15)

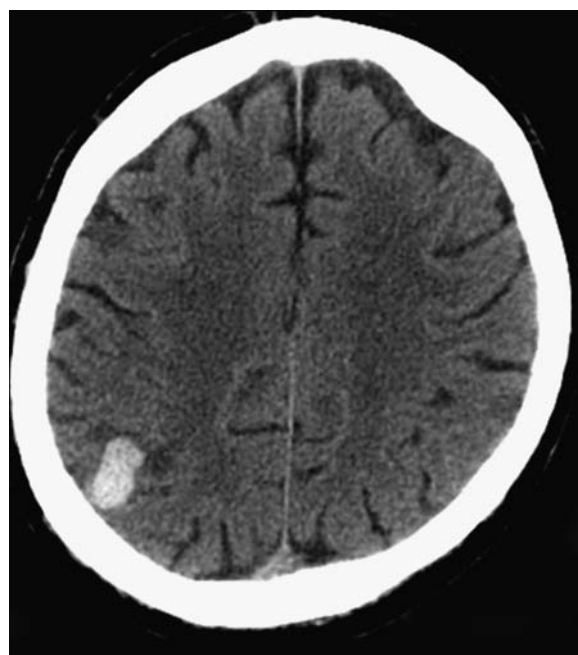
## BACKGROUND

Palinacousis has been described as a paroxysmal spontaneous auditory illusion in which environmental sounds continue to persist after the initial stimulus is removed.<sup>1</sup> It can be triggered by various forms of damage to the temporal lobe, though it has been observed in patients with lesions in the parietal lobe as well.<sup>1–3</sup> It is often associated with epileptiform activity on EEG, and has been described as both an ictal and postictal phenomenon.<sup>1,3</sup> Moreover, other perceptual disorders often accompany the condition, including phonagnosia, paracusia, hyperacusis, palinopsia, prosopagnosia, aphasia, and visuospatial disorders.<sup>3,4</sup> An interesting case was reported when auditory perseveration was triggered by a second stimulus.<sup>2</sup> We present a case of a patient who developed

palinacousis and demonstrated atypical symptoms that have not yet been observed in the literature.

## CASE REPORT

A 70-year-old right-handed white man was brought by his wife to the emergency room due to odd behavior for 2 days. He is nonsmoker with history of hypertension, 3-vessel coronary artery disease after percutaneous stent revascularization, and atrial fibrillation on warfarin and aspirin. The wife described the patient to be acting differently and somewhat disoriented. According to the patient, he could not explain why people talking to him sounded strange, speaking in different voices which he heard before. For example, he would talk to a man and would hear him as talking with the voice of the woman he previously talked to. He thought it was funny and he could not concentrate on what the other person was saying because he would be laughing. This behavior worried his wife prompting them to visit the emergency room. Review of systems revealed past symptoms of congestive heart failure and palpitation, which resolved after successful electrical cardioversion of his atrial fibrillation several months back. On admission, his general examination was unremarkable. His vital signs were normal, and his EKG showed sinus rhythm. Neurological examination showed normal cranial nerves, normal motor, sensory, and cerebellar functions, and normal language function. His Mini-Mental State Examination score was 30/30. During the examination, the patient occasionally burst into laughter claiming that the examiner's voice sounded like the nurse who talked to him initially. CT brain showed a 8 mL acute lobar intracerebral hemorrhage in the right posterior parietal area with mild surrounding edema (Fig. 1). MRI of the brain



**FIGURE 1.** Computed tomography scan of the brain showing right parietal intracerebral hemorrhage.

From the \*College of Medicine; and †Department of Neurology, SUNY Upstate Medical University, Syracuse, NY.

The authors declare no conflict of interest.

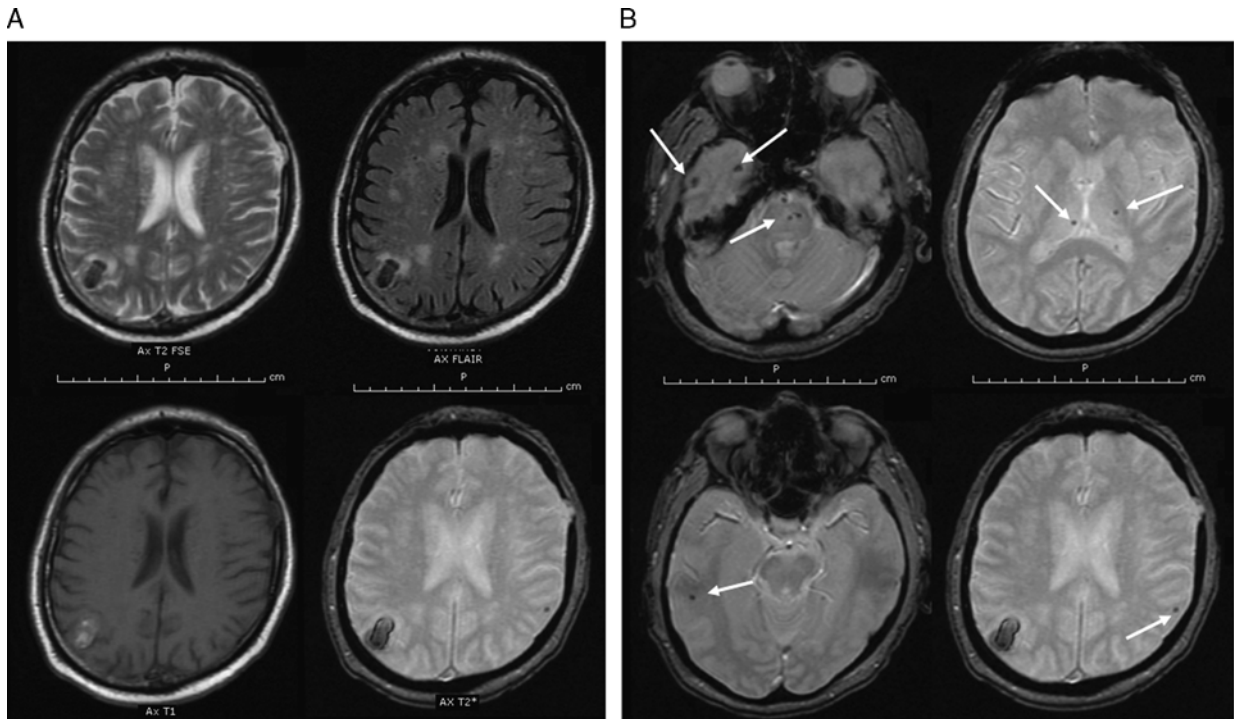
Reprints: Julius G.S. Latorre, MD, MPH, Department of Neurology, SUNY Upstate Medical University, 750 East Adams St, Syracuse, NY 13210.

E-mail: latorrej@upstate.edu.

Copyright © 2015 Wolters Kluwer Health, Inc. All rights reserved.

ISSN: 1074-7931/16/2101-0013

DOI: 10.1097/NRL.0000000000000069



**FIGURE 2.** A, Magnetic resonance imaging sequence showing right parietal intracerebral hemorrhage. B, Gradient echo sequence showing deep and cortical microhemorrhages (white arrow).

showed hyperintense T2 lesion consistent with microvascular changes and multiple microhemorrhages along the subcortical, cortical, and infratentorial areas suggestive of cerebral amyloid angiopathy (Fig. 2). MRA of the head and neck did not show any vascular abnormality. His INR on admission was 2.6 and was promptly reversed. The rest of his laboratory workup was unremarkable.

During his hospitalization, the patient exhibited several auditory perceptual disturbances. On occasion, he complained of hearing a very low-pitched intonation in people's voices, including his own. At other times, he would hear a cyclical pattern of sounds that transitioned from noisy to silent. His most disturbing auditory symptoms persisted for several days and presented in 2 distinct forms. At first, he described hearing his deceased mother's voice speaking to him through other people's speech. Later on, he mentioned that after talking to one person, he would hear a second person speaking to him in the first person's voice. He would also sometimes hear his voice as if it was the voice of the person he just spoke to. During physical therapy, the patient reported that therapist voices would suddenly change to those of people he had heard on television, which provoked uncontrollable fits of laughter. The condition was disturbing enough to render the patient unable to consistently follow commands, and he often needed redirection to complete simple tasks. An EEG was performed while he was having these episodes and did not reveal any focal findings or epileptiform abnormalities.

Nonauditory perceptual disturbance was occasionally expressed by the patient, with 1 occasion when he noted that the people around him "looked funny." At other times, he had trouble with visuospatial processing during occupational therapy sessions.

At discharge, the patient's auditory perseveration was limited to nonverbal sounds, which continued to be triggered occasionally by loud stimulus (eg, smoke detector alarm) at 2 months. No further verbal perseveration was noted.

## DISCUSSION

Our patient presented with elaborate auditory perceptual disorders not previously described elsewhere. The normal

hearing and bedside audiologic testing ruled out abnormality in peripheral auditory system. The patient's deep insight and understanding of his condition makes psychotic hallucination unlikely. The absence of cognitive dysfunction and normal Mini-Mental State Examination and the transient nature of the condition ruled out dementia as etiology. The normal EEG during his episodes of auditory perseveration rules out seizure or postictal state. The gradual disappearance of his symptoms likely correlated with the resolution of the surrounding cerebral edema along the hemorrhagic focus.

Palinacousis is typically associated with irritation of the temporal lobe caused by various lesions and/or seizure activity.<sup>1,2</sup> The condition is rare, with only 15 reported cases so far,<sup>3</sup> but it may be underdiagnosed as some patients have accompanying language disorder making the assessment almost impossible unless the aphasia improves. While it is uncommon for patients to develop auditory perseveration with lesions localized to other areas of the brain, several cases have reported involvement of the parietal lobes.<sup>2,3</sup> In fact, 1 case report described a lesion to the medial geniculate body that caused the patient to present with similar symptoms.<sup>4</sup> In addition, palinacousis has often been associated with seizures and related epileptiform activity. In a series of 7 patients, 6 had seizures either during or after their auditory hallucinations.<sup>1</sup> While palinacousis has been traditionally observed as an ictal phenomenon, another study provides evidence that it may also be seen as a postictal event.<sup>3</sup>

The most striking feature of the current case was the atypical presentation of auditory symptoms in the patient. Palinacousis generally presents as realistic, neutral sounds brought on by various auditory stimuli. The human voice is the most commonly perseverated sound. Perseveration occurs almost immediately after the stimulus but may occur as late as 24 hours after.<sup>1</sup> Recently, an atypical version of auditory

perseveration was reported in which the patient would receive a primary auditory stimulus that would extinguish a secondary stimulus in the form of an echo. In addition, if 3 stimuli were presented, the first 2 would extinguish the third. As the patient spoke to her doctor, she reported that she heard an echo of her voice coming out of his mouth.<sup>2</sup>

In the current case, the patient's auditory symptoms were similar yet distinct from what was recently reported.<sup>2</sup> While both cases involved the interplay of multiple auditory stimuli, the patient in the current case demonstrated a more direct and straightforward A-B-C pattern of perseveration. A more accurate way to describe the patient's symptoms could be termed triggered abnormal auditory perception with perseveration. For instance, the patient would talk to a person, and then would hear the next person speaking in the previous person's voice.

Of the 15 cases of palinacousis reviewed, almost all lesions were localized in the left temporal and parietal lobes.<sup>3,5</sup> In our patient, the hemorrhagic lesion was located in the nondominant somatosensory association cortex of the right parietal lobe. Functional MRI studies have shown that the right parietal cortex is heavily involved in auditory verbal imagery for tasks involving perception of speech in the second or third person.<sup>6</sup> Phonagnosia, a related condition manifesting as deficit in familiar voice recognition, has been correlated with right parietal lesion.<sup>7</sup>

As more cases of palinacousis are described in the literature, it has become evident that this phenomenon does not

always present in a typical manner. It can be triggered by a wide variety of lesions throughout the brain, and it may or may not be associated with epileptiform activity. While auditory perseveration is the hallmark of this condition, it may range from simple repetitions to the distinct forms of altered perception with perseveration as seen in the current case. Even though much work has been done to create a better understanding of palinacousis since the first major study in the 1970s, experience has demonstrated that it is a far more perplexing phenomenon than originally imagined.

## REFERENCES

1. Jacobs L, Feldman M, Diamond SP, et al. Palinacousis: persistent or recurring auditory sensations. *Cortex*. 1973;9:275–287.
2. Di Dio AS, Fields MC, Rowan AJ. Palinacousis- auditory perseveration: two cases and a review of the literature. *Epilepsia*. 2007;48:1801–1806.
3. Mohamed W, Ahuja N, Shah A. Palinacousis—evidence to suggest a post-ictal phenomenon. *J Neurol Sci*. 2012;317:6–12.
4. Fukutake T, Hattori T. Auditory illusions caused by a small lesion in the right medial geniculate body. *Neurology*. 1998;51:1469–1471.
5. Kim JS, Kwon M, Jung JM. Palinacousis in temporal lobe intracerebral hemorrhage. *Neurology*. 2007;68:1321–1322.
6. Shergill SS, Bullmore ET, Brammer MJ, et al. A functional study of auditory verbal imagery. *Psychol Med*. 2001;31:241–253.
7. Van Lancker DR, Cummings JL, Kreiman J, et al. Phonagnosia: a dissociation between familiar and unfamiliar voices. *Cortex*. 1988;24:195–209.