



Disponible en ligne sur
ScienceDirect
www.sciencedirect.com

Elsevier Masson France
EM|consulte
www.em-consulte.com



Clinical case

A case of dorsolateral pontine infarct: Description of a new vascular alternating syndrome

Description d'un syndrome alterne du tronc cérébral : à propos d'un cas d'infarctus de la partie dorsolatérale de la protubérance

S. Obaid^a, E. Magro^a, R. Seizeur^b, M.W. Bojanowski^{a,*}

^a Department of surgery, division of neurosurgery, hôpital Notre-Dame, centre hospitalier de l'université de Montréal (CHUM), 1560, rue Sherbrooke-Est, H2L 4M1 Montréal, QC, Canada

^b Service de neurochirurgie, CHU de la Cavale, I, Tanguy-Prigent, 29200 Brest, France

ARTICLE INFO

Article history:

Received 6 April 2015
Received in revised form
14 September 2015
Accepted 23 September 2015
Available online xxx

Keywords:

Alternating syndrome
Pontine infarct
Basilar artery
Long circumferential branch aneurysm

Mots clés :

Syndrome alterne
Infarctus
Protubérance
Artère basilaire
Anévrisme
Longue branche circonférentielle

ABSTRACT

Introduction. – Inferolateral pontine infarcts are well-described lesions of the anterior inferior cerebellar artery territory with a wide variety of clinical presentations. We report the case of isolated unilateral hearing loss and contralateral sensation of coldness due to a dorsolateral lower pontine infarct.

Case description. – We describe the case of a 48-year-old female patient who developed isolated selective high-frequency hearing loss on the left side, and contralateral hemibody sensation of coldness. MRI showed a left-sided dorsolateral lower pontine ischemic lesion. A subsequent angiogram revealed the lesion to result from the spontaneous dissection of a long circumferential branch of the basilar artery.

Conclusion. – To our knowledge, this is the first reported case of a vascular alternating syndrome consisting of isolated ipsilateral hearing loss and contralateral thermal dysesthesia from a dorsolateral lower pontine infarct. Occlusion of a long perforating branch of the basilar artery and consequent posterolateral lower pontine infarct may result in an alternating syndrome with subtle clinical symptoms. Knowledge of this type of syndrome may direct physicians towards the diagnosis of a dorsolateral lower pontine infarct, despite vague clinical complaints.

© 2015 Published by Elsevier Masson SAS.

RÉSUMÉ

Introduction. – Les infarctus de la protubérance inférolatérale du territoire de l'artère cérébelleuse inféro-antérieure peuvent produire une symptomatologie clinique variée. Nous décrivons le cas d'une perte d'audition ipsilatérale à la lésion, accompagnée d'une dysesthésie thermique controlatérale à un infarctus de la portion dorsolatérale de la protubérance inférieure.

Cas clinique. – Une femme de 48 ans a développé une perte d'audition sélective aux hautes fréquences, accompagnée d'une sensation de froid de l'hémicorps controlatéral. L'imagerie par résonance magnétique a mis en évidence une lésion ischémique de la portion dorsolatérale de la protubérance inférieure du côté gauche. L'angiographie conventionnelle a révélé que cette lésion résultait d'une dissection spontanée d'une longue branche circonférentielle de l'artère basilaire.

Conclusion. – À notre connaissance, il s'agit du premier cas rapporté d'un syndrome alterne vasculaire caractérisé par une perte d'audition unilatérale et d'une dysesthésie thermique controlatérale résultant d'un infarctus de la portion dorsolatérale de la protubérance inférieure. L'occlusion d'une longue branche perforante de l'artère basilaire peut causer un infarctus pontique se traduisant en un syndrome alterne se manifestant par une symptomatologie frustrée. La reconnaissance de ce syndrome permettra de guider les cliniciens vers le diagnostic d'une atteinte du tronc cérébral.

© 2015 Publié par Elsevier Masson SAS.

Abbreviations: AICA, Anterior inferior cerebellar artery; BA, Basilar artery; DLLPI, Dorsolateral pontine infarct; ILPIs, Inferolateral pontine infarcts.

* Corresponding author.

E-mail address: michel.bojanowski.chum@ssss.gouv.qc.ca (M.W. Bojanowski).

<http://dx.doi.org/10.1016/j.neuchi.2015.09.002>

0028-3770/© 2015 Published by Elsevier Masson SAS.

1. Introduction

Inferolateral pontine infarcts (ILPIs) are widely described lesions of the anterior inferior cerebellar artery (AICA) territory often resulting from occlusion of the AICA itself or at times from the more proximal vertebrobasilar system [1]. The classical AICA syndrome was first described by Adams et al. in 1943 in a patient with clinical evidence of damage to the inferolateral pons [2]. The wide range of clinical signs and symptoms of this syndrome is rarely fully exhibited by patients with ILPIs, which leads to the generally accepted term of “incomplete AICA syndrome” [1,3]. Nevertheless, even in cases with subtle clinical symptoms, knowledge of the specific description of individual incomplete syndromes may prompt physicians to suspect an ILPI. This is the first reported case, to our knowledge, of isolated ipsilateral hearing loss and contralateral thermal dysesthesia due to a dorsolateral pontine infarct (DLLPI).

2. Case report

A 48-year-old female patient, with no significant previous medical history, was admitted to the emergency department following a thunderclap headache and reduced level of consciousness. Three weeks earlier, the patient had consulted for complaints of right-sided hemiparesthesia, but no imaging was performed. Paresthesia persisted until her arrival at the hospital. Upon arrival, the patient was in an obtunded state (Glasgow Coma Scale 13) and deteriorated rapidly into a state of unresponsiveness. An immediate computed tomography (CT) scan showed a diffuse subarachnoid haemorrhage with secondary hydrocephalus (Fig. 1A). An emergency

external ventricular drain was subsequently inserted and the immediate postoperative CT angiogram revealed a 6-mm aneurysm of a left long circumferential branch of the basilar artery (BA) (Fig. 1B, C). Conventional angiography performed the following day revealed the disappearance of the aneurysm and occlusion of the long circumferential branch, suggesting thrombosis of the dissecting aneurysm and the parent artery (Fig. 1D). The AICA was patent (Fig. 1D). Initial cerebral MRI revealed a hyper-intense lesion on T2 sequences at the left dorsolateral pons and inferior cerebellar peduncle, with no diffusion restriction (Fig. 2A–C). These images suggested that a spontaneous dissection of a long circumferential branch of the BA had occurred 3 weeks prior to admission, when the patient became symptomatic. Improvement of the patient’s level of consciousness occurred 72 hours after admission. However, the patient complained of left ear hearing loss and a sensation of coldness on the right side of the body. In addition, she complained of intermittent diplopia, however upon examination, the extraocular movements were well-preserved. No evidence of vestibular deficit, or any other cranial nerve damage, was observed. Follow-up MRI at 3 weeks revealed regression of the medial aspect of the lesion (Fig. 3A, B). Six weeks following initial presentation, isolated hearing loss and contralateral hemibody thermal dysesthesia was unchanged. A pure tone audiometry revealed a high-frequency, severe to profound left sided sensorineuronal hearing loss (Fig. 4).

3. Discussion

Diagnosing brainstem infarcts is often challenging, as it requires rigorous knowledge of its anatomy. In order to facilitate

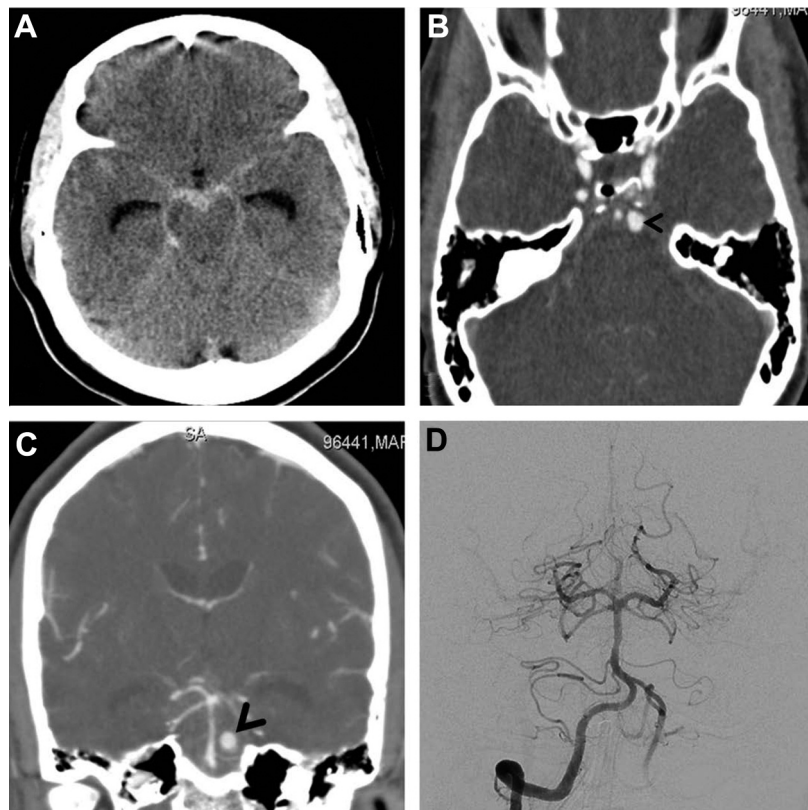


Fig. 1. A. Non-contrast brain CT-scan: subarachnoid haemorrhage and dilated temporal horns of the lateral ventricles. B, C. Initial angio-CT-scan, axial (B) and coronal (C) views: left-sided 6-mm long circumferential BA branch aneurysm (black arrow head). D. Cerebral conventional angiography: patent left AICA, occlusion of the left BA long circumferential branch and no evidence of any aneurysm.

A. Tomodensitométrie cérébrale sans contraste : hémorragie sous-arachnoïdienne et dilatation des cornes temporales des ventricules latéraux. B, C. Angiotomodensitométrie cérébrale initiale, coupes axiale (B) et coronale (C) : anévrisme de 6 mm d'une longue branche circonférentielle de l'artère basilaire du côté gauche. D. Angiographie cérébrale conventionnelle : artère cérébelleuse antéro-inférieure gauche perméable, occlusion de la longue branche circonférentielle de l'artère basilaire et absence d'opacification de l'anévrisme.

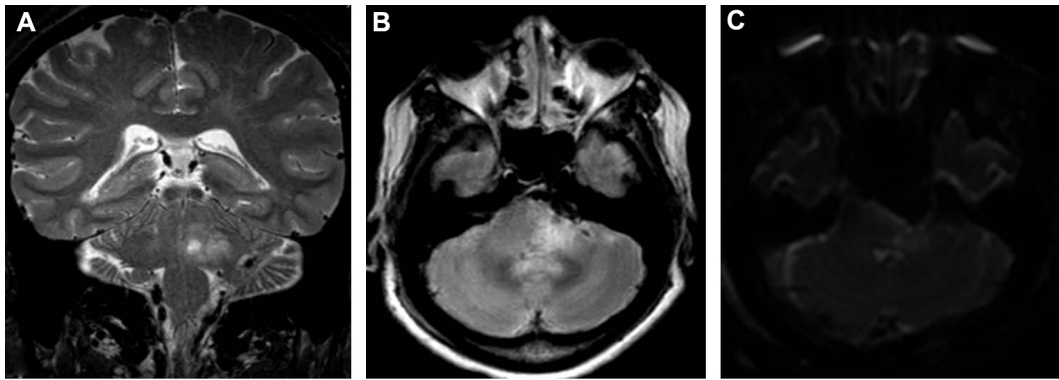


Fig. 2. Initial brain MRI scans. A, B. Coronal (A) and axial (B) T2-weighted sequences: left-sided hyperintense region of the dorsolateral caudal pons. C. Diffusion-weighted MRI: no restriction of diffusion.
Imagerie par résonance magnétique (IRM) cérébrale. A, B. Séquence T2 : région hyperintense de la protubérance dorsolatérale du côté gauche. C. IRM de diffusion : absence de restriction de diffusion.

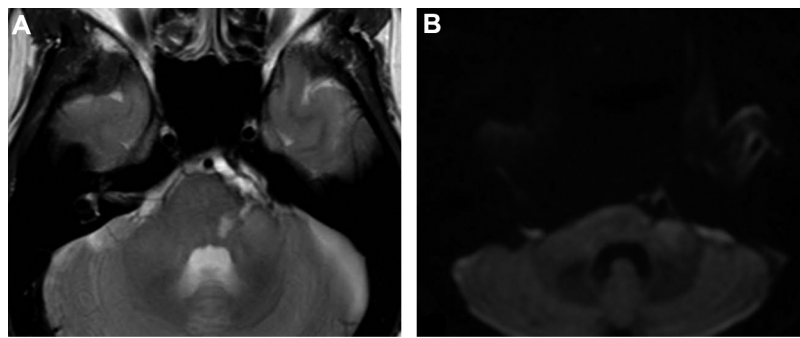


Fig. 3. Brain MRI scans 3 weeks following the stroke. A. Axial T2-weighted MRI: left-sided medial regression of the hyperintense region of the dorsolateral caudal pons. Diffusion-weighted MRI remained restriction-free.
IRM cérébrale trois semaines après l'infarctus. A. Coupe axiale, séquence T2 : régression médiale de la région hyperintense de la protubérance dorsolatérale caudale. B. La séquence de diffusion ne révèle pas de restriction.

recognition and diagnosis of ischaemic brainstem lesions, various clinical syndromes have been described. Depending on the affected artery, some brainstem strokes may be difficult to recognize. In lower pontine strokes, AICA occlusion usually leads to noisy symptomatic syndromes, considering the vast territory supplied by the artery. In addition, occlusion of smaller calibre branches may also result in clinically observable strokes. This is the case in occlusion of BA short perforating branches, which can cause damage to the anteriorly located corticospinal tract resulting in obvious motor

deficits. However, occlusion of BA long perforating branches can go unrecognized, since the ensuing stroke may lead to subtle clinical syndromes. In fact, subtle complaints such as partial hearing loss or light paresthesia may be either overlooked or attributed to less worrisome peripheral aetiologies. Nevertheless, early recognition remains at times essential to rapidly initiate treatment and prevent ischaemic or haemorrhagic complications. To our knowledge, no previous case of isolated hearing loss with contralateral thermal dysesthesia has been reported. This type of alternating syndrome has probably gone unnoticed considering the subtle clinical symptoms that may be associated with strokes involving the dorsolateral lower pons caused by occlusion of the BA long perforators. Awareness of this vascular alternating syndrome is thus paramount as it constitutes the first step of its recognition.

The dorsolateral portion of the lower pons is supplied by long circumferential perforating branches of the BA. The peripheral aspect of this area encloses the cochlear nuclei, the trigeminal nuclei and tract, the solitary tract, the sympathetic tract as well as the more laterally located spinothalamic tract (Fig. 5). Occlusion of BA long circumferential perforators may thus lead to lesions of these structures. In the present case, initial MRI revealed a hyperintense T2-weighted lesion at the dorsolateral lower pons (Fig. 2). The observed hyperintensity partly resulted from ischemic oedema, since follow-up imaging revealed regression of the medial portion of the lesion (Fig. 3). In contrast, the persistent T2 hyperintensity in the lateral portion of the brainstem likely resulted from ischaemia despite the absence of any restriction on diffusion-weighted sequences [4,5]. The observed stroke was caused by the occlusion of the BA long circumferential branch observed on

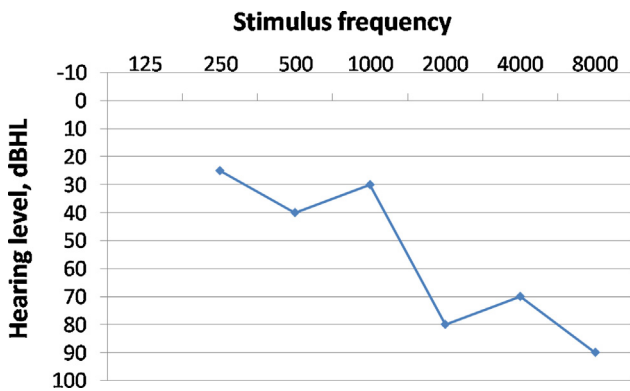


Fig. 4. Pure-tone bone-conduction audiogram in the masking lever revealing severe hearing loss at high frequencies on the left side.
La conduction osseuse des sons purs à l'audiogramme a révélé une perte de l'audition aux hautes fréquences du côté gauche.

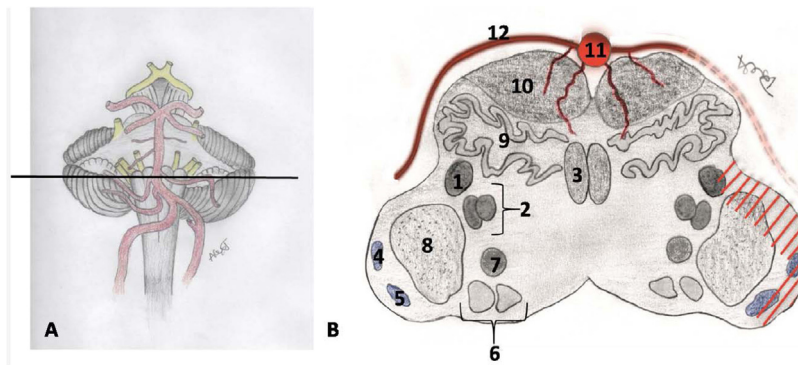


Fig. 5. Schematic illustration of the caudal Pons and its components. A. Coronal illustration with a horizontal line indicating the level of the cross-section shown in B. B. Axial illustration. The dashed area depicts the symptomatic ischemic lesion affecting the spinothalamic tract and the posterior aspect both ventral and dorsal cochlear nuclei. 1: spinothalamic tract; 2: spinal trigeminal nucleus and tract; 3: medial lemniscus; 4: ventral cochlear nucleus; 5: dorsal cochlear nucleus; 6: vestibular nuclei; 7: solitary nucleus; 8: inferior cerebellar peduncle; 9: inferior olivary nucleus; 10: corticospinal fibres; 11: basilar artery; 12: long circumferential artery.

Illustration de la protubérance caudale et de ses structures anatomiques. A. Ligne horizontale indiquant le niveau de la coupe montrée en B. B. Illustration axiale. Les régions hachurées délimitent la lésion ischémique symptomatique qui intéresse le faisceau spinothalamique et l'aspect postérieur des noyaux cochléaires ventraux et dorsaux. 1 : faisceau spinothalamique ; 2 : noyau trigéminal et son faisceau ; 3 : lemniscus médian ; 4 : noyau cochléaire ventral ; 5 : noyau cochléaire dorsal ; 6 : noyaux vestibulaires ; 7 : noyau solitaire ; 8 : pédoncule cérébelleux inférieur ; 9 : noyau olivaire inférieur ; 10 : fibres corticospinales ; 11 : artère basilaire ; 12 : artère circonférentielle longue.

conventional angiography. In this patient, the persistent ischemic lesion was translated into unremitting left-sided hearing loss and contralateral sensation of a cold hemibody. Similarly, the disappearance of the lesional oedema involving the slightly medially located abducens nucleus may explain the resolution of diplopia.

The dorsolateral location of the pontine segment of descending sympathetic fibres renders damage to this structure a plausible aetiology for the reported thermal dysesthesia. In fact, contralateral sensation of coldness associated with lower skin temperature and hyperhidrosis may result from lesions to the sympathetic tract following hemispheric and brainstem strokes [6]. It is believed that coldness and hyperhidrosis are due to reflex sympathetic activity on the contralateral side following damage to central sympathetic tracts [6–9]. Hyperhidrosis in these cases seemed to develop late and early sensation of coldness should thus not exclude sympathetic dysfunction [6–9]. However, the absence of Horner's syndrome disfavours the diagnosis of sympathetic tract lesion, as most patients presenting with this type of autonomic dysfunction initially exhibit the triad of facial anhidrosis, myosis and ptosis [9]. Rather, symptoms in the present case most probably resulted from injury to the spinothalamic tract with concomitant hemibody cold sensation [10]. Furthermore, damage to the DLLPI-territory pontomedullary junction cochlear nuclei likely explains the observed hearing loss. In addition to the observed radiological stroke location, selective high-frequency hearing loss on pure tone audiometry (Fig. 4) exhibited in this patient also suggests damage to these nuclei. In fact, cochlear nuclei follow a tonotopic distribution in which higher frequency sound inputs are integrated posteriorly in both the anterior and posterior nuclei [11].

The combination of subtle clinical findings associated with damage to structures supplied by BA long circumferential perforators and the frequently observed subclinical translation of radiological infarcts [1,12] most likely explains the present clinical findings. The prior history of hemiparesthesia suggests that the BA long circumferential branch dissection and the ensuing DLLPI probably occurred 3 weeks prior to presentation. At that time, no imaging was performed and the pontine stroke went unrecognized. Knowledge of this alternating syndrome could have directed physicians towards the diagnosis and treatment of the DLLPI. Earlier recognition of the dissection might have allowed for aneurysm-exclusion and prevention of subarachnoid haemorrhage.

The presence of subarachnoid haemorrhage in the present case rapidly suggested the diagnosis of a pontine stroke. However, in the absence such haemorrhagic event, it could have been challenging to recognize brainstem strokes, particularly when clinical symptoms are subtle such as in lesions supplied by BA long perforators. Accordingly, description of this alternating syndrome may raise awareness for future diagnosis of DLLPIs.

4. Conclusion

Occlusion of a BA long perforating branch can result in an ischaemic alternating syndrome of the dorsolateral inferior pontine region with subtle clinical symptoms of hearing loss and thermal dysesthesia. Knowledge of such a syndrome may warn physicians to consider the diagnosis of DLLPIs despite subtle deficits.

Financial support

None.

Disclosure of interest

The authors declare that they have no competing interest.

Acknowledgement

The authors are grateful to Alex Tran for the illustration.

References

- [1] Kumral E, Kisabay A, Ataç C. Lesion patterns and etiology of ischemia in the anterior inferior cerebellar artery territory involvement: a clinical-diffusion weighted-MRI study. *Eur J Neurol* 2006;13:395–401.
- [2] Adams RD. Occlusion of the anterior inferior cerebellar artery. *Arch Neurol Psychiatry* 1943;49:765–70.
- [3] Amarenco P, Rosengart A, DeWitt D, Pessin MS, Caplan LR. Anterior inferior cerebellar artery territory infarcts. Mechanisms and clinical features. *Arch Neurol* 1993;50(2):154–61.
- [4] Ay H, Buonanno FS, Rordorf G, Schaefer PW, Schwamm LH, Wu O, et al. Normal diffusion-weighted MRI during stroke-like deficits. *Neurology* 1999;52:1784–92.
- [5] Yi H-A, Lee S-R, Lee H, Ahn B-H, Park B-R, Whitman GT. Sudden deafness as a sign of stroke with normal diffusion-weighted brain MRI. *Acta Oto Laryngologica* 2005;125:1119–21.

- [6] Naver H, Blomstrand C, Ekholm S, Jensen C, Karlsson T, Wallin G. Autonomic and thermal sensory symptoms and dysfunction after stroke. *Stroke* 1995;26:1379–85.
- [7] Awada A, Ammar A, Al-Rajeh S, Borollosi M. Excessive sweating: an uncommon sign of basilar artery occlusion. *J Neurol Neurosurg Psychiatry* 1991;54:277–8.
- [8] Fisher CM. Bilateral occlusion of basilar artery branches. *J Neurol Neurosurg Psychiatry* 1977;40:1182–9.
- [9] Rousseaux M, Hurtevent JF, Benaïm C, Cassim F. Late contralateral hyperhidrosis in lateral medullary infarcts. *Stroke* 1996;27(5):991–5.
- [10] Gilroy J, Meyer JS. *Medical neurology*. 3rd ed. New York: Macmillan Publishing Co. Inc; 1979. p. 155.
- [11] Muniak MA, Rivas A, Montey KL, May BJ, Francis Hw, Ryugo DK. 3D model of frequency representation in the cochlear nucleus of the CBA/J mouse. *J Comp Neurol* 2013;521(7):1510–32.
- [12] Ikegami-Takada T, Izummikawa M, Doi T, Takada Y, Tomoda K. AICA syndrome with facial palsy following vertigo and acute sensorineural hearing loss. *Auris Nasus Larynx* 2012;39:244–8.