



Ruptured Intracranial Dermoid: Is Surgery Indispensable: 11-Year Follow-Up of a Rare Entity

Navneet Singla and Ankur Kapoor

Key words

- Intraventricular
- Ruptured dermoid
- Surgery

Abbreviations and Acronyms

MRI: Magnetic resonance imaging

Department of Neurosurgery, Postgraduate Institute of Medical Education and Research, Chandigarh, India

To whom correspondence should be addressed:

Ankur Kapoor, M.S., M.Ch.

[E-mail: dr.ankurkapoor@gmail.com]

Citation: *World Neurosurg.* (2016) 88:693.e23-693.e24.
<http://dx.doi.org/10.1016/j.wneu.2015.12.049>

Journal homepage: www.WORLDNEUROSURGERY.org

Available online: www.sciencedirect.com

1878-8750/\$ - see front matter © 2016 Elsevier Inc.
All rights reserved.

INTRODUCTION

Dermoid cysts are rare intracranial lesions that arise as the result of trapped ectodermal cells at the time of closure of the neural groove.¹ Rupture of these lesions into subarachnoid and intraventricular spaces has been reported rarely and is associated with a myriad of symptoms.²⁻⁴ Although surgical intervention urgently is considered for such events, occasionally a conservative approach may tide over such a catastrophic event. We present a similar rare case in which seizures caused by intraventricular rupture of dermoid were controlled adequately by antiepileptics and demonstrate an 11-year follow up.

CASE REPORT

A 22-year-old female patient presented with history of seizures for 3 months. Over the course of 1 week, the patient noticed an increasing frequency of seizures. On examination, patient was conscious and coherent. There were no focal deficits, and fundus appeared normal. Imaging in the form of computed tomography revealed a hypodense focal lesion in suprasellar area. Magnetic resonance imaging (MRI) confirmed the presence of a ruptured suprasellar dermoid that

■ **BACKGROUND:** Dermoid cysts are rare intracranial lesions that can occasionally rupture into intraventricular and subarachnoid spaces and can present with a myriad of symptoms. The surgical intervention in such cases is demanding, because the disseminated contents are spread widely in intraventricular and subarachnoid space.

■ **CASE DESCRIPTION:** A 22-year-old female patient who presented with history of seizures was diagnosed as having a left parasellar ruptured dermoid. Because there were no features of increased intracranial pressure, conservative management was considered with antiepileptic administration. At 11 years of follow-up, the patient continues to do well on 2 antiepileptics with repeat imaging showing no change in size of lesion.

■ **CONCLUSIONS:** Surgical intervention may not be essential in all patients with ruptured intracranial dermoids. In a few selected patients who do not manifest increased intracranial pressure and show no change in the size of the lesion on sequential radiologic follow-up, conservative management may be attempted, especially when the ruptured intracranial dermoid is located at eloquent areas and with wide dissemination of contents.

appeared hypointense on T1-weighted imaging and showed no enhancement on gadolinium (**Figure 1A–C**). Evidence of rupture was present in form of multiple hypointense focal areas spread along intraventricular, the foramen of Monro, and subarachnoid spaces.

The patient was started on phenytoin for control of seizures. A surgical intervention was not considered at this time, because the patient was preserved clinically, and her seizures were controlled with antiepileptics. A repeat MRI at 6 months time showed persisting intraventricular contents of dermoid and no change in the size of the suprasellar lesion. Two years later, the patient again experienced similar episode of seizures, and clobazam was added. Since, then patient has had intermittent episodes of seizures over the ensuing 11 years and no further extension of lesion on imaging (**Figure 1D–F**).

DISCUSSION

Intracranial dermoid is a rare entity, comprising to 0.04%–0.6% of all brain

tumors.¹⁻³ It contains a stratified squamous epithelial capsule, sebaceous glands, and hair follicles as contents. Although uncommonly reported, these lesions may rupture into the subarachnoid and intraventricular spaces and cause symptoms such as headache, hemiparesis, seizures, features of increased intracranial pressure, and transient cerebral ischemia as the result of vasospasm of vessels and also psychorganic syndromes.^{2,4} Once ruptured, these lesions progress in size gradually and so are taken up for surgical intervention. Radiologic description includes well-defined focal hypodense lesions on computed tomography and hyperintensity on T1-weighted MRI.¹ The enhancement on gadolinium varies from minimal to none. Occasionally in ruptured cysts, one may find fat contents disseminated along the sylvian fissure and within ventricles, as seen in our case.¹⁻³

Previous reports have described surgical intervention for ruptured dermoids, despite difficult resection because of their adherence to surrounding neurovascular bundles. Occasionally patients undergo surgery more

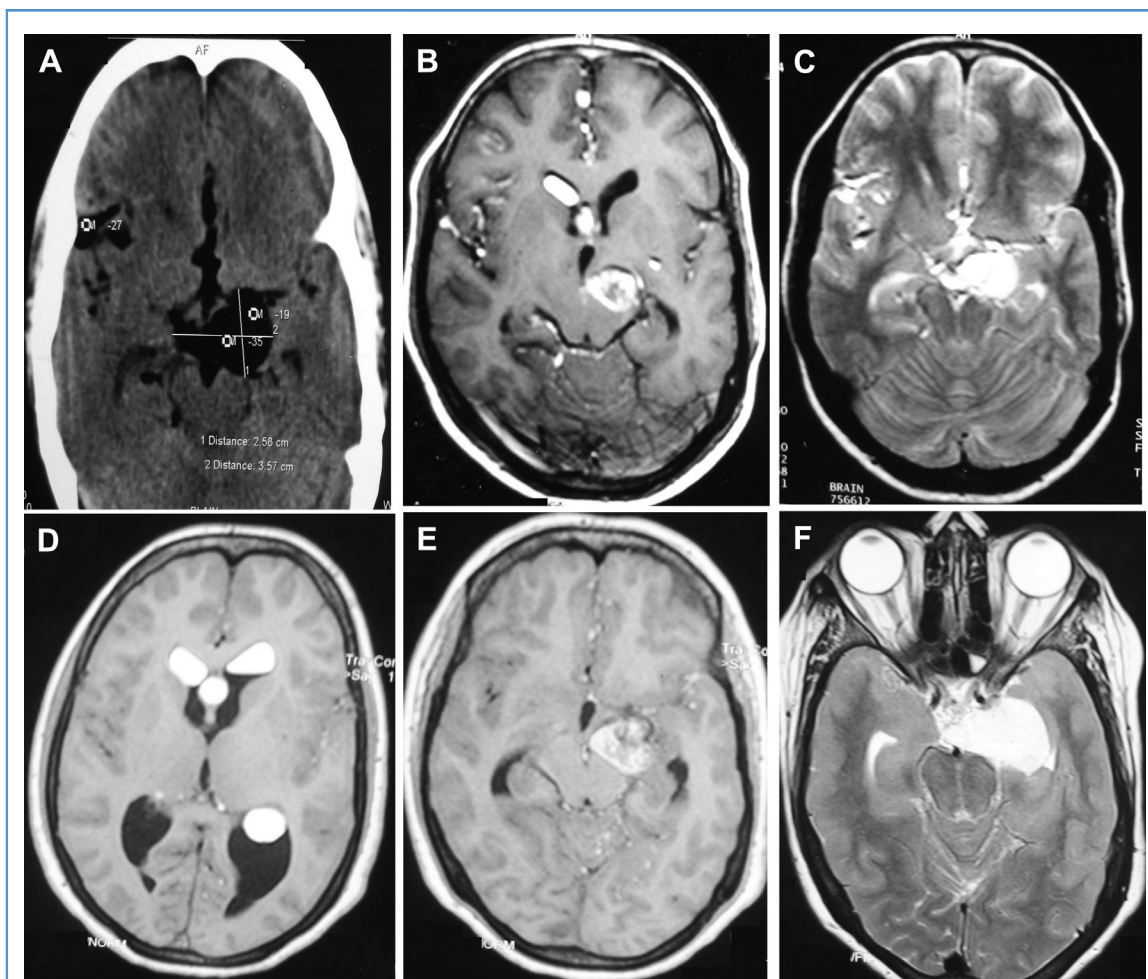


Figure 1. Noncontrast computed tomography (CT) of the head and T1-weighted and T2-weighted magnetic resonance imaging (MRI) show a left parasellar lesion that is (A) hypodense on CT and hyperintense on (B) T1-weighted and (C) T2-weighted MRI with disseminated fat droplets in lateral ventricle, the foramen of Monro, and subarachnoid space. Follow-up MRI after 11 years shows (D) intraventricular hyperintense contents on T1-weighted imaging, (E) parasellar dermoid with moderate enhancement on gadolinium, and (F) hyperintensity on T2-weighted imaging.

than once.^{1,3} We opted for conservative management because of the eloquent location of dermoid at the left parasellar area and diffuse subarachnoid and intraventricular dissemination. It is not known whether this rupture causes acute symptoms or acute presentation occurs as a consequence of a chronic remote rupture. Failure to achieve complete excision of contents of ruptured dermoid at time of surgery, as reported earlier, itself lays the foundation of a trial of rather a conservative approach. The surgical intervention can be limited to those selected patients who experience increased intracranial pressure or refractory seizures.

Although based on single case report, we believe a subset of such patients may suffice with conservative approach and therefore

surgical intervention may not be essential for all ruptured dermoids; however, a close clinical and regular radiologic follow-up is paramount in such patients.

REFERENCES

1. Liu JK, Gottfried ON, Salzman KL, Schmidt RH, Couldwell WT. Ruptured intracranial dermoid cysts: clinical, radiographic, and surgical features. *Neurosurgery*. 2008;62:377-384.
2. Ecker RD, Atkinson JL, Nichols DA. Delayed ischemic deficit after resection of a large intracranial dermoid: case report and review of the literature. *Neurosurgery*. 2003;52:706-710.
3. Martin R, Knone A, Schuknecht B, Kuhn W. Rapid development of occlusion hydrocephalus by intraventricular fat possibly derived from a ruptured

dermoidcyst. *J Neurol Neurosurg Psychiatr*. 1989;52:134-135.

4. Orakcioglu B, Halatsch ME, Fortunati M, Unterberg A, Yonekawa Y. Intracranial dermoid cysts: variations of radiological and clinical features. *Acta Neurochir (Wien)*. 2008;150:1227-1234.

Conflict of interest statement: The authors declare that the article content was composed in the absence of any commercial or financial relationships that could be construed as a potential conflict of interest.

Received 26 October 2015; accepted 12 December 2015

Citation: *World Neurosurg*. (2016) 88:693.e23-693.e24.

<http://dx.doi.org/10.1016/j.wneu.2015.12.049>

Journal homepage: www.WORLDNEUROSURGERY.org

Available online: www.sciencedirect.com

1878-8750/\$ - see front matter © 2016 Elsevier Inc.

All rights reserved.