

[Orthopaedic Surgery]

Spontaneous Bilateral Vertebral Artery Dissection During a Basketball Game: A Case Report

Manuel F. Mas Rodriguez, MD,*[†] Rafael Arias Berrios, MD,[†]
and Eduardo Ramos, MD[†]

Spontaneous vertebral artery dissection accounts for 2% of all ischemic strokes and can occur as a consequence of sports events. We present an unusual case of spontaneous bilateral vertebral artery dissection in a 30-year-old male patient during a basketball game. He developed severe dysphagia, right hemiparesis, and balance dysfunction. We also present a review of the pathology, diagnosis, symptomatology, treatment, prognosis, and occurrence of this entity in sports.

Keywords: spontaneous bilateral vertebral artery dissection; stroke; basketball; sports

Stroke is a rare condition in the young adult population, with fewer than 5% of all strokes occurring in adults younger than 45 years. Vertebral artery dissection (VAD) accounts for 20% of these cases and is a possible result of trauma or chiropractic neck maneuvers. Spontaneous occurrence is rare.

CASE REPORT

A 30-year-old man with an unremarkable medical history was admitted to the emergency room after experiencing numbness on the right side of his face and dizziness while playing basketball. He recounts that he quickly had a transient cold sensation on the right side of his face extending to his right arm and leg. These symptoms were followed by a cramp-like sensation on the right arm and weakness of the right leg. Afterward, the remaining symptoms were weakness/numbness on the right side of the face and difficulty with speech and swallowing. The patient recently had an uneventful upper respiratory tract infection and had no toxic habits. Family history was unremarkable.

In the emergency room, he had right facial asymmetry with tongue deviation to the right and right hemiparesis. Laboratory values and the initial head computed tomography scan were unremarkable. Forty-eight hours later, magnetic resonance

imaging (MRI) of the brain showed multiple recent infarcts at both cerebellar hemispheres, suggestive of a VAD (Figure 1). Magnetic resonance angiography (MRA) showed bilateral VAD (Figure 2). He was anticoagulated and required gastrostomy for severe dysphagia.

The patient was admitted to an inpatient rehabilitation facility where he scored 81 on the Functional Independence Measure¹⁷ at initial evaluation. He was discharged after 16 days, with a score of 107. At 6 months, he was asymptomatic, and continues to work as a security guard.

DISCUSSION

Spontaneous vertebral artery dissection (SVAD) is a nontraumatic tear or disruption in the wall of the vertebral artery.⁴ It is a rare cause of ischemic stroke, comprising 2% of all ischemic strokes.³⁰ However, in patients younger than 45 years, SVAD accounts for 20% of all ischemic strokes, with an annual incidence of 2.6 to 5 in 100,000.³ Recently, the incidence of SVAD has increased, in part because of the higher use of modern diagnostic imaging studies rather than a true increase.¹⁸ There is no clear sex predominance; however, women tend to develop this condition 5 years earlier than men.⁴ Simultaneous damage of multiple vessels can occur in 30% of cases.³ A recent multicenter study evaluating spontaneous cervicocranial

From the [†]Department of Physical Medicine, Rehabilitation & Sports Medicine, School of Medicine, University of Puerto Rico, Guaynabo, Puerto Rico

*Address correspondence to Manuel F. Mas Rodriguez, MD, Physical Medicine and Rehabilitation, School of Medicine, University of Puerto Rico, PO box 365067, San Juan, Puerto Rico, 00969 (e-mail: manuelmasrodriguez@gmail.com).

The authors report the following potential conflicts of interest in the development and publication of this article: Editorial support was provided by grants from the National Center for Research Resources (U54 RR 026139-01A1) and the National Institute on Minority Health and Health Disparities (8U54 MD 007587-03) from the National Institutes of Health.

DOI: 10.1177/1941738114547347

© 2014 The Author(s)

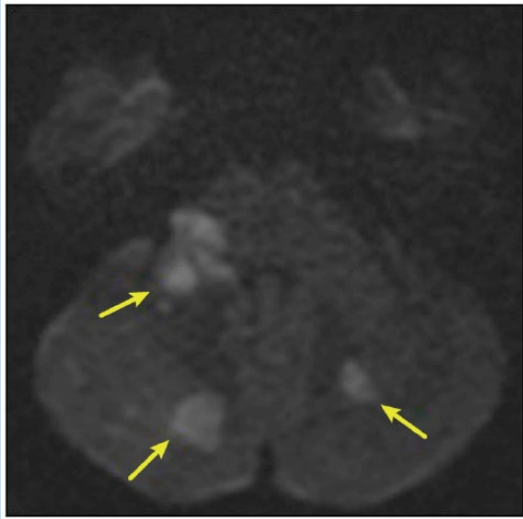


Figure 1. Axial diffusion-weighted image (DWI) demonstrating focal areas of restricted diffusion in both cerebellar lobes, compatible with acute infarcts.

dissections reported that 7% have bilateral vertebral artery involvement.¹⁴ Bilateral VAD has been linked to chiropractic maneuvers of the cervical spine, yet has also been reported as a result of a volleyball game, basketball match, swimming, dancing, or even episodes of mild exertion such as lifting a dog or coughing.^{14,28} Sudden neck movements and stretching can cause arterial tears.⁴

Pathophysiology

The extracranial vertebral artery is vulnerable to dissection in 3 segments throughout its course: at its origin from the subclavian artery, through the spine within the intervertebral foramina, and at the dura when penetrating the cranium.³ This last segment is the most common location for dissection.⁴ Extracranial VAD can extend intracranially in 10% of cases.⁴

Clinical Features

Headaches occur in 50% to 75% of patients who experience SVAD.^{12,18} Pain is often localized at the occipital area unilaterally, yet can occur bilaterally as well. Posterior neck pain can be the initial symptom.⁹ Tinnitus, vertigo, nausea, unilateral facial numbness, and balance disturbance can all be accompanying symptoms.¹⁸

Neurologic sequelae after an SVAD depend largely on the site of brain ischemia. Frequent patterns of ischemic brain damage are cerebellar infarction in the posterior inferior cerebellar artery territory and lateral medullary infarction.⁴ Lateral medullary syndrome (Wallenberg syndrome)¹¹ can manifest as contralateral loss of pain and temperature sensation on the trunk with similar symptoms on the ipsilateral side of the face.⁵ Other findings can include ipsilateral Horner syndrome as well as limb ataxia,

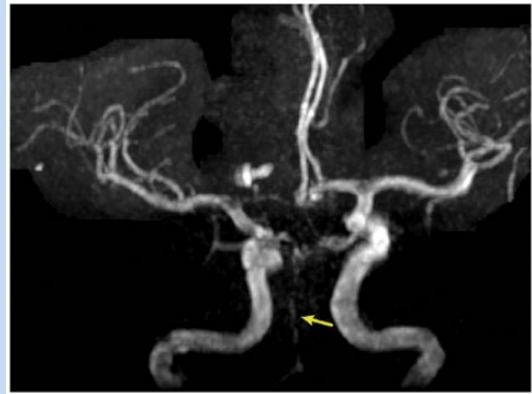

Figure 2. Magnetic resonance angiography image showing almost complete thrombosis of the basilar artery (arrow). This is an extension from the vertebral artery dissection and thrombosis.

vertigo, nystagmus, nausea, vomiting, and dysarthria.³⁸ Dysphagia occurs in 50% to 100% of patients with this syndrome.²⁷

Diagnosis

Diagnosis of SVAD should be considered with symptoms consistent with a cerebrovascular event accompanied by neck and/or occipital pain. Younger patients with no previous risk factors experiencing symptoms after strenuous activities or chiropractic maneuvers should further increase the consideration of SVAD on the differential diagnosis.⁴ Digital subtraction angiography is the gold standard for diagnosis.^{2,3,12,18} The most common findings are an eccentric, smooth, or irregularly tapered stenosis.¹²

MRI and MRA are viable alternatives to digital subtraction angiography for cerebral artery dissection, with a reported sensitivity of 60%.^{4,12,18} More recently, computed tomography angiography is more sensitive (100%) and specific (98%) in the diagnosis of VAD.¹² Color duplex ultrasound is an adjuvant diagnostic tool with MRI and MRA,^{15,32} with a sensitivity of 75% to 86% efficacy. It is now a follow-up examination tool.^{12,17}

The current recommended initial imaging studies are MRI or MRA followed by computed tomography angiography if diagnosis is still in question.^{4,12,18}

Treatment

Management of SVAD focuses on antithrombotic therapy.^{3,4,12,18} Intravenous heparin infusion is commonly used in the acute phase followed by oral anticoagulation with warfarin for the next 3 months.³ If follow-up imaging is unremarkable, anticoagulation can be switched to oral antiplatelet therapy for 3 additional months.¹² A risk factor for anticoagulation is increased bleeding, but several studies have proven no additional risk of hemorrhage with heparin or any other

anticoagulant.^{3,4,12} Controversy exists in the selection of the treatment for SVAD. A Cochrane review found no increased risk of ischemic events or intracranial bleeding with the use of either anticoagulants or antiplatelet agents.²²

Prognosis

Persistent neurologic symptoms after discharge were seen in 42% of patients with this condition.^{6,12} In a prospective study of 169 patients with SVAD, outcome was favorable (modified Rankin scale of 0 or 1) in 82% of patients presenting with ischemic symptoms.¹ Low baseline score on the National Institute of Health Stroke Scale (NIHSS) and younger age were independent predictors of a favorable outcome. Bilateral SVAD was not a factor related to poor clinical outcome.¹ Patients with SVAD have a significantly better modified Rankin scale when compared with those with spontaneous internal carotid artery dissection (sICAD). Recurrent transient ischemic attacks and ischemic strokes were more common in patients with SVAD when compared with those with sICAD. Only higher NIHSS score was seen as a risk factor for increased mortality and poor outcome in this study.³⁵

In general, SVAD has a relatively benign prognosis, with low risk of recurrence of ischemic and/or aneurysmal symptoms.¹⁸

Vertebral Artery Dissection in Sports

To our knowledge, SVAD has only been reported once during or after a basketball game. A professional basketball player developed symptoms of stroke and died 7 days later.⁸ Similar sequelae have been seen after playing golf, including unilateral vertebral artery occlusion, dissection, and/or aneurysm formation.^{13,24,33,37} The proposed mechanism in all these cases coincides to be a mechanical stretch on the vertebral artery caused by sudden neck movement while playing golf, especially during a golf swing. VAD occurs in contact sports such as judo,²⁰ mixed martial arts,³¹ and kickboxing.²³ In these cases, symptoms do not necessarily occur during a match yet are linked to sport contact including grappling or kick to the jaw. Of these, only the judoka suffered immediate neurologic symptoms during contact sports participation. VAD has occurred in Australian football,²⁵ rugby,²⁵ tennis,^{25,29} and soccer.^{26,34} VAD has also been seen in horse racing,¹⁰ weight lifting,²¹ scuba diving,¹⁹ inline skating,¹⁶ trampoline jumping,³⁶ and gymnastics.⁷

CONCLUSION

Although uncommon in the general population, VAD is an important cause of ischemic stroke in young adults, and spontaneous occurrence is rare. However, VAD can occur during sports events and should be considered as a differential diagnosis in young patients with spontaneous occurrence of ischemic stroke symptomatology.

ACKNOWLEDGMENT

The authors thank Gory Ballester-Ortiz, MD, University of Puerto Rico School of Medicine for imaging study analysis.

REFERENCES

- Arnold M, Bousser MG, Fahmi G, et al. Vertebral artery dissection: presenting findings and predictors of outcome. *Stroke*. 2006;37:2499-2503.
- Auer A, Felber S, Schmidauer C, Waldenberger P, Aichner F. Magnetic resonance angiographic and clinical features of extracranial vertebral artery dissection. *J Neurol Neurosurg Psychiatry*. 1998;4:474-481.
- Campos-Herrera CR, Scaff M, Yamamoto FI, Conforto AB. Spontaneous cervical artery dissection: an update on clinical and diagnostic aspects. *Arq Neuropsiquiatr*. 2008;66:922-927.
- Caplan LR. Dissection of brain-supplying arteries. *Nat Clin Pract Neurol*. 2008;4:34-42.
- Chan I. An evidence-based practice for the treatment of lateral medullary syndrome. *Hong Kong J Occup Ther*. 2009;19:50-55.
- Chandra A, Suliman A, Angle N. Spontaneous dissection of the carotid and vertebral arteries: the 10-year UCSD experience. *Ann Vasc Surg*. 2007;21:178-185.
- De Broucker T, Amazan C, Forsy E, Piquet V. Dissection of a vertebral artery during gymnastics [in French]. *Presse Med*. 1990;19:176.
- De Giorgio F, Vetrugno G, De Mercurio D, et al. 1. Dissection of the vertebral artery during a basketball game: a case report. *Med Sci Law*. 2004;44:80-86.
- Dziewas R, Konrad C, Dräger B, et al. Cervical artery dissection—clinical features, risk factors, therapy and outcome in 126 patients. *J Neurol*. 2003;250:1179-1184.
- Fletcher J, Davies PT, Lewis T, Campbell MJ. Traumatic carotid and vertebral artery dissection in a professional jockey: a cautionary tale. *Br J Sports Med*. 1995;29:143-144.
- Fukuoka T, Takeda H, Dembo T, et al. Clinical review of 37 patients with medullary infarction. *J Stroke Cerebrovasc Dis*. 2012;21:594-599.
- Fusco MR, Harrigan MR. Cerebrovascular dissections—a review. Part I. Spontaneous dissections. *Neurosurgery*. 2011;68:242-257.
- Guptha SH, Promnitz AD, Warner A, Baron JC. A 'collapsing' golfer. *Cerebrovasc Dis*. 2005;19:281-282.
- Hassan A, Jadhav V, Zacharatos H, et al. Survival after spontaneous cervicocranial dissections: a multicenter study. *J Stroke Cerebrovasc Dis*. 2013;22:389-396.
- Hoffmann M, Sacco RL, Chan S, Mohr JP. Noninvasive detection of vertebral artery dissection. *Stroke*. 1993;24:815-819.
- Karnik R, Rothmund T, Bonner G, Valentin A, Reuther G. Inline skating as a possible cause of consecutive bilateral vertebral artery dissection. *Acta Neurol Scand*. 2000;101:70-71.
- Keith RA, Granger CV, Hamilton BB, Sherwin FS. The functional independence measure: a new tool for rehabilitation. *Adv Clin Rehabil*. 1987;1:6-18.
- Kim YK, Schulman S. Cervical artery dissection: pathology, epidemiology and management. *Thromb Res*. 2009;123:810-821.
- Konno K, Kurita H, Ito N, Shiokawa Y, Saito I. Extracranial vertebral artery dissection caused by scuba diving. *J Neurol*. 2001;248:816-817.
- Lannuzel A, Moulin T, Amsallem D, Galmiche J, Rumbach L. Vertebral-artery dissection following a judo session: a case report. *Neuropediatrics*. 1994;25:106-108.
- Low A, Dovey J, Ash-Miles J. Vertebral artery dissection in weightlifter with performance enhancing drug use. *BMJ Case Rep*. 2011;2011. pii:bcr09201114768.
- Lyrer P, Engelter S. Antithrombotic drugs for carotid artery dissection. *Cochrane Database Syst Rev*. 2003;(3):CD000255.
- Malek AM, Halbach VV, Phatouros CC, Meyers PM, Dowd CF, Higashida RT. Endovascular treatment of a ruptured intracranial dissecting vertebral aneurysm in a kickboxer. *J Trauma*. 2000;48:143-145.
- Maroon JC, Gardner P, Abula AA, El-Kadi H, Bost J. "Golfer's stroke": golf-induced stroke from vertebral artery dissection. *Surg Neurol*. 2007;67:163-168.
- McCrorry P. Vertebral artery dissection causing stroke in sport. *J Clin Neurosci*. 2000;7:298-300.
- Motohashi O, Kameyama M, Kon H, Fujimura M, Onuma T. A case of vertebral artery occlusion following heading play in soccer [in Japanese]. *No Shinkei Geka*. 2003;31:431-434.
- Oshima F, Yokozeki M, Hamanaka M, et al. Prediction of dysphagia severity: an investigation of the dysphagia patterns in patients with lateral medullary infarction. *Intern Med*. 2013;52:1325-1331.

28. Prabhakar S, Bhatia R, Khandelwal N, Lal V, Das CP. Vertebral artery dissection due to indirect neck trauma: an underrecognised entity. *Neurol India*. 2001;49:384-390.
29. Roualdes G, Lartigue C, Boudigue MD, et al. Dissection of the extracranial vertebral artery after a tennis match [in French]. *Presse Med*. 1985;14:2108.
30. Shi S, Chen K, Ge X, Ni B. Lessons from the diagnosis and treatment of spontaneous vertebral arterial dissection. Case report. *Interv Neuroradiol*. 2009;15:203-208.
31. Slowey M, Maw G, Furyk J. Case report on vertebral artery dissection in mixed martial arts. *Emerg Med Australas*. 2012;24:203-206.
32. Sturzenegger M, Mattle HP, Rivoir A, Rihs F, Schmid C. Ultrasound findings in spontaneous extracranial vertebral artery dissection. *Stroke*. 1993;24:1910-1921.
33. Taniguchi A, Wako K, Naito Y, Kuzuhara S. Wallenberg syndrome and vertebral artery dissection probably due to trivial trauma during golf exercise [in Japanese]. *Rinsbo Shinkeigaku*. 1993;33:338-340.
34. Tekin S, Aykut-Bingol C, Aktan S. Case of intracranial vertebral artery dissection in young age. *Pediatr Neurol*. 1997;16:67-70.
35. von Babo M, De Marchis GM, Sarikaya H, et al. Differences and similarities between spontaneous dissections of the internal carotid artery and the vertebral artery. *Stroke*. 2013;44:1537-1542.
36. Wechsler B, Kim H, Hunter J. Trampolines, children, and strokes. *Am J Phys Med Rehabil*. 2001;80:608-613.
37. Yamada SM, Goto Y, Murakami M, Hoya K, Matsuno A. Vertebral artery dissection caused by swinging a golf club: case report and literature review. *Clin J Sport Med*. 2014;24:155-157.
38. Zorowitz R, Baerga E, Cucurullo S. Types of stroke. In: Cucurullo S, ed. *Physical Medicine and Rehabilitation Board Review*. New York, NY: Demos Medical; 2004:11.

For reprints and permission queries, please visit SAGE's Web site at <http://www.sagepub.com/journalsPermissions.nav>.