

CROSSED APHASIAS CAN BE MIRROR IMAGE OR ANOMALOUS

CASE REPORTS, REVIEW AND HYPOTHESIS

by MICHAEL P. ALEXANDER, MARIA R. FISCHETTE,
and RICHARD S. FISCHER

(From the Aphasia Program, Braintree Hospital, and Department of Neurology, Boston University School of Medicine, Boston, Massachusetts, USA)

SUMMARY

Individual cases of crossed aphasia (aphasia after a right hemisphere lesion in a right-hander) have often been reported. A number of theories have been proposed as to the neuropsychological and/or neurobiological mechanisms that might underlie this phenomenon, but there is still disagreement about its language phenomenology and possible significance. We report 2 cases of crossed aphasia after stroke and review 34 cases from the literature with anatomical documentation of lesion site. Analysis of this material suggests that they represent at least two populations. There may be general conclusions concerning mechanisms of cerebral lateralization to be learned from the investigation of anomalous groups such as crossed aphasics.

INTRODUCTION

Aphasia in a dextral following a lesion of the right hemisphere (crossed aphasia) is rare. Although estimates vary, the incidence is probably between 1 and 2% of all dextral aphasics (Gloning *et al.*, 1969). The neurobiological mechanisms of this phenomenon are unknown, and the neuropsychological correlates are only incompletely understood. We report 2 cases of dextrals with crossed aphasia. One patient had an entirely anomalous aphasia profile; the other had entirely appropriate *intrahemispheric* syndromes, although in the 'wrong' hemispheres. Detailed evaluation is reported both of spoken and written language, as well as for other cerebral functions which are commonly held to be strongly lateralized. Cases in which there is dissociated lateralization of cerebral functions which are usually anatomically linked may illuminate the basic mechanisms of lateralization. Review of the recent literature on this subject suggests some plausible neuropsychological correlations.

Correspondence to: Dr Michael P. Alexander, Braintree Hospital, 250 Pond Street, Braintree, MA 02184, USA.

CASE REPORTS

Case 1

The subject is a 54-yr-old man. He holds a Master's degree and before his illness was employed as an engineer. He speaks only English. He is fully right-handed; for 8 of 8 unimanual tasks (e.g., shaving, throwing a ball, etc.) he indicated a strong right hand preference. One (a son) of 9 primary relatives is left-handed. The patient had no previous neurological history. In January, 1987 he suffered a right hemisphere vascular lesion resulting in fluent aphasia and a left hemiplegia. He was referred to Braintree Rehabilitation Hospital. We examined him at 2½ wks, 15½ wks and 11 months after his stroke.

Neurological examination revealed a severe left hemiparesis, moderate left-sided sensory loss primarily affecting the face and hand, and no visual field defect or hemifield neglect to double simultaneous stimulation. There were no impairments of articulatory agility, speech prosody (including affective elements) or voice volume. Neurological examination of the right half of the body was entirely normal.

Language examination

Spontaneous output was fluent and grammatical but very empty, with much phonemic, neologistic and extended English jargon. When asked why he was in hospital, he replied 'Vaguely it happened without sustenance . . . on a Thursday . . . Friday, no a . . .'. Asked about his work he said, 'Outlining the facon . . . facilities . . . whether it was all retick or all rentrices, but she does not seem to be producing what is going in'.

Auditory comprehension was impaired. The patient correctly pointed to named or described objects before him on a table (10/12). He had difficulty matching parts of objects to their names (6/10). He matched objects to a one sentence functional description (6/6). Body part name matching (11/12) and colour name matching (6/6) were good. He carried out 4/5 one-step commands with objects ('Hand me the comb'). He was unable to follow any more complex commands. Responses to simple yes/no questions were correct, but performance decreased as complexity and length increased. Comprehension of explicitly grammatical material was at chance level.

Naming was very poor (2/7 common objects, no parts of objects, and 2/10 body parts) with perseveration and bizarre responses. The following sample represents a string of 5 body parts that he was asked to name: nose, 'nose'; knee, 'right-handed nose'; shoulder, 'balanced eagle'; (cue: sho . . .), 'shoulder pad'; hair, 'I don't know'; (cue: ha . . .), 'hair'; thigh, 'logging pad'.

Repetition was normal except for occasional bizarre substitutions on the longest items. Recitation was normal. The patient was able to sing with good melody but with paraphasic lyrics.

Narrative writing using the preferred right hand showed preserved orthography, fluency, and paragrammatism. The content was perseverative jargon. The following is his written description of the Cookie Theft picture:

Joe Paris is releveled us of new olding apive which is redgiving is for us on the ricewater us to being giving on the board board stararts. The bying is berried to by going in unside. His is unsunang, us of here hering herrings. The herrist horisting.

Writing to dictation was typical of phonological agraphia (Roeltgen *et al.*, 1983).

Reading aloud was paralexia and deteriorated with length. On the Boston Diagnosis Aphasia Examination (Goodglass and Kaplan, 1983) scores were: symbol-word recognition 9/10, word picture match 8/10, sentence-paragraph comprehension 3/8. Output included semantic and phonemic paralexias as well as extended English jargon. Reading comprehension was adequate at the single word level, but worse than auditory for longer material.

Neuropsychological examination

Ideomotor praxis. Buccofacial and right arm praxis to command were normal. Visuospatial abilities appeared nearly intact. The patient was able to copy simple and complex geometric designs

with no evidence of left-sided neglect. On line bisection he bisected each line normally and worked from left to right. Map Orientation was intact (13/14), as was right/left orientation. His scaled score on the Block Design subtest of the Wechsler Adult Intelligence Scale-Revised was 8 (age-scaled score was 9). On Judgement of Line Orientation he achieved an age corrected score of 24 which places him in the average range. Copying the Rey-Osterrieth Complex Figure was well organized and integrated, as was his copy of the geometric figures of the Wechsler Memory Scale (Visual Reproduction). In contrast, however, his immediate memory of the figures was poor (4/14 details), reflecting such errors as loss of specific internal details and misplacement of single elements. In a 30 min delayed condition, his productions were marred by the intrusion of details from one design into another which resulted in a figure that was a conglomeration of the others.

Attention. Attention and concentration were normal during clinical testing. He was able to maintain his effort and energy and showed no motor impersistence. Visual span of attention was 5 forwards and 4 backwards (Corsi Block Test). On Trails A, he was able to connect the alternating numbers fairly well although his time was rather slow (85 s). Perseveration was prominent throughout.

Affect. Prosody and facial expression were normal.

Emotion. The patient was aware of his deficits but remained unconcerned and unrealistically optimistic. Insight into the implications of his disability seemed reduced despite discussion of his limitations.

Course

When reevaluated at 15 wks postonset, the basic profile described above was unchanged. Spontaneous narrative output showed a less severe jargon aphasia; the major limitation to communication was word finding difficulty. Asked about his major activities, he responded 'Three days of the week I go to the Phys Ed area. I get some . . . some . . . and I get a little training there. The girl there teaches me to . . . what do you call it? Barbara does the . . . (gestures range of motion with his hand). Barbara still is nursing the hand. I still can't get any louse out of the hand. The right shoulder is fine. I just don't have any inkwince for the right foot (he meant the hand). And that's about what I've been doing.' Auditory comprehension was slightly improved. Perseveration was less prominent. Insight was still impaired although the vocational implications of his hemiparesis seemed clearer to him.

When examined at 11 months after onset, he had shown additional interim improvement. Spontaneous output was much less paraphasic. He described the 'Cookie Theft Picture' (Goodglass and Kaplan, 1983) with 'The boy is . . . uh . . . in a chair reaching for a cookie and he's going to fall. The girl is waiting for him also. In the other (gestures to the side) . . . on the kitchen table the wife is drying the dishes but the . . . the sink is flowing over . . . flowing over and the dishes uh . . . uh . . . uh . . . they're running over.' Responsive conversation was also largely free of paraphasias. Confrontation naming and auditory comprehension were equally improved. Writing remained extremely paraphasic and perseverative. His written description of the same picture went 'The boy is getting the spoon cookie jarried the boy is getteing. The girl commed the the cookies. The wife is cutting the wiffing the water is cutting overed.'

CT findings

CT showed a large frontal opercular and perirolandic cortical and subcortical infarct (fig. 1). There was also an extensive lesion in the putamen. The left occipital lobe was longer than the right, and the right frontal lobe was longer than the left. This is the most common profile of CT asymmetries in right-handed men and is considered 'typical' (Koff *et al.*, 1986).

Summary

To infer from the profile of deficits after his right brain injury, this patient has a mixture of anomalous lateralizations. The severe language deficit—both spoken and written—after right brain

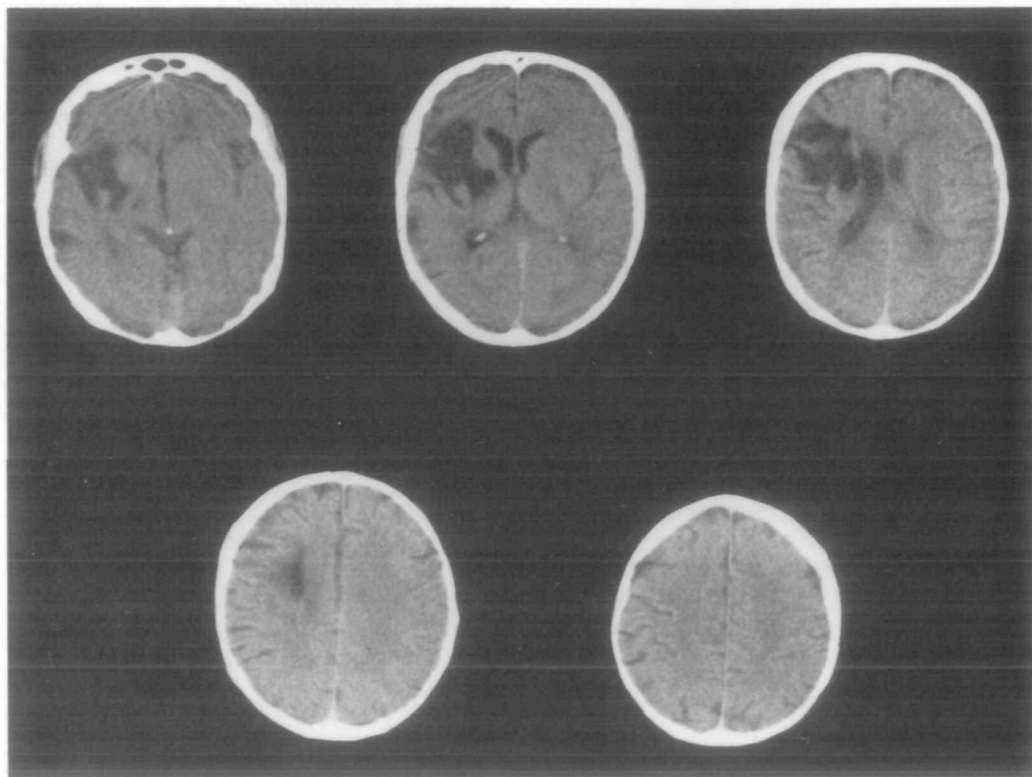


FIG. 1. CT scan of *Case 1* performed 9 months after onset. The structures involved by the lesion are discussed in the text.

injury is, of course, anomalous, and constitutes crossed aphasia. The absence of any ideomotor apraxia is not surprising after right brain injury in a right-hander. The absence of any left hemifield neglect and of configurational difficulties with complex constructional tasks is anomalous after a right brain lesion of the size of this case. The unrealistic optimism and cheerfulness may be an expected effect of major right frontal damage.

Some authors would have rejected this patient for study because of his left-handed son (Joanette *et al.*, 1982), but such exclusion would seem to be excessively strict. A large study of the relationship of handedness to CT asymmetries and to family histories of handedness demonstrated that 22% of right-handed men have a left-hander in the family (Koff *et al.*, 1986). It does not seem reasonable to exclude this patient because 1 of 9 first degree relatives was left-handed, although it is important to note the family history as future studies may identify a role for the factor of family history of handedness in crossed aphasia.

Case 2

The subject is a 65-yr-old college-educated woman who speaks only English. She is fully right-handed, and has no family history of left-handedness. There is no past history of neurological events. In June 1987 she had a subarachnoid haemorrhage from a right posterior communicating artery aneurysm. There was acute hydrocephalus which was treated by a shunt operation. The aneurysm was clipped on day 11. For the next 3 days there was fluctuating alertness, unspecified aphasia and a left hemiparesis. Eight days after the clipping and 19 days after the haemorrhage,

the patient was noted to be speaking 'gibberish'. She was transferred to Braintree Rehabilitation Hospital where we examined her at 4 and at 9 weeks postonset.

Neurological examination revealed a mild left hemiparesis, greater in the leg than the arm, a very mild left-sided sensory loss, and no visual field defects or neglect. There were no impairments in articulatory agility, speech prosody, including affective elements, or voice volume. There were no neurological abnormalities on the right side of the body.

Language examination

Spontaneous output was fluent, grammatical, but moderately empty with significant phonemic and semantic paraphasias. There was mild pressure of speech.

Auditory comprehension was nearly normal. There was mild confusion for the identification of low frequency body parts (10/12). Pointing span was only 2, but the Token Test score was 35/39 correct. Comprehension of complex yes/no questions and a variety of grammatical structures was entirely normal.

Confrontation naming was impaired. Errors were seen in all word categories. Phonemic paraphasias and perseveration were common.

Repetition was markedly abnormal with abundant phonemic paraphasias, omission of words, paraphrasia and perseveration. The following are 3 consecutive examples of sentence repetition.

Dogs chase cats → 'Jags docs case, no a dog will chase cats'. Cows eat grass → 'Crats eat grass'. The car is in the garage → 'The cow is in garage'. Recitation was equally paraphasic. The patient was able to produce adequate melody in song.

Writing using the preferred right hand showed good orthography and word structure. The patient was perseverative but generally could write to dictation and to naming most common nouns. Attempts to produce written sentences were marked by word finding difficulties and paraphrasing of intended syntax. Reading aloud demonstrated severe phonemic paralexia. Reading comprehension was normal.

Neuropsychological examination

Ideomotor praxis. There was no buccofacial apraxia. Very mild limb apraxia was evident, manifested as mild spatial rotation errors and during the use of body parts in representational tasks such as pretending to brush her hair.

Visuospatial. There were no problems with basic visual perception. The patient was able to match geometric designs (Benton Visual Recognition Test 16/16) and there was no evidence of neglect on line bisection or visual cancellation tasks. Drawings from copy of simple geometric designs were moderately good, however, complex constructions were markedly distorted and segmented. On the Rey Osterrieth Complex Figure she used a part-by-part problem solving approach and was unable to reproduce the overall configuration of the design. On the Block Design subtest of the WAIS-R she broke configuration on design 2 and achieved a subscale score of 6 (age scaled score was 7). She could identify 14/14 map locations. There was pronounced right/left confusion.

Attention. Concentration for testing was normal. There was no excess fatigability and no motor impersistence. The patient had a reduced auditory span with a pointing span of only 2 and a digit span of 3.

Affect. The patient had normal affective prosody. There was full range of affect.

Emotion. Mood seemed generally appropriate, but the patient was often labile. She exhibited extremely disinhibited, intrusive and socially inappropriate behaviours. She made many self-deprecatory comments about failures and was often surprisingly frustrated and emotional about minor errors.

Course

When reevaluated at 9 weeks postonset, the basic profile described above was unchanged. Spontaneous narrative output was less paraphasic, but phonemic substitutions still were detected

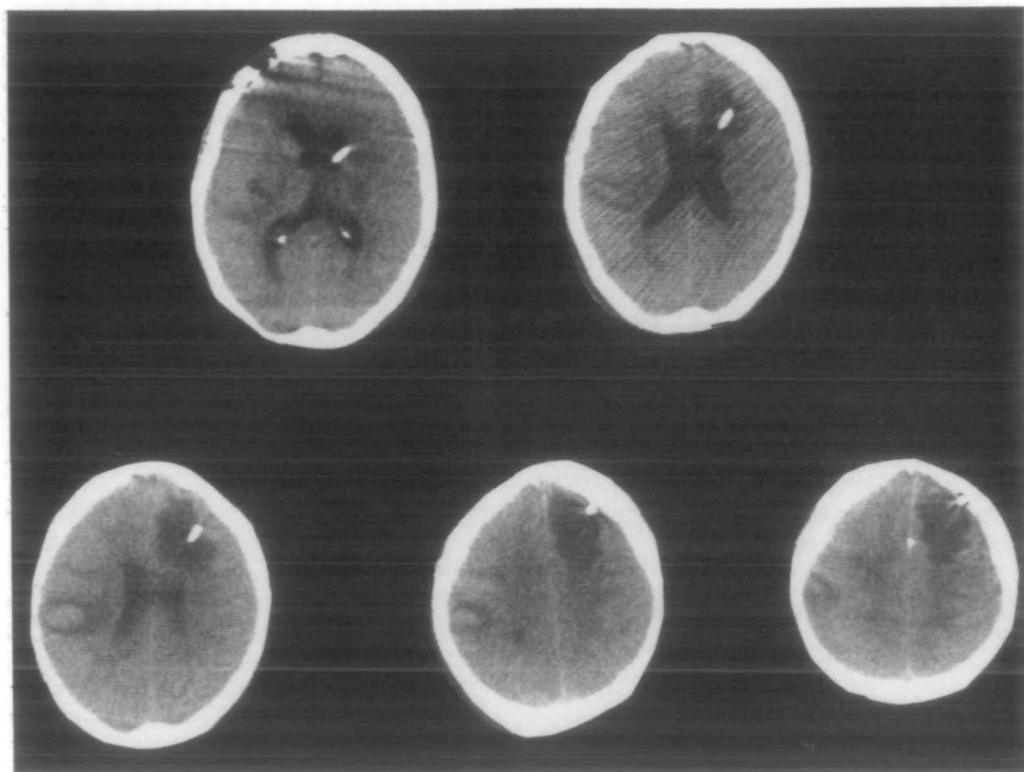


FIG. 2. CT scan of Case 2 performed 3 weeks after onset. The structures involved by the lesions are discussed in the text.

(quote → 'kwait'; garage → 'gurrab'). Word finding deficits were mild. Repetition of phonetically complex targets produced abundant phonemic paraphasia with unsuccessful attempts at correction. Digit span was still 3. Writing was much improved although similar letter substitutions were occasionally made. The motor, sensory and visual impairments had completely cleared.

CT findings

An infarct was seen in the right supramarginal gyrus with extension into the posterior superior paraventricular white matter; there was resolving consolidated blood density (fig. 2). There was a second large infarct in the left frontal lobe, predominantly medial and superior. The intraventricular shunt was in the left frontal horn. Right occipital length was greater than that on the left, and left frontal length was greater than that on the right. For right-handed women this is an uncommon pattern of cerebral asymmetries and is considered 'atypical' (Koff *et al.*, 1986).

Summary

In this patient, to infer from the profile of deficits seen after right parietal and left prefrontal lesions, there is also a mixture of anomalous lateralizations of mental function. The patient has impaired spoken and written language, but also mild ideomotor apraxia and significant configuration visuospatial problems.

Many investigators (Joannette *et al.*, 1982) would be reluctant to include this patient because of the complicated neurological course and because of the presence of bilateral lesions. It is even

possible that the anomalies in this case are intrahemispheric, i.e., the fluent aphasia is secondary to the left prefrontal lesion. We have included this patient because the aphasia emerged in step with the left hemiparesis and the CT images clearly eliminate any further possible lesions.

LITERATURE REVIEW

Kreindler *et al.* (1966) have suggested that there are several potential profiles of anomalous dominances in both right and left-handers. Their conclusions were based on a review of the literature of crossed aphasia and on an analysis of 5 personally examined cases (2 with tumours and 3 with a vascular aetiology, but none with imaging or postmortem localization). They proposed that language, praxis, and visuospatial function could lateralize independently of each other, and that right and left-handers would have different profiles of anomalous lateralization.

Brown and Hécaen (1976) proposed that in crossed aphasics, as in left-handed aphasics and children with acquired aphasia, analysis of aphasia profiles would reveal an excessive number of cases with nonfluent, agrammatic output regardless of the lesion location. They proposed a unifying theory: all 3 groups had incomplete lateralization which was manifested as agrammatism regardless of lesion profile.

Henderson (1983) described 3 right-handed cases with posterior right hemisphere lesions in whom the aphasia profiles—1 conduction and 2 Wernicke's—were appropriate for the lesion locations had they been in the left hemisphere. He reviewed the existing literature on crossed aphasia and observed that there were very few cases in which both detailed language examination and adequate anatomical information were available. Far from finding an excess of nonfluent cases, he observed that the aphasia profile of crossed aphasia was often fluent and that the lesions in the reported cases were appropriately posterior. He proposed that right hemisphere language representation in crossed aphasics mirrors that of the left hemisphere in routine clinical experience. His hypothesis does not speak to the lateralization of other functions. Two of his cases had a mixture of classical left hemisphere signs (aphasia) and right hemisphere signs (severe constructional impairments and left hemineglect). None of the cases had significant apraxia and none had affective prosody disturbances. Attention, motor impersistence and emotional function were not explicitly reported.

Joanette *et al.* (1982) reviewed all 72 reported cases up to 1981; they determined that only 10 were adequate for analysis, and their analysis was not concerned with exact anatomical correlations. They did note that crossed aphasia could be fluent even in the presence of significant hemiparesis (4 of the 10 cases). They also observed that cases could have primarily subcortical or cortical and subcortical lesions. They noted the coincident occurrence of a classical right hemisphere visuospatial disturbance in 6 cases, and the frequent dissociation between the aphasia profiles of spoken versus written language. They considered possible

explanations for crossed aphasia, including incomplete lateralization and mirror image hypotheses, and found evidence to reject them all.

Basso *et al.* (1985a) returned to a model similar to that suggested by Kreindler *et al.* (1966). Their results are largely compatible with Henderson's suggestion that the clinical picture which results from right hemisphere lesions is a mirror of that which would have resulted if the lesion had been on the left. There were, however, 2 cases (nos 2 and 5) with anomalous aphasia/apraxia profiles which are incompatible with the theories of Henderson and Brown and Hécaen. Case 2 of Basso *et al.* had neologistic jargon, mildly impaired auditory comprehension, normal repetition except for very lengthy targets, incomprehensible writing, mild buccofacial apraxia, and no significant visuospatial problems. At 4 months postonset, examination was normal. CT demonstrated an infarct in the frontal operculum without striatal involvement. This case is similar to our Case 1, although milder and with better recovery. In the overall group of cases there were frequent dissociations between written and spoken language. The authors suggested that there may be more than one syndrome of crossed aphasia. This report gives explicit consideration to the possibility that crossed aphasics recover more fully than standard aphasics, but they were unable to compare recovery profiles explicitly enough to reach a definite conclusion about whether their cases had recovered more than expected.

We have attempted to review all cases of crossed aphasia after single right hemisphere strokes reported in the past few years in the English or French literature; 34 cases were included for analysis. These were the cases for which detailed language data were presented and that had CT (or at least radionuclide scans) or postmortem studies were available to provide adequate anatomical information. In one report (Pillon *et al.*, 1979), CT scans for the 2 cases were not published, but for their Case 1 the timing of the CT was appropriate and the description sufficiently detailed for inclusion.

For our primary analysis, language data from the postacute epoch (2 weeks to 2 months) were used when available and clearly identified. The aphasia diagnoses that we have affixed in the tables are ours, although most agree with the diagnoses of the original authors. In several cases reviewed below, only language data from the first few days or months postonset were presented or the time postonset of the reported data was not specified. It may be inappropriate to make judgements about behavioural-anatomical correlations in these circumstances so these cases have been indicated in the tables. One report (Hinson *et al.*, 1984) provides adequate detail, but only for an examination done 6 yrs after onset; we have not included this report. Not all 34 cases provided sufficient information to make a diagnosis for every neuropsychological domain.

We have not included analysis of children with crossed aphasia (e.g., Ferro *et al.*, 1982) because of the additional complication of accounting for developmental differences. For a similar reason we have not included cases of congenital lesions even if they first presented in adulthood, such as arteriovenous malformations

(Demeurisse *et al.*, 1986). We have also not included cases of crossed aphasia after brain tumours (e.g., Larrabee *et al.*, 1982; Aboo-Baker and Labauge, 1987; Martins *et al.*, 1987), not because of questions about the laterality of the lesion but because *intra*hemispheric questions are always ambiguous with infiltrative lesions. There are some cases that we did not include because of the absence of a CT scan (or its equivalent) at a time postonset appropriate to define lesion morphology, even if language description was adequate (e.g., Hamasaki *et al.*, 1987).

From our reading of these cases, 22 out of 34 (Table 1) had aphasia profiles which were within plausible expectations of *intra*hemispheric localization by the standard aphasia correlations (Wechsler, 1976; Urbain *et al.*, 1978; April and Han, 1980; Trojanowski *et al.*, 1980; Carr *et al.*, 1981, Cases 1, 2; Denes and Caviezel, 1981; Yarnell, 1981, Case 1; Brust *et al.*, 1982; Haaland and Miranda, 1982; Henderson, 1983; Kapur and Dunkley, 1984; Sweet *et al.*, 1984; Basso *et al.*, 1985a, Cases 1, 3, 4, 7; Mendez and Benson, 1985, Case 3; Rapcsak *et al.*, 1987; Gonzalez Rothi *et al.*, 1987). The problems inherent in defining any 'standard' aphasia correlations are discussed below. In this group the aphasia profile can be considered to show a *mirror image* (Henderson, 1983) of aphasia after left hemisphere injury. This conclusion represents our interpretation of the cases; the authors of some of these reports did not define their cases as we have interpreted them. For example, Urbain *et al.* (1978) described their case as nonfluent and agrammatic, but that conclusion was based on an examination at only 10 days after the stroke. Even then most of the transcribed output seems to be of sentence length and paragrammatical. By 25 days after the stroke, there was prosodic disturbance and phonemic paraphasia, but fluent language structure. The CT lesion was in the posterior portion of Wernicke's area and the supramarginal and angular gyri.

Twelve cases (Table 2) had fluent aphasia (acutely or within a short interval after onset) despite large suprasylvian and prerolandic or perirolandic lesions (Assal *et al.*, 1981; Carr *et al.*, 1981, Case 3; Yarnell, 1981, Cases 2, 3; Assal, 1982; Pillon *et al.*, 1982; Puel *et al.*, 1982; Habib *et al.*, 1983; Basso *et al.*, 1985a, Cases 2, 5, 6; Fournet *et al.*, 1987). This is an anomalous group. Eleven of these 12 cases had profound jargon agraphia despite, in some cases, relatively minor spoken language disturbances. These 12 cases can be considered to have an *anomalous* aphasia profile in comparison with aphasia after left hemisphere lesions. The denotations *mirror image* and *anomalous* refer only to the aphasia profile, not to any portion of the other neuropsychological deficits that are discussed below.

We believe that our Case 1 is an example of the anomalous type of crossed aphasia. Despite a frontal and striatal lesion, he had fluent jargon aphasic output. Our Case 2 is probably an example (perhaps a double example) of the mirror image type of crossed aphasia. With a lesion in the *right* supramarginal gyrus, she had a fluent aphasia with primarily phonemic output disturbances, exaggerated in repetition, but normal comprehension.

TABLE 1. MIRROR IMAGE CROSSED APHASICS

<i>Case</i>	<i>Language</i>		<i>Apraxia</i>		<i>Summary of published CT</i>
	<i>Spoken</i>	<i>Written</i>	<i>Facial</i>	<i>Limb</i>	
Wechsler (1976)	Broca	Illiterate	Mild	None	Large suprasylvian, perirolandic (only 1 CT slice published)
Urbain <i>et al.</i> (1978)	Conduction	Same	Mild	None	Supramarginal gyrus, angular gyrus, superior temporal gyrus
April and Han (1980)	Broca	Same/ severe	N/A	N/A	Large suprasylvian and frontal opercular
Trojanowski <i>et al.</i> (1980)	Broca	Same	N/A	None	Large prerolandic gyrus
Carr <i>et al.</i> (1981) 1*	Mild Broca	N/A	N/A	N/A	Frontal opercular (isotope scan)
Carr <i>et al.</i> (1981) 2	Probably global	Same	N/A	N/A	Large putaminal haemorrhage
Denes and Caviezel (1981)	Mild Broca to anomic	Same/mild	Mild	None	Frontal cortical and subcortical
Yarnell (1981) 1	Wernicke	Same	N/A	N/A	Superior temporal and supramarginal gyri (isotope scan)
Brust <i>et al.</i> (1982)	Akinetic/ echolalic		Too akinetic to test		Large medial frontal incl. supplementary motor area (postmortem)
Haaland and Miranda (1982)	Conduction	Same/mild	N/A	None	Small posterior peri-insular
Henderson (1983) 1	Conduction	Same	None	None	Inferior parietal and caudate-capsular
Henderson (1983) 2	Wernicke	Same	None	Very mild	Posterior temporal and temporoparietal junction
Henderson (1983) 3	Wernicke	Same	None	Very mild	Inferior parietal; extremely large ventricles
Kapur and Dunkley (1984)**	Mild TCMA	Same	None	None	Large capsularputaminal with PVWM (postmortem)
Sweet <i>et al.</i> (1984)	Wernicke	Same	N/A	None	Superior temporal and supramarginal gyri (postmortem)
Basso <i>et al.</i> (1985a) 1	Mild Broca	Severe	None	None	Large frontal opercular and caudate-capsular
Basso <i>et al.</i> (1985a) 3	Transcortical sensory	N/A	None	Severe	Large medial occipital-temporal and paramedian thalamic
Basso <i>et al.</i> (1985a) 4	Wernicke to conduction	Same	Mild	None	Superior temporal, supramarginal, angular gyri
Basso <i>et al.</i> (1985a) 7	Broca to mild Broca	Same	None	None	Large frontal opercular and peri-insular
Mendes and Benson (1985)*	Conduction	Impaired	None	None	Large supramarginal, angular, and superior temporal gyri
Gonzalez Rothi <i>et al.</i> (1987)**	Normal	Severe	None	None	Lateral parieto-occipital
Rapcsak <i>et al.</i> (1987)	Broca	Same	Severe	Severe	Large suprasylvian, perirolandic and striate-capsular

* Only assessment earlier than 2 weeks. ** Only assessment later than 3 months. N/A = no information available. TCMA = transcortical motor aphasia; PVWM = periventricular white matter.

TABLE 2. ANOMALOUS CROSSED APHASICS

Case	Aphasia		Apraxia		Summary of published CT
	Spoken	Written	Facial	Limb	
Pillon <i>et al.</i> (1979)	Mild TCMA	Jargon	None	None	3 cm, subrolandic, pre- and postrolandic
Assal <i>et al.</i> (1981)	Conduction	Jargon	Mild	None	Large suprasylvian, perirolandic (postmortem)
Assal (1982)*	Conduction	Jargon	Impaired	None	Large frontal opercular, perirolandic and inferior parietal
Carr <i>et al.</i> (1981)	Transcortical sensory	Same/severe	N/A	N/A	Large deep perirolandic
Yarnell (1981) 2*	Conduction	Same/severe	Impaired	N/A	Very large suprasylvian, perirolandic
Yarnell (1981) 3	Wernicke	Same/severe	None	None	Very large perisylvian, perirolandic
Puel <i>et al.</i> (1982)	Broca to conduction	Jargon	Mild	None	Very large perisylvian, perirolandic and frontal
Habib <i>et al.</i> (1983)	Conduction/mild	Jargon/mild	N/A	N/A	Capsular-putaminal with deep frontal PVWM
Basso <i>et al.</i> (1985a) 2	Transcortical sensory	Jargon	Mild	None	Large frontal opercular
Basso <i>et al.</i> (1985a) 5	Anomic	Jargon	Impaired	Impaired	Large perisylvian, perirolandic
Basso <i>et al.</i> (1985a) 6	Wernicke/mild to normal	Jargon	None	None	Capsular-putaminal haemorrhage
Fournet <i>et al.</i> (1987)	Conduction	Jargon	None	None	Large perisylvian, perirolandic and frontal

* Only assessment later than 3 months. TCMA = transcortical motor aphasia. PVWM = periventricular white matter.

Ideomotor apraxia

Eleven of 24 cases (Tables 1, 2; no information in 10 others) showed buccofacial apraxia (Wechsler, 1976; Urbain *et al.*, 1978; Assal *et al.*, 1981; Denes and Caviezel, 1981; Yarnell, 1981, Case 2; Assal, 1982; Puel *et al.*, 1982; Basso *et al.*, 1985a, Cases 2, 4, 5; Rapcsak *et al.*, 1987). Three of 27 (Tables 1, 2; no information in 7 others) showed limb apraxia persistent beyond the acute period (Basso *et al.*, 1985a, Cases 3, 5; Rapcsak *et al.*, 1987). Case review indicates that at least 6 others could plausibly have been expected to show significant limb apraxia with the same lesion in the left hemisphere (Wechsler, 1976; Yarnell, 1981, Case 3; Assal, 1982; Puel *et al.*, 1982; Kapur and Dunkley, 1984; Basso *et al.*, 1985a, Cases 1, 7; Mendez and Benson, 1985).

Visuospatial impairment

Fourteen of 30 (Table 3; no information in 4 others) had significant left neglect and/or major constructional difficulties of a type that suggested right hemisphere lesions (Pillon *et al.*, 1979; Carr *et al.*, 1981, Cases 1, 3; Haaland and Miranda,

1982; Puel *et al.*, 1982; Henderson, 1983, Cases 2, 3; Kapur and Dunkley, 1984; Sweet *et al.*, 1984; Basso *et al.*, 1985a, Cases 3, 7; Mendez and Benson, 1985, Case 3; Fournet *et al.*, 1987; Rapcsak *et al.*, 1987).

Affect and attention

There were scattered examples of inappropriate affect and global attention disorders (Table 4); usually no information was reported. There was no obvious distribution of these deficits with either aphasia group (mirror effect or anomalous). In the 10 cases in which a specific statement was made about affective prosody, there were no abnormalities (Table 4); only 5 of these cases (Pillon *et al.*, 1979; Denes and Caviezel, 1981; Assal, 1982; Puel *et al.*, 1982; Rapcsak *et al.*, 1987) had lesions in either the prerolandic region or the descending motor pathways where impairments in affective prosody might have been expected (Ross, 1981). Specific information about emotional state was generally not provided in these reports.

TABLE 3. HEMIFIELD NEGLECT AND CONSTRUCTIONAL IMPAIRMENTS

<i>Mirror image cases</i>			<i>Anomalous cases</i>		
	<i>Neglect</i>	<i>Spatial</i>		<i>Neglect</i>	<i>Spatial</i>
Henderson (1983) 1	None	Mild (L)	Habib <i>et al.</i> (1983)	Mild	Mild
Henderson (1983) 2	Severe	Severe (R)	Yarnell (1981) 2	Mild	N/A
Henderson (1983) 3	Severe	Severe (R)	Yarnell (1981) 3	N/A	N/A
Brust <i>et al.</i> (1982)	Too akinetic to test		Carr <i>et al.</i> (1981) 3	Severe	N/A
Haaland and Miranda (1982)	None	Moderate (mixed L and R)	Assal (1982)	None	Mild (L)
Yarnell (1981) 1	N/A	N/A	Assal <i>et al.</i> (1981)	Mild	Normal
Denes and Caviezel (1981)	None	Normal	Pillon <i>et al.</i> (1979)	Mild	Impaired
Carr <i>et al.</i> (1981) 1	N/A	Severe (acute only)	Puel <i>et al.</i> (1982)	Severe	Normal
Carr <i>et al.</i> (1981) 2	N/A	Moderate	Basso <i>et al.</i> (1985a) 2	None	None
Urbain <i>et al.</i> (1978)	None	Mild (L)	Basso <i>et al.</i> (1985a) 5	Mild	Moderate
Wechsler (1976)	None	Normal	Basso <i>et al.</i> (1985a) 6	None	None
Sweet <i>et al.</i> (1984)	Severe	Severe	Fournet <i>et al.</i> (1987)	Severe	Moderate (R)
Basso <i>et al.</i> (1985a) 1	None	Mild			
Basso <i>et al.</i> (1985a) 3	Severe	Severe			
Basso <i>et al.</i> (1985a) 4	None	Mild			
Basso <i>et al.</i> (1985a) 7	Severe	Severe			
April and Han (1980)	N/A	Impaired			
Trojanowski <i>et al.</i> (1980)	N/A	N/A			
Kapur and Dunkley (1984)	Severe	Severe			
Mendes and Benson (1985)	Severe	Impaired			
Gonzalez Rothi <i>et al.</i> (1987)	None	None			
Rapcsak <i>et al.</i> (1987)	Moderate	Severe			

TABLE 4. CLASSICAL RIGHT HEMISPHERE SIGNS IN CROSSED APHASIA

Case	<i>Affect</i>				
	<i>Prosody</i>	<i>Mood</i>	<i>Concern</i>	<i>Attention</i>	<i>Music</i>
Henderson (1983) 1	Normal	Normal	Normal	Normal	Normal
Henderson (1983) 2	Normal	Euphoric	Reduced	Normal	Normal
Henderson (1983) 3	Normal	Normal	N/A	Normal	Normal
Denes and Caviezel (1981)	Normal	Normal	Normal	Normal	N/A
Assal (1982)	Normal	Normal	N/A	Normal	N/A
Urbain <i>et al.</i> (1978)	Normal	Normal	N/A	N/A	N/A
Puel <i>et al.</i> (1982)	Normal	Normal	Normal	Normal	N/A
Pillon <i>et al.</i> (1979) 1	Normal	Euphoric	Reduced	Normal	N/A
Fournet <i>et al.</i> (1987)	Normal	Normal	Normal	Impaired	N/A
Yarnell (1981) 3	N/A	N/A	N/A	Impaired	N/A
Basso <i>et al.</i> (1985a) 3	N/A	N/A	N/A	Impaired	N/A
Rapcsak <i>et al.</i> (1987)	Normal	Normal	N/A	N/A	N/A

There was also too little systematic information about CT asymmetries to reach any conclusions about a relationship with aphasia type. Henderson *et al.* (1984) have reviewed the CT asymmetries in many of the modern cases. They concluded that there was no relationship between the occurrence of crossed aphasia and the pattern of cerebral asymmetries; the majority of cases available for review seemed to be of the mirror effects variety. Our anomalous case (Case 1) had typical asymmetries and the mirror case (Case 2) had reversed asymmetries. It remains to be demonstrated whether cerebral asymmetries might define a relationship between the type of crossed aphasia and the underlying gross cerebral morphology.

DISCUSSION

Level of analysis of reported cases

In the literature on crossed aphasia, there are at least four different levels of analysis in different reports. First, many reports describe cases from an anecdotal standpoint as virtual curiosity pieces. Further reports of this type do not appear necessary. Secondly, some reports attempt to define the incidence of crossed aphasia; most reports, ours included, are not population studies and cannot inform about incidence. Most authorities seem to accept the 1-2% figure of Gloning *et al.* (1969). Thirdly, a few reports explicitly grapple with the biological or neuropsychological mechanisms of cerebral localization of function as implied by these unusual cases. This level of analysis requires explicit description of the cognitive operations other than language, as well as the subcomponents of language. This is the challenge of Kreindler *et al.* (1966). Basso *et al.* (1985a) have an excellent consideration of this problem, as do many of the reports that we designated anomalous. Fourthly, there is a level of analysis that suggests that these cases of radical exception to standard cerebral localization may define the

boundaries along which cognitive functions dissociate in the less radically, but still exceptional, atypical left hemisphere lesion cases (Basso *et al.*, 1985b). This level of analysis has not been investigated systematically, although its potential importance has been recognized (Caplan, 1987).

Prevalence of anomalous profiles in crossed aphasia

Reconciling the disparate observations and levels of analysis is not entirely possible at present, but some tentative conclusions about crossed aphasia may be advanced. Detailed literature review does support Henderson's (1983) conclusion that there is an overall conformity between the clinicoanatomical relationships of crossed aphasia and classical aphasia. There are two elements to this overall conformity. First, the aphasia profile is 'appropriate' for the intrahemispheric lesion location. Secondly, the components of the aphasic profiles—spoken and written—are congruent with the classical profiles. That there might be an overall conformity of the language disorder says nothing about conformity of any other neuropsychological deficits.

In our review, however, 35% of the reported cases had dramatic language and/or clinicoanatomical anomalies. Among these anomalous crossed aphasia cases there is some overall similarity, but they are certainly not uniformly or even predominantly nonfluent cases as asserted by Brown and Hécaen (1976). They are, in fact, uniformly fluent. Both elements of the overall conformity may be anomalous. First, language profile is anomalous given the intrahemispheric locus of the lesion; obviously, analysis at this level motivated our designation of the cases. All 12 patients had fluent, often paraphasic, language, despite predominantly anterior or deep and anterior lesions. The second factor defining conformity is congruity of the components of the aphasia profile whatever the lesion site. In some cases—our Case 1, Case 2 of Basso *et al.* (1985a), and the case of Habib *et al.* (1983), for example—written and spoken language were equally fluent and paraphasic, and comprehension of written and spoken language was similar. But other cases—Case 5 of Basso *et al.* (1985a), the case of Fournet *et al.* (1987), perhaps the case of Assal (1982) and also Case 1 of Pillon *et al.* (1979)—had anomalous dissociations between impairments in written and spoken language. These patients are doubly anomalous, both in the intrahemispheric dimension and in the internal relationships of the language components. Perhaps in this subset of anomalous crossed aphasia, the central perirolandic regions of the right hemisphere have a specific but restricted role in language, primarily at a phonemic level. This would account for the several 'unexpected' conduction aphasics whose primary language abnormality was phonemic substitution in spoken and written language. Alternatively, perhaps these cases have an even more discretely restricted impairment at the phoneme-grapheme correspondence level—hence the large number of phonemic jargon agraphics.

Thus far we have only used 'anomalous' to refer to the aphasic profile. The patients had other neuropsychological deficits that potentially might be equally

atypical. Praxis, particularly limb praxis, seems frequently to be spared in cases of crossed aphasia. Perhaps, as a general rule, limb praxis is more strongly related to handedness than to spoken language. Thus in these cases limb praxis would segregate with handedness and not aphasia. This could be compatible with case reports of persistent severe limb apraxia accompanied by little (Selnes *et al.*, 1982) or no (Junqué *et al.*, 1986) aphasia after major left hemisphere infarcts in right-handers.

Superimposition of impairments typical of right hemisphere damage has been noted in about one-third of reported cases. These impairments can be either in global or hemifield attention or in visuospatial functions. The presence of 'typical' right hemisphere lesion disturbances has been described both in the mirror and the anomalous aphasic cases. The report of Basso *et al.* (1985b) again speaks to the need for a general account for all anomalies. In their report, there were 6 cases with language disorders that were 'exceptions' after left hemisphere lesions with intrahemispheric lesion profiles similar to our Case 1. Detailed information is provided on 2 cases. Case 18 had a score on a test of constructional ability of 0/20; Case 20 had a similar lesion and a similar, but milder, aphasia with a score of 18/20 on the same test. It seems that spatial functions may have their own independent mechanism for anomalous development, but any specific relationship of impaired spatial functions to any or all of the aphasia profiles has not been demonstrated. Likewise, no specific relationship has been suggested between the attentional and emotional disturbances and the aphasia in these cases.

Problems in defining 'exceptions' and anomalous profiles

There are several partly related methodological and theoretical problems that profoundly confound any conclusions, including ours, about anomalies in crossed aphasia. The first problem is the absence of any acceptable metric for what is or is not anomalous for standard aphasia (left hemisphere lesions in right-handers). The label 'anomalous' often simply depends upon the diagnostic system used. Strictly taxonomic systems (Kertesz, 1979) will find a typical label for virtually all cases, with 'anomic aphasia' serving as a safe harbour for otherwise heterogeneous cases. There will be no anomalous cases in this taxonomy. Systems based on venerable but clinical notations of the classical syndromes (Goodglass and Kaplan, 1983) may find a typical label for only 40% of cases (Albert *et al.*, 1981). In a recent and very careful analysis (Basso *et al.*, 1985b) of a large population of standard aphasics (excluding cases with solely subcortical lesions), only 17% had aphasia profiles that did not conform to the classical syndromes. Among these nonconforming cases, there were numerous different variations from 'anticipated' findings, although 6 of the 36 exceptions were fluent aphasics (a variety of syndrome diagnoses) despite exclusively anterior and suprasylvian lesions. The 12 anomalously fluent crossed aphasia cases reviewed here were, on the contrary, more—although not entirely—homogeneous, and they were 100% of the 'intra-hemispheric exceptions'.

There is one important limitation to the interpretation of all studies to date of the 'exceptions' to aphasia classification, namely the absence of adequate consideration of the specific contributions of subcortical lesion sites to the clinical profile. Even the otherwise estimable report of Basso *et al.* (1985b) gives sparse attention to the subcortical extent of lesions and even that attention does not differentiate reliably between periventricular extent and shallower subcortical involvement. There is ample evidence that specific subcortical lesion profiles have specific correlations with aphasia profiles (Damasio *et al.*, 1982; Alexander *et al.*, 1987; Alexander, 1988). We believe that several of the exceptions in the report of Basso *et al.* (1985b) might be less exceptional with consideration of subcortical lesion extent in addition to their focus on cortical lesion site. Is it exceptional to find Broca's aphasia without a lesion in Broca's area if there is a lesion in the entire anterior periventricular white matter (Knopman *et al.*, 1983)? This is not an argument to expand the number of classical syndromes, rather an argument to consider all elements of anatomy before discarding it as an explanatory tool. In our literature review, we attempted to consider all aspects of anatomy. For instance, the case of Assal *et al.* (1981) might be anomalous precisely because of the subcortical lesion extent into deep frontal lesions.

The second problem in interpretation of anomalies is syndrome drift. Not only must a syndrome be specified as 'appropriate' for a given anatomical location, but it also must be specified as 'appropriate' for a given time in the course of the illness. Kertesz and McCabe (1977) considered this issue explicitly, demonstrating a number of common syndrome shifts over time. Mohr (1976) has reflected on this problem for the specific case of Broca's aphasia. The conclusion from Mohr seems inescapable: persistent Broca's aphasia is usually a late-appearing syndrome of partial recovery. Similar conclusions about anomia as the residual profile of acute Broca's aphasia are reached in the follow-up studies of Kertesz and McCabe (1977). Others have explicitly (Prins *et al.*, 1978; Knopman *et al.*, 1983) or implicitly (Leischner, 1976) demonstrated the same phenomenon.

For purposes of anatomical correlations, Mazzocchi and Vignolo (1979) proposed a set of rules to deal with syndrome shift that we found sensible and attempted to follow. The strongest and most direct correlations were between postacute images (more than 3 weeks postonset) and postacute behaviours (3 weeks to 2 months). Admittedly, the interval designated 'postacute' is arbitrary and may be 2 months, 3 months or more. In some cases, the very late profile may not differ at all from the postacute profile, but study of any epoch other than the postacute should be clearly designated. Perhaps the issue of time postonset is a factor in the report of Basso *et al.* (1985b). For instance, 4 of 9 Wernicke's aphasics with anterior lesions were first evaluated at more than 5 months postonset. In our review of the literature on crossed aphasia, we have indicated in the tables any case for whom the available language examination was not from the postacute interval. As described above, when both the acute and postacute intervals were described, we took the postacute even if the original authors relied on the acute.

The third methodological problem is that most studies of crossed aphasia have attempted to classify only into the classical syndromes. Whatever are the merits of classical syndromes as clinical diagnoses in neurology (Benson, 1979), they are certainly too polytypic to serve as the elemental units of disordered language (Caramazza, 1984; Schwartz, 1984). It is a testimony to the clinical validity of the syndrome that 83% of all cases with single lesions might find a home within one of them, but we have argued in other contexts (Alexander, 1988) that it is more profitable to analyse brain behaviour relationships at the level of individual speech or language signs than at the level of the syndrome. Robust biological relationships may be found between specific, perhaps overlapping, distributed anatomical systems and specific speech or language systems. Thus far this argument seems most forcefully made for subcortical structures and their cortical projections (Alexander and Naeser, 1988). For all the cases of crossed aphasia that we reviewed, we attempted this type of sign-by-region analysis when sufficient language detail and lesion image were presented. We do not suppose that the individual clinical signs that we have analysed are the elemental units of language disorder. They are, however, closer than syndromes. Hence, to repeat, the syndrome designations on the tables are to orientate the reader to the general profile of language to facilitate review.

A final problem is the possibility that recovery is more rapid or more complete in crossed aphasics, but there is, as yet, inadequate analysis of enough cases over time to be certain. There are isolated cases in which recovery seems quite exceptional. The patient reported by Denes and Caviezel (1981) could be interpreted as an appropriate postacute syndrome but with exceptionally complete recovery at 6 months. In our Case 2 recovery was prompt, but probably not unexpected for a small haemorrhagic infarct in the supramarginal gyrus. In the very anomalous cases, it is difficult to know how to judge 'expected' recovery.

With all of those caveats about what is 'appropriate' or 'exceptional' or a 'precise fit' or 'standard', can we argue for 'anomalies' at all? The patients are statistically anomalous by being aphasic at all after right hemisphere lesions. With characterization of aphasics at the gross level of the syndrome and with little consideration of subcortical anatomy, only 17% of standard cases cannot be accounted for, and only 6 (examples 15-21, 3% of all cases) of the 'exceptions' of Basso *et al.* (1985b) had clinicoanatomical profiles very similar to our anomalous cases, that is, fluent paraphasic aphasias with suprasylvian, primarily perirolandic lesions generally similar to our Case 1. In comparison, 35% of crossed aphasia cases cannot be accounted for even with consideration at the subsyndromic level and with explicit consideration of subcortical anatomy. We believe that this argues for significant anomalies among crossed aphasics. Further, the very problem of defining anomalies emphasizes the importance of searching for an explanation of all 'anomalous' cases whether the lesion is right or left. Crossed aphasics may simply offer greater opportunity to explore this issue than 'standard' aphasics.

Potential general value in the study of crossed aphasics

It is possible that the neurobiological rules (assuming that some exist) which govern the separate lateralizations of separable cerebral functions can be uncovered by asking the same experimental questions of other groups of atypical patients. There are reports of crossed apraxics (Mani and Levine, 1987). There are reports of right-handers with left hemisphere lesions without aphasia but with severe spatial and/or limb praxis disturbances (Heilman *et al.*, 1974; Selnes *et al.*, 1982; Junqué *et al.*, 1986). These patients presumably would have presented with crossed aphasia had they suffered right hemisphere lesions. Perhaps even left-handers with unilateral brain lesions may segregate into similar groups: one group organized precisely as right-handers (Naeser and Borod, 1986), a second group with mirror effects for all cognitive domains, that is, in which the anomalies are only *interhemispheric* (Taylor and Solomon, 1979; Delis *et al.*, 1983), and a third, and probably smallest group, with anomalous lateralizations and localizations (Heilman *et al.*, 1973; Case 2 of Archibald, 1987).

CONCLUSIONS

It seems then that there are several possible partitions of lateralized functions, although not precisely along the lines suggested by Kreindler *et al.* (1966). There may be several testable hypotheses about the linkage of dissociated functions in crossed aphasics. (1) In some crossed aphasics the phonological and semantic levels of language may be lateralized differently. (2) Limb praxis may be more strongly correlated with handedness than is language. (3) Buccofacial praxis may be more closely correlated with the hemisphere responsible for speaking. (4) The bizarre quality of unspoken output in some cases may be associated with superimposed right hemisphere-like attentional impairments. (5) Affective prosody and melody in song may always lateralize together. There are undoubtedly other possibilities.

Investigation of these questions will require more precision in specifying the level of analysis than has hitherto been common in the study of crossed aphasics. It will require separate delineation of spoken language and written language, at the level of phonology, phonemics, semantics, and syntax, as well as of buccofacial praxis, limb praxis, visuospatial function (also no doubt subdivisible), hemifield attention, global attention, affect (including prosody), and conscious emotional function. Analysis of lesion location will require consideration of subcortical as well as cortical structures. With anatomy and behaviours defined, it will be possible to ask if the specific profiles (sign-by-sign, not at the level of the syndrome) fit those that might be 'expected' after the same lesion in the left hemisphere.

Beyond just crossed aphasia, similar questions can be asked of all cases with single lesions. Are the lateralized cerebral functions in the 'expected' hemisphere? Anomalies here are the most obvious, but perhaps the least interesting. If lateralization is anomalous, what functions have an obligatory lateralization with

or across from each other? Within whichever hemisphere the functions are lateralized, is the intrahemispheric locus of function 'expected'? Again, within either hemisphere, what functions have obligatory relationships to each other? Does interhemispheric anomalous lateralization permit more intrahemispheric anomalous localization? Anomalies in intrahemispheric localization are more dramatic when interhemispheric lateralization is normal—the 'exceptions'—but there is, as yet, no evidence that the intrahemispheric anomalies are fundamentally different if they are in the 'expected' hemisphere or not. These are the real challenges of crossed aphasia.

ACKNOWLEDGEMENTS

We thank Dr Yves Joanette and Dr Douglas I. Katz for their helpful suggestions. This work was presented in part at the meeting of the American Academy of Aphasia held in Phoenix, Arizona, in October, 1987.

REFERENCES

- ABOO-BAKER F, LABAUGE R (1987) Alexie et agraphie par lésion de l'hémisphère droit chez un droitier non aphasique. *Revue Neurologique*, **143**, 294–297.
- ALBERT ML, GOODGLASS H, HELM-ESTABROOKS N, RUBENS AB, ALEXANDER MP (1981) *Clinical Aspects of Dysphasia*. New York: Springer, pp. 17–19.
- ALEXANDER MP (1988) Variability in the syndrome of Broca's aphasia in a rehabilitation hospital: implications for research strategies. *Aphasiology*, **2**, 219–223.
- ALEXANDER MP, NAESER MA, PALUMBO CL (1987) Correlations of subcortical CT lesion sites and aphasia profiles. *Brain*, **110**, 961–991.
- ALEXANDER MP, NAESER MA (1988) Cortical-subcortical differences in aphasia. *Research Publications: Association for Research in Nervous and Mental Disease*, **66**, 215–228.
- APRIL RS, HAN M (1980) Crossed aphasia in a right-handed bilingual Chinese man: a second case. *Archives of Neurology, Chicago*, **37**, 342–346.
- ARCHIBALD YM (1987) Persisting apraxia in two left-handed, aphasic patients with right-hemisphere lesions. *Brain and Cognition*, **6**, 412–428.
- ASSAL G (1982) Étude neuropsychologique d'une aphasie croisée avec jargonographie. *Revue Neurologique*, **138**, 507–515.
- ASSAL G, PERENTES E, DERUAZ J-P (1981) Crossed aphasia in a right-handed patient: postmortem findings. *Archives of Neurology, Chicago*, **38**, 455–458.
- BASSO A, CAPITANI E, LAIACONA M, ZANOBIIO ME (1985a) Crossed aphasia: one or more syndromes? *Cortex*, **21**, 25–45.
- BASSO A, LECOURS AR, MORASCHINI S, VANIER M (1985b) Anatomoclinical correlations of the aphasias as defined through computerized tomography: exceptions. *Brain and Language*, **26**, 201–229.
- BENSON DF (1979) *Aphasia, Alexia and Agraphia*. New York and Edinburgh: Churchill Livingstone, pp. 65–71.
- BROWN JW, HÉCAEN H (1976) Lateralization and language representation: observations on aphasia in children, left-handers, and 'anomalous' dextrals. *Neurology, Minneapolis*, **26**, 183–189.
- BRUST JCM, PLANK C, BURKE A, GUOBADIA MMI, HEALTON EB (1982) Language disorder in a right-hander after occlusion of the right anterior cerebral artery. *Neurology, New York*, **32**, 492–497.

- CAPLAN D (1987) *Neurolinguistics and Linguistic Aphasiology: An Introduction*. Cambridge: Cambridge University Press, pp. 237-255.
- CARAMAZZA A (1984) The logic of neuropsychological research and the problem of patient classification in aphasia. *Brain and Language*, **21**, 9-20.
- CARR MS, JACOBSON T, BOLLER F (1981) Crossed aphasia: analysis of four cases. *Brain and Language*, **14**, 190-202.
- DAMASIO AR, DAMASIO H, RIZZO M, VARNEY N, GERSH F (1982) Aphasia with nonhemorrhagic lesions in the basal ganglia and internal capsule. *Archives of Neurology, Chicago*, **39**, 15-20.
- DELIS DC, KNIGHT RT, SIMPSON G (1983) Reversed hemispheric organization in a left-hander. *Neuropsychologia*, **21**, 13-24.
- DEMEURISSE G, HUBLET C, COEKAERTS MJ, DEROUCK M, CAPON A (1986) Assessment of hemispheric dominance for language in crossed aphasia by two atraumatic methods. *Cortex*, **22**, 305-311.
- DENES G, CAVIEZEL F (1981) Dichotic listening in crossed aphasia: 'paradoxical' ipsilateral suppression. *Archives of Neurology, Chicago*, **38**, 182-185.
- FERRO JM, MARTINS IP, PINTO F, CASTRO-CALDAS A (1982) Aphasia following right striato-insular infarction in a left-handed child: a clinico-radiological study. *Developmental Medicine and Child Neurology*, **24**, 173-182.
- FOURNET F, VIRAT-BRESSAUD ME, GUARD O, DUMAS R, AUPLAT P, MARCHAL G (1987) Alexie-agraphie croisée chez un droitier. *Revue Neurologique*, **143**, 214-219.
- GLONING I, GLONING K, HAUB G, QUATEMBER R (1969) Comparison of verbal behavior in right-handed and non-right-handed patients with anatomically verified lesion of one hemisphere. *Cortex*, **5**, 43-52.
- GONZALEZ ROTH LJ, ROELTGEN DP, KOOISTRA CA (1987) Isolated lexical agraphia in a right-handed patient with a posterior lesion of the right cerebral hemisphere. *Brain and Language*, **30**, 181-190.
- GOODGLASS H, KAPLAN E (1983) *The Assessment of Aphasia and Related Disorders*. Second edition. Philadelphia: Lea and Febiger.
- HAALAND KY, MIRANDA F (1982) Psychometric and CT scan measurements in a case of crossed aphasia in a dextral. *Brain and Language*, **17**, 240-260.
- HABIB M, JOANETTE Y, ALI-CHERIF A, PONCET M (1983) Crossed aphasia in dextrals: a case report with special reference to site of lesion. *Neuropsychologia*, **21**, 413-418.
- HAMASAKI T, SUZUKI K, HIRAKAWA K, IMAHORI Y, NAKAJIMA S (1987) Un cas japonais d'aphasie croisée chez un droitier. *Revue Neurologique*, **143**, 47-54.
- HEILMAN KM, COYLE JM, GONYEA EF, GESCHWIND N (1973) Apraxia and agraphia in a left-hander. *Brain*, **96**, 21-28.
- HEILMAN KM, GONYEA EF, GESCHWIND N (1974) Apraxia and agraphia in a right-hander. *Cortex*, **10**, 284-288.
- HENDERSON VW (1983) Speech fluency in crossed aphasia. *Brain*, **106**, 837-857.
- HENDERSON VW, NAESER MA, WEINER JM, PIENIADZ JM, CHUI HC (1984) CT criteria of hemisphere asymmetry fail to predict language laterality. *Neurology, Cleveland*, **34**, 1086-1089.
- HINSON DA, WESTMORELAND DE, CARROLL WA, BODMER BA (1984) Persistent Broca's aphasia after right cerebral infarction in a right hander. *Neurology, Cleveland*, **34**, 387-389.
- JOANETTE Y, PUEL M, NESPOULOUS J-L, RASCOL A, ROCH LECOURE A (1982) Aphasie croisée chez les droitiers. I. Revue de la littérature. *Revue Neurologique*, **138**, 575-586.
- JUNQUÉ C, LITVAN I, VENDRELL P (1986) Does reversed laterality really exist in dextrals? a case study. *Neuropsychologia*, **24**, 241-254.
- KAPUR N, DUNKLEY B (1984) Neuropsychological analysis of a case of crossed dysphasia verified at postmortem. *Brain and Language*, **23**, 134-147.
- KERTESZ A (1979) *Aphasia and Associated Disorders*. New York: Grune and Stratton, pp. 75-119.
- KERTESZ A, MCCABE P (1977) Recovery patterns and prognosis in aphasia. *Brain*, **100**, 1-18.

- KREINDLER A, FRADIS A, SEVASTOPOL N (1966) La répartition des dominances hémisphériques. *Neuropsychologia*, **4**, 143-149.
- KNOPMAN DS, SELNES OA, NICCUM N, RUBENS AB, YOCK D, LARSON D (1983) A longitudinal study of speech fluency in aphasia: CT correlates of recovery and persistent nonfluency. *Neurology, Cleveland*, **33**, 1170-1178.
- KOFF E, NAESER MA, PIENIADZ JM, FOUNDAS AL, LEVINE HL (1986) Computed tomographic scan hemispheric asymmetries in right- and left-handed male and female subjects. *Archives of Neurology, Chicago*, **43**, 487-491.
- LARRABEE GJ, KANE RL, RODGERS JA (1982) Neuropsychological analysis of a case of crossed aphasia: implications for reversed laterality. *Journal of Clinical Neuropsychology*, **4**, 131-142.
- LEISCHNER A (1976) Aptitude of aphasics for language treatment. In: *Recovery in Aphasics*. Edited by Y. Lebrun and R. Hoops. Amsterdam: Swets and Zeitlinger, pp. 112-123.
- MANI RB, LEVINE DN (1987) Crossed buccofacial apraxia. *Neurology, Cleveland*, **37**, Supplement 1, 126.
- MARTINS IP, FERRO JM, TRINDADE A (1987) Acquired crossed aphasia in a child. *Developmental Medicine and Child Neurology*, **29**, 96-109.
- MAZZOCCHI F, VIGNOLO LA (1979) Localisation of lesions in aphasia: clinical-CT scan correlations in stroke patients. *Cortex*, **15**, 627-653.
- MENDEZ MF, BENSON DF (1985) Atypical conduction aphasia: a disconnection syndrome. *Archives of Neurology, Chicago*, **42**, 886-891.
- MOHR JP (1976) Broca's area and Broca's aphasia. In: *Studies in Neurolinguistics*, Volume 1. Edited by H. Whitaker and H. A. Whitaker. New York and London: Academic Press, pp. 201-235.
- NAESER MA, BOROD JC (1986) Aphasia in left-handers: lesion site, lesion side, and hemispheric asymmetries on CT. *Neurology, Cleveland*, **36**, 471-488.
- PILLON B, DESI M, LHERMITTE F (1979) Deux cas d'aphasie croisée avec jargonographie chez des droitiers. *Revue Neurologique*, **135**, 15-30.
- PRINS RS, SNOW CE, WAGENAAR E (1978) Recovery from aphasia: spontaneous speech versus language comprehension. *Brain and Language*, **6**, 192-211.
- PUEL M, JOANETTE Y, LEVRAT M, NESPOULOUS J-L, VIALA M-F, ROCH LECOURS A, RASCOL A (1982) Aphasie croisée chez les droitiers. II. Étude neurolinguistique et neuropsychologique d'un cas. Evolution sur deux ans. *Revue Neurologique*, **138**, 587-600.
- RAPCSAK SZ, GONZALEZ ROTH LJ, HEILMAN KM (1987) Apraxia in a patient with atypical cerebral dominance. *Brain and Cognition*, **6**, 450-463.
- ROELTGEN DP, SEVUSH S, HEILMAN KM (1983) Phonological agraphia: writing by the lexical-semantic route. *Neurology, Cleveland*, **33**, 755-765.
- ROSS ED (1981) The aprosodias: functional-anatomic organization of the affective components of language in the right hemisphere. *Archives of Neurology, Chicago*, **38**, 561-569.
- SCHWARTZ MF (1984) What the classical aphasia categories can't do for us, and why. *Brain and Language*, **21**, 3-8.
- SELNES OA, RUBENS AB, RISSE GL, LEVY RS (1982) Transient aphasia with persistent apraxia: uncommon sequela of massive left-hemisphere stroke. *Archives of Neurology, Chicago*, **39**, 122-126.
- SWEET EWS, PANIS W, LEVINE DN (1984) Crossed Wernicke's aphasia. *Neurology, Cleveland*, **34**, 475-479.
- TAYLOR HG, SOLOMON JR (1979) Reversed laterality: a case study. *Journal of Clinical Neuropsychology*, **1**, 311-322.
- TROJANOWSKI JQ, GREEN RC, LEVINE DN (1980) Crossed aphasia in a dextral: a clinicopathological study. *Neurology, New York*, **30**, 709-713.
- URBAIN E, SERON X, REMITS A, COBBEN A, VAN DER LINDEN M, MOUCHETTE R (1978) Aphasie croisée chez une droitière: à propos d'une observation. *Revue Neurologique*, **134**, 751-759.
- WECHSLER AF (1976) Crossed aphasia in an illiterate dextral. *Brain and Language*, **3**, 164-172.
- YARNELL PR (1981) Crossed dextral aphasia: a clinical radiological correlation. *Brain and Language*, **12**, 128-139.

