

Cerebral and Cutaneous Involvements of Xanthoma Disseminatum Successfully Treated with an Interleukin-1 Receptor Antagonist: A Case Report and Minireview

Mario Campero^{a, b} Sebastián Campero^c Julia Guerrero^d Achille Aouba^f
Alex Castro^e

^aDepartamento de Neurología, Clínica Las Condes, ^bDepartamento de Neurología y Neurocirugía, ^cFacultad de Medicina and ^dDepartamento de Fisiología, Universidad de Chile, and ^eServicio de Patología, Clínica Alemana de Santiago, Santiago, Chile; ^fDepartment of Internal Medicine and Clinical Immunology, CHU de Caen, Caen, France

Key Words

Xanthoma disseminatum · Central nervous system · Non-Langerhans cell histiocytosis · Contrast-enhancing brain lesions · Diabetes insipidus · Interleukin receptor antagonist

Abstract

A young male presented with panhypopituitarism (including diabetes insipidus) and temporal lobe epilepsy. A histology specimen of cutaneous papules was diagnostic of non-Langerhans histiocytosis. The diagnosis of xanthoma granulomata was considered based on the clinical and brain MRI findings. Brain lesions significantly worsened over time despite radiotherapy until anakinra induced a complete clinical and radiological remission of all active lesions. Although a single case, the outcome of this patient with xanthoma disseminatum treated with an interleukin-1 receptor antagonist opens and strengthens new and recent physiopathogenic and treatment perspectives for the otherwise difficult-to-treat non-Langerhans cell histiocytosis. Similar results with anakinra have been observed in patients with Erdheim-Chester disease and in multicentric reticulohistiocytosis.

© 2016 S. Karger AG, Basel

Introduction

Non-Langerhans histiocytosis (NLH) is a group of rare disorders characterised by the infiltration of lipoid granulomas with CD68+ and CD1a– macrophages in different tissues [1, 2]. Among the areas of the central nervous system (CNS) involved in all the subtypes of NLH, infiltration of the pituitary gland is a frequent feature often expressed as diabetes insipidus. Nonetheless, lesions may affect any part of the brain [3, 4]. The NLH prognosis is unpredictable, and mortality rates may reach close to 60% at 32 months [5]. To date, there is no treatment consensus for NLH. Steroids and cytostatic drugs have been used with occasional transient improvement [6, 7]. In small case series, interferon- α has resulted in variable recovery [6]. A recent report [8] describes 2 patients with Erdheim-Chester disease (ECD), a form of NLH, treated with the recombinant interleukin (IL)-1 receptor antagonist anakinra, which induced significant or complete resolution of this inflammatory myeloid neoplasm [9]. It is suggested that the anti-inflammatory effect of anakinra

A.A. and A.C. contributed equally to this work.

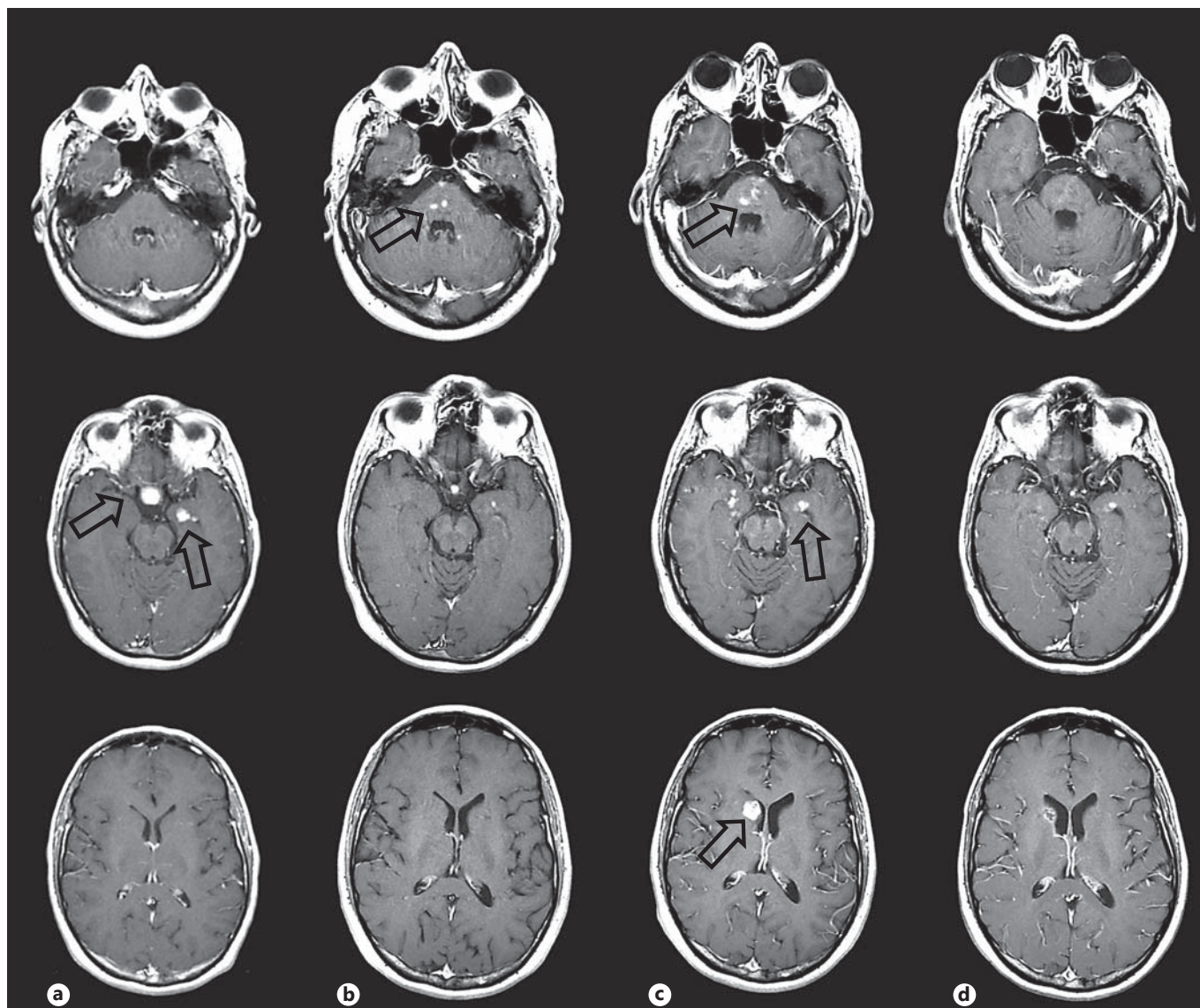


Fig. 1. Contrast-enhanced axial T1-weighted MRI images showing the brainstem at the pons level (upper row), pituitary and medial temporal lobes (middle row), and at the level of the head of the caudate nucleus. These images are arranged in columns by time sequence: at the time of diagnosis (**a**); 2 years after diagnosis (**b**); 4 years after diagnosis and just before treatment (**c**); 7 months after treatment (**d**). **a** Heterogeneous contrast-enhancing lesion in the sellar region and the left medial temporal lobe (arrows). No pontine and caudate nucleus lesions are seen. **b** The sellar and medial

temporal lobes are slightly smaller after radiotherapy. Contrast-enhancing lesions in the pons are seen without abnormalities in the head of the caudate nucleus (arrow). **c** Bilateral medial temporal lobar lesions with increase in pontine lesion size and development of a large rounded lesion in the head of the right caudate nucleus (arrows). **d** All contrast-enhancing lesions have significantly diminished or disappeared 7 months after IL-1 receptor antagonist.

on macrophages would account for the improvement in the proliferation of these cells in different areas.

Here, we present a patient with a cutaneous immunohistological diagnosis of NLH with progressive involvement of the CNS, unresponsive to radiotherapy, in whom

all CNS and cutaneous lesions exhibited complete remission during treatment with anakinra. The clinical pattern without skeletal involvement and the type of cutaneous lesions, followed for several years, support the diagnosis of xanthoma disseminatum (XD).

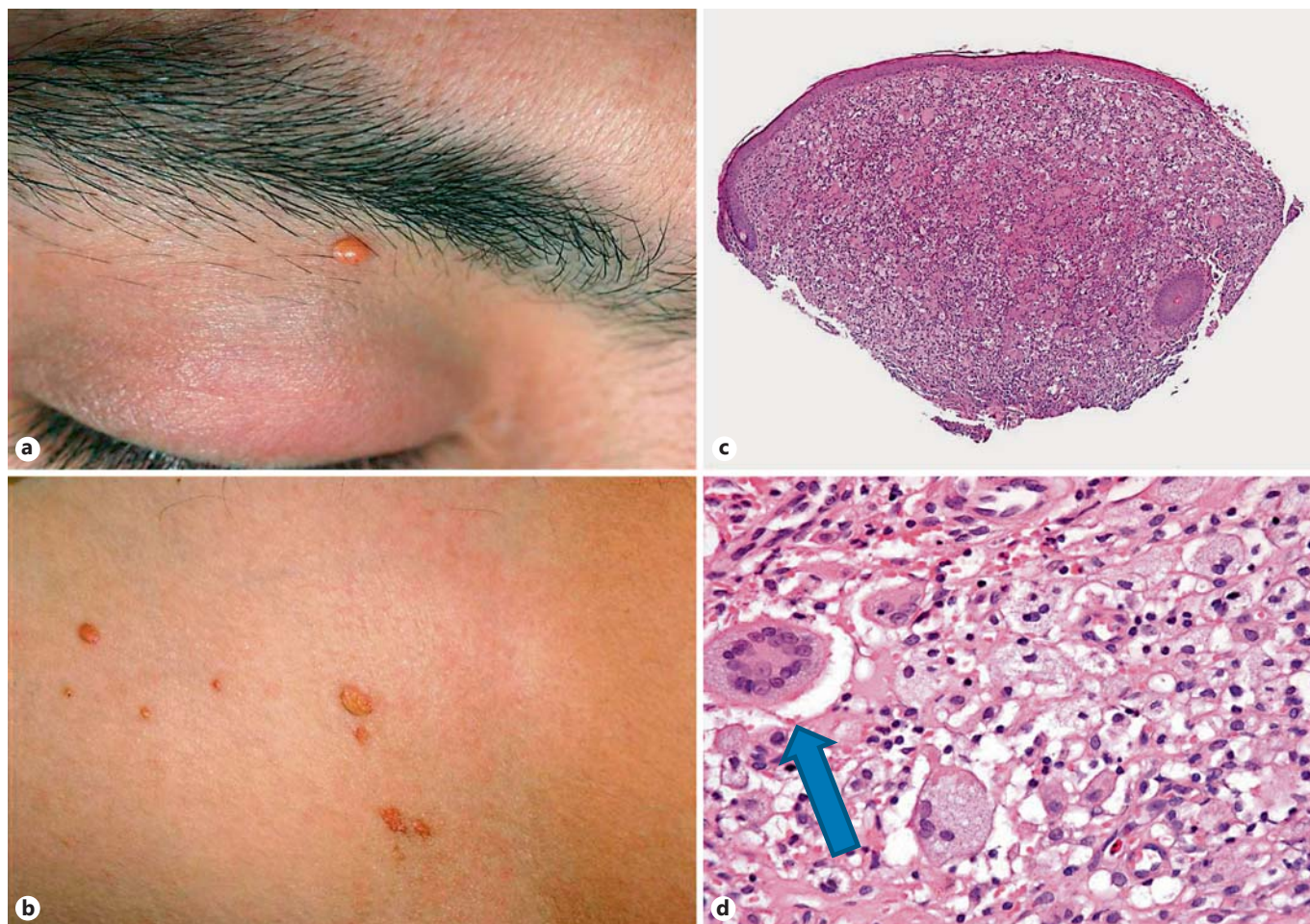


Fig. 2. **a, b** Yellow-brownish papules of the skin. **c** Low resolution microscopic specimen of a papule with epidermal and dermal infiltrate. **d** High resolution of a macrophage and neutrophil infiltrate

with several mononuclear and multinuclear histiocytes; the latter arranged in wreath-like fashion are typical for Touton cells (arrow). Paraffin-embedded, HE stain. Original magnification $\times 100$.

Case Report

A Caucasian male, 32 years old and previously in good health, presented with a mild headache and significant polydipsia and polyuria, leading to the suspicion of diabetes insipidus. He also referred to impotence and a conspicuous reduction in beard growth. Oligozoospermia was found. He also developed fits of sudden epigastric discomfort associated with memory flashbacks lasting a few seconds followed by profuse sweating. The diagnosis of panhypopituitarism and temporal lobe epilepsy was made, and a first brain MRI was obtained. This first brain MRI (2005) showed a heterogeneous lesion in the sellar region and another in the left medial temporal lobe (fig. 1a). Both lesions displayed great enhancement with paramagnetic contrast. The patient had thoracic and abdominal CT scans which were unrevealing. The patient never complained of limb pains, and skeleton X-ray examinations requested for other studies found no bone abnormality.

At that time, isolated cutaneous lesions characterised by yellow-brownish papules less than 5 mm in diameter were found dis-

tributed along the abdomen, axilla and eyelids (fig. 2a, b). The histology was characteristic of NLH. Figures 2c and d show the pathological specimen obtained from the chest wall. This was a nodular lesion characterised by a dermal infiltrate of histiocytes, lymphocytes, neutrophils and a variable number of xanthoma cells with foamy cytoplasm, both mononucleated and multinucleated. The latter are giant cells with multiple nuclei arranged in wreath-like fashion, described as Touton cells (arrow). The histiocytes were CD68+, CD4+ and CD1a- (fig. 2). The biopsy sample did not exhibit the V600E mutation of the *BRAF* gene.

The clinical presentation, the histopathology of cutaneous lesions and the MRI findings were consistent with XD, a form of NLH with cutaneous and CNS involvement. At that time, symptomatic treatment with hormone replacement and anti-epileptic drugs was initiated with adequate symptomatic results. Conformational fractionated radiation therapy (total 38 Gy) to the left medial temporal lobe and pituitary gland was received in 5 sessions over 30 days (January 2006) based on the opinion of the local oncology/haematology committee.

Table 1. Synopsis of systemic treatments proposed for XD

First author	Organs involved, other than the skin	Treatments proposed	Outcome
Calverly [22], 1995	Buccal mucosa, lips, eyelids, bones, bone marrow, liver and spleen	Prednisone and vinblastine	Failure
Pruvost [28], 2004	Pharynx, larynx and trachea mucosae	(1) Thalidomide (2) Cyclophosphamide (3) Vinblastine (32 cycles)	(1) Failure (2) Failure (3) Very good remission
Seaton [30], 2004	Eye, laryngeal mucosae, pituitary gland, CNS	Cyclophosphamide	Partial remission
Buyukavci [21], 2005	Liver	Prednisone and azathioprine	Failure
Savaşan [29], 2005	Liver and bone marrow	(1) HLH-94 protocol (etoposide, cyclosporine) (2) High-dose chemotherapy (carmustine, etoposide, cytarabine, melphalan) and matched unrelated donor bone marrow transplantation	(1) Failure (2) Complete remission
Bastida [20], 2007	Conjunctiva, nasopharyngeal mucosae	Doxycycline	Good regression
Eisendle [23], 2008	Bone, conjunctiva, nasopharyngeal and buccal mucosae	(1) Etoposide and subcutaneous interferon (2) Rosiglitazone, simvastatin, acipimox	(1) Failure (2) Failure
Lee [26], 2011	Buccal mucosa, soft palate and tongue	(1) Cortisone, cyclophosphamide (2) Rosiglitazone, simvastatin, acipimox	(1) Failure (2) Partial remission
Khezri [24], 2011	5 patients with variably associated soft palate, eye, pituitary gland and stalk involvements	5–8 cycles of cladribine	Good partial remission marked in cutaneous lesions (2 patients) or failure (3 patients)
Kim [25], 2012	Pituitary gland with diabetes insipidus	Statins, fenofibrate and cyclophosphamide	Partial remission of the pituitary gland involvement, but failure in skin lesions
Park [27], 2014	Not applicable	(1) Doxycycline (2) Cyclosporine, doxycycline	(1) Failure (2) Partial remission
Zinoun [31], 2015	Stomach, lung and bone	Corticosteroids 1 mg/kg/day and thalidomide 100 mg/day	Overall good outcome, more marked on cutaneous lesions
Our present case	Pituitary gland and CNS	(1) Radiotherapy on CNS lesions (2) Anakinra	(1) Failure (2) Complete remission of all active lesions

Serial brain MRIs (yearly) displayed progressive development of contrast-enhancing lesions in the brainstem, right caudate nucleus and bilateral medial temporal lobes without significant changes in the irradiated left temporal lobe lesion or pituitary enhancement (fig. 1). This progression prompted another treatment option.

Treatment with anakinra, 100 mg subcutaneously daily, was started in July 2009 with very mild local side effects at the injection sites. All cutaneous lesions disappeared within 15 months.

Three and 8 months after the daily subcutaneous injections, there was a significant and sustained reduction in all contrast-enhancing lesions, both in the brainstem, temporal lobes and the right caudate nucleus (fig. 1d). The patient has remained asymptomatic since anakinra on a 5-year follow-up. Anakinra was continued on a weekly dose for 2 years, and during the last year he has used a monthly dose. The patient is still on anti-epileptic drugs but without clinical or electroencephalographic evidence of seizures.

Discussion

NLH belongs to a heterogeneous group of disorders originating from dendritic cells with proliferation of macrophages containing lipid material and expressing CD68 and factor XIII. NLH involving dermal dendritic cells includes XD, juvenile or adult xanthogranuloma, and ECD. The localisation and accumulation sites of these cells define these different entities: purely dermal in juvenile or adult xanthogranuloma; systemic with high dermal tropism in XD, or multisystemic, including dermal involvement in ECD. Bones and the CNS are often involved in the two systemic entities with dermal lesions while infiltration of the retroperitoneum area is characteristic of ECD [7, 8, 10].

The distribution of xanthomas in the CNS does not seem to be specific in each form of NLH. In fact, the ECD [6, 11, 12], xanthogranuloma disseminatum [1, 2, 3–5, 13] and juvenile xanthogranulomas [14] may have similar distributions in their CNS lesions. Finally, the XD diagnosis in the present patient is supported by the pattern of skin lesions and the absence of other symptoms/involvement as in the ECD. In the latter, skeletal infiltration is very frequently, if not always, observed, and notably with a typical bilateral and symmetric metaphyseal involvement of limb bones.

Three clinical patterns of XD have been described [3]: a persistent form, a less common progressive form and a rare spontaneously regressive form [12]. CNS involvement with diabetes insipidus has been associated with the progressive clinical pattern, and the involvement of other areas occurs in less than 5% of XD [3].

There is no standard treatment of NLH, including XD. The effectiveness of radiation therapy is unclear due to the limited number of cases; even though radiation therapy often exhibited none or a small palliating stabilizing effect on XD as seen in our case, two reports experienced successful outcome in this context [15, 16]. Considering systemic management, ECD treatment options included interferon- α , anakinra and Braf targeting drugs [3, 17]. But unlike in ECD, the *BRAF* mutation has not yet been found in other NLH including multicentric reticulohistiocytosis (MCRH) and XD in the literature and in our case [18, 19]. For MCRH, because of the frequent failure of cytotoxic and anti-TNF- α drugs and the risk of associated malignant conditions, an interesting complete remission was obtained with anakinra [18]. Similarly, besides local treatment for isolated and/or accessible lesions in XD, several treatment strategies showed disappointing results (or were successful in isolated cases), including lipid-lowering agents, prednisone, interferon- α , immu-

nosuppressants and chemotherapies (table 1) [20–31]. The proposal of anakinra therefore appears adequate in our XD patient, by analogy with its harmless and successful results in ECD and MCRH, on the basis of histological and biological evidence for the leading role of IL-1 cytokines in these last two NLH [3, 18]. Indeed, the different subtypes of NLH share largely common immune, histopathological and probably pathophysiological features, and their differential diagnosis is frequently based on some specific organ involvements.

It was unlikely that the CNS lesions had improved due to the radiotherapy since it was given on a conformational field 4 years before anakinra, and all the lesions grew despite the radiotherapy. Spontaneous improvement of brain lesions in NLH has been described [13], but it is not very likely in this case since there is a clear temporal relationship between the initiation of anakinra and the resolution of the contrast-enhancing lesions. In fact, our patient also exhibited a complete remission of cutaneous xanthomas under this systemic treatment.

Though just a single case, the outcome of this XD treated with an IL-1 receptor antagonist opens and strengthens new and recent physiopathogenic and treatment perspectives for the otherwise difficult-to-treat NLH group since the same results have been observed with ECD and MCRH, with a very favourable safety profile for this targeted therapy.

Acknowledgements

We are indebted to our patient who has allowed us to communicate his case.

Statement of Ethics

The local Ethics Committee acknowledged and found sufficient the signed agreement to report the case.

Disclosure Statement

The authors declare no conflicts of interest. There is no funding related to this report.

References

- 1 Caputo R, et al: Progressive histiocytosis: description of a case of slow-course non-Langerhans cell histiocytosis. *Dermatology* 2002; 205:293–297.
- 2 Caputo R, et al: The various clinical patterns of xanthoma disseminatum. Considerations on seven cases and review of the literature. *Dermatology* 1995;190:19–24.
- 3 Oka M, et al: Xanthoma disseminatum with intracranial involvement: case report and literature review. *Int J Dermatol* 2010;49:193–199.
- 4 Zak IT, et al: Xanthoma disseminatum of the central nervous system and cranium. *AJNR Am J Neuroradiol* 2006;27:919–921.
- 5 Alexander AS, et al: Xanthoma disseminatum: a case report and literature review. *Br J Radiol* 2005;78:153–157.
- 6 Braithe F, et al: Successful treatment of Erdheim-Chester disease, a non-Langerhans-cell histiocytosis, with interferon-alpha. *Blood* 2005;106:2992–2994.
- 7 Chepuri NB, Challa VR: Xanthoma disseminatum: a rare intracranial mass. *AJNR Am J Neuroradiol* 2003;24:105–108.
- 8 Aouba A, et al: Rationale and efficacy of interleukin-1 targeting in Erdheim-Chester disease. *Blood* 2010;116:4070–4076.
- 9 Haroche J, et al: The histiocytosis Erdheim-Chester disease is an inflammatory myeloid neoplasm. *Expert Rev Clin Immunol* 2015;11: 1033–1042.
- 10 Conley A, et al: Non-Langerhans cell histiocytosis with isolated CNS involvement: an unusual variant of Erdheim-Chester disease. *Neuropathology* 2010;30:634–647.
- 11 Chandran V, et al: Erdheim-Chester disease: a rare clinical presentation as multiple system atrophy. *Mov Disord* 2009;24:461–463.
- 12 Wright RA, Hermann RC, Parisi JE: Neurological manifestations of Erdheim-Chester disease. *J Neurol Neurosurg Psychiatry* 1999; 66:72–75.
- 13 Park HY, et al: A case of xanthoma disseminatum with spontaneous resolution over 10 years: review of the literature on long-term follow-up. *Dermatology* 2011;222:236–243.
- 14 Lalitha P, Reddy M, Reddy KJ: Extensive intracranial juvenile xanthogranulomas. *AJNR Am J Neuroradiol* 2011;32:E132–E133.
- 15 Moloney JR: Xanthoma disseminatum: its otolaryngological manifestations. *J Laryngol Otol* 1979;93:201–210.
- 16 Patel KH, El-Yassir M, Erzurum SA: Juvenile xanthogranuloma – a rare cause of unilateral orbital swelling in an elderly patient. *Orbit* 2015;34:106–108.
- 17 Haroche J, et al: Reproducible and sustained efficacy of targeted therapy with vemurafenib in patients with BRAF(V600E)-mutated Erdheim-Chester disease. *J Clin Oncol* 2015;33: 411–418.
- 18 Aouba A, et al: Assessment and effective targeting of interleukin-1 in multicentric reticulohistiocytosis. *Joint Bone Spine* 2015;82: 280–283.
- 19 Haroche J, et al: High prevalence of BRAF V600E mutations in Erdheim-Chester disease but not in other non-Langerhans cell histiocytoses. *Blood* 2012;120:2700–2703.
- 20 Bastida J, et al: Adult disseminated primary papular xanthoma treated with doxycycline. *Arch Dermatol* 2007;143:667–669.
- 21 Buyukavci M, et al: Xanthoma disseminatum with hepatic involvement in a child. *Pediatr Dermatol* 2005;22:550–553.
- 22 Calverly DC, et al: Xanthoma disseminatum in an infant with skeletal and marrow involvement. *J Pediatr Hematol Oncol* 1995;17:61–65.
- 23 Eisendle K, et al: Inflammation and lipid accumulation in xanthoma disseminatum: therapeutic considerations. *J Am Acad Dermatol* 2008;58(2 suppl):S47–S49.
- 24 Khezri F, Gibson LE, Tefferi A: Xanthoma disseminatum: effective therapy with 2-chlorodeoxyadenosine in a case series. *Arch Dermatol* 2011;147:459–464.
- 25 Kim WJ, et al: Successful treatment of xanthoma disseminatum with combined lipid lowering agents. *Ann Dermatol* 2012;24:380–382.
- 26 Lee EH, Kang TW, Kim SC: Successful treatment of xanthoma disseminatum with simvastatin. *J Dermatol* 2011;38:1015–1017.
- 27 Park M, Boone B, Devos S: Xanthoma disseminatum: case report and mini-review of the literature. *Acta Dermatovenereol Croat* 2014; 22:150–154.
- 28 Pruvost C, et al: Vinblastine treatment for extensive non-X histiocytosis (xanthoma disseminatum) (in French). *Ann Dermatol Venereol* 2004;131:271–273.
- 29 Savaşan S, et al: Successful bone marrow transplantation for life threatening xanthogranuloma disseminatum in neurofibromatosis type-1. *Pediatr Transplant* 2005;9:534–536.
- 30 Seaton ED, Pillai GJ, Chu AC: Treatment of xanthoma disseminatum with cyclophosphamide. *Br J Dermatol* 2004;150:346–349.
- 31 Zinoun M, et al: Xanthoma disseminatum with asymptomatic multisystem involvement. *Ann Dermatol Venereol* 2015;142:276–280.