

Endovascular management of internal carotid artery injuries secondary to endonasal surgery: case series and review of the literature

Peter T. Sylvester, MD, MS,¹ Christopher J. Moran, MD,² Colin P. Derdeyn, MD,^{1,2}
DeWitte T. Cross, MD,² Ralph G. Dacey, MD,¹ Gregory J. Zipfel, MD,¹ Albert H. Kim, MD, PhD,¹
Ravi Uppaluri, MD, PhD,³ Bruce H. Haughey, MBChB, MS,³ Rene Tempelhoff, MD,⁴
Keith M. Rich, MD,¹ John Schneider, MD, MA,³ Richard A. Chole, MD, PhD,³ and
Michael R. Chicoine, MD¹

Departments of ¹Neurosurgery, ³Otolaryngology, and ⁴Anesthesia, and ²Division of Neuroradiology, Mallinckrodt Institute, Washington University School of Medicine, St. Louis, Missouri

OBJECTIVE Internal carotid artery (ICA) injury is a rare but severe complication of endonasal surgery. The authors describe their endovascular experience managing ICA injuries after transsphenoidal surgery; they review and summarize the current literature regarding endovascular techniques; and they propose a treatment algorithm based on the available evidence.

METHODS A retrospective review of 576 transsphenoidal pituitary adenoma resections was performed. Cases of ICA injury occurring at our institution and transfers from other hospitals were evaluated. Endovascular treatments for ICA injury reported in the literature were also reviewed and summarized.

RESULTS Seven cases were identified from the institutional cohort (mean age 46.3 years, mean follow-up 43.4 months [1–107 months]) that received endovascular treatment for ICA injury. Five injuries occurred at our institution (5 [0.9%] of 576), and 2 injuries occurred at outside hospitals. Three patients underwent ICA sacrifice by coil placement, 2 underwent lesion embolization (coil or stent-assisted coil placement), and 2 underwent endoluminal reconstruction (both with flow diversion devices). Review of the literature identified 98 cases of ICA injury treated with endovascular methods. Of the 105 total cases, 46 patients underwent ICA sacrifice, 28 underwent lesion embolization, and 31 underwent endoluminal reconstruction. Sacrifice of the ICA proved a durable solution in all cases; however, the rate of persistent neurological complications was relatively high (10 [21.7%] of 46). Lesion embolization was primarily performed by coil embolization without stenting (16 cases) and stent-assisted coiling (9 cases). Both techniques had a relatively high rate of at least some technical complication (6 [37.5%] of 16 and 5 [55.6%] of 9, respectively) and major technical complications (i.e., injury, new neurological deficit, or ICA sacrifice) (5 [31.3%] of 16 and 2 [22.2%] of 9, respectively). Endoluminal reconstruction was performed by covered stent (24 cases) and flow diverter (5 cases) placement. Covered stents showed a reasonably high rate of technical complications (10 [41.7%] of 24); however, 8 of these problems were resolved, leaving a small percentage with major technical complications (2 [8.3%] of 24). Flow diverter placement was also well tolerated, with only 1 minor technical complication.

CONCLUSIONS Endovascular treatments including vessel sacrifice, coil embolization (with or without stent assistance), and endoluminal reconstruction offer a tailored approach to ICA injury management after endonasal surgery. Vessel sacrifice remains the definitive treatment for acute, uncontrolled bleeding; however, vessel preservation techniques should be considered carefully in select patients. Multiple factors including vascular anatomy, injury characteristics, and risk of dual antiplatelet therapy should guide best treatment, but more study is needed (particularly with flow diverters) to refine this decision-making process. Ideally, all endovascular treatment options should be available at institutions performing endonasal surgery.

<http://thejns.org/doi/abs/10.3171/2015.6.JNS142483>

KEY WORDS internal carotid artery; decision making; endonasal surgery; endovascular procedures; treatment outcomes; pituitary surgery

ABBREVIATIONS ACoA = anterior communicating artery; BTO = balloon test occlusion; CCF = carotid-cavernous fistula; EC-IC = extracranial-intracranial; EVD = external ventricular drain; ICA = internal carotid artery; PCoA = posterior communicating artery; PED = Pipeline Embolization Device.

SUBMITTED November 1, 2014. **ACCEPTED** June 3, 2015.

INCLUDE WHEN CITING Published online January 15, 2016; DOI: 10.3171/2015.6.JNS142483.

IATROGENIC internal carotid artery (ICA) injuries are infrequent but challenging complications during endonasal surgery, with potentially disabling or fatal consequences. Injury to the ICA may be evident immediately intraoperatively with high volume arterial bleeding or may become evident unexpectedly in a delayed fashion days to years after surgery with development of a pseudoaneurysm or delayed hemorrhage.⁴⁹ Studies have reported a 0.2%–2.0% incidence rate of ICA injury during transsphenoidal surgery for pituitary adenomas.^{7,20,49,59,73,80,82} Diagnostic catheter angiography is typically advisable if ICA injury is suspected, and endovascular intervention may be warranted.

The largest single study was reported in 1997 by Raymond and colleagues, who retrospectively identified ICA injuries in 17 (0.9%) of 1800 transsphenoidal surgeries for pituitary adenoma including 8 occlusions, 6 stenoses, and 3 pseudoaneurysms.⁷³ Five patients underwent permanent balloon occlusion of the ICA. Delayed epistaxis occurred in 10 patients, 5 of whom did not have a recognized arterial injury during surgery. The authors directly related 3 deaths and 5 permanent deficits to arterial injuries or their treatment. These results highlight the significant consequences that can occur as a result of ICA injury and the potential for unexpected delayed hemorrhage.

Various endovascular options are available for the treatment of iatrogenic ICA injury. In 2013, Gardner et al. reported 7 ICA injuries in 2015 endoscopic endonasal cases performed over the course of 13 years.²⁹ They proposed an algorithm including the use of covered stents and ICA coil sacrifice for the treatment of pseudoaneurysms and injuries presenting with active extravasation on diagnostic angiography. The treatment of delayed ICA hemorrhage and the use of other vessel-sparing techniques such as embolization with or without stent assistance and flow diversion were not addressed. To date, a comprehensive report incorporating the latest endovascular techniques for the treatment of both acute and delayed ICA injury after endonasal surgery has not been made.

In this study, we performed a retrospective review of a single institutional experience with endovascular management of intra- or postoperative ICA injury specifically following transsphenoidal surgery for pituitary adenoma. A comprehensive review of the literature on endovascular management of ICA injury following endonasal surgery was also performed. Injury details, procedural characteristics, and outcomes after endovascular treatments were evaluated, and general endovascular treatment modality recommendations are proposed based on the current series and literature review.

Methods

Patients

Institutional review board (IRB) approval was obtained for this study. Data were abstracted from medical records and an IRB-approved prospective and retrospective brain tumor surgery and intraoperative MRI database containing demographic, pre-, peri-, and postoperative data from 576 transsphenoidal surgeries performed for pituitary adenoma at our institution from 1993 to 2013. Five patients

(0.9%) were identified as having undergone endovascular treatment for ICA injury after transsphenoidal surgery for pituitary adenomas. Two endovascular treatments were performed for ICA injuries sustained at an outside hospital.

Periprocedural Details

For the 5 ICA injuries that occurred at our institution, intraoperative hemostasis after ICA injury was achieved by direct packing of the sella, sphenoid sinus, and nasal cavity using Gelfoam (Pfizer) and cottonoids prior to pursuing digital subtraction angiography. Patients were transported from the operating room while anesthetized, with the surgical and anesthesia teams present during the endovascular procedure. No external ventricular drain (EVD) was placed or CT scans performed prior to angiography. Angiography was performed in the angiography suite rather than in the operating room to optimize biplanar imaging for diagnostic angiography and subsequent endovascular procedures. Four of the 5 patients were returned to the operating room after angiography for the removal of cottonoids and definitive closure. One patient (Case 4) received definitive closure prior to transfer to the angiography suite.

Endovascular Procedures

For all 7 ICA injuries, patients were positioned supine and were maintained under general anesthesia while arterial access was achieved in the common femoral artery, with placement of a 6-Fr sheath. Diagnostic angiography was performed using a high-resolution biplane angiographic unit (Neurostar or Axiom Artis, Siemens Healthcare). Balloon test occlusion (BTO) was performed to examine the collateral circulation in cases intended for ICA occlusion by placement of a temporary balloon in the ICA proximal to the level of the injury, and assessing collateral circulation by subsequent selective injections of the contralateral ICA and the vertebral arteries. Assessments were made of the collateral perfusion to the territory of the balloon-occluded ICA, including supply from the anterior communicating artery (ACoA), the posterior communicating artery (PCoA), and retrograde filling via the ophthalmic artery and pial collaterals. The symmetry of the venous phase was assessed.¹

Treatment of ICA injuries was performed using 1 of 3 treatment paradigms including 1) ICA sacrifice, 2) ICA lesion embolization, and 3) ICA endoluminal reconstruction. Sacrifice of the ICA was performed using various coil systems to develop a construct covering the injured portion of the artery, spanning from proximal to the ophthalmic artery origin to the petrous ICA. Embolization of ICA lesions was achieved using coils with or without a stent-assisted system. Stent-assisted coiling was performed using the Enterprise closed-cell design stent (Cordis Neurovascular, Inc.) or the Neuroform open-cell design stent (Stryker), which were delivered as previously reported.^{37,39} Endoluminal reconstruction was performed via flow diversion with the Pipeline Embolization Device (PED, ev3) as previously reported.³⁸ Patients were recommended to continue aspirin for at least 1 year and clopidogrel for at least 2 months after either stent or flow diverter placement. When

indicated, patients remained intubated and were taken back to the operating room for completion of the transsphenoidal surgery for resection of the pituitary adenoma.

Literature Search

The literature was reviewed to summarize the available endovascular treatment options for iatrogenic ICA injury during endonasal surgery. A search of MEDLINE/PubMed, Scopus, and Embase was performed. The search strategy “internal carotid artery AND (injury OR pseudoaneurysm OR fistula) AND (endovascular OR Pipeline OR flow diverter OR stent OR coil) identified 2057 reports. Review of these articles and citations from relevant articles identified 60 pertinent articles. Data from these papers were abstracted, summarized, and evaluated.

Results

Case Characteristics

Baseline operative treatment and ICA injury characteristics including patient age, sex, prior and most recent treatment for pituitary adenoma, preoperative presentation, preangiography presentation, timing of angiography relative to most recent operative therapy, and results of angiography are listed in Table 1. Four females and 3 males were identified, with a mean age of 46.3 years (range 27–86 years) at the time of endovascular treatment. In 4 of 5 of these cases, hemostasis was obtained with Gelfoam and cottonoids, and these patients received definitive endovascular treatment either immediately (Cases 1, 2, and 3) or 3 days after transsphenoidal surgery (Case 4). Case 5 had adequate intraoperative control of bleeding and a negative angiogram, but a small pseudoaneurysm was identified on follow-up angiography 5 days later, and endovascular treatment was performed 15 days after transsphenoidal surgery. Cases 6 and 7 were referred to our hospital with epistaxis following transsphenoidal surgery, but operative notes were not available for review. Case 6 had 2 weeks of epistaxis 2 months after transsphenoidal surgery, and Case 7 had epistaxis and coil extrusion into the nasopharynx and oropharynx 20 years after transsphenoidal surgery, ICA injury, and prior coil emboliza-

tion of a pseudoaneurysm. Diagnostic angiography of the 7 endovascular cases identified 6 pseudoaneurysms (mean size 5.5 mm, median size 2.5 mm, range 2–18 mm) and 1 filling defect suggestive of active extravasation. The 3 cases that received BTO (Cases 1, 2, and 3) demonstrated good collateral filling from the contralateral circulation. Assessment of collateral circulation by standard angiography demonstrated good filling in Cases 5 and 7 and poor filling in Cases 4 and 6.

A literature review identified 60 articles and 98 cases of endovascular treatments for ICA injury following endonasal surgery (105 cases including the current series). Surgery types included 82 transsphenoidal surgeries (78.1%), 16 endonasal sinus surgeries (15.2%), 2 maxillectomies (1.9%), and 5 unspecified endonasal surgeries (4.8%). Endovascular treatments were grouped into ICA sacrifice (Table 2), ICA endoluminal reconstruction (Table 3), and ICA lesion embolization (Table 4). The highest case totals were reported for ICA sacrifice (46 [43.8%]), followed by endoluminal reconstruction (31 [29.5%]) and lesion embolization (28 [26.7%]), with an increased rate of endoluminal reconstruction in recent years (Fig. 1). The distribution of ICA injury type by endovascular treatment type is shown in Fig. 2.

The timing of ICA injury identification was not reported for 7 of 105 cases. Figure 3 shows the timing of ICA injury identification and treatment arranged by treatment type. Intraoperative ICA injury was recognized in 84 (85.7%) of 98 cases, with 54 (64.3%) of 84 patients receiving immediate treatment and 30 (35.7%) of 84 patients receiving delayed treatment. Immediate treatments included ICA sacrifice (28 cases), covered stents (16 cases), lesion embolization (9 cases: stent-assisted coiling in 5 and only coiling in 4), and unreported stent repair type (1 case). Delayed treatments after intraoperative identification of ICA injury included embolization (13 cases: 1 balloon, 2 Onyx, 1 stent-assisted coil, 9 coils only), ICA sacrifice (10), and covered stent (5). Delayed identification of ICA injury was reported in 14 (14.3%) of 98 cases. All of these were reported to have pseudoaneurysms. Treatments included lesion embolization (5 cases: 2 stent-assisted coiling, 3 coiling), ICA sacrifice (4), covered stent (2), and flow di-

TABLE 1. Baseline treatment and injury characteristics

Case No.	Age (yrs), Sex	Prior Tx	Most Recent Tx	Preop Presentation	Preangiography Presentation	Timing of Angiography	Angiography Results
1	30, F	None	TSS	Cushing's disease	Intraop bleeding	Intraop	BTO: adequate; 2-mm PA, moderate stenosis
2	40, F	None	TSS	BH + HA	Intraop bleeding	Intraop	BTO: adequate; 2-mm PA
3	27, M	None	TSS	HA + gynecomastia	Intraop bleeding	Intraop	BTO: adequate; 2-mm filling defect
4	86, F	None	TSS	BH + lt CN III palsy	Intraop bleeding	Intraop	Poor collaterals; 5-mm PA
5	21, M	6 mos prior: TSS	TSS	BH	Intraop bleeding	Intraop	Good collaterals; no injury detected
6	42, M	Dopamine agonist	TSS	BH	Epistaxis	POM 2	Poor collaterals; 18-mm PA
7	78, F	20 yrs prior: TSS, ICA PA, coil obliteration	TSS	NA	Epistaxis + extruding coil	POY 20	Good collaterals; 10-mm PA: coil obliterated; 5-mm PA: recurrent neck

BH = bitemporal hemianopsia; CN = cranial nerve; HA = headache; intraop = intraoperative; NA = not applicable; PA = pseudoaneurysm; POM = postoperative month; POY = postoperative year; TSS = transsphenoidal surgery; Tx = treatment.

TABLE 2. Literature review of endovascular ICA sacrifice following endonasal surgery

Authors & Year	Surgery Type	Injury/Tx Timing	Injury Type/Details	Neurological Outcome	FU	Last Reported Outcome
Current series: Case 1	TSS	Intraop/intraop	PA	No deficits	107 mos	Good
Case 2	TSS	Intraop/intraop	PA	Visual field deficit	12 mos	Partial recovery
Case 3	TSS	Intraop/intraop	Irregularity	Expressive aphasia, hemiparesis	58 mos	Full recovery
Smith et al., 2015	TSS	Intraop/intraop	NR	No deficits	36 mos	Good
Fu et al., 2013	TSS	POY 6/POY 6	PA	Hemiplegia, dysarthria	NR	Partial recovery
Cinar et al., 2013	TSS	NR/POD 1	Dissection/thrombus	No deficits	NR	Good
	TSS	NR/POD 1	Active bleed	No deficits	NR	Good
Kalinin et al., 2013	TSS	Intraop/intraop	Active bleed	Rt cerebral infarct	6 days	Death
	TSS	Intraop/intraop	PA	No deficits	NR	Good
Cinar et al., 2013	TSS	NR/POD 9	PA	No deficits	3 days	Death
	TSS	NR/POD 3	Active bleed	No deficits	NR	Good
Gardner et al., 2013	TSS	Intraop/intraop	PA	No deficits	NR	Good
	Endo	Intraop/intraop	Stenosis	No deficits	NR	Good
	Endo	Intraop/intraop	Active bleed	No deficits	NR	Good
Fujino et al., 2012	Max	Intraop/intraop	Active bleed	No deficits	NR	Good
Gondim et al., 2011	TSS	Intraop/intraop	PA	No deficits	NR	Good
Zada et al., 2010	TSS	Intraop/intraop	NR	No deficits	NR	NR
Ghatge & Modi, 2010	TSS	Intraop/intraop	Active bleed	No deficits	6 mos	Good
Biswas et al., 2009	Max	POD 4/POD 4	PA	Hemispheric stroke	NR	Partial recovery
Crowley et al., 2009	TSS	POW 4/POW 4	PA	Expressive aphasia	5 wks	Partial recovery
Fatemi et al., 2008	TSS	Intraop/intraop	PA	No deficits	NR	NR
Wang et al., 2008	TSS	Intraop/intraop	Active bleed	No deficits	NR	Good
	TSS	Intraop/intraop	CCF	No deficits	NR	Good
Pepper et al., 2007	ESS	Intraop/intraop	Active bleed	No deficits	6 mos	Good
	ESS	Intraop/intraop	Active bleed	Unilat visual loss	1 yr	No recovery
Koitschev et al., 2006	ESS	Intraop/intraop	CCF	No deficits	5 yrs	Good
	ESS	Intraop/intraop	Active bleed	No deficits	NR	Good
Ciceri et al., 2006	TSS	Intraop/intraop	PA	No deficits	2 yrs	Good
Weidenbecher et al., 2005	ESS	Intraop/POD 15	PA	No deficits	1 yr	Good
Oeken & Bootz, 2004	ESS	Intraop/POD 1	Active bleed	Stroke	2 days	Death
Kim et al., 2002	TSS	Intraop/intraop	PA	No deficits	8 mos	Good
Kai et al., 2001	TSS	Intraop/POD 20	PA	BTO fail, EC-IC bypass; no deficits	NR	Good
Laws, 1999	TSS	Intraop/intraop	PA	No deficits	NR	Good
	TSS	Intraop/intraop	PA	No deficits	NR	NR
Park et al., 1998	ESS	Intraop/intraop	PA	No deficits	7 days	Good
Chen et al., 1998	TSS	Intraop/POW 1	PA	No deficits	2 mos	Good
Raymond et al., 1997	TSS	POD 3/POY 10	PA	No deficits	12 mos	Good
	TSS	Intraop/POD 9	Stenosis	Unilat blindness	4 yrs	No recovery
	TSS	Intraop/POD 9	Irregularity	Hemiparesis	2 yrs	Full recovery
	TSS	Intraop/POD 1	Irregularity	CN III, IV, & VI palsies	6 mos	Partial recovery
	TSS	Intraop/intraop	Stenosis	MCA infarct, EC-IC bypass (thrombosed)	2 yrs	Partial recovery
Isenberg & Scott, 1994	ESS	Intraop/intraop	PA	No deficits	5 yrs	Good
Hollis et al., 1994	ESS	Intraop/POW 4	PA	No deficits	3 mos	Good
Ahuja et al., 1992	TSS	Intraop/POD 11	PA	Hemiparesis	14 mos	Full recovery
Hudgins et al., 1992	ESS	Intraop/intraop	PA	No deficits	NR	Good
Pigott et al., 1987	TSS	Intraop/intraop	CCF	No deficits	12 mos	Good

Endo = endonasal; ESS = endonasal sinus surgery; FU = follow-up; Max = maxillectomy; MCA = middle cerebral artery; NR = not reported; POD = postoperative day; POW = postoperative week.

TABLE 3. Literature review of endovascular ICA endoluminal reconstruction following endonasal surgery

Authors & Year	Surgery Type	Injury/Tx Timing	Injury Type/Details	Embolization Technique & Outcome	Neurological Outcome	FU	Last Reported Outcome
Current series: Case 5	TSS	POD 5/POD 15	PA	Pipeline PID 0: ICA patent, flow stasis in PA; PIM 6: ICA patent, PA obliterated	No deficits	16 mos	Good
Case 7	TSS	POY 20/POY 20	PA	Pipeline PID 0: ICA patent, contrast stasis in PA	No deficits	1 day	Good
Griauzde et al., 2015	TSS	Intraop/intraop	Active bleed	Covered stent PID 3: bare stent for apposition, ICA patent, no endoleak	No deficits	12 mos	Good
	TSS	Intraop/intraop	Active bleed	Covered stent No endoleak	No deficits	12 mos	Good
	TSS	Intraop/intraop	Active bleed	Covered stent 6 hrs postembo: rebleed, ICA sacrifice	Stroke	6 days	Death
Nerva et al., 2015	TSS	POD 9/POD 15	PA	Pipeline PID 0: mild in-stent stenosis; PIM 4: ICA patent, PA obliterated	No deficits	9 mos	Good
	TSS	NR/POD 4	PA	Pipeline PID 0: endoleak, angioplasty; PIW 2: ICA patent, PA obliterated	No deficits	3 mos	Sepsis, death
Kim et al., 2015	TSS	Intraop/intraop	Active bleed	Covered stent Gap but no endoleak, in-stent thrombosis, IA abciximab, ICA patent	No deficits	85 mos	Good
	TSS	Intraop/intraop	Active bleed	Covered stent ICA patent, no endoleak	No deficits	56 mos	Good
	TSS	Intraop/intraop	Active bleed	Covered stent No endoleak, in-stent thrombosis, IA abciximab, ICA patent	No deficits	54 mos	Good
	TSS	Intraop/intraop	Active bleed	Covered stent No endoleak, in-stent thrombosis, IA abciximab, ICA patent	No deficits	44 mos	Good
	TSS	Intraop/intraop	Active bleed	Covered stent Endoleak, 2nd stent placed, ICA patent	No deficits	40 mos	Good
	TSS	Intraop/intraop	Active bleed	Covered stent ICA patent, no endoleak	No deficits	28 mos	Good
	TSS	Intraop/POD 2	PA	Covered stent ICA patent, no endoleak	No deficits	12 mos	Good
	TSS	Intraop/intraop	Active bleed	Covered stent Endoleak, failure of 2nd covered stent, ×2 Pipelines, ICA patent, no endoleak	No deficits	54 mos	Good
Cinar et al., 2013	TSS	NR/POD 15	CCF	Covered stent ICA patent, no endoleak	No deficits	NR	Good
Gardner et al., 2013	TSS	Intraop/POD NR	PA	Stent repair ICA patent, no endoleak	No deficits	9 mos	Good
Kalinin et al., 2013	TSS	Intraop/POD 8	PA	Covered stent ICA patent, no endoleak	No deficits	NR	Good
Amenta et al., 2012	ESS	Intraop/POD 7	PA	Pipeline PIM 4: PA obliterated	No deficits	6 mos	Good

(continued)

TABLE 3. Literature review of endovascular ICA endoluminal reconstruction following endonasal surgery (continued)

Authors & Year	Surgery Type	Injury/Tx Timing	Injury Type/Details	Embolization Technique & Outcome	Neurological Outcome	FU	Last Reported Outcome
Dong et al., 2012	TSS	POY 6/POY 6	PA	Covered stent ICA patent, no endoleak	No deficits	4 days	Good
Ghatge & Modi, 2010	TSS	Intraop/intraop	Active bleed	Covered stent IVH, EVD placed	Stroke, herniation	3 days	Death
Charalampaki et al., 2009	TSS	Intraop/intraop	Aneurysm laceration	Stent repair NR	No deficits	NR	Good
Reich et al., 2009	ESS	Intraop/intraop	PA	Covered stent PID 2: endoleak, bare stent placed, ICA patent, no endoleak	No deficits	2 yrs	Good
Wang et al., 2008	TSS	Intraop/intraop	Active bleed	Covered stent ICA patent, no endoleak	No deficits	NR	Good
	TSS	Intraop/POY 8	PA	Covered stent ICA patent, no endoleak	No deficits	NR	Good
Lippert et al., 2007	Endo	POD 19/POD 19	PA	Covered stent ICA patent, no endoleak	No deficits	2 mos	Good
	ESS	Intraop/intraop	PA	Covered stent ICA patent, no endoleak	No deficits	6 mos	Good
Leung et al., 2006	TSS	Intraop/intraop	PA	Covered stent ICA patent, no endoleak	No deficits	3 mos	Good
de Souza et al., 2003	TSS	Intraop/POM 7	PA	Covered stent ICA patent, no endoleak	No deficits	1 mo	Good
Vanninen et al., 2003	TSS	Intraop/POD 19	PA	Covered stent ICA patent, no endoleak	Dysphasia/hemiparesis	1 yr	Full recovery
Kocer et al., 2002	TSS	Intraop/intraop	CCF	Covered stent ICA patent, no endoleak	No deficits	3 mos	Good

IA = intraarterial; IVH = intraventricular hemorrhage; PID = postintervention day; PIM = postintervention month; PIW = postintervention week; postembo = postembolization.

version (3). The mean time from operation to endovascular treatment for these cases was 1138 days (range 2 days–20 years, median 28 days).

Endovascular ICA Sacrifice

Institutional Cases

Cases 1, 2, and 3 from our institutional experience showed complete ipsilateral ICA occlusion after therapeutic sacrifice. Figure 4 shows representative angiography images (Case 2). Postoperatively, Cases 1 and 3 had no neurological deficits on most recent follow-up (107 and 58 months); however, Case 3 had mild right-sided hemiparesis and expressive aphasia postoperatively, which resolved prior to discharge. Case 2 developed a small permanent visual field defect 1 day after ICA sacrifice. Postprocedure angiography demonstrated good filling of the ipsilateral ophthalmic artery; however, a diminished retinal blush was noted.

Analysis of Institutional and Literature Cases

Literature review and the current series identified 46 cases in which the patient underwent endovascular ICA sacrifice. Devices used included balloons (26 cases),^{2,19, 26,34–36,43,48,63–66,68,70,73,85,86} coils (16),^{8,19,21,27–29,31,41,44,89} balloons

with coils (2),^{17,18} the Amplatzer vascular plug (1),³⁰ and methods not reported (1)⁷⁷ (Table 2). Extracranial-intracranial (EC-IC) bypass was performed in 2 cases.^{41,73} Injury types included pseudoaneurysms (24 cases), active bleeding (10), carotid-cavernous fistula (CCF) (2), stenosis (3), dissection (1), vessel irregularity (2), and not reported (4). Clinical outcomes were not reported in 3 cases. New neurological deficits were reported in 13 (28.3%) of 46 cases. Neurological improvement was reported in 9 of 13 cases that had a neurological deficit (6 of 13 partial, 3 of 13 full), leaving 10 (21.7%) of 46 cases with at least some associated neurological deficit. Death was reported in 3 cases, with 2 from sequela of cerebral infarction (postprocedure Days 2 and 6).^{43,63} The third death was related to primary disease and not ICA sacrifice.¹⁹

Endovascular ICA Lesion Embolization

Institutional Cases

Case 4 from our institutional series received stent-assisted coiling using the Enterprise stent for a wide-necked, 5-mm pseudoaneurysm. Preprocedural angiography demonstrated poor collateral circulation. Treatment was deferred for 3 days following transsphenoidal surgery to allow time for healing before starting dual antiplatelet

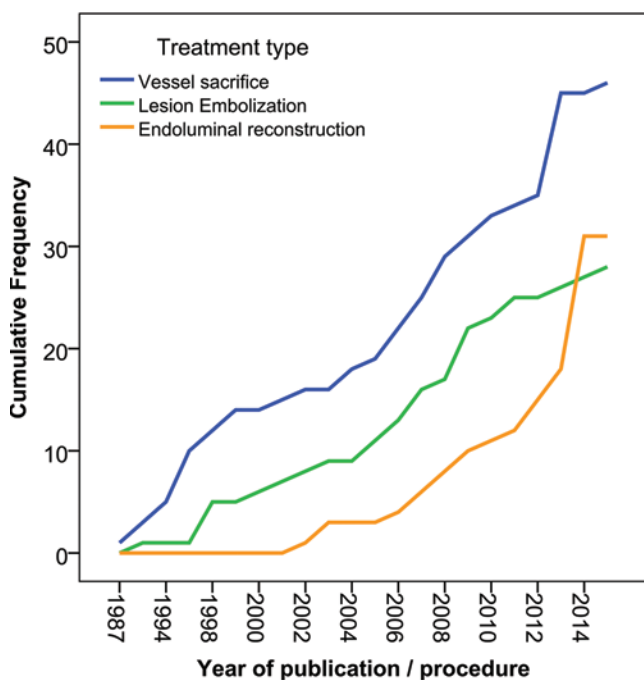
TABLE 4. Literature review of endovascular ICA lesion embolization following endonasal surgery

Authors & Year	Surgery Type	Injury/Tx Timing	Injury Type/Details	Embolization Technique & Outcome	Neurological Outcome	FU	Last Reported Outcome
Current series: Case 4	TSS	Intraop/intraop	PA	Stent-coil Residual, ICA patent	Stroke	22 days	Death
Case 6	TSS	POM 2/POM 2	PA	Coils Obliterated PIM 4: recurrence, stent-coil PIM 12: recurrence, Onyx PIM 36: spontaneous ICA occlusion	No deficits	3 yrs	Good
Patel et al., 2015	TSS	Intraop/POD 1	PA	Onyx Residual PID 12: recurrence, additional Onyx	No deficits	3 mos	Good
Dedmon et al., 2014	ESS	Intraop/intraop	PA	Coils Obliterated PID 7: recurrence, additional coils PID 9: epistaxis, ICA sacrifice coils & Onyx PIM 2 & 16: coil extrusion	No deficits	16 mos	Good
Tuchman et al., 2013	TSS	POW 6/POW 6	PA	Stent-coil Obliterated	Hemiparesis	NR	Full recovery
Gondim et al., 2011	TSS	Intraop/intraop	PA	Stent-coil Obliterated	No deficits	6 mos	Good
	TSS	Intraop/intraop	PA	Stent-coil Obliterated	Hemiparesis	6 mos	Partial recovery
Berker et al., 2010	TSS	Intraop/intraop	Aneurysm laceration	Stent-coil Obliterated	No deficits	NR	Good
Struffert et al., 2009	Endo	Intraop/POD 20	PA	Coils Obliterated PID 5: carotid ligation PIM 26: coil extrusion	No deficits	26 mos	Good
	TSS	POD 10/POD 10	PA	Stent-coil Obliterated PIM 9: coil extrusion	No deficits	21 mos	Good
Medel et al., 2009	TSS	Intraop/POM 6	PA	Onyx Obliterated	No deficits	4 mos	Good
Kalia et al., 2009	TSS	Intraop/intraop	CCF	Stent-coil Obliterated PIM 1: recurrence, covered stent placed, no endoleak	No deficits	2.5 yrs	Good
Cathelinaud et al., 2008	ESS	Intraop/POW 2	PA	Stent-coil Obliterated	No deficits	48 mos	Good
Buerke et al., 2007	ESS	Intraop/POD 27	PA	Coils Obliterated	No deficits	10 mos	Good
Dusick et al., 2007	TSS	Intraop/intraop	PA	Coils Obliterated	No deficits	NR	NR
Hattori et al., 2006	TSS	Intraop/POY 8	PA	Coil Residual PIW 4: epistaxis, ICA sacrifice, poor collateral circulation, EC-IC bypass	No deficits	NR	NR
Ciceri et al., 2006	TSS	NR/POY 1	PA	Stent-coil Obliterated	No deficits	4 yrs	Good
Vergez et al., 2005	TSS	POD 2/POD 2	PA	Coils Obliteration	No deficits	NR	Good

(continued)

TABLE 4. Literature review of endovascular ICA lesion embolization following endonasal surgery (continued)

Authors & Year	Surgery Type	Injury/Tx Timing	Injury Type/Details	Embolization Technique & Outcome	Neurological Outcome	FU	Last Reported Outcome
Vergez et al., 2005	Endo	POY 14/POY 14	PA	Coils Rupture, BTO passed, ICA occlusion	No deficits	NR	Good
Zada et al., 2003	TSS	Intraop/POD 6	PA	Coils Obliterated	No deficits	NR	Good
Kadyrov et al., 2002	TSS	Intraop/POW 5	PA	Coils Residual PIW 2: migration, stent-coil, obliterated	No deficits	1 yr	Good
Cappabianca et al., 2001	TSS	Intraop/intraop	PA	Coils Obliterated	No deficits	1 yr	Good
Kobayashi et al., 2000	TSS	Intraop/intraop	CCF	Coils Obliterated	No deficits	10 mos	Good
Chen et al., 1998	TSS	Intraop/POW 2	PA	Coils Obliterated	No deficits	1 yr	Good
Lempert et al., 1998	TSS	Intraop/POW 5	PA	Coils Obliterated	No deficits		Good
	TSS	Intraop/POM 1	PA	Coils Obliterated	No deficits	4 mos	Good
	TSS	Intraop/POY 1	PA	Coils Obliterated	No deficits	12 mos	Good
Ahuja et al., 1992	TSS	Intraop/POY 3	CCF	Balloon Obliterated PID 5: balloon deflation, replaced, obliterated	No deficits	1 yr	Good

**FIG. 1.** Line graph showing cumulative frequency of endovascular treatment types including ICA sacrifice (*blue*), lesion embolization (*green*), and endoluminal reconstruction (*orange*) from 1987 to 2015. Figure is available in color online only.

therapy. Postprocedure angiography demonstrated near-total obliteration of the pseudoaneurysm with stent patency. This patient had multiple preoperative comorbidities, which contributed to postprocedure morbidity (e.g., myocardial infarction, cerebral infarction), and expiration 1 month later. Case 6 received coil embolization without stent assistance for an 18-mm pseudoaneurysm 2 months after transsphenoidal surgery at an outside hospital (Fig. 5). Prior to admission for treatment, the patient received several blood transfusions despite nasal packing for epistaxis. Preembolization angiography demonstrated poor collateral circulation. Postembolization angiography at 4 months showed coil compaction, which required placement of a Neuroform stent over the aneurysm neck and the introduction of additional coils. Brisk epistaxis occurred 8 months later, and angiography revealed pseudoaneurysm recurrence, which was near completely obliterated using Onyx (HD-500). Angiography performed 2 years later revealed complete ICA occlusion, with good collateral flow via the ophthalmic artery, ACoA, and pial collaterals, with limited PCoA collateral flow. Occlusion was likely due to Onyx coating the intraarterial stent tines and patient noncompliance with antiplatelet medication. No neurological deficits were noted in the postoperative period.

Analysis of Institutional and Literature Cases

A literature review and the current series identified 28 cases receiving endovascular ICA lesion embolization. Injury types included pseudoaneurysms (24 cases), CCF (3), and aneurysm laceration (1). Techniques included stent-as-

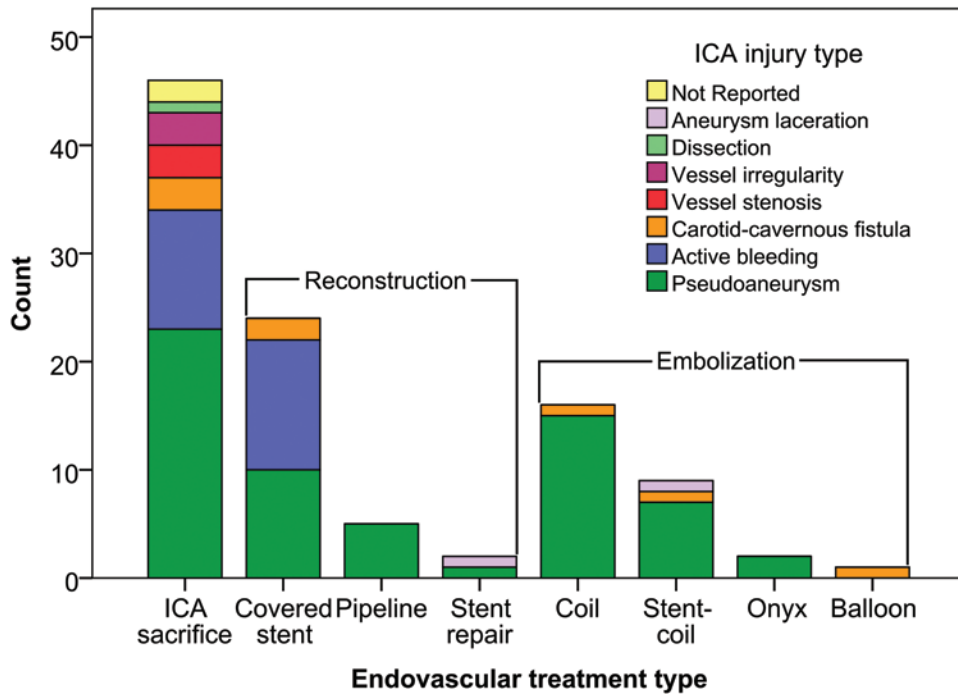


FIG. 2. Bar graph showing counts for the types of ICA injuries reported binned by the endovascular treatment type that was used. Figure is available in color online only.

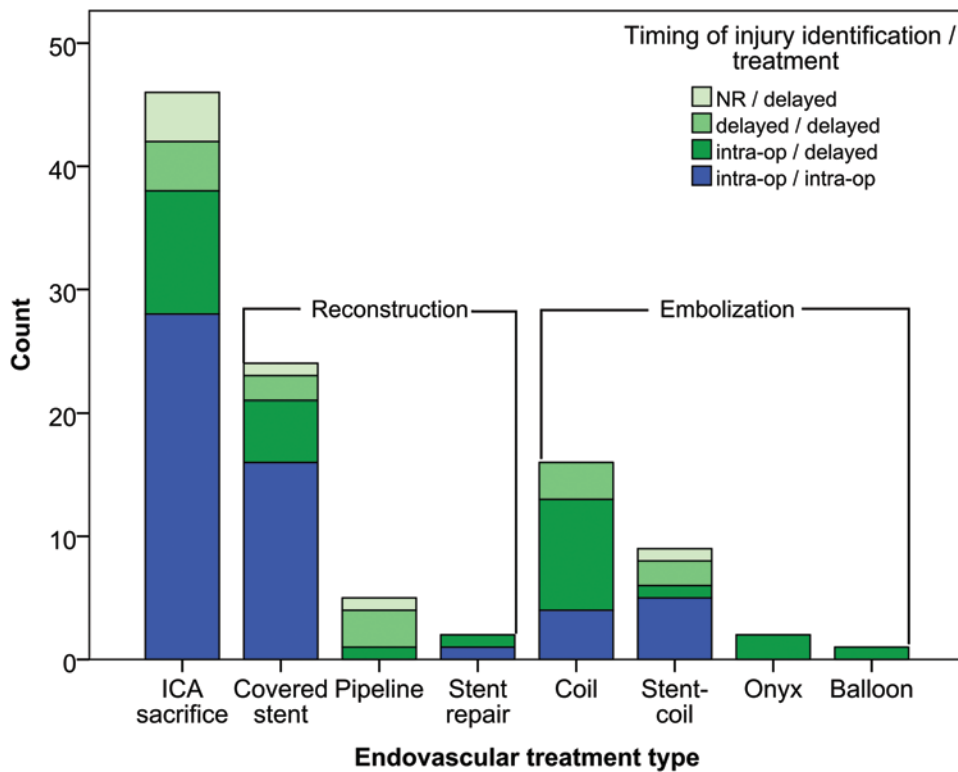


FIG. 3. Bar graph showing counts for the timing of ICA injury identification and treatment binned by the endovascular treatment type (*blue* indicates intraoperative, shades of *green* indicate delayed). Figure is available in color online only.

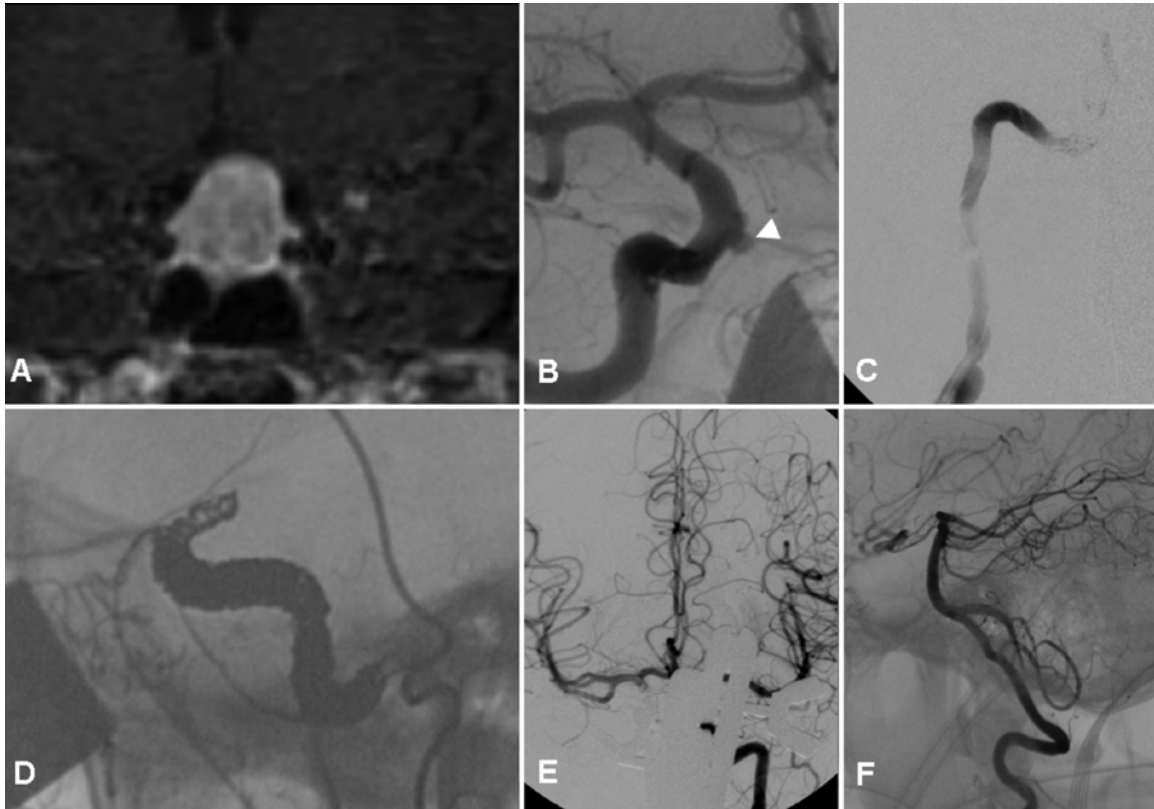


FIG. 4. Case 2. Representative angiographic images showing a pituitary adenoma with suprasellar extension and cavernous sinus invasion (A) and a small pseudoaneurysm on the arterial phase diagnostic angiogram after right ICA injury (white arrowhead) (B). Sacrifice of the right ICA on arterial phase angiography (C) with coils extending from distal to the ophthalmic artery origin to the petrous ICA segment on lateral fluoroscopy (D). Left carotid (E) and vertebral artery (F) arterial phase angiograms demonstrating good collateral circulation.

sisted coiling (9 cases),^{6,12,18,31,42,79,81} coil embolization without stenting (16),^{10,11,17,23,25,33,40,46,50,79,90} balloon embolization without stenting (1),² and Onyx embolization (2).^{61,67} (Table 3). Completely successful treatment (lesion obliteration, ICA patency, no neurological deficits, no additional treatment) was achieved in 16 (57.1%) of 28 cases, which by treatment type was 4 (44.4%) of 9, 10 (62.5%) of 16, 0 (0%) of 1, and 1 (50%) of 2 cases, respectively. Minimal technical complications from stent-assisted coiling included covered stent placement for CCF recurrence (1 case) and hemiparesis with full recovery (1), while more significant complications included coil extrusion 9 months after the stent placement was removed endoscopically (1) and partially resolved hemiparesis (1). In addition, Case 4 in our series went on to have multiple strokes; however, these were in multiple vascular distributions and not due specifically to endovascular treatment. Technical complications following coil embolization without stenting occurred in 6 of 16 cases. Only 1 of these complications could be considered minor (coil migration requiring stent-assisted coiling). The remaining major technical complications (resulting in injury/ICA sacrifice/new deficit) included recurrence (3 cases; treated with ICA sacrifice [1], pseudoaneurysm trapping with EC-IC bypass [1],³³ or stent-assisted coiling and Onyx with incidental ICA sacrifice [1]), pseudoaneurysm rupture requiring ICA sacrifice (1), and coil

extrusion (1). The 1 case of balloon embolization without stent was complicated by balloon deflation and fistula reopening, requiring placement of a larger balloon. One of the 2 reported Onyx embolization cases was complicated by incomplete embolization, requiring additional Onyx. New neurological deficits were noted after ICA lesion embolization in 3 (10.7%) of 28 cases. Neurological improvement was reported in 2 of 2 patients who had a neurological deficit (1 partial, 1 full).

Endoluminal Reconstruction

Institutional Cases

Flow diversion with the PED was used for pseudoaneurysm obliteration for Cases 5 and 7 in our series. Both cases had delayed endovascular treatment after transphenoidal surgery (15 days and 20 years, respectively) and were considered safe candidates for dual antiplatelet therapy. Case 5 had a growing 3-mm pseudoaneurysm discovered in the early postoperative period that was treated successfully with PED placement, with clinical follow-up showing pseudoaneurysm obliteration at 6 months and no neurological deficits at 16 months after endovascular treatment (Fig. 6). Case 7 had a recurrent 5-mm area of pseudoaneurysm near the base of a 20-year-old pseudoaneurysm previously treated with coiling at an outside hospital after

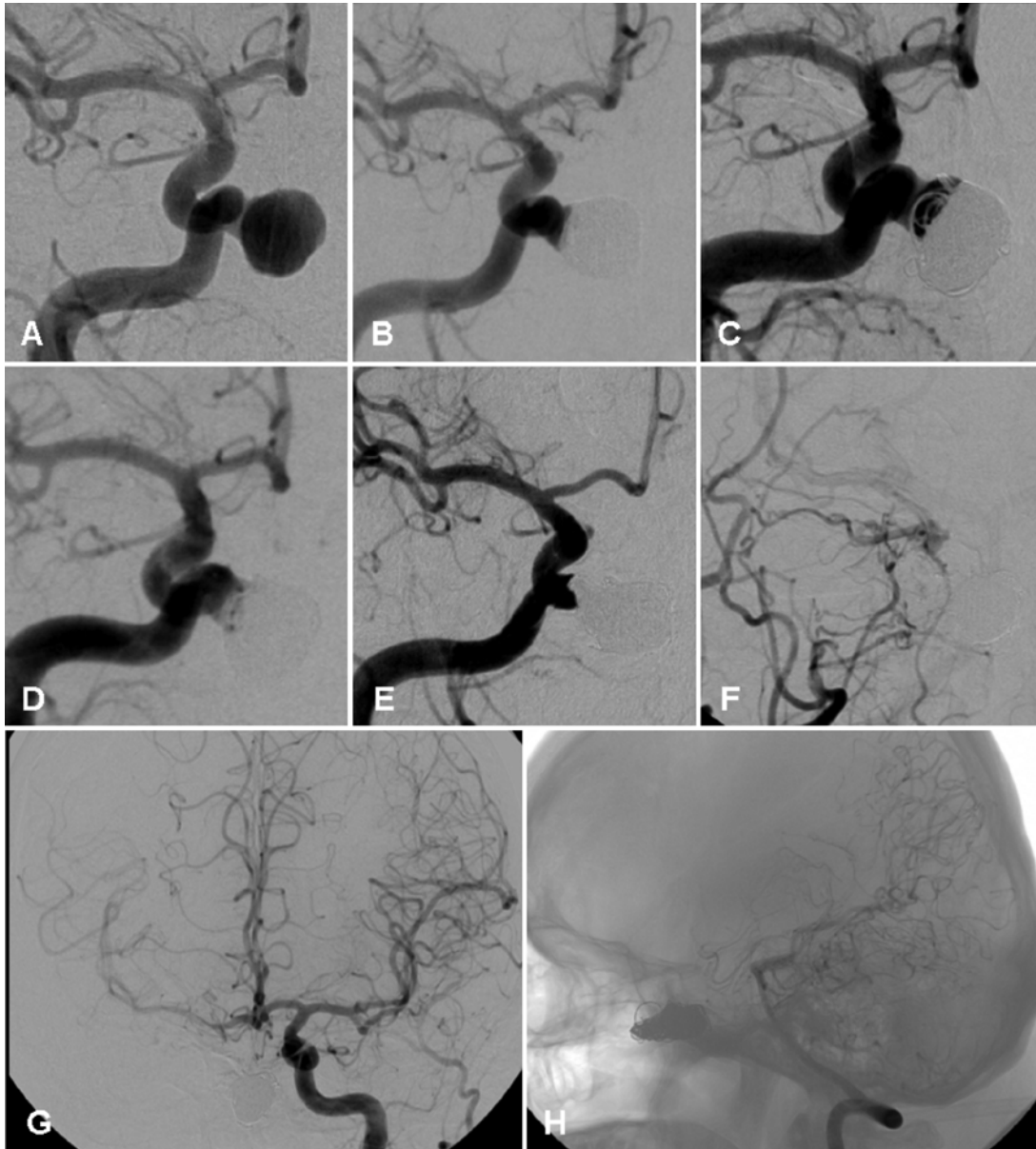


FIG. 5. Case 6. Arterial phase angiographic images. **A:** Large pseudoaneurysm following transsphenoidal pituitary adenoma resection and ICA injury at an outside hospital. **B:** Coil placement without stent assistance showing near-complete obliteration of the pseudoaneurysm 2 months after pituitary adenoma resection. **C:** Coil compaction and recurrence of aneurysm 4 months after coiling, with subsequent stent-assisted coiling (**D**). **E:** Angiographic image obtained 1 year after stent-assisted coiling; the patient presented with severe epistaxis and pseudoaneurysm recurrence, which was obliterated using Onyx. **F:** Follow-up image obtained 1 year later showing complete occlusion of the right ICA. **G:** Good collateral flow is demonstrated from the left ICA across the ACoA; however, the PCoA only offered a weak contribution (**H**).

transsphenoidal surgery (Fig. 7). The patient had intermittent epistaxis and did not require nasal packing. Decreased flow in the pseudoaneurysm was noted after PED placement, and the patient suffered no new neurological deficits. Unfortunately, this patient was lost to follow-up; thus, longer clinical outcomes data are not available.

Analysis of Institutional and Literature Cases

A literature review and the current series identified 31 cases that received endovascular ICA endoluminal recon-

struction. Techniques included covered stent placement (24 cases),^{19,22,24,30,32,43,44,47,51,54,74,76,83,85} multiple uncovered stents (1),²⁹ flow diversion (5),^{4,62} and stenting method not reported (1)¹⁶ (Table 4). Injury types included pseudoaneurysms (16 cases), active bleeding (12), CCF (2), and aneurysm laceration (1). Flow diversion was used exclusively for pseudoaneurysm repair. Treatment outcomes were not reported in 2 cases (1 stent method was reported and 1 flow diverter). Completely successful treatment (lesion obliteration, ICA patency, no neurological deficits, no additional

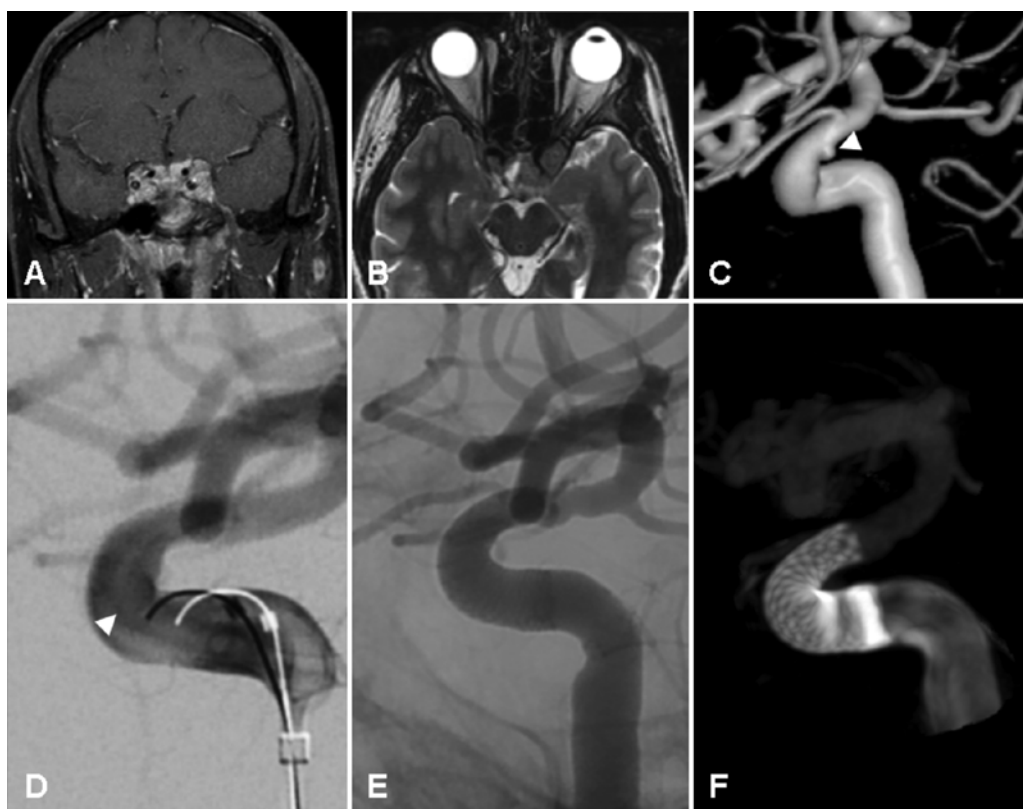


FIG. 6. Case 5. **A and B:** Preoperative coronal T1-weighted gadolinium-enhanced (A) and axial T2-weighted (B) MR images showing distorted ICA anatomy following prior transsphenoidal surgery and recurrence of a large pituitary adenoma. **C and D:** 3D rotational reconstruction and arterial phase angiographic images obtained 5 days after surgery showing a 2-mm right ICA pseudoaneurysm proximal to the junction of the cavernous and clinoid segment of the ICA (white arrowheads). **E and F:** Arterial phase and dyna CT scan showing placement of a PED.

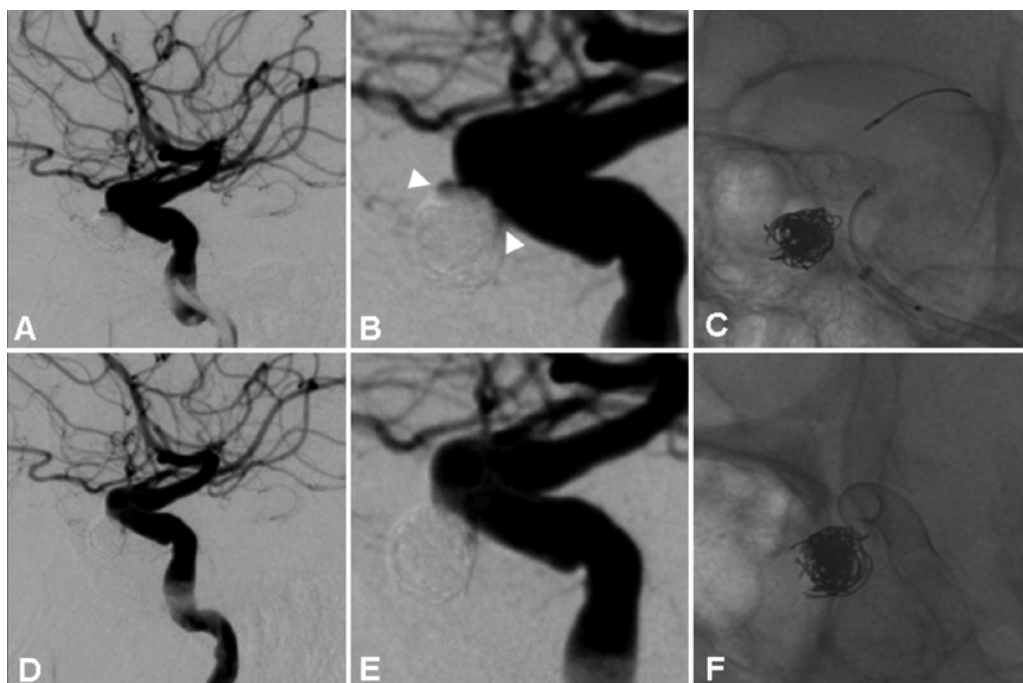


FIG. 7. Case 7. This patient presented with coil extrusion through the nose and epistaxis. **A–D:** Angiographic images showing an ICA pseudoaneurysm (arrowheads) resulting from transsphenoidal surgery that was perioperatively coiled 20 years prior. **E and F:** Angiographic images obtained after PED placement, which resulted in resolution of symptoms without ipsilateral ICA stenosis.

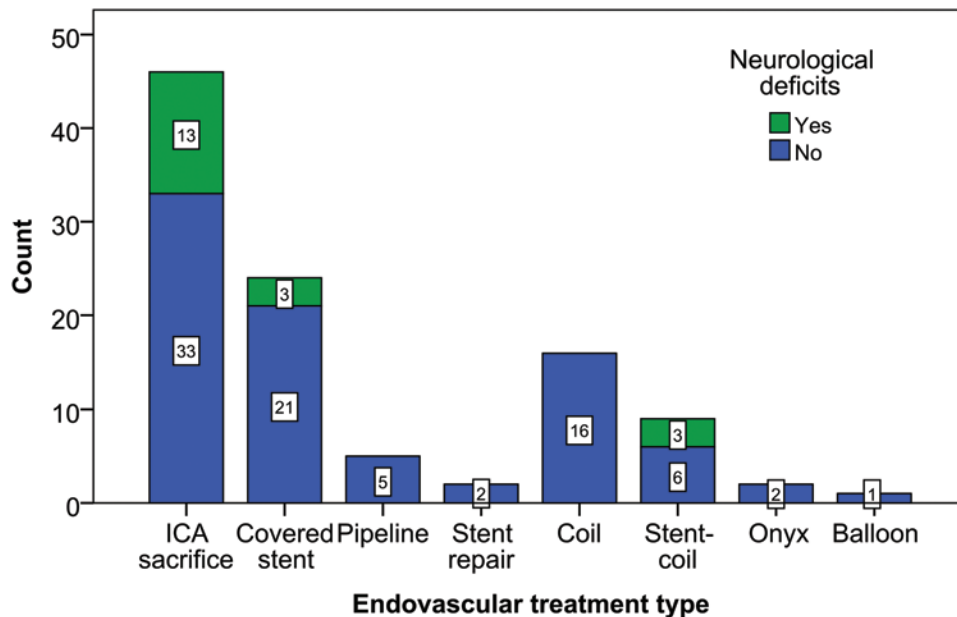


FIG. 8. Bar graph showing counts for presence or absence of neurological deficits associated with endovascular treatment binned by endovascular treatment type. Figure is available in color online only.

treatment) was achieved in 14 (58.3%) of 24 cases, 1 of (100%) 1, and 3 (75%) of 4, respectively, for each treatment type. Only minimal technical complications were reported in 8 (80%) of 10 covered stent placements that did not have completely successful treatment including temporary stroke symptoms (1 case), abciximab for in-stent thrombosis (3) and covered stent (1), flow diverter (1), or bare stent (2) for endoleak. More significant treatment complications include rebleeding with ICA sacrifice (1 case) and intraventricular hemorrhage requiring EVD placement and intensive care management (1 case); both cases resulted in mortality. New neurological deficits were noted after ICA endoluminal reconstruction in 1 (3.6%) of 28 cases that did not result in mortality, and full neurological recovery was noted. A death from sepsis unrelated to ICA injury was reported 3 months after flow diverter placement.

Outcomes From Institutional and Literature Cases

The distribution of neurological deficits by endovascular treatment type is shown in Figs. 8 and 9. Neurological deficits associated with ICA injury treatment were reported in 19 (18.1%) of 105 cases (Fig. 8). Full recovery was noted in 5 (26.3%) of 19 cases, partial recovery in 7 (36.8%) of 19, no recovery in 2 (10.5%) of 19, and death in 5 (26.3%) of 19 (Fig. 9). The distribution of technical problems by endovascular treatment type for endoluminal reconstruction and lesion embolization is shown in Figs. 10 and 11. Technical problems were reported in 24 cases (Fig. 10), with 9 of 24 cases having major technical problems and 15 of 21 having minor technical problems reported (Fig. 11; Table 5). Timing of postprocedural clinical follow-up was reported in 72 (68.6%) of 105 cases and ranged between 1 day and 107 months. In cases with at least 1 year of follow-up (33 of 72), no new neurological deficits were reported to be associated with ICA injury treatment.

Discussion

Given the severity of ICA injury, the treatment team should have a standardized protocol for definitive perioperative management during endonasal surgery. Careful technique is paramount, but even large series from experienced centers show that ICA injury occurs in 0.2%–2.0% of cases. A recent study of the Nationwide Inpatient Sample quoted a 0.1% rate of endovascular intervention following transsphenoidal surgery, with nearly identical rates between low and high volume center (0.2% vs 0.1%, respectively).⁹ We recommend that neurointerventional radiology services be available whenever performing endonasal surgery. High-risk procedures should likely be performed at Comprehensive Stroke Centers, which require around the clock endovascular coverage.³ It is not our practice to obtain preoperative angiography, even when risk factors are present, as distortion of ICA anatomy and ICA aneurysms can generally be detected on routine MRI sequences; however, preoperative angiography could be considered in higher-risk situations. The type of endovascular treatment should be selected carefully after consideration of multiple factors. Figure 12 illustrates a proposed algorithm for the management of ICA injury.

Sacrifice of the ICA with endovascular coiling remains the definitive method for managing ICA injury and should be considered strongly in cases of acute, uncontrolled bleeding. BTO or some form of angiographic assessment of collateral circulation should be performed in all patients considered for ICA sacrifice. A relatively low risk of permanent neurological deficit has been associated with BTO (0.4% in 1 study).^{58,78} Patients with intraoperative ICA injury identification and treatment were under general anesthesia for the BTO; therefore, collateral flow was assessed angiographically,¹ without the benefit of neurological assessments or post-BTO nuclear medicine

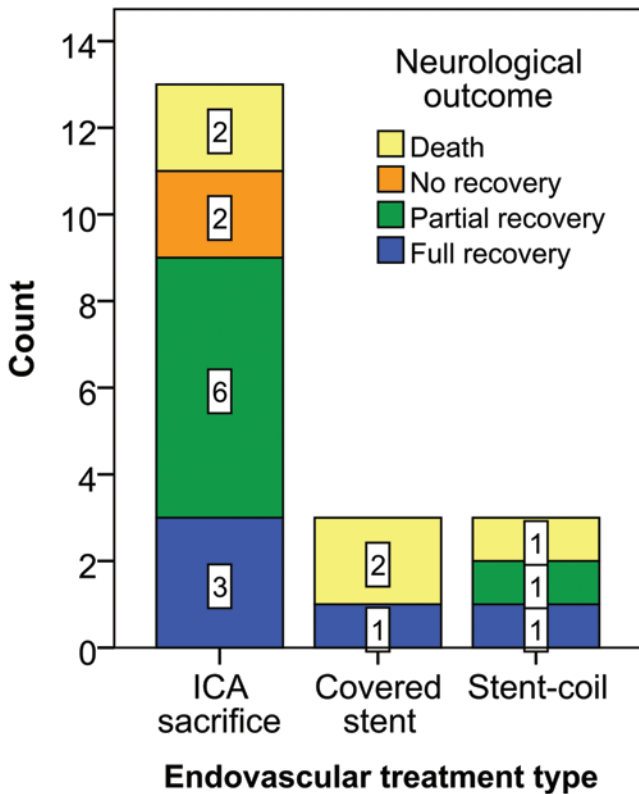


FIG. 9. Bar graph showing counts for neurological outcome following initial neurological deficit associated with endovascular treatment binned by endovascular treatment type. Neurological outcomes are defined as full recovery (blue), partial recovery (green), no recovery (orange), and death (yellow). Figure is available in color online only.

SPECT imaging.^{55,75} The decision to perform ICA sacrifice in 3 cases (Cases 1, 2, and 3) was determined based on 1) good collateral filling demonstrated on BTO (all 3 cases); 2) persistent extravasation of blood observed on angiography (Case 3); and 3) contraindication for dual antiplatelet therapy (Case 3 and/or 4) and ICA injury prior to stent usage at our institution (Case 1). Cases 2 and 3 developed mild and/or transient symptoms potentially associated with coil occlusion. Including our series, 46 patients received ICA sacrifice following endonasal surgery, with an associated permanent neurological complication rate of 21.7%. No patients had recurrence of bleeding. A study from our institution reported on 37 patients who received ICA sacrifice for various indications (mainly head/neck tumors involving the ICA and ICA aneurysms), with a 16.2% ipsilateral stroke rate within 1 month of the procedure.⁸⁷ While these results indicate that ICA sacrifice can provide durable injury control, the rate of neurological deficits following treatment can be high, and the potential future consequences as the patient ages are unclear. It is our suggestion that the default treatment strategy for ICA injury after endonasal surgery should, if possible, be an appropriate form of vessel preservation, and that endovascular ICA sacrifice should be considered only when necessary or as a salvage option.

Determining eligibility for dual antiplatelet therapy is of primary importance early in the decision-making

process following identification of ICA injury. Dual antiplatelet therapy is required following stent graft or flow diverter placement to minimize risks of stent thrombosis and distal emboli, but this treatment increases the risk of perioperative hemorrhage. If the patient is deemed to have a temporary contraindication for dual antiplatelet therapy (e.g., postoperative), then delay in treatment could be considered. Factors suggesting an urgent need for treatment include active bleeding, large pseudoaneurysm, and a significant mechanism of injury. Case 5 in the current series was delayed until 15 days after surgery before PED placement over a small pseudoaneurysm. This strategy may carry an increased risk of ICA lesion rupture, which must be weighed against the risk of dual antiplatelet therapy. A literature review revealed no intracranial hematoma for the 22 patients who received initiation of dual antiplatelet therapy the same day as surgery for covered stent (16 patients), stent-assisted coiling (5), or unspecified stent (1) placement. It has been proposed that residual tumor could be a relative contraindication for dual antiplatelet therapy given the risk of bleeding from healing vasculature within the tumor.⁶²

Patients with active bleeding or CCF who are good candidates for dual antiplatelet therapy should initially be considered for covered stent placement. Case reports have described the use of the JoStent (Jomed International) and Symbiot self-expanding stent (Boston Scientific/Scimed) to exclude pseudoaneurysm or close lacerations. These stents have also been shown to be effective for the treatment of traumatic CCF and maintain good patency.⁴⁵ Case 3 in the current series had active bleeding identified on angiography, but the decision was made to perform ICA sacrifice instead of covered stent placement based on 1) good collateral circulation on BTO and 2) residual prolactinoma, and the potential need for future surgery increased concern for initiating dual antiplatelet therapy. A literature review indicated that covered stent placement was generally well tolerated, with 58.3% of the procedures resulting in successful treatment (lesion control, no persistent neurological deficit) with covered stent placement only and an additional 33.3% having minimal technical complications (transient stroke symptoms, abciximab for in-stent thrombosis, endovascular endoleak repair). In contrast to these results, it appears that treatment failure can be catastrophic as evident by the reported 2 deaths. One patient died after rebleeding, likely secondary to poor stent apposition and dual antiplatelet therapy, followed by an adequate BTO, ICA sacrifice, and ipsilateral ischemic stroke.³² The other death was the result of intraventricular hemorrhage, presumably due to endoleak in a patient with already inhibited platelet function.³⁰ Covered stent rigidity, which can be problematic given the tortuosity of the cavernous ICA, likely contributed to both of these complications. A variety of methods have been reported to improve stent apposition and resolve endoleak including placement of coils between the stent and vessel wall and deploying bare stents or flow diverters in a telescoping manner.^{32,45,72,76} Another potential risk of covered stent placement is occlusion of branching arteries (e.g., ophthalmic artery), but the cited studies do not report this complication. Vasospasm has also been reported following placement of a covered

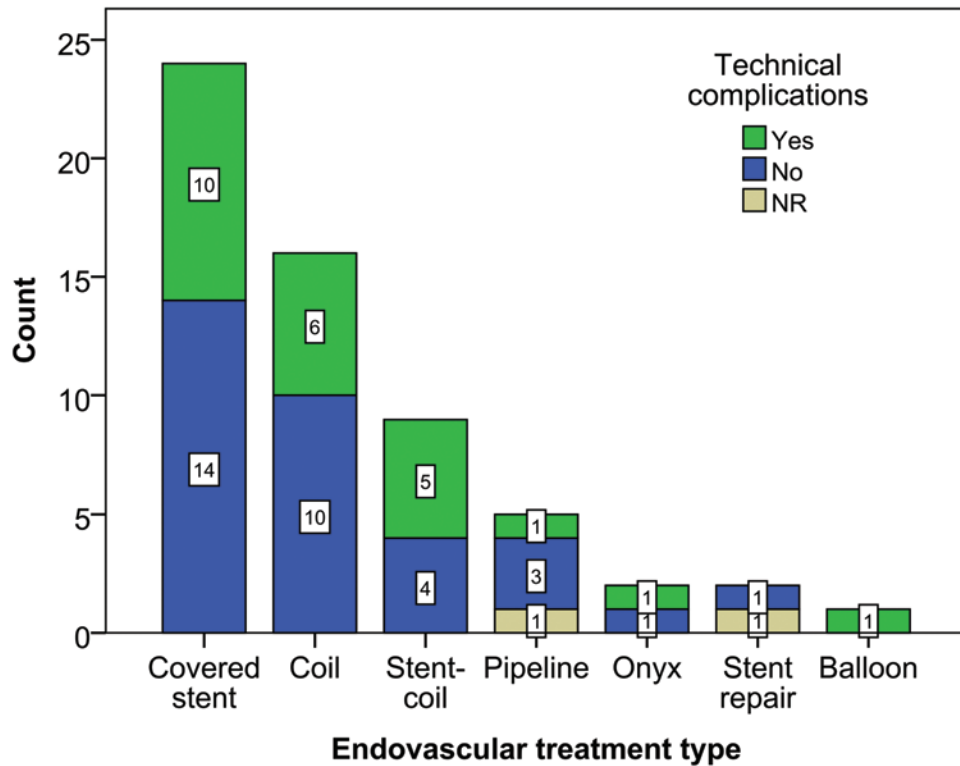


FIG. 10. Bar graph showing counts for presence or absence of technical complications following endovascular treatment binned by endovascular treatment type. NR = not reported. Figure is available in color online only.

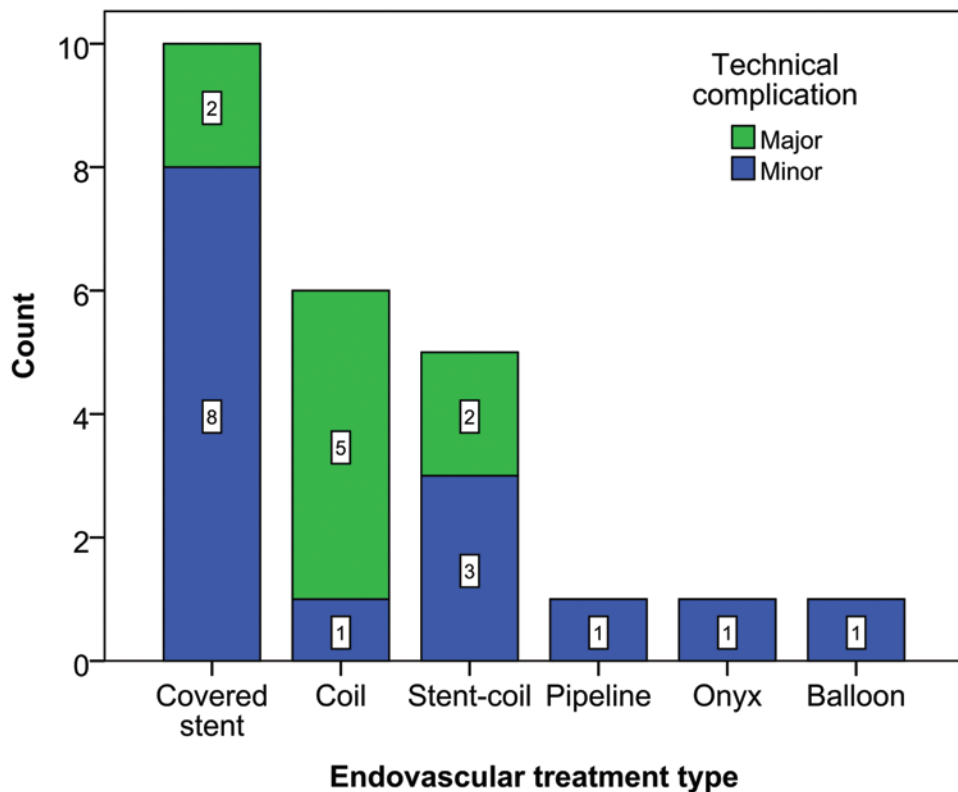


FIG. 11. Bar graph showing counts for technical complications divided into major (resulting in injury/ICA sacrifice/new deficit; blue) and minor (green) categories. Figure is available in color online only.

TABLE 5. Summary of technical complications from literature review

Tx Type & Complications	Solution	Outcome
Major complications		
Covered stent		
IVH	EVD	Stroke, death
Recurrence	Sacrifice	Stroke, death
Coil		
Coil extrusion	TSS	Coil removal, no deficits
Recurrence	Multiembolization	Spontaneous occlusion, no deficits
Recurrence (×2)	Sacrifice (×2)	No deficits (×2)
Residual	EC-IC bypass, sacrifice	Patent graft, no deficits
Stent-coil		
Coil extrusion	TSS	Coil removal, no deficits
Hemiparesis	Observation	Partial recovery
Minor complications		
Covered stent		
Endoleak (×4)	Graft placement (×4)	No endoleak, no deficits
Thrombosis (×3)	Abciximab (×3)	Stent patent, no deficits
Hemiparesis	Observation	Full resolution
Pipeline		
Endoleak	Angioplasty	Stent patent, no deficits
Stent-coil		
Residual	Observation	Unrelated stroke, death
Recurrence	Graft placement	No endoleak, no deficits
Hemiparesis	Observation	Full recovery
Coil		
Residual/recurrence	Embolization	Obliteration, no deficits
Onyx		
Recurrence	Embolization	Obliteration, no deficits
Balloon		
Failure	Embolization	Obliteration, no deficits

stent in a tortuous ICA segment, but this resolved without consequence after intraarterial papaverine infusion.⁴⁷ In-stent thrombosis is another concerning issue, but this complication has been treated effectively, as reported by Kim et al., using abciximab in 3 of 7 cases.⁴⁴ Failure or expected failure of covered stent placement in these patients can be treated with ICA sacrifice with or without high-flow EC-IC bypass, depending on the adequacy of collateral circulation. In complicated situations, other operative

options include craniotomy with direct repair of the ICA within the cavernous sinus or trapping the aneurysm via cervical carotid ligation; supraclinoid ICA clip ligation can also be considered. Similar to the EC-IC bypass case in the series of Raymond et al.,⁷³ a case report from 2001 documented an ICA injury during transsphenoidal surgery with failed BTO, ICA occlusion, and EC-IC arterial bypass from the proximal external carotid artery to the middle cerebral artery, resulting in successful ICA occlusion and bypass graft patency.⁴¹ Rangel-Castilla et al. reviewed 235 EC-IC bypasses performed in a 7-year period. Eight of these cases occurred after ICA injury during transsphenoidal resection and/or failed endovascular management. All bypasses were patent at the end of available follow-up (3–36 months), and all cases had modified Rankin Scale scores of either 0 or 1.⁷² Based on these studies, one could consider EC-IC bypass to augment the cerebral circulation after ICA injury.

Patients with a pseudoaneurysm who are good candidates for dual antiplatelet therapy should initially be evaluated for vessel preservation with either covered stent, stent-assisted coiling, or flow diverter placement. Covered stent remains a reasonable treatment option for many patients in this group for reasons described above. Stent-assisted coiling facilitates aneurysm obliteration by limiting coil herniation into the parent artery and has been adopted for the treatment of certain saccular aneurysms (e.g., wide necked)^{5,13} and traumatic pseudoaneurysms.⁴⁰ Currently, the 2 most commonly used devices are the Enterprise^{52,53} and Neuroform⁷¹ stents. Case 4 in the current series achieved near-total pseudoaneurysm obliteration with good vessel patency using the Enterprise device, but the patient died of comorbidity 22 days after the procedure. In Case 6 in the current series, a Neuroform stent was used for treatment of a residual pseudoaneurysm neck, which later required additional embolization with Onyx before unintended ICA occlusion. A comparison of the Enterprise and Neuroform stents used for procedures at our institution suggested that the Enterprise stent was easier to deploy in tortuous ICA segments but was associated with increased thrombotic events compared with the Neuroform stent.³⁷ A literature review and the current series identified 9 cases primarily treated with stent-assisted coiling, resulting in completely successful treatment in 4 cases (44.4%) and only minor treatment complications in 3 cases (33.3%). The remaining 2 cases had partially resolved hemiparesis and coil extrusion through the nose, which was treated with transsphenoidal surgery. The PED was approved by the Food and Drug Administration in April 2011 as the first flow-diverting device for intracranial use in the US and has been shown to be particularly effective for the treatment of wide-necked, large cerebral aneurysms^{15,57} and noninferior to stent-assisted coiling for small saccular aneurysms.¹⁴ Patients in 2 cases in the current series underwent PED placement; Case 5 achieved complete pseudoaneurysm obliteration, and Case 7 received 3 flow diverters but was lost to follow-up. Neither patient developed a postoperative neurological deficit. Amenta et al. reported complete exclusion of an ICA pseudoaneurysm at 6 months after PED placement.⁴ Nerva et al. reported complete obliteration of 2 pseudoaneurysms at 2 weeks and 4 months after PED

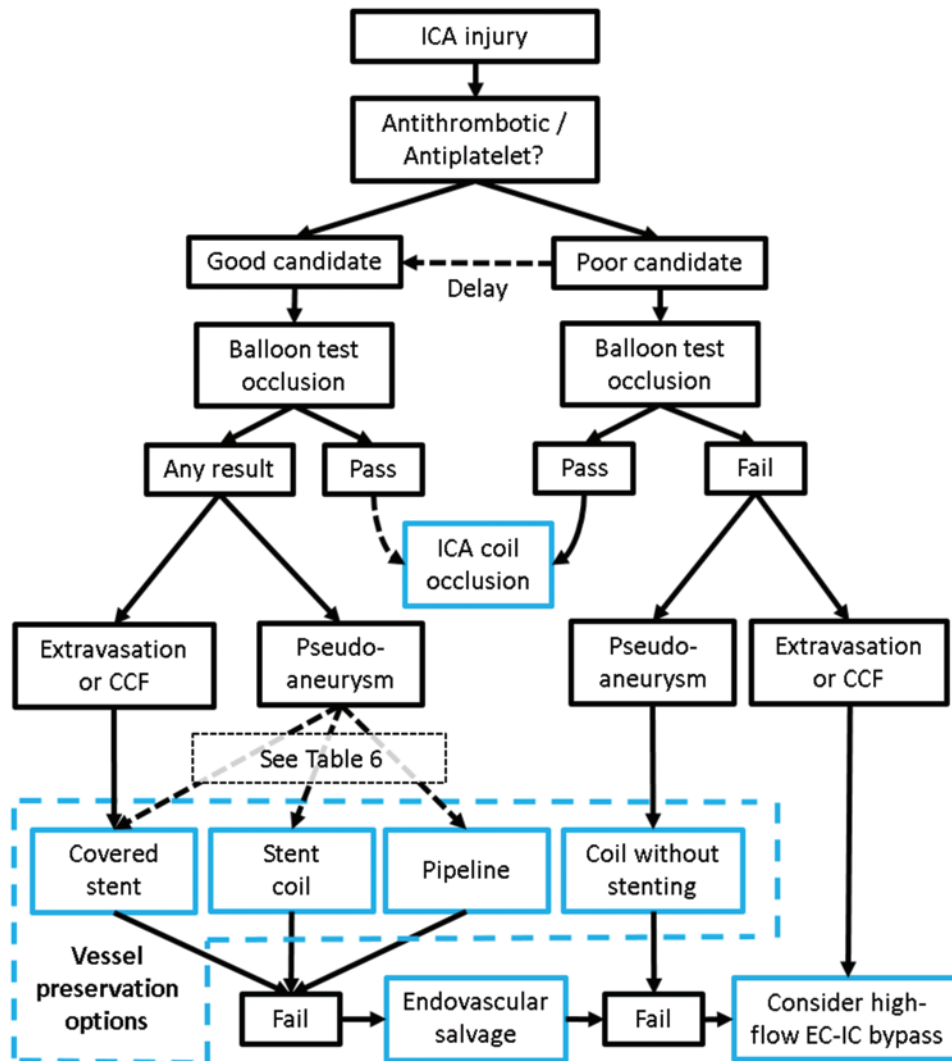


FIG. 12. Schematic showing the proposed algorithm for endovascular treatment for identified ICA injury after endonasal surgery. Dashed arrows represent options dictated by best clinical judgment; solid arrows represent treatment recommendations. Solid blue boxes represent endovascular and surgical treatment options. Dashed blue box represents available vessel preservation options. Figure is available in color online only.

placement.⁶² In the combined case series, no neurological deficits associated with PED placement were reported; however, 1 patient died of primary disease 3 months after treatment. Decision making for these patients should include factors such as urgent need for lesion control, tortuosity of ICA segment involved, presence of directly adjacent branching vessels, and pseudoaneurysm characteristics (Table 6). Covered stents are a reasonable option for nontortuous ICA segments when branching vessels will not interfere with deployment. Telescoping stents and coils can be used to improve apposition if needed. Flow diverters and stent-assisted coil placement may be preferred for cases in which tortuous ICA anatomy or branch vessel occlusion is a concern. Flow diverters require time (weeks to months) to thrombose the pseudoaneurysm and should not be used in cases with intermittent bleeding, enlargement, or concern for rupture.³⁸ A good aneurysm thrombosis rate (85%–90% at 6 months–1 year^{60,64,69,88}) and the absence of

risk of coil compaction or pseudoaneurysm rupture during placement make flow diversion a good treatment option for nonurgent lesions with poor coiling characteristics (e.g., wide neck or small dome due to segmental artery injury). In addition to the extended thrombosis time, another disadvantage of flow diversion is that a microcatheter cannot be advanced through the mesh, which limits future options for treatment in the instance of obliteration failure.⁸¹ Stent-assisted coiling is a good option for lesions with characteristics favorable for coiling and where there is need for urgent lesion control, with the principle risks being lesion rupture during placement and coil compaction. Again, ICA sacrifice and EC-IC bypass should be considered for patients with adequate and inadequate collaterals, respectively, if vessel preservation is deemed difficult or fails.

Patients who are poor candidates for dual antiplatelet therapy and either require urgent therapy or will never tolerate dual antiplatelet therapy have limited treatment

TABLE 6. Decision making: good candidates for dual antiplatelet therapy with iatrogenic ICA pseudoaneurysm

Variable	Covered Stent	Stent-Coil	Pipeline
Characteristic			
Need immediate lesion control	+	+	–*
Tortuous ICA segment	–†	+	+
Directly adjacent branching vessels	–	+	+
Narrow neck	+	+	+
Broad neck	+	–	+
Enlarging	+	–	–
Risk			
Stent thrombosis	+	+	+
Occlusion of branching vessels	+	–	–
Device compaction into lesion	–	+	–
Lesion rupture during placement	–	+	–
Rebleeding before lesion thrombosis	–	–	+

+ = yes; – = no.

* Pseudoaneurysms take weeks to months to thrombose after Pipeline placement.

† Covered stents have less flexibility, but can be buttressed with coils, stents, or Pipeline to improve vessel wall apposition and reduce endoleak.

options. ICA sacrifice should be initially considered for patients with good collateral circulation. For patients with pseudoaneurysms and poor collateral circulation, coil embolization of the lesion can be considered without stent placement. This strategy obviates the need for perioperative dual antiplatelet therapy but carries increased risk of coil compaction, rebleeding, and coil extrusion into the parent vessel or nasopharynx. This technique was used in Case 6 in the current series due to poor collateral circulation and perceived favorability of the aneurysm for coiling (i.e., narrow neck [4 mm], large aneurysm [18 mm]). Coil compaction after treatment led to enlargement of the aneurysm, which led to 2 additional endovascular treatments including stent-assisted coiling and Onyx embolization. The rate of major technical complication was high in this group (6 (37.5%) of 16 cases), and coil compaction was reported in 4 (25%) of 16 patients. Luo et al. cautioned against the use of coils alone for the treatment of acute traumatic carotid aneurysms, citing the inherent fragility, wide neck, and often indistinct anatomy of these aneurysms,⁵⁶ but these results suggest that this treatment may be a reasonable option, either as definitive or as a form of bridge therapy given the few choices available to these patients. Limited experience in 3 patients indicates that Onyx embolization may also be a good treatment option, but more experience is needed.^{61,67}

Conclusions

Several endovascular techniques are available for the management of the early and delayed identification of ICA injury following endonasal surgery. Vessel sacrifice remains the definitive treatment option in the acute setting and for patients who cannot tolerate dual antiplatelet

therapy and has been demonstrated to be reasonably well tolerated in select patients. Selection and timing of vessel-sparing treatment depends on multiple factors including anatomy, collateral circulation, presence of active hemorrhage versus pseudoaneurysm, and the estimated risk of therapeutic dual antiplatelet therapy. Endovascular treatment selection should be tailored to the unique features of each case.

Acknowledgments

We would like to thank IMRIS, Inc. for sponsoring the IMRIS Multicenter iMRI Neurosurgery Database (I-MiND), which was used to obtain case series data for this project. Study data were collected and managed using REDCap electronic data capture tools hosted at Washington University School of Medicine in St. Louis.

References

- Abud DG, Spelle L, Pötin M, Mounayer C, Vanzin JR, Moret J: Venous phase timing during balloon test occlusion as a criterion for permanent internal carotid artery sacrifice. *AJNR Am J Neuroradiol* **26**:2602–2609, 2005
- Ahuja A, Guterman LR, Hopkins LN: Carotid cavernous fistula and false aneurysm of the cavernous carotid artery: complications of transphenoidal surgery. *Neurosurgery* **31**:774–779, 1992
- Alberts MJ, Latchaw RE, Selman WR, Shephard T, Hadley MN, Brass LM, et al: Recommendations for comprehensive stroke centers: a consensus statement from the Brain Attack Coalition. *Stroke* **36**:1597–1616, 2005
- Amenta PS, Starke RM, Jabbour PM, Tjoumakaris SI, Gonzalez LF, Rosenwasser RH, et al: Successful treatment of a traumatic carotid pseudoaneurysm with the Pipeline stent: Case report and review of the literature. *Surg Neurol Int* **3**:160, 2012
- Benitez RP, Silva MT, Klem J, Veznedaroglu E, Rosenwasser RH: Endovascular occlusion of wide-necked aneurysms with a new intracranial microstent (Neuroform) and detachable coils. *Neurosurgery* **54**:1359–1368, 2004
- Berker M, Aghayev K, Saatci I, Palaoglu S, Onerci M: Overview of vascular complications of pituitary surgery with special emphasis on unexpected abnormality. *Pituitary* **13**:160–167, 2010
- Berker M, Hazer DB, Yücel T, Gürlek A, Cila A, Aldur M, et al: Complications of endoscopic surgery of the pituitary adenomas: analysis of 570 patients and review of the literature. *Pituitary* **15**:288–300, 2012
- Biswas D, Daudia A, Jones NS, McConachie NS: Profuse epistaxis following sphenoid surgery: a ruptured carotid artery pseudoaneurysm and its management. *J Laryngol Otol* **123**:692–694, 2009
- Brinjikji W, Lanzino G, Cloft HJ: Cerebrovascular complications and utilization of endovascular techniques following transphenoidal resection of pituitary adenomas: a study of the Nationwide Inpatient Sample 2001–2010. *Pituitary* **17**:430–435, 2014
- Buerke B, Tombach B, Stoll W, Heindel W, Niederstadt T: Magnetic resonance angiography follow-up examinations to detect iatrogenic pseudoaneurysms following otorhinolaryngological surgery. *J Laryngol Otol* **121**:698–701, 2007
- Cappabianca P, Briganti F, Cavallo LM, de Divitiis E: Pseudoaneurysm of the intracavernous carotid artery following endoscopic endonasal transsphenoidal surgery, treated by endovascular approach. *Acta Neurochir (Wien)* **143**:95–96, 2001
- Cathelinaud O, Bizeau A, Rimbot A, Arteaga C, Verdalle P:

- Endoscopic endonasal surgery complication: new methods of intracavernous internal carotid artery injury treatment. **Rev Laryngol Otol Rhinol (Bord)** **129**:305–308, 2008
13. Chalouhi N, Jabbour P, Singhal S, Drueding R, Starke RM, Dalyai RT, et al: Stent-assisted coiling of intracranial aneurysms: predictors of complications, recanalization, and outcome in 508 cases. **Stroke** **44**:1348–1353, 2013
 14. Chalouhi N, Starke RM, Yang S, Bovenzi CD, Tjoumakaris S, Hasan D, et al: Extending the indications of flow diversion to small, unruptured, saccular aneurysms of the anterior circulation. **Stroke** **45**:54–58, 2014
 15. Chalouhi N, Tjoumakaris S, Starke RM, Gonzalez LF, Rاندazzo C, Hasan D, et al: Comparison of flow diversion and coiling in large unruptured intracranial saccular aneurysms. **Stroke** **44**:2150–2154, 2013
 16. Charalampaki P, Ayyad A, Kockro RA, Perneczky A: Surgical complications after endoscopic transsphenoidal pituitary surgery. **J Clin Neurosci** **16**:786–789, 2009
 17. Chen D, Concus AP, Halbach VV, Cheung SW: Epistaxis originating from traumatic pseudoaneurysm of the internal carotid artery: diagnosis and endovascular therapy. **Laryngoscope** **108**:326–331, 1998
 18. Ciceri EFM, Regna-Gladin C, Erbetta A, Chiapparini L, Nappini S, Savoiardo M, et al: Iatrogenic intracranial pseudoaneurysms: neuroradiological and therapeutical considerations, including endovascular options. **Neurol Sci** **27**:317–322, 2006
 19. Cinar C, Bozkaya H, Parildar M, Oran I: Endovascular management of vascular injury during transsphenoidal surgery. **Interv Neuroradiol** **19**:102–109, 2013
 20. Ciric I, Ragin A, Baumgartner C, Pierce D: Complications of transsphenoidal surgery: results of a national survey, review of the literature, and personal experience. **Neurosurgery** **40**:225–237, 1997
 21. Crowley RW, Dumont AS, Jane JA Jr: Bilateral intracavernous carotid artery pseudoaneurysms as a result of sellar reconstruction during the transsphenoidal resection of a pituitary macroadenoma: case report. **Minim Invasive Neurosurg** **52**:44–48, 2009
 22. de Souza JM, Domingues FS, Espinosa G, Gadelha M: Cavernous carotid artery pseudo-aneurysm treated by stenting in acromegalic patient. **Arq Neuropsiquiatr** **61** (2B):459–462, 2003
 23. Dedmon M, Meier J, Chambers K, Remenschneider A, Mehta B, Lin D, et al: Delayed endovascular coil extrusion following internal carotid artery embolization. **J Neurol Surg Rep** **75**:e255–e258, 2014
 24. Dong X, Zhang Y, Zhang JM, Yu J: Endovascular stent-graft placement for an iatrogenic internal carotid artery pseudoaneurysm following transsphenoidal surgery. **Neurol India** **60**:670–672, 2012
 25. Dusick JR, Esposito F, Malkasian D, Kelly DF: Avoidance of carotid artery injuries in transsphenoidal surgery with the Doppler probe and micro-hook blades. **Neurosurgery** **60** (4 Suppl 2):322–329, 2007
 26. Fatemi N, Dusick JR, de Paiva Neto MA, Kelly DF: The endonasal microscopic approach for pituitary adenomas and other parasellar tumors: a 10-year experience. **Neurosurgery** **63** (4 Suppl 2):244–256, 2008
 27. Fu M, Patel T, Baehring JM, Bulsara KR: Cavernous carotid pseudoaneurysm following transsphenoidal surgery. **J Neuroimaging** **23**:319–325, 2013
 28. Fujino H, Ito S, Sugiyama H, Yoshiga D, Karashima Y, Yokoyama T: [A case of coil embolization for unexpected massive bleeding caused by internal carotid artery injury.] **Masui** **61**:314–317, 2012 (Jpn)
 29. Gardner PA, Tormenti MJ, Pant H, Fernandez-Miranda JC, Snyderman CH, Horowitz MB: Carotid artery injury during endoscopic endonasal skull base surgery: incidence and outcomes. **Neurosurgery** **73** (2 Suppl Operative):ons261–ons270, 2013
 30. Ghatge SB, Modi DB: Treatment of ruptured ICA during transsphenoidal surgery. Two different endovascular strategies in two cases. **Interv Neuroradiol** **16**:31–37, 2010
 31. Gondim JA, Almeida JP, Albuquerque LA, Schops M, Gomes E, Ferraz T, et al: Endoscopic endonasal approach for pituitary adenoma: surgical complications in 301 patients. **Pituitary** **14**:174–183, 2011
 32. Griaudze J, Gemmete JJ, Pandey AS, McKean EL, Sullivan SE, Chaudhary N: Emergency reconstructive endovascular management of intraoperative complications involving the internal carotid artery from trans-sphenoidal surgery. **J Neurointerv Surg** **7**:67–71, 2015
 33. Hattori I, Iwasaki K, Horikawa F, Tanji M, Gomi M: [Treatment of a ruptured giant internal carotid artery pseudoaneurysm following transsphenoidal surgery: case report and literature review.] **No Shinkei Geka** **34**:1141–1146, 2006 (Jpn)
 34. Hollis LJ, McGlashan JA, Walsh RM, Bowdler DA: Massive epistaxis following sphenoid sinus exploration. **J Laryngol Otol** **108**:171–173, 1994
 35. Hudgins PA, Browning DG, Gallups J, Gussack GS, Peterman SB, Davis PC, et al: Endoscopic paranasal sinus surgery: radiographic evaluation of severe complications. **AJNR Am J Neuroradiol** **13**:1161–1167, 1992
 36. Isenberg SF, Scott JA: Management of massive hemorrhage during endoscopic sinus surgery. **Otolaryngol Head Neck Surg** **111**:134–136, 1994
 37. Kadkhodayan Y, Rhodes N, Blackburn S, Derdeyn CP, Cross DT III, Moran CJ: Comparison of Enterprise with Neuroform stent-assisted coiling of intracranial aneurysms. **AJR Am J Roentgenol** **200**:872–878, 2013
 38. Kadkhodayan Y, Shetty VS, Blackburn SL, Reynolds MR, Cross DT III, Moran CJ: Pipeline embolization device and subsequent vessel sacrifice for treatment of a bleeding carotid pseudoaneurysm at the skull base: a case report. **J Neurointerv Surg** **5**:e31, 2013
 39. Kadkhodayan Y, Somogyi CT, Cross DT III, Derdeyn CP, Zipfel GJ, Chicoine MR, et al: Technical, angiographic and clinical outcomes of Neuroform 1, 2, 2 Treo and 3 devices in stent-assisted coiling of intracranial aneurysms. **J Neurointerv Surg** **4**:368–374, 2012
 40. Kadyrov NA, Friedman JA, Nichols DA, Cohen-Gadol AA, Link MJ, Piepgras DG: Endovascular treatment of an internal carotid artery pseudoaneurysm following transsphenoidal surgery. Case report. **J Neurosurg** **96**:624–627, 2002
 41. Kai Y, Hamada J, Nishi T, Ushio Y: [Successful treatment with bypass and interventional surgery for a ruptured pseudo carotid artery aneurysm after transsphenoidal surgery: a case report.] **No Shinkei Geka** **29**:241–245, 2001 (Jpn)
 42. Kalia JS, Niu T, Zaidat OO: The use of a covered stent graft for obliteration of high-flow carotid cavernous fistula presenting with life-threatening epistaxis. **J Neurointerv Surg** **1**:142–145, 2009
 43. Kalinin PL, Sharipov OI, Shkarubo AN, Fomichev DV, Kutin MA, Alekseev SN: [Damage to the cavernous segment of the internal carotid artery in transsphenoidal endoscopic removal of pituitary adenomas (report of four cases).] **Zh Vopr Neurokhir Im N N Burdenko** **6**:24–33, 2013 (Russian)
 44. Kim BM, Jeon P, Kim DJ, Kim DI, Suh SH, Park KY: Jostent covered stent placement for emergency reconstruction of a ruptured internal carotid artery during or after transsphenoidal surgery. **J Neurosurg** **122**:1223–1228, 2015
 45. Kim SH, Shin YS, Yoon PH, Kim DI: Emergency endovascular treatment of internal carotid artery injury during a transsphenoidal approach for a pituitary tumor—case report. **Yonsei Med J** **43**:119–122, 2002
 46. Kobayashi N, Abe T, Furuya H, Dohi K, Shimazu M, Sasaki

- K, et al: [Successful treatment using detachable coils for traumatic carotid cavernous fistula as a complication of transsphenoidal surgery for a pituitary adenoma: a case report.] **No Shinkei Geka** **28**:167–171, 2000 (Jpn)
47. Kocer N, Kizilkilic O, Albayram S, Adaletli I, Kantarci F, Islak C: Treatment of iatrogenic internal carotid artery laceration and carotid cavernous fistula with endovascular stent-graft placement. **AJNR Am J Neuroradiol** **23**:442–446, 2002
48. Koitschev A, Simon C, Löwenheim H, Naegele T, Ernemann U: Management and outcome after internal carotid artery laceration during surgery of the paranasal sinuses. **Acta Otolaryngol** **126**:730–738, 2006
49. Laws ER Jr: Vascular complications of transsphenoidal surgery. **Pituitary** **2**:163–170, 1999
50. Lempert TE, Halbach VV, Higashida RT, Dowd CF, Urwin RW, Balousek PA, et al: Endovascular treatment of pseudoaneurysms with electrolytically detachable coils. **AJNR Am J Neuroradiol** **19**:907–911, 1998
51. Leung GKK, Auyeung KM, Lui WM, Fan YW: Emergency placement of a self-expandable covered stent for carotid artery injury during trans-sphenoidal surgery. **Br J Neurosurg** **20**:55–57, 2006
52. Lim J, Suh SH, Lee KY, Hong CK, Park SW: Endovascular treatment of iatrogenic intracranial pseudoaneurysm following stent angioplasty. **J Neuroimaging** **22**:194–196, 2012
53. Lim YC, Kang JK, Chung J: Reconstructive stent-buttressed coil embolization of a traumatic pseudoaneurysm of the supraclinoid internal carotid artery. **Acta Neurochir (Wien)** **154**:477–480, 2012
54. Lippert BM, Ringel K, Stoeter P, Hey O, Mann WJ: Stent-graft-implantation for treatment of internal carotid artery injury during endonasal sinus surgery. **Am J Rhinol** **21**:520–524, 2007
55. Lorberboym M, Pandit N, Machac J, Holan V, Sacher M, Segal D, et al: Brain perfusion imaging during preoperative temporary balloon occlusion of the internal carotid artery. **J Nucl Med** **37**:415–419, 1996
56. Luo CB, Teng MMH, Chang FC, Lirng JF, Chang CY: Endovascular management of the traumatic cerebral aneurysms associated with traumatic carotid cavernous fistulas. **AJNR Am J Neuroradiol** **25**:501–505, 2004
57. Lylyk P, Miranda C, Ceratto R, Ferrario A, Scrivano E, Luna HR, et al: Curative endovascular reconstruction of cerebral aneurysms with the pipeline embolization device: the Buenos Aires experience. **Neurosurgery** **64**:632–643, 2009
58. Mathis JM, Barr JD, Jungreis CA, Yonas H, Sekhar LN, Vincent D, et al: Temporary balloon test occlusion of the internal carotid artery: experience in 500 cases. **AJNR Am J Neuroradiol** **16**:749–754, 1995
59. May M, Levine HL, Mester SJ, Schaitkin B: Complications of endoscopic sinus surgery: analysis of 2108 patients—incidence and prevention. **Laryngoscope** **104**:1080–1083, 1994
60. McAuliffe W, Wycoco V, Rice H, Phatouros C, Singh TJ, Wenderoth J: Immediate and midterm results following treatment of unruptured intracranial aneurysms with the pipeline embolization device. **AJNR Am J Neuroradiol** **33**:164–170, 2012
61. Medel R, Crowley RW, Hamilton DK, Dumont AS: Endovascular obliteration of an intracranial pseudoaneurysm: the utility of Onyx. **J Neurosurg Pediatr** **4**:445–448, 2009
62. Nerva JD, Morton RP, Levitt MR, Osbun JW, Ferreira MJ, Ghodke BV, et al: Pipeline Embolization Device as primary treatment for blister aneurysms and iatrogenic pseudoaneurysms of the internal carotid artery. **J Neurointerv Surg** **7**:210–216, 2015
63. Oeken J, Bootz F: [Severe complications after endonasal nasal sinus surgery. An unresolved problem.] **HNO** **52**:549–553, 2004 (Ger)
64. O’Kelly CJ, Spears J, Chow M, Wong J, Boulton M, Weill A, et al: Canadian experience with the pipeline embolization device for repair of unruptured intracranial aneurysms. **AJNR Am J Neuroradiol** **34**:381–387, 2013
65. Oskouian RJ, Kelly DF, Laws ER Jr: Vascular injury and transsphenoidal surgery. **Front Horm Res** **34**:256–278, 2006
66. Park AH, Stankiewicz JA, Chow J, Azar-Kia B: A protocol for management of a catastrophic complication of functional endoscopic sinus surgery: internal carotid artery injury. **Am J Rhinol** **12**:153–158, 1998
67. Patel AS, Horton TG, Kalapos P, Cockroft KM: Onyx-HD 500 embolization of a traumatic internal carotid artery pseudoaneurysm after transsphenoidal surgery. **J Neuroimaging** **25**:656–659, 2015
68. Pepper JP, Wadhwa AK, Tsai F, Shibuya T, Wong BJF: Cavernous carotid injury during functional endoscopic sinus surgery: case presentations and guidelines for optimal management. **Am J Rhinol** **21**:105–109, 2007
69. Piano M, Valvassori L, Quilici L, Pero G, Boccardi E: Mid-term and long-term follow-up of cerebral aneurysms treated with flow diverter devices: a single-center experience. **J Neurosurg** **118**:408–416, 2013
70. Pigott TJ, Holland IM, Punt JA: Carotico-cavernous fistula after trans-sphenoidal hypophysectomy. **Br J Neurosurg** **3**:613–616, 1989
71. Pride GL Jr, Replogle RE, Rappard G, Graybeal CL, White J, Purdy P: Stent-coil treatment of a distal internal carotid artery dissecting pseudoaneurysm on a redundant loop by use of a flexible, dedicated nitinol intracranial stent. **AJNR Am J Neuroradiol** **25**:333–337, 2004
72. Rangel-Castilla L, McDougall CG, Spetzler RF, Nakaji P: Urgent cerebral revascularization bypass surgery for iatrogenic skull base internal carotid artery injury. **Neurosurgery** **10**:640–648, 2014
73. Raymond J, Hardy J, Czepko R, Roy D: Arterial injuries in transsphenoidal surgery for pituitary adenoma; the role of angiography and endovascular treatment. **AJNR Am J Neuroradiol** **18**:655–665, 1997
74. Reich O, Ringel K, Stoeter P, Maurer J: [Injury of ICA during endonasal sinus surgery and management by endovascular stent application.] **Laryngorhinootologie** **88**:322–326, 2009 (Ger)
75. Segal DH, Sen C, Bederson JB, Catalano P, Sacher M, Stollman AL, et al: Predictive value of balloon test occlusion of the internal carotid artery. **Skull Base Surg** **5**:97–107, 1995
76. Shakir HJ, Garson AD, Sorkin GC, Mokin M, Eller JL, Dumont TM, et al: Combined use of covered stent and flow diversion to seal iatrogenic carotid injury with vessel preservation during transsphenoidal endoscopic resection of clival tumor. **Surg Neurol Int** **5**:81, 2014
77. Smith TR, Hulou MM, Huang KT, Nery B, de Moura SM, Cote DJ, et al: Complications after transsphenoidal surgery for patients with Cushing’s disease and silent corticotroph adenomas. **Neurosurg Focus** **38**(2):E12, 2015
78. Standard SC, Ahuja A, Guterman LR, Chavis TD, Gibbons KJ, Barth AP, et al: Balloon test occlusion of the internal carotid artery with hypotensive challenge. **AJNR Am J Neuroradiol** **16**:1453–1458, 1995
79. Struffert T, Buhk JH, Buchfelder M, Rohde V, Doerfler A, Knauth M: Coil migration after endovascular coil occlusion of internal carotid artery pseudoaneurysms within the sphenoid sinus. **Minim Invasive Neurosurg** **52**:89–92, 2009
80. Sylvester PT, Evans JA, Zipfel GJ, Chole RA, Uppaluri R, Haughey BH, et al: Combined high-field intraoperative magnetic resonance imaging and endoscopy increase extent of resection and progression-free survival for pituitary adenomas. **Pituitary** **18**:72–85, 2015
81. Tuchman A, Khalessi AA, Attenello FJ, Amar AP, Zada G:

Delayed cavernous carotid artery pseudoaneurysm caused by absorbable plate following transsphenoidal surgery: case report and review of the literature. **J Neurol Surg Rep** 74:10–16, 2013

82. Valentine R, Wormald PJ: Carotid artery injury after endonasal surgery. **Otolaryngol Clin North Am** 44:1059–1079, 2011
83. Vanninen RL, Manninen HI, Rinne J: Intracellular iatrogenic carotid pseudoaneurysm: endovascular treatment with a polytetrafluoroethylene-covered stent. **Cardiovasc Intervent Radiol** 26:298–301, 2003
84. Vergez S, Folia M, Michenet F, Rose X, Lacroix-Loubes F, Percodani J, et al: [Pseudoaneurysm of the internal carotid artery revealed by epistaxis: report of two cases.] **Rev Laryngol Otol Rhinol (Bord)** 126:151–154, 2005 (Fr)
85. Wang N, Chen G, Zhi XL, Chen WJ, Xu YQ, Ling F: Diagnosis and treatment of internal carotid artery injury in endonasal transsphenoidal approach for pituitary adenoma resection. **Chinese J Contemp Neurol Neurosurg** 8:329–333, 2008
86. Weidenbecher M, Huk WJ, Iro H: Internal carotid artery injury during functional endoscopic sinus surgery and its management. **Eur Arch Otorhinolaryngol** 262:640–645, 2005
87. Whisenant JT, Kadkhodayan Y, Cross DT, Moran CJ, Derdeyn CP: Incidence and mechanisms of stroke after permanent carotid artery occlusion following temporary occlusion testing. **J Neurointerv Surg** 7:395–401, 2014
88. Yu SCH, Kwok CK, Cheng PW, Chan KY, Lau SS, Lui WW, et al: Intracranial aneurysms: midterm outcome of pipeline embolization device — a prospective study in 143 patients with 178 aneurysms. **Radiology** 265:893–901, 2012
89. Zada G, Cavallo LM, Esposito F, Fernandez-Jimenez JC, Tasiou A, De Angelis M, et al: Transsphenoidal surgery in patients with acromegaly: operative strategies for overcoming technically challenging anatomical variations. **Neurosurg Focus** 29(4):E8, 2010
90. Zada G, Kelly DF, Cohan P, Wang C, Swerdloff R: Endonasal transsphenoidal approach for pituitary adenomas and other

sellar lesions: an assessment of efficacy, safety, and patient impressions. **J Neurosurg** 98:350–358, 2003

Disclosures

Dr. Chicoine reports receiving funding from IMRIS Inc. for an unrestricted educational grant that has helped support the iMRI database, outcomes analysis, and establishment of the IMRIS Multicenter iMRI Neurosurgery Database (I-MiND). Dr. Moran reports receiving consulting fees from ev3, Covidien, and Medtronic. Dr. Derdeyn reports receiving industry support as a consultant from Microvention (Angio core laboratory for the LVIS trial), Penumbra (Data Safety Monitoring Board [DSMB] and the 3D Separator trial), Silk Road (DSMB for the ROAD-STER trial); and owning stock options for Pulse Therapeutics. Dr. Sylvester reports receiving grant support from the Clinical and Translational Science Award (CTSA) program of the National Center for Advancing Translational Sciences (NCATS) of the National Institutes of Health (NIH) under Award Numbers UL1 TR000448 and TL1 TR000449 from 2012 to 2013.

Author Contributions

Conception and design: Chicoine, Sylvester. Acquisition of data: Chicoine, Sylvester, Moran, Derdeyn, Cross, Zipfel, Kim, Uppaluri, Haughey. Analysis and interpretation of data: Chicoine, Sylvester. Drafting the article: Chicoine, Sylvester. Critically revising the article: Chicoine, Sylvester, Moran, Derdeyn, Cross, Zipfel, Kim, Uppaluri, Haughey, Tempelhoff, Rich, Schneider, Chole. Reviewed submitted version of manuscript: all authors. Approved the final version of the manuscript on behalf of all authors: Chicoine. Statistical analysis: Chicoine, Sylvester. Administrative/technical/material support: Chicoine, Sylvester, Dacey. Study supervision: Chicoine, Dacey.

Correspondence

Michael R. Chicoine, Department of Neurosurgery, Washington University School of Medicine, 660 S. Euclid Ave., Campus Box 8057, St. Louis, MO 63110. email: chicoinem@wudosis.wustl.edu.