

Holmes' tremor as a delayed complication of thalamic stroke



William Alves Martins^{a,*}, Luiz Carlos Porcello Marrone^a, Helena Fussiger^a, Viviane Maria Vedana^a, Rafael do Amaral Cristovam^a, Marjorye Z. Taietti^a, Antonio Carlos Huf Marrone^{a,b}

^a Department of Neurology, Hospital São Lucas, Pontifícia Universidade Católica do Rio Grande do Sul (PUCRS), Avenida Ipiranga 6690, CEP: 90610-000, Brazil

^b Internal Medicine, Division of Neurology, Faculty of Medicine, PUCRS, Porto Alegre, Brazil

ARTICLE INFO

Article history:

Received 20 September 2014

Accepted 18 September 2015

Keywords:

Holmes' tremor

Movement disorders

Symptomatic tremor

Thalamic stroke

Thalamic tremor

Ventral posterolateral nucleus

ABSTRACT

Movement disorders are not commonly associated with stroke. Accordingly, thalamic strokes have rarely been associated with tremor, pseudo-athetosis and dystonic postures. We present a 75-year-old man who developed a disabling tremor 1 year after a posterolateral thalamic stroke. This tremor had low frequency (3–4 Hz), did not disappear on focus and was exacerbated by maintaining a static posture and on target pursuit, which made it very difficult to perform basic functions. MRI demonstrated an old ischemic lesion at the left posterolateral thalamus. Treatment with levodopa led to symptom control. Lesions in the midbrain, cerebellum and thalamus may cause Holmes' tremor. Delayed onset of symptoms is usually seen, sometimes appearing 2 years after the original injury. This may be due to maturation of a complex neuronal network, leading to slow dopaminergic denervation. Further studies are needed to improve our understanding of this unique disconnection syndrome.

© 2015 Elsevier Ltd. All rights reserved.

1. Introduction

Movement disorders are uncommon manifestations of stroke [1]. Among these, thalamic strokes have rarely been associated with tremor, pseudo-athetosis and dystonic postures [2]. Thalamic tremor has a low frequency (3–5 Hertz) and high amplitude, manifests at rest but with severe worsening on posture and, especially, when reaching a target [2,3]. Thalamic tremor is now classified within the spectrum of Holmes' tremor (HT), which also comprises lesions in the midbrain and cerebellum causing similar symptoms [3]. Symptoms may develop up to 2 years after such lesions. We present a patient with this tremor appearing 1 year after a posterolateral thalamic stroke.

2. Case report

A 75-year-old hypertensive man came to our office with a 2 year history of a resting tremor in his right hand. On neurological examination, this tremor was irregular and coarse, had low frequency (3 Hz) and was exacerbated by maintaining a static posture and during movement. This kinetic tremor made it very difficult to perform basic functions. Examination also showed a slight bradykinesia and rigidity on his right arm. Tendon reflexes were symmetrically brisk. Strength was preserved, but there was decreased sensation to tactile stimuli on the right.

Past medical history revealed two previous strokes, without any explicit neurological disability. Three years earlier, he had a moderate hemiparesis and hemianesthesia on his right side, both of which abated, slowly giving place to the tremor. A thalamic lacunar stroke was diagnosed at the time and he was started on aspirin.

Brain MRI demonstrated small old lacunar strokes bilaterally, but on the left posterolateral thalamus there was a large ischemic lesion (Fig. 1). This lesion was associated with moderate brain atrophy and slightly enlarged left lateral ventricle. He was diagnosed and started on levodopa 1,000 mg/day, with minor improvement of his symptoms.

3. Discussion

Thalamic stroke usually causes sensory dysfunction, such as hemianesthesia, severe pain (Dejerine–Roussy syndrome), sensory ataxia and cognitive alterations, including transcortical aphasia [4]. However, these manifestations vary widely depending which thalamic nucleus is affected [4]. Rarely, a Holmes-like tremor can occur years after vascular lesions of thalamus [1,2].

HT is a unique form of symptomatic tremor, resulting from lesions of the central nervous system [3]. Characteristically it has three components: rest, postural and intentional. Frequency is usually less than 4.5 Hz and amplitude markedly widens in goal-directed action. HT formerly received many names (rubral, midbrain or thalamic, or cerebellar outflow tremor), depending on the affected region that resulted in its presentation. However, except for some patients with thalamic lesions who can also present with dystonic or choreoathetoid features [5], the phenomenology does not differ significantly [3]. Therefore, the term HT is now applied.

Although most authors believe pathophysiology of thalamic tremor lies in the interruption of cerebellum-rubro-thalamic fibers to the ventral posterolateral thalamic nucleus [6], lesions that spare this nucleus have been associated with tremor [2]. Interruption of this pathway before arrival at the ventral intermediate (Vim) nucleus in the thalamus can result in postural and action tremor [7]. Interestingly, Vim thalamotomy has been used successfully to treat HT triggered by midbrain injury, suggesting thalamic participation on generation of oscillatory discharges in HT outside the thalamus [8]. Also of interest, dopaminergic denervation has been demonstrated in functional studies in midbrain injuries leading to HT [9]. Nigrostriatal dysfunction in thalamic tremor can only be speculated, but response to dopaminergic agents support this hypothesis. Delayed onset and variability of anatomic location [3], suggest that rather than a single lesion site, mechanism of tremor initiation involves maturation of a complex neuronal network much like those seen in some epileptic disorders.

Treatment of thalamic tremor is the same as other types of HT and relies mainly on dopaminergic agents. Other drugs such as

* Corresponding author. Tel.: +55 51 3320 2760.

E-mail address: walvesm.br@gmail.com (W.A. Martins).

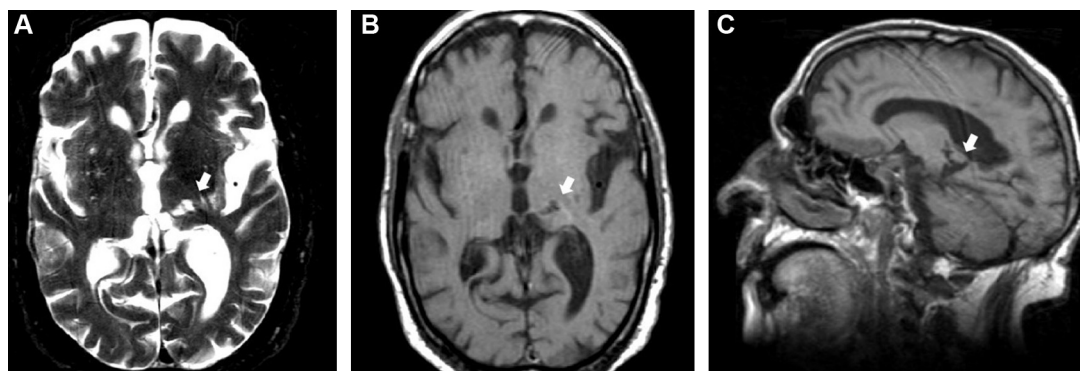


Fig. 1. Axial (A) T2-weighted and (B) T1-weighted MRI showing an old ischemic lesion in the posterolateral thalamus (arrow). (C) Sagittal T1-weighted MRI demonstrating the same lesion (arrow) and an enlarged lateral ventricle.

propranolol, clonazepam and levetiracetam, among others, have also been used, which reflects our lack of consensus about its pathophysiology. HT is usually refractory to medical treatment, sometimes responding only to functional neurosurgery [6].

Thalamic lesions disrupt a range of complex synaptic networks, which may evolve to functional disability years after the original injury. HT is an example of this “tremorigenic” network that may be quite unresponsive to treatment. Further studies are needed to improve our understanding and management of this unique disconnection syndrome.

Conflicts of Interest/Disclosures

The authors declare that they have no financial or other conflicts of interest in relation to this research and its publication.

<http://dx.doi.org/10.1016/j.jocn.2015.09.014>

References

- [1] Mehanna R, Jankovic J. Movement disorders in cerebrovascular disease. *Lancet Neurol* 2013;12:597–608.
- [2] Miwa H, Hatori K, Kondo T, et al. Thalamic tremor: case reports and implications of the tremor-generating mechanism. *Neurology* 1996;46:75–9.
- [3] Deuschl G, Bain P, Brin M, et al. Consensus statement of the movement disorder society on tremor. *Mov Disord* 1998;13:2–23.
- [4] Schmähmann JD. Vascular syndromes of the thalamus. *Stroke* 2003;34:2264–78.
- [5] Cho C, Samkoff LM. A lesion of the anterior thalamus producing dystonic tremor of the hand. *Arch Neurol* 2000;57:1353–5.
- [6] Krystkowiak P, Martinat P, Cassim F, et al. Thalamic tremor: correlations with three-dimensional magnetic resonance imaging data and pathophysiological mechanisms. *Mov Disord* 2000;15:911–8.
- [7] Vidailhet M, Jédynek CP, Pollak P, et al. Pathology of symptomatic tremors. *Mov Disord* 1998;13:49–54.
- [8] Kim MC, Son BC, Miyagi Y, et al. Vim thalamotomy for Holmes' tremor secondary to midbrain tumour. *J Neurol Neurosurg Psychiatry* 2002;73:453–5.
- [9] Paviour DC, Jäger HR, Wilkinson L, et al. Holmes tremor: application of modern neuroimaging techniques. *Mov Disord* 2006;21:2260–2.

Post-hemorrhagic hydrocephalus presenting as cauda equina syndrome in a patient with spinal dysraphism



Matthew T. Bender, Geoffrey P. Colby, Judy Huang*

Department of Neurosurgery, Johns Hopkins University School of Medicine, Johns Hopkins Hospital, 1800 Orleans Street, Zayed Tower 6115F, Baltimore, MD 21287, USA

ARTICLE INFO

Article history:

Received 27 October 2015

Accepted 31 October 2015

Keywords:

Cauda equina

Hydrocephalus

Spinal dysraphism

Subarachnoid hemorrhage

ABSTRACT

Hydrocephalus has varied presentations in patients with a history of spinal dysraphism. This is a unique case of post-subarachnoid hemorrhage hydrocephalus presenting as cauda equina syndrome. We report on a 32-year-old woman with remotely repaired spinal defect who experienced subarachnoid hemorrhage and underwent anterior communicating artery aneurysm clipping. Post-operatively, she developed urinary and fecal incontinence as the sole presenting symptom of communicating post-hemorrhagic hydrocephalus. New neurological deficits in this population can also be attributed to recurrent cord tethering or syrinx, both of which were demonstrated on her lumbar spine MRI, but her incontinence resolved with external ventricular drain placement and cerebrospinal fluid diversion. There are few case reports of patients with closed neural tube defects and hydrocephalus and none in the adult population to our knowledge. Neurological change in patients with any history of spinal dysraphism may reflect altered cerebrospinal fluid dynamics affecting either end of the neuraxis.

© 2015 Elsevier Ltd. All rights reserved.

* Corresponding author. Tel.: +1 410 502 5767; fax: +1 443 287 0683.

E-mail address: jhuang24@jhmi.edu (J. Huang).