

CASE REPORT

**Detection of cerebral amyloid angiopathy by 3-T magnetic resonance imaging and amyloid positron emission tomography in a patient with subcortical ischaemic vascular dementia**

HirotaKa KIDA,<sup>1</sup> Masayuki SATOH,<sup>1</sup> Yuichiro II,<sup>2</sup> Hidenao FUKUYAMA,<sup>3</sup> Masayuki MAEDA<sup>4</sup> and Hidekazu TOMIMOTO<sup>1,2</sup>

Departments of <sup>1</sup>Dementia Prevention and Therapeutics, <sup>2</sup>Neurology, and <sup>4</sup>Radiology, Graduate School of Medicine, Mie University, Mie, and <sup>3</sup>Human Brain Research Center, Graduate School of Medicine, Kyoto University, Kyoto, Japan

*Correspondence:* Dr Masayuki Satoh MD PhD, Department of Dementia Prevention and Therapeutics, Graduate School of Medicine, Mie University, 2-174 Edobashi, Tsu, Mie 514-8507, Japan. Email: bruckner@clin.medic.mie-u.ac.jp

*Received 9 July 2015; revision received 26 October 2015; accepted 30 November 2015.*

Financial disclosure statement: The authors have no financial ties to disclose.

Contributions: Dr Kida treated the patient and acquired the data. Dr Satoh wrote the article and interpreted the findings of neuropsychological assessments. Dr Ii interpreted the MRI findings. Prof. Fukuyama performed the PiB-positron emission tomography study and interpreted the findings. Dr Maeda diagnosed based on the neuroimaging findings. Prof. Tomimoto critiqued and revised the manuscript for important intellectual content.

**Key words:** *Alzheimer's disease (AD), cerebral amyloid angiopathy (CAA), double inversion recovery, Pittsburgh compound B (PiB), subcortical ischaemic vascular dementia (SIVD), susceptibility weighted imaging (SWI).*

**INTRODUCTION**

Alzheimer's disease (AD) and vascular dementia (VaD) are the two most common diseases that cause dementia. Hitherto, AD and VaD have been interpreted from the viewpoint of the dualism. However, over the past few decades, a considerable body of evidence has revealed that many vascular risk factors are also risk factors for AD. Recently, AD and VaD have been deemed to frequently coexist with one another and to have pathological interaction.<sup>1</sup>

The most frequent subtype of VaD is subcortical ischaemic vascular dementia (SIVD), which is caused

**Abstract**

The patient was an 81-year-old man who had been treated for hypertension for several decades. In 2012, he developed gait disturbance and mild amnesia. One year later, his gait disturbance worsened, and he developed urinary incontinence. Conventional brain magnetic resonance imaging using T<sub>2</sub>-weighted images and fluid-attenuated inversion recovery showed multiple lacunar infarctions. These findings fulfilled the diagnostic criteria for subcortical ischaemic vascular dementia. However, susceptibility weighted imaging showed multiple lobar microbleeds in the bilateral occipitoparietal lobes, and double inversion recovery and 3-D fluid-attenuated inversion recovery images on 3-T magnetic resonance imaging revealed cortical microinfarctions in the left parietal-temporo-occipito region. Pittsburgh compound B-positron emission tomography revealed diffuse uptake in the cerebral cortex. Therefore, we diagnosed the patient with subcortical ischaemic vascular dementia associated with Alzheimer's disease. The use of the double inversion recovery and susceptibility weighted imaging on 3-T magnetic resonance imaging may be a supplemental strategy for diagnosing cerebral amyloid angiopathy, which is closely associated with Alzheimer's disease.

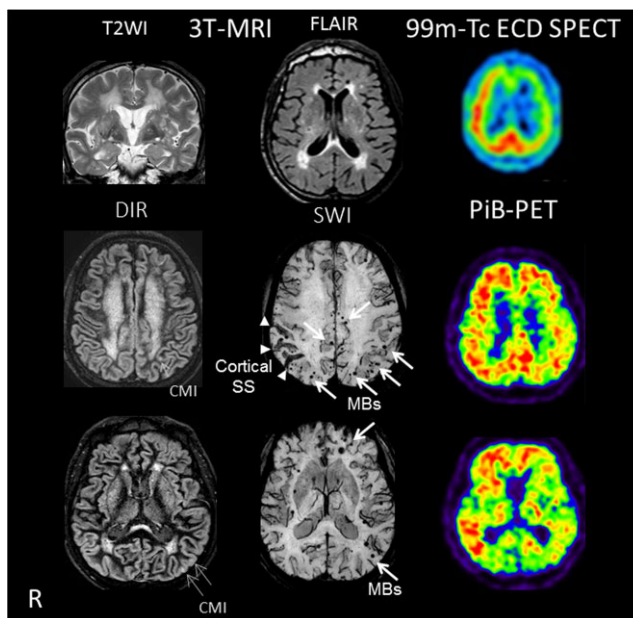
by hypertensive small vessel disease (SVD) in the subcortical regions. Cerebral amyloid angiopathy (CAA) is the other SVD subtype in the cortical regions, and it is almost always found in AD brains. Neuroimaging findings of hypertensive SVD consist of lacunar infarcts, white matter lesions, and deep microbleeds (MB), whereas those for CAA show lobar MB, cortical superficial siderosis, and cortical microinfarcts (CMI). In elderly individuals, CMI are mostly attributable to CAA and, therefore, can be often observed in AD brains.<sup>2</sup> The size of CMI ranges between a few hundred µm to 4 mm, so they may not

be detected by conventional magnetic resonance imaging (MRI).<sup>3</sup> Recently, however, new imaging techniques using 7-T MRI or 3-T MRI combined with double inversion recovery have made it feasible to detect CMI in a clinical setting.<sup>4-6</sup>

**CASE PRESENTATION**

The patient was an 81-year-old man who had been treated for hypertension for several decades. In 2012, he had developed gait disturbance with mild inclination to left side. He consulted with a doctor and was diagnosed with multiple lacunar infarcts. He also complained of mild amnesia, which did not affect his activities of daily living. One year later, his gait disturbance worsened, with his strides becoming smaller and his movement slower. Urinary urgency and incontinence were also observed, so he consulted with the memory clinic at our hospital.

On examination, he was polite and cooperative. Neurological examination showed rigidity in all limbs, a small-step gait, and broad-based magnetic gait. He had no hand tremor. His laboratory findings, including thyroid hormones, vitamin B1, vitamin B12, and antibodies for syphilis, were unremarkable. Assessments of his neurocognitive function showed moderate impairment of intellectual, memory, and frontal lobe function, but his visuospatial ability was preserved (Table 1). Conventional brain MRI using T<sub>2</sub>-weighted images and fluid-attenuated inversion recovery showed multiple lacunar infarcts in the basal ganglia and deep white matter (Fig. 1). Mild atrophy of the hippocampus was observed mostly on the right.



**Figure 1** The results of neuroimaging studies using 3-T MRI with T<sub>2</sub>WI, FLAIR, DIR, and SWI; SPECT; and PiB-PET. The results of conventional neuroimaging studies using T<sub>2</sub>WI and FLAIR showed multiple lacunar infarcts and diffuse white matter ischaemic changes (top row, left and centre images). In the <sup>99m</sup>Tc-ECD SPECT, regional cerebral blood flow in the bilateral frontal lobes was decreased dominantly on the left (top row, right). The DIR and SWI images showed CMI, MB, and cortical subarachnoid haemorrhage (SAH) (bottom two rows, left and centre). Note that CMI and MB were observed mainly at the occipitoparietal regions. The results of PiB-PET showed diffuse tracer deposits at the cortex of the patient’s brain (bottom two rows, right). <sup>99m</sup>Tc-ECD, <sup>99m</sup>Tc-ethyl cysteinate dimer; CMI, cortical microinfarct; DIR, double inversion recovery; FLAIR, fluid attenuated inversion recovery; MB, microbleeds; PET, positron emission tomography; PiB, Pittsburgh compound B; R, right; SPECT, single photon emission computed tomography; SS, superficial siderosis; SWI, susceptibility weighted imaging; T<sub>2</sub>WI, T<sub>2</sub>-weighted image.

**Table 1** Results of neuropsychological assessments

Tests	Patient results	Normal			
		Mean	SD		
Intellect	MMSE	21	>23	-	
	RCPM	19	26.9	5.396	
	Score (/36) Time (s)	420			
Memory	RBMT	Standard score (/24)	10	19.73	2.98
		Screening score (/12)	2	9.15	1.78
Visuospatial	Cube drawing	Good			
	Necker cube drawing	Good			
Frontal	WF	Animal (words/min)	7	14.3	-
		Letters (words/min)	2	8.1	-
	TMT-A	Time (s)	315	140.2	34.7
	TMT-B†	Time (s)	-	202.6	49.6

†Patient did not complete TMT-B. MMSE, Mini-Mental State Examination; RBMT, Revermead Behavioural Memory Test; RCPM, Raven’s Coloured Progressive Matrices; TMT, Trail Making Test; WF, word fluency.

$^{99m}\text{Tc}$ -ethyl cysteinate dimer single photon emission computed tomography revealed a left-dominant decrease in regional cerebral blood flow in the bilateral frontal lobes. These results appeared to fulfil the diagnostic criteria for SIVD proposed by Erkinjuntti *et al.*<sup>7</sup>

Susceptibility weighted imaging, which can finely detect MB, showed multiple lobar MB and cortical superficial siderosis in the bilateral occipitoparietal and right parietal regions, respectively (Fig. 1). Furthermore, double inversion recovery and 3-D fluid-attenuated inversion recovery images on 3-T MRI revealed CMI in the left parietal-temporo-occipito region. Therefore, we conducted Pittsburgh compound-B (PiB)-positron emission tomography, which revealed diffuse uptake in the cerebral cortex. It has been reported that pure CAA shows occipital-dominant PiB retention, but in AD, the occipital cortex has a lower PiB retention than the frontal, temporal, or parietal cortex.<sup>8</sup> Our patient showed diffuse PiB retention, but it was relatively low in the occipital cortex.

In short, amyloid-related vasculopathy suggested the existence of CAA, and PiB-positron emission tomography revealed AD pathology in the patient's brain. Therefore, we diagnosed the patient with SIVD associated with AD.

## DISCUSSION

The present case suggested that AD and SIVD may coexist more frequently than expected. Indeed, frequent associations between hypertensive SVD, CAA, and AD pathologies have been pointed out in previous studies.<sup>9</sup> The high incidence of dual pathology may be attributed to vasoconstriction by amyloid  $\beta$ , amyloid  $\beta$  aggregation by cerebral ischaemia, or suppression of perivascular drainage of amyloid  $\beta$  by hypertensive SVD.<sup>10</sup>

The differential diagnosis between AD and SIVD is important because their treatment and prevention strategies differ from each other. AD patients invariably exhibit CAA, but CAA with severe intensity is very frequently complicated by AD. The amyloid-related imaging abnormalities may be a clue to detecting AD

pathology. However, the clinical utility of PiB-positron emission tomography is strictly limited based on a set of specific appropriate use criteria, because even healthy controls may exhibit positive results and compromise the pathological significance of AD.<sup>11</sup> The use of the double inversion recovery and susceptibility weighted imaging on 3-T MRI may supplement the diagnosis of CAA, especially if it substantially affects cerebral microcirculation, and may provide clues to detect AD pathology in a clinical setting.

## ACKNOWLEDGMENT

None.

## REFERENCES

- 1 Viswanathan A. Vascular risk factors and dementia. *Neurology* 2009; **72**: 358–374.
- 2 Okamoto Y, Ihara M, Fujita Y, Ito H, Takahashi R, Tomimoto H. Cortical microinfarcts in Alzheimer's disease and subcortical vascular dementia. *Neuroreport* 2009; **20**: 990–996.
- 3 Gouw AA, Seewann A, van der Flier WM *et al.* Heterogeneity of small vessel disease: a systematic review of MRI and histopathology correlations. *J Neurol Neurosurg Psychiatry* 2011; **82**: 126–135.
- 4 Li Y, Maeda M, Kida H *et al.* In vivo detection of cortical microinfarcts on ultrahigh-field MRI. *J Neuroimaging* 2013; **23**: 28–32.
- 5 van Veluw SJ, Zwanenburg JJ, Engelen-Lee J *et al.* In vivo detection of cerebral cortical microinfarcts with high-resolution 7T MRI. *J Cereb Blood Flow Metab* 2013; **33**: 322–329.
- 6 van Dalen JW, Sciric EE, van Veluw SJ *et al.* Cortical microinfarcts detected in vivo on 3 Tesla MRI: clinical and radiological correlates. *Stroke* 2015; **46**: 255–257.
- 7 Erkinjuntti T, Inzitari D, Pantoni L *et al.* Research criteria for subcortical vascular dementia in clinical trials. In: Jellinger K, Schmidt R, Windisch M, eds. *Advances in Dementia Research*. Vienna: Springer, 2000; 23–30.
- 8 Johnson KA, Gregas M, Becker JA *et al.* Imaging of amyloid burden and distribution in cerebral amyloid angiopathy. *Ann Neurol* 2007; **62**: 229–234.
- 9 Park JH, Seo SW, Kim C *et al.* Pathogenesis of cerebral microbleeds: in vivo imaging of amyloid and subcortical ischemic small vessel disease in 226 individuals with cognitive impairment. *Ann Neurol* 2013; **73**: 584–593.
- 10 Kumar-Singh S. Cerebral amyloid angiopathy: pathogenetic mechanisms and link to dense amyloid plaques. *Genes Brain Behav* 2008; **7** (Suppl 1): 67–82.
- 11 Johnson KA, Minoshima S, Bohnen NI *et al.* Appropriate use criteria for amyloid PET: a report of the Amyloid Imaging Task Force, the Society of Nuclear Medicine and Molecular Imaging, and the Alzheimer's Association. *J Nucl Med* 2013; **54**: 476–490.