

High resolution MRI in treatment decision of anterior communicating artery aneurysm accompanied by visual symptoms: Endovascular treatment or surgical clipping? A report of two cases and literature review

Peng Liu, Xianli Lv, Youxiang Li* and Ming Lv*

Abstract

Anterior communicating artery (ACoM) aneurysm accompanied by visual symptoms is rarely reported. The first case is an asymptomatic 65-year-old woman who presented with an ACoM aneurysm, and the pre-procedure high-resolution magnetic resonance imaging (MRI) revealed an ACoM aneurysm compressed the left optic nerve and the chiasma with a size of 8.3×9.2 mm. She suffered a sudden onset of left eye visual loss and the temporal hemianopia of the right eye after endovascular embolization. She had a light sensation of the left eye and minor enlargement of the visual field in the right eye at the six-month follow-up. The second case is a symptomatic 55-year-old woman suffering a visual loss in the left eye and inferior nasal quadrantanopsia in her right eye. Pre-operative high-resolution MRI found an ACoM aneurysm compressing the left part of the chiasma with a size of 7.1×8.3 mm. Her visual symptoms improved after surgical clipping. High-resolution MRI could depict the anatomic relationship between the ACoM aneurysm and the surrounding optic pathways. Endovascular treatment of an ACoM aneurysm may result in visual deterioration due to the mass effect or ischemia after the procedure. Surgical clipping of the ACoM aneurysm could relieve the compression symptoms.

Keywords

Endovascular treatment, aneurysm, anterior communicating artery, vision loss, temporal hemianopia, high resolution, magnetic resonance imaging

Received 20 October 2015; accepted 1 December 2015

Introduction

Anterior communicating artery (ACoM) aneurysm accounts for 25%–38% of total cerebral aneurysm cases presenting with subarachnoid hemorrhage.^{1,2} In rare circumstances, visual symptoms are encountered in ACoM aneurysms, with an incidence of 3%.² Observation during the clipping surgery shows that an ACoM aneurysm might bear a tight adhesion with the optic nerves or chiasm.³ An ACoM aneurysm directing posteriorly and inferiorly may result in visual symptoms while the size is small.² Compression of the chiasm with or without the optic nerves may result in bilateral visual impairment.⁴

Recently, the advent of high-resolution magnetic resonance imaging (MRI) makes possible the delineation of the aneurysm anatomy as well as the visualization of the aneurysm wall.⁵ The three-dimensional (3D) sequence of MRI can clearly manifest the anatomic relationship between the aneurysm and the surrounding optic pathways. Moreover, with the help of contrast medium, we can delineate the features of the aneurysm

wall. Enhancement of the aneurysm wall has been deemed as a biomarker for aneurysm instability.⁵

Recently, an increasing number of intracranial aneurysms have been treated with endovascular treatment to relieve visual symptoms, depending on the hypothesis that shrinkage of the organized thrombus and retraction of the aneurysm wall may result in elimination of the expansive pressure within the aneurysm.⁶ However, after endovascular treatment, the aneurysmal mass effect may still persist. Microsurgical clipping also offers the opportunity to decompress the optic nerve and reduce the mass effect.⁷

Department of Interventional Neuroradiology, Beijing Neurosurgical Institute and Beijing Tiantan Hospital, Capital Medical University, Beijing, China

*These authors contributed equally to this work

Corresponding author:

Youxiang Li, Beijing Neurosurgical Institute, No. 6, Tiantan Xili, Dongcheng, Beijing, 100050, PR. China.
Emails: liyouxiang@263.net

Here we report two cases of AComA aneurysms accompanied by visual symptoms; peer literature was also reviewed and discussed.

Case report

Case 1

A 65-year-old woman presented with incidental AComA aneurysm diagnosed by magnetic resonance angiography (MRA). Examination of both eyes was normal. High-resolution MRI was performed for her, revealing that an aneurysm sac compressed the left optic nerve and chiasma (Figure 1(a), (b)).

The MRI was performed on a 3.0T MR scanner (Achieva TX, Philips, Best, The Netherlands) with a 32-channel head coil. The internal carotid artery wall was imaged by 3D black-blood T1W- volume isotropic turbo-spin-echo acquisition (VISTA) sequence before contrast injection and at about six minutes after administration of gadolinium-diethylenetriaminepentaacetic acid dimeglumine (Gd-DTPA) (Magnevist; Bayer Schering Pharma, Berlin, Germany; 0.1 mmol/kg). Imaging parameters were repetition time/echo time (TR/TE), 700/30 ms; turbo spin echo (TSE) factor, 49

including four startup echoes; sense factor, 2; field of view (FOV), $160 \times 160 \times 54 \text{ mm}^3$; voxel size, $0.6 \times 0.6 \times 0.6 \text{ mm}^3$.

The post-contrast VISTA sequence showed obvious circumferential aneurysmal wall enhancement (Figure 1(c)). The subsequent digital subtraction angiography (DSA) revealed an AcomA aneurysm filling from the left anterior cerebral artery (Figure 1(d)). The aneurysm fundus was directed inferiorly and to the left, with a size of $8.3 \times 9.2 \text{ mm}$.

Endovascular embolization was decided for this asymptomatic and unruptured aneurysm. Under general anesthesia, the double catheter technique was used and the aneurysm was occluded with a small neck remnant (Figure 1(e)). Ten hours after the procedure, the patient suffered a sudden onset of left visual loss. Ophthalmic examination showed visual loss in the left eye and temporal hemianopia of the right eye (Figure 2(a), (b)).

Immediate computed tomography (CT) scan showed no intracranial hemorrhage (Figure 3(a)). The following day, we performed emergency DSA, which manifested the near complete occlusion of the aneurysm (Figure 1(f)). Then we re-examined the patient in our hospital with high-resolution MRI, which showed the

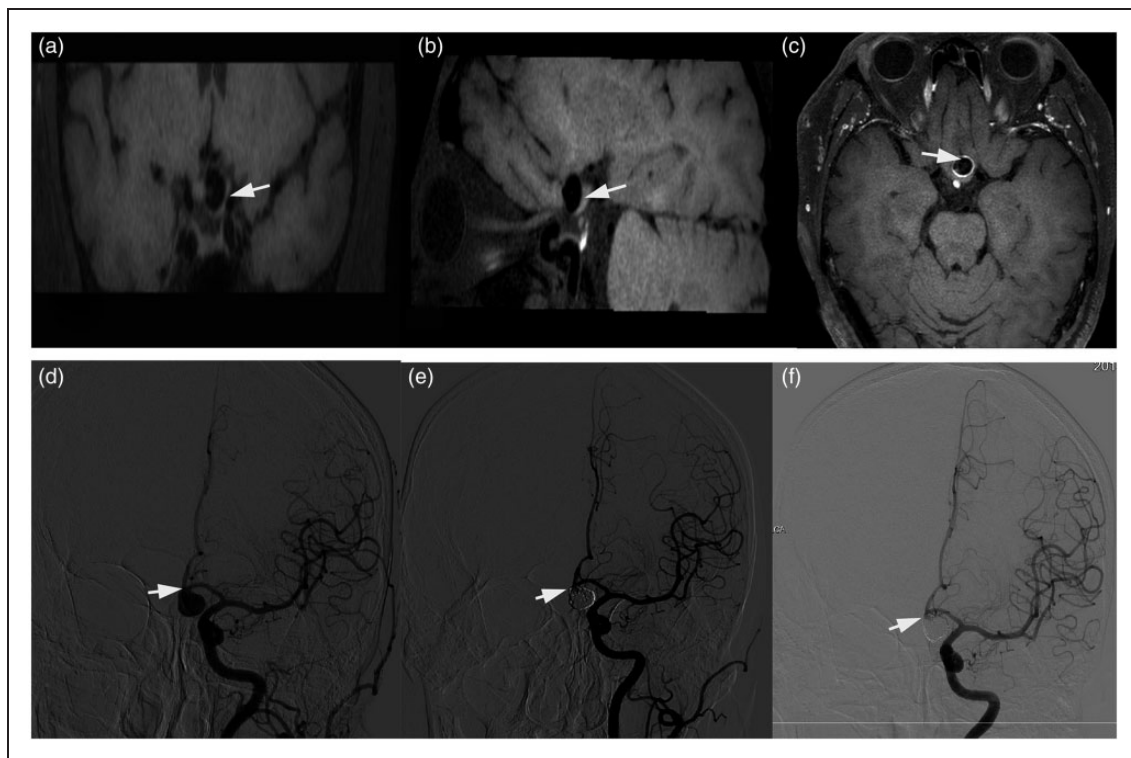


Figure 1. (a), (b) The 3D T1 VISTA sequence from different angles showed the compression of the left optic nerve and the optic chiasma (white arrow). (c) After the administration of the Gd-DTPA, the post-T1 VISTA showed the circumferential aneurysmal wall enhancement (white arrow); (d) Left internal carotid artery angiogram of anteroposterior view showed an aneurysm arising from the anterior communicating artery and directed inferiorly and posteriorly (white arrow). (e) The immediate post-procedure of the left internal carotid artery angiogram showed the near complete occlusion of the aneurysm (residual neck filling of the contrast medium) (white arrow). (f) The second day after the onset of left eye vision loss, the post-procedure of the left internal carotid artery angiogram showed there was no occlusion of the parent vessel and stable occlusion of the aneurysm (white arrow). 3D: three-dimensional; VISTA: volume isotropic turbo-spin-echo acquisition; Gd-DTPA: gadolinium-diethylenetriaminepentaacetic acid dimeglumine.

aneurysm sac was filled with thrombus (Figure 3(b), (c)). The compression of the left optic nerve and chiasma was still present. The patient was given steroid therapy, nerve nutrition and hyperbaric oxygen therapy. Clinical follow-up at six months demonstrated left eye light sensation and minor enlargement of the right visual field

(Figure 2(c), (d)). The six-month follow-up angiography showed the recurrence of the aneurysm neck (Figure 4(a)). After consulting with the neurosurgeon, we performed surgical clipping. During the surgery, we found the aneurysm sac still compressed the left optic nerve and chiasma, resulting in a deep groove into the

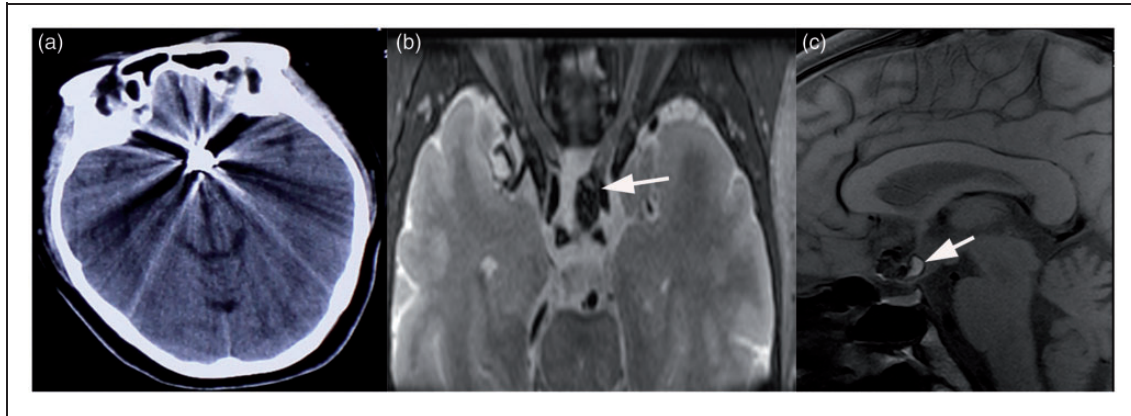


Figure 2. (a), (b) Post-procedure visual field examination showed visual loss in the left eye and temporal hemianopia of the right eye. (c), (d) Eye examination one month after the endovascular treatment showed enlargement of the visual field in the right eye and no obvious change in the left eye.

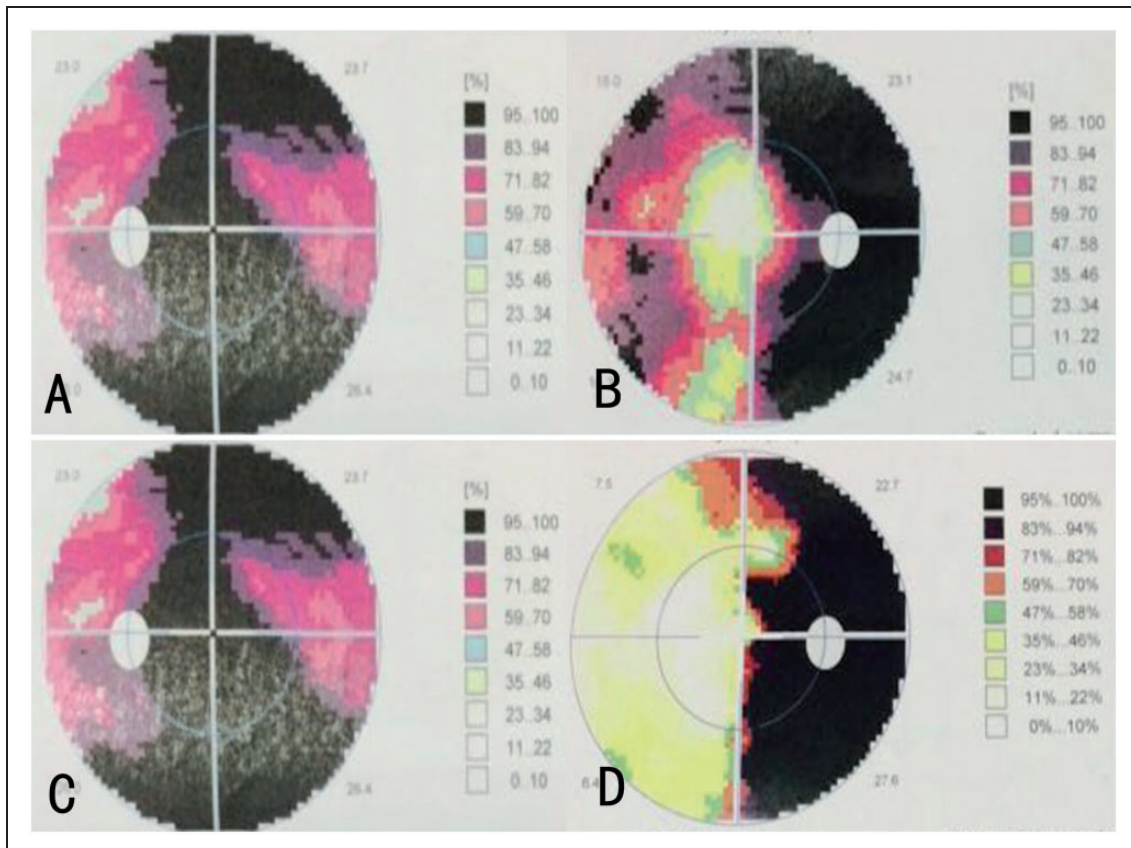


Figure 3. (a) Post-procedure CT scan showed no intracranial hemorrhage after the onset of left eye vision loss. (b) The axial view of the T1 MRI of the brain showed the aneurysm still compressed the left optic nerve and the optic chiasm (white arrow). (c) The coronal view of the T2 MRI of the brain showed the presence of the hyperintense thrombus (white arrow) at the neck of the aneurysm. CT: computed tomography; MRI: magnetic resonance imaging.

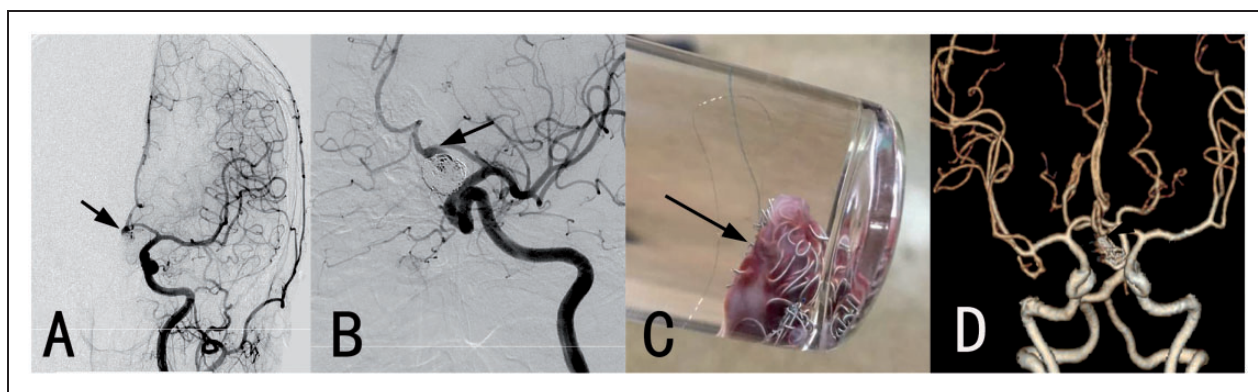


Figure 4. (a), (b) Six-month follow-up angiography showed the recurrence of the aneurysm sac (black arrow). Then we performed surgical clipping. (c) The excised aneurysm sac was preserved in a bottle of formalin. (d) Immediate postoperative CTA showed the complete obliteration of the aneurysm sac (black arrow). CTA: computed tomography angiography.

optic nerve compatible with the imaging of the preprocedure MRI. Then we clipped the aneurysm neck and excised the aneurysm sac (Figure 4(b), (c)). The subsequent postoperative computed tomography angiography (CTA) showed the complete obliteration of the aneurysm (Figure 4(d)).

Case 2

A 55-year-old woman presented with visual loss of the left eye. Ophthalmologic examination showed left visual loss and inferior nasal quadrantanopsia of her right eye (Figure 5(a), (b)). MRA revealed an AComA aneurysm. High-resolution MRI as mentioned in Case 1 was performed and showed the chiasma was compressed by the AComA (Figure 6(a), (b)). The post-contrast T1 VISTA sequence showed the partial enhancement of aneurysm wall (Figure 6(c)). DSA revealed an AcomA aneurysm filling from the left anterior cerebral artery. The aneurysm fundus was directed inferiorly and to the left, with a size of 7.1×8.3 mm (Figure 6(d) (e)). Following our experience in the first case, surgical clipping was decided. After the surgery, the patient recovered with improvement of visual symptoms three weeks after the surgery (Figure 5(c), (d)). Postoperative CTA showed the complete obliteration of the aneurysm (Figure 6(f)). The six-month follow-up CTA showed complete occlusion of the aneurysm with no recurrence.

Review of previous cases

We searched the PubMed database using the keywords “anterior communicating artery aneurysm” and “visual symptoms,” “blindness,” or “vision loss.” We found 11 articles describing 34 people with cases of AcomA aneurysms accompanied by visual symptoms who were treated with endovascular procedure ($n=7$), surgical clipping ($n=26$), or conservative treatment ($n=1$) (Table 1).^{2,4,7–15} The mean age was 52.6 ± 17.7 years with a range of 22 to 66 years. As to the 25 aneurysms with record of aneurysm size, 11 (44%) aneurysms were

larger than 10 mm, while the size in 14 (56%) aneurysms was smaller than 10 mm. The most frequent aneurysm direction was inferior (58.8%, 20/34).

Of 34 patients, two patients with surgical clipping died. Of the remaining 31 survivors, 70.8% (17/24) patients in the surgical group showed improved visual symptoms, which was significantly higher than the 28.6% (two of seven) in the coiling group ($p=0.047$, Fisher’s exact test).

Discussion

Visual deterioration can be induced by AComA aneurysm compression. To our knowledge, AComA aneurysms presenting with visual symptoms are usually large or giant aneurysms.⁸ In 2000, Lownie et al. reported 18 cases of giant AComA aneurysms and found that optic apparatus compression occurred with AComA aneurysms (2.7–3.2 cm) that are pointing inferiorly.⁸ However, most AComA aneurysms rupture when they are small to medium size before they became large enough to compress the optic apparatus.²

The patterns of visual symptoms were specified and categorized as either visual acuity deterioration (visual sensations, visual loss and blindness) or impaired visual fields.^{2,4,6–16} Presentation with only monocular visual loss is very rare,⁵ and the common pattern of visual loss is bilateral field deficits as shown in our cases. It should also be noted that the projection of the AComA aneurysm also contributes to the advent of visual symptoms. Pre-surgical radiologic assessment showed that if the AComA aneurysm protrudes more toward the anterior direction, it may compress the optic nerve. If the aneurysm protrudes more toward the posterior direction as shown in our case, it may compress the optic chiasm.²

As to the two unruptured cases in our study, the compression of the left optic nerve as well as the chiasm was clearly depicted in the high-resolution MRI imaging from different perspectives. The 3D VISTA sequence imaging can suppress the flow signals and their artifacts and makes possible precise

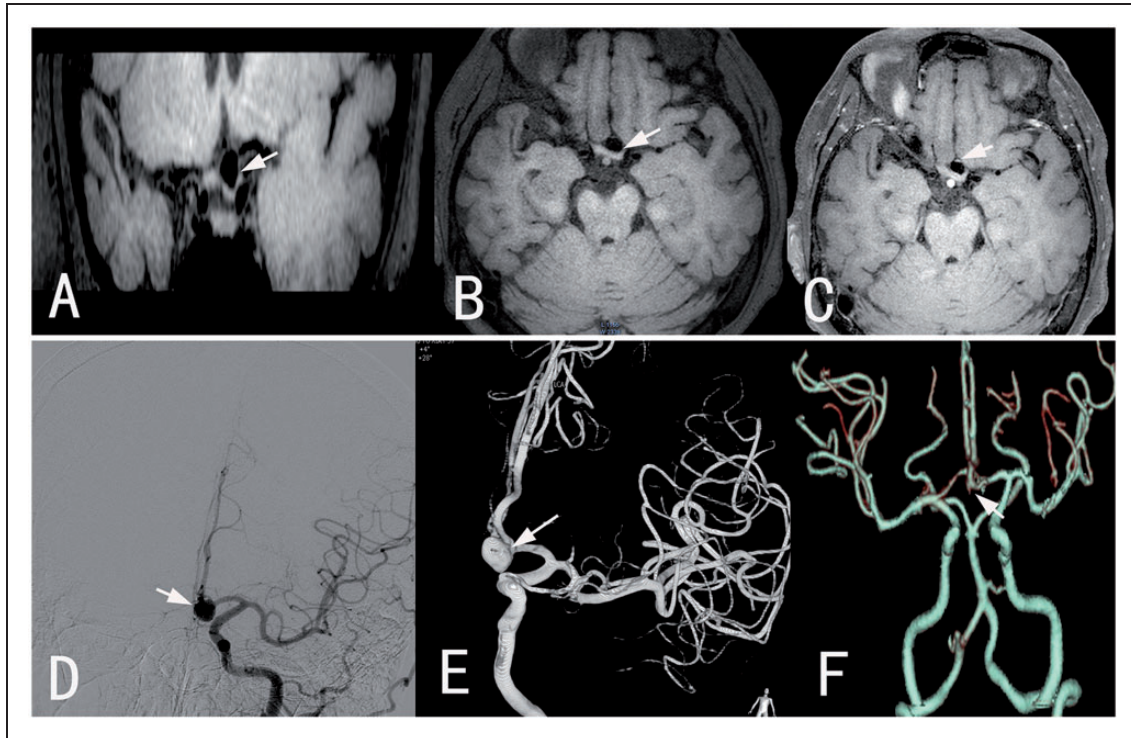


Figure 5. (a), (b) Pre-operation visual field examination showed visual loss in the left eye and inferior nasal quadrantanopsia of the right eye. (c), (d) Eye examination three weeks after surgical clipping showed obvious improvement of the visual field.

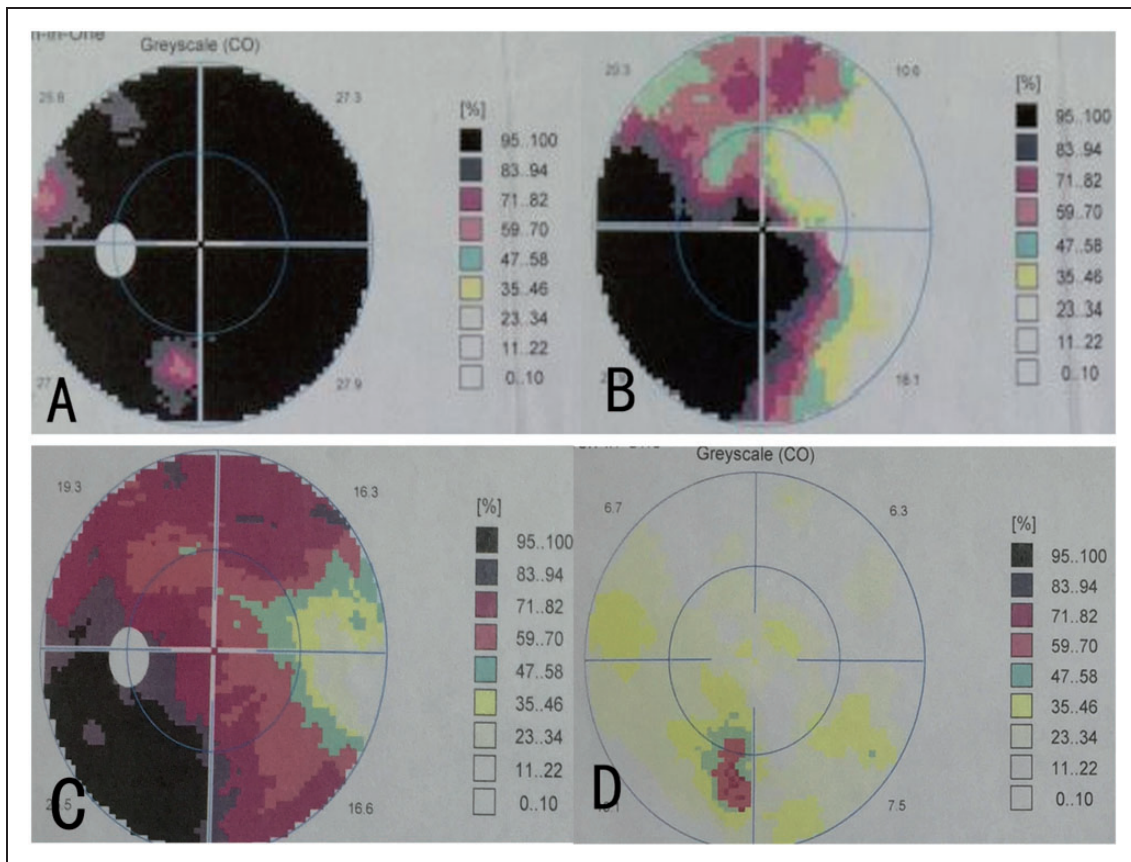


Figure 6. (a), (b) The 3D T1 VISTA sequence from different angles showed the compression of the left optic nerve and the optic chiasm (white arrow). (c) After the administration of the Gd-DTPA, the post-T1 VISTA showed the partial aneurysmal wall enhancement. (d) Left internal carotid artery angiogram of the anteroposterior view showed an aneurysm arising from the anterior communicating artery and directed inferiorly and posteriorly. (e) Immediate postoperative CTA showed the complete obliteration of the aneurysm sac.
3D: three-dimensional; VISTA: volume isotropic turbo-spin-echo acquisition; Gd-DTPA: gadolinium-diethylenetriaminepentaacetic acid dimeglumine.

Table 1. Summary of previously reported cases of anterior communicating artery aneurysms accompanied with visual symptoms.

Authors ^{Ref} /year	Case no.	Age/sex	Visual symptoms	Aneurysm size	Aneurysm direction	Treatment selection	Symptom relieved during follow-up
Shukla et al., ⁶ 2013	1	65/male	Vision loss, right eye temporal hemianopia	26*25*23 mm	Inferior and posterior	Conservative treatment	Not mentioned
Bhat and Sampath, ⁹ 2011	1	22/male	Decreased vision, left eye	NA	Inferior	Clipping	Improved (12 months)
Lee et al., ¹¹ 2011	1	43/female	Normal	3*8 mm	Inferior	Coiling	Deteriorated (two weeks)
Schuss et al., ⁷ 2011	1	57/female	Decreased visual acuity	9 mm	Not mentioned	Clipping	Recovered (three months)
	1	61/female	Decreased visual acuity	7 mm	Not mentioned	Clipping	Recovered (three months)
	1	60/female	Decreased visual acuity	12 mm	Not mentioned	Clipping	Improved (eight months)
	1	46/male	Decreased visual acuity	27 mm	Not mentioned	Clipping	Improved (five months)
	1	56/male	Decreased visual acuity	9 mm	Not mentioned	Coiling	Unchanged (three months)
Park et al., ² 2009	10	50.6/4 male	Visual dimness (5) Unilateral visual field defect (2) Unilateral visual loss (3)	>1 cm (n=3) <1 cm (n=6) Giant (n=1)	Anterior and superior (n=2) Posterior and superior (n=5) Anterior and inferior (n=3)	Clipping	Improved (n=8) Unchanged (n=2)
Umredkar et al., ¹⁵ 2009	1	45/female	Vision loss, right eye	3 mm	Anterior and inferior	Clipping	Unchanged (one year)
Claes et al., ¹¹ 2006	1	29/female	Vision loss, left eye left superior hemianopia	NA	NA	Coiling	Improved, but superior hemianopia still persists (one year)
Craenen et al., ¹² 2004	1	37/female	Vision loss, left eye	NA	Inferior and to the left	Coiling	Unchanged
Hara et al., ¹³ 2002	1	66/female	Normal	NA	NA	Clipping	Deteriorated
	1	63/female	Normal	NA	NA	Clipping	Deteriorated
Lowrie et al., ⁸ 2000	1	49/female	Counting fingers, right eye	2.7 cm	Inferior	Clipping	Unchanged
	1	41/male	Vision loss, left eye	2.7 cm	Inferior	Clipping	Unchanged
	1	25/male	No light perception	3.2 cm	Inferior	Clipping	Improved
Chan et al., ¹⁴ 1997	1	35/female	Vision loss, left eye and upper temporal field defect, right eye	20 mm	Inferior	Coiling	Improved
	1	47/female	Vision loss, right eye	NA	Inferior toward the optic nerve	Coiling	Unchanged
	1	42/male	Vision loss, right eye	NA	Inferior toward the optic nerve	Clipping	Improved
	1	26/male	Vision loss, left eye	NA	Anterior and inferior	Clipping	Improved
	1	49/female	Vision loss, left eye	NA	Inferior	Clipping	Died
	1	35/female	Vision loss, left eye and hemianopia, right eye	5 mm	Inferior	Clipping	Died
Present case	1	65/female	Normal	8.3*9.2 mm	Inferior and to the left	Coiling	Deteriorated
Present case	1	55/female	Vision loss, left eye	7.1*8.3 mm	Inferior	Clipping	Improved

acquisition of the luminal configuration.¹⁶ In addition, in terms of spatial resolution in slice-select direction, partial volume effects, and fine-structure obscurity, the 3D sequence is superior to the traditional two-dimensional sequence. We can reconstruct the acquired images from different angles to better delineate the anatomical relationships.

Although prior to the procedure the presence of compression was detected in our first case, the patient suffered no visual symptoms. Probably, the visual loss after the procedure was heralding the aneurysm's increasing size. However, visual loss due to aneurysm compression usually fluctuates, unlike that from tumors where visual loss is gradually progressive. These fluctuations are induced by thrombosis or intermittent dilation of aneurysm.¹⁵ The visual field deficit might have started with bitemporal hemianopia due to chiasm compression, which the patient would not have noticed. The right optic nerve would have gotten compressed later, presenting with monocular visual loss.

In addition, it is reported that compression from the aneurysm may not be the only factor, even though intracranial aneurysm may compress the optic pathway.² Occlusion of the blood supply to the nerves may also contribute. It is reported that the chiasm's superior capillary network is supplied by the anterior cerebral and AComAs.⁹ As observed in our Case 1, the immediate post-procedural MRI scan verified the presence of the thrombus. So we suspected that the sudden vision loss of the left eye was induced by the formation of a thrombus within the aneurysm neck, then followed by the occlusion of the small vessels originating from the AComA.

As to the treatment of the unruptured aneurysm, whether to treat or not as well as the treatment selection remains controversial. However, the post-contrast T1-VISTA showed circumferential aneurysmal wall enhancement in Case 1 and partial aneurysmal wall enhancement in Case 2, indicating the unstable status of the aneurysm. Recently, an increasing number of cases have been evaluated by high-resolution MRI to find some markers for predicting aneurysm rupture.⁵ The enhancement of the aneurysm wall after gadolinium contrast injection has been regarded as an unstable factor for inflammation, and therefore as a potential marker of aneurysm instability.

Surgical clipping permits immediate relief from compression; endovascular coiling does not resolve the mass effect. However, visual symptom improvement after endovascular treatment has often been discussed as a reduction of aneurysm pulsatility.^{17,18} Treatment in a timely manner has often been discussed as a significant factor in predicting visual outcome.³ However, case reports on complications of this treatment such as incomplete aneurysm coiling, and failure to alleviate symptoms related to mass effect have also been published.^{19,20} In our Case 1, the patient developed deterioration of vision after coil embolization, although there is no visual symptom before treatment. The optic nerves and chiasm are probably more susceptible to

mass effect because of long-standing compressive forces from aneurysm pulsations.

After reviewing similar cases in the literature, we found the recovery of vision after endovascular or clipping surgery was variable and ranged from no improvement to complete recovery.^{2,4,6-16} The Fisher's exact test showed that surgical clipping was significantly superior to endovascular procedure in improving visual symptoms (70.8% vs 28.6%, $p < 0.05$). In 2015, Shimizu et al. evaluated 39 cases of large or giant paraclinoid aneurysms treated with endovascular coiling and microsurgical clipping with special reference to visual outcomes, and concluded that visual outcomes with microsurgical clipping and endovascular coiling were almost the same.²¹ In 2011, Schuss et al. reviewed 165 cases of intracranial aneurysms complicated by visual dysfunction due to compression of the optical nerve treated with endovascular treatment or surgical clipping.⁷ The authors concluded that aneurysm-related visual dysfunction developing from direct mechanical compression might improve after surgical clipping and endovascular coiling. However, the authors found surgical clipping might achieve a significantly higher rate of visual improvement ($p = 0.002$) compared with endovascular treatment and, according to the multivariate analysis, surgical clipping was the only variable significantly associated with improvement of visual outcome ($p = 0.02$). Among the 20 cases reported by the authors, five patients had AComA aneurysms. Four patients who underwent surgical clipping all recovered or had improved visual symptoms. The patient with coil embolization had unchanged visual symptoms. Our experience with the two cases agrees with the profile of the study.

Conclusion

AComA aneurysm coiling may cause vision symptoms after the procedure and should be considered very carefully in patients presenting with compression of the optic pathways. Preoperative MRI is helpful and necessary to delineate the relationship between the aneurysm and the optic pathways. The mass effect after the endovascular procedure should be taken into consideration. Under this circumstance, surgical clipping appears to be a better choice.

Acknowledgments

Informed consent was obtained from the individual participants included in this study to publish related materials. Institutional review board approval was obtained from Beijing Tiantan Hospital's ethics committee for this study.

Declaration of conflicting interests

The authors declared no potential conflicts of interest with respect to the research, authorship, and/or publication of this article.

Funding

The authors disclosed receipt of the following financial support for the research, authorship, and/or publication of this

article: This work was supported by the Commission of Beijing Municipal Science and Technology, Municipal Clinical Special Application Study, the Special Fund Project (No.Z14110000211441); Beijing Talents Training Project (Category D) and Beijing Hygiene System High-level Hygienic Technical Personnel Training Program and the Talents Program of Beijing Tiantan Hospital (Hospital Backbone Program); National Natural Science Foundation (2060194).

References

- Norwood EG, Kline LB, Chandra-Sekar B, et al. Aneurysmal compression of the anterior visual pathways. *Neurology* 1986; 36: 1035–1041.
- Park JH, Park SK, Kim TH, et al. Anterior communicating artery aneurysm related to visual symptoms. *J Korean Neurosurg Soc* 2009; 46: 232–238.
- Date I, Asari S and Ohmoto T. Cerebral aneurysms causing visual symptoms: Their features and surgical outcome. *Clin Neurol Neurosurg* 1998; 100: 259–267.
- Shukla DP, Bhat DI and Devi BI. Anterior communicating artery aneurysm presenting with vision loss. *J Neurosci Rural Pract* 2013; 4: 305–307.
- Edjlali M, Gentic JC, Régent-Rodriguez C, et al. Does aneurysmal wall enhancement on vessel wall MRI help to distinguish stable from unstable intracranial aneurysms? *Stroke* 2014; 45: 3704–3706.
- Pico F, Biousse V, Chapot R, et al. Aneurysm of the anterior cerebral artery disclosed by unique hemianopic scotoma [article in French]. *Rev Neurol (Paris)* 2002; 158: 347–350.
- Schuss P, Güresir E, Berkefeld J, et al. Influence of surgical or endovascular treatment on visual symptoms caused by intracranial aneurysms: Single-center series and systematic review. *J Neurosurg* 2011; 115: 694–699.
- Lownie SP, Drake CG, Peerless SJ, et al. Clinical presentation and management of giant anterior communicating artery region aneurysms. *J Neurosurg* 2000; 92: 267–277.
- Bhat DI and Sampath S. Anterior communicating artery aneurysm presenting as monocular blindness. *Br J Neurosurg* 2011; 25: 644–646.
- Lee SH, Koh JS, Lee CY, et al. Penetration and splitting of the optic apparatus by intrasaccular coils within an anterior communicating artery aneurysm. *Clin Neurol Neurosurg* 2011; 113: 578–581.
- Claes C, Milea D, Bodaghi B, et al. Acute retrobulbar optic neuropathy due to rupture of an anterior communicating artery aneurysm. *Acta Ophthalmol Scand* 2006; 84: 145–146.
- Craenen G, Brown SM, Freedman KA, et al. Rapid, painless unilateral vision loss in a 37-year-old healthy woman. *Surv Ophthalmol* 2004; 49: 343–348.
- Hara N, Mukuno K, Ohtaka H, et al. Ischemic optic neuropathy associated with subarachnoid hemorrhage after rupture of anterior communicating artery aneurysm. *Ophthalmologica* 2003; 217: 79–84.
- Chan JW, Hoyt WF, Ellis WG, et al. Pathogenesis of acute monocular blindness from leaking anterior communicating artery aneurysms: Report of six cases. *Neurology* 1997; 48: 680–683.
- Umredkar AA, Singla N and Gupta SK. Ruptured anterior communicating artery aneurysm presenting with monocular blindness. *Neurol India* 2009; 57: 826–828.
- Naggara O, Oppenheim C, Louillet F, et al. Traumatic intracranial dissection: Mural hematoma on high-resolution MRI. *J Neuroradiol* 2010; 37: 136–137.
- White PM, Lewis SC, Nahser H, et al. HydroCoil Endovascular Aneurysm Occlusion and Packing Study (HELPS trial): Procedural safety and operator-assessed efficacy results. *AJNR Am J Neuroradiol* 2008; 29: 217–223.
- Kazekawa K, Tsutsumi M, Aikawa H, et al. Internal carotid aneurysms presenting with mass effect symptoms of cranial nerve dysfunction: Efficacy and imitations of endosaccular embolization with GDC. *Radiat Med* 2003; 21: 80–85.
- Ferns SP, Sprengers ME, van Rooij WJ, et al. Coiling of intracranial aneurysms: A systematic review on initial occlusion and reopening and retreatment rates. *Stroke* 2009; 40: e523–e529.
- Tawk RG, Villalobos HJ, Levy EI, et al. Surgical decompression and coil removal for the recovery of vision after coiling and proximal occlusion of a clinoidal segment aneurysm: Technical case report. *Neurosurgery* 2006; 58: E1217.
- Shimizu T, Naito I, Aihara M, et al. Visual outcomes of endovascular and microsurgical treatment for large or giant paraclinoid aneurysms. *Acta Neurochir (Wien)* 2015; 157: 13–20.