

Carotid Body Tumor as a Cause of Stroke

Hrvoje Budinčević^{1,2}, Ana Piršić¹, Tihana Bohm¹, Tomislav Trajbar³, Ante Ivkošić³,
Tomislav Pavlović⁴, Ivan Bielen^{1,2} and Silva Soldo-Butković^{2,5}

Abstract

We herein report a case of a 78-year-old woman who was admitted to our hospital due to a stroke with left-sided hemiparesis. Ultrasound of the carotid arteries showed a carotid body tumor on the bifurcation of the right common carotid artery, which was subsequently confirmed by a further neuroradiological investigation. Magnetic resonance imaging of the head confirmed an acute ischemic lesion located in the right periventricular region. The carotid body tumor (CBT) was surgically removed and confirmed on histopathology. Our case reveals the role of carotid ultrasound in the diagnosis of a CBT, which may be a potential cause of stroke.

Key words: carotid body tumor, stroke, ultrasound

(Intern Med 55: 295-298, 2016)

(DOI: 10.2169/internalmedicine.55.5350)

Introduction

Paragangliomas are rare tumors of the head and neck arising from paraganglionic tissue which is derived from the neural crest (1). Paraganglia are chemoreceptor organs that are distributed throughout the body. They include the glomus jugulare and glomus tympanicum within the temporal bone, carotid body tumors (CBTs) arising from the carotid body and along the nerves in the head and neck, such as the vagal or laryngeal nerves (2). They grow slowly and rarely metastasize (3). The association between CBTs and stroke has not been clearly demonstrated in the literature, however, cerebrovascular accidents are serious postoperative complications (4).

We herein describe a CBT as a potential cause of stroke and the role of carotid ultrasound.

Case Report

We herein present the case of a 78-year-old Caucasian woman who presented with sudden onset of left-sided hemiparesis. Her previous medical history included arterial hypertension for the last twenty years and diabetes mellitus for

the last two years. She was taking lisinopril, chlorthalidone and gliclazide on a regular basis. A neurological and physical examination on admission showed mild to moderate left-sided hemiparesis, elevated blood pressure (190/120 mmHg) and tachycardia of 130 beats per minute. Cardiac and carotid auscultation revealed no bruits.

On admission to the ward, the patient's blood pressure and heart rate had normalized. The laboratory exams were mainly within the normal ranges; we found only slight hyperglycemia and elevated values of cholesterol (5.52 mmol/L), low-density lipoprotein (3.76 mmol/L) and triglycerides (2.22 mmol/L). An electrocardiography (ECG) showed a sinus rhythm with heart rate of 102 per minute. Initial computerized tomography (CT) of the brain showed a discrete hypodense area of the insula in the right parieto-temporal region, which was suspected to be an acute lesion with one older vascular lesion on the fronto-parietal right side. Ultrasound of the carotid and vertebral arteries showed calcified plaques in the proximal parts of both internal carotid arteries and a highly vascularized tumor mass (dimensions of 11.8×8.5 mm) likely to be a CBT on the bifurcation of the right common carotid artery (Fig. 1), which was confirmed with CT angiography (CTA) of the neck vessels (Fig. 2). Magnetic resonance imaging (MRI) of the brain using the fluid-

¹Stroke and Intensive Care Unit, Department of Neurology, Sveti Duh University Hospital, Croatia, ²School of Medicine, Josip Juraj Strossmayer University of Osijek, Croatia, ³Department of Surgery, Sveti Duh University Hospital, Croatia, ⁴Department of Radiology, Sveti Duh University Hospital, Croatia and ⁵Department of Neurology, University Hospital Center Osijek, Croatia

Received for publication March 16, 2015; Accepted for publication May 7, 2015

Correspondence to Dr. Hrvoje Budinčević, hbudincevic@gmail.com

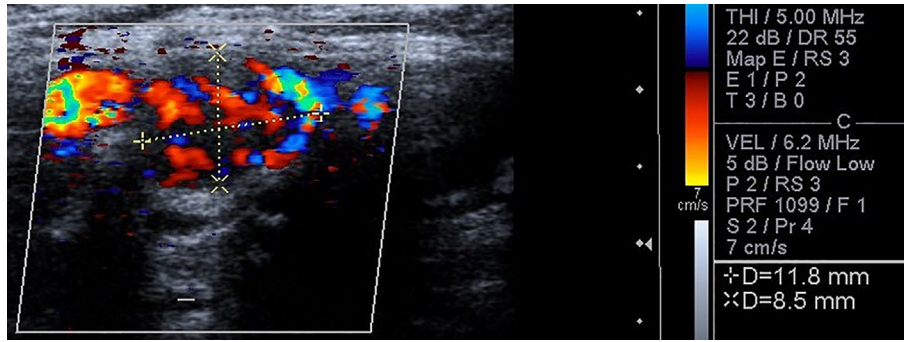


Figure 1. Duplex ultrasound showing the carotid body tumor.

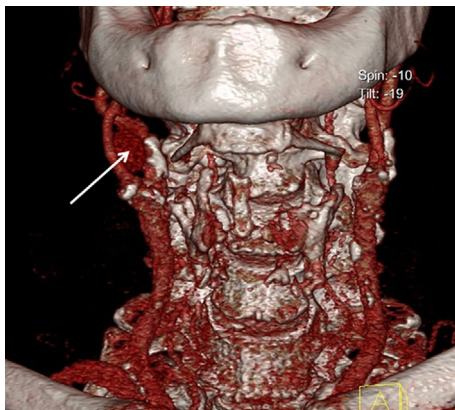


Figure 2. CT angiography of the neck vessels showing a carotid body tumor on the bifurcation of the right common carotid artery with mild compression of the right internal carotid artery (arrow).

attenuated inversion recovery (FLAIR) technique confirmed an acute ischemic lesion located in the right periventricular region (Fig. 3). MRI of the neck using the short tau inversion recovery (STIR) technique showed a hyperintense signal on the bifurcation of the right common carotid artery, which could correspond to a CBT (Fig. 3). The patient was examined by a surgeon who suggested elective surgery of the CBT within five weeks.

To exclude any possible hormonal activity of the tumor, additional laboratory tests were performed: the adrenaline, noradrenaline, dopamine, metanephrine and normetanephrine levels in the urine, as well as neuron-specific enolase in the serum, were within the normal ranges. Normal values of thyroid hormones and negative antithyroglobulin antibodies and anti-thyroid peroxidase antibodies were also found. The patient was discharged with slight right-sided hemiparesis and prescribed acetylsalicylic acid and rosuvastatin along with her previous therapy.

The surgically removed tumor was approximately 2×2 cm in the area of the right carotid bifurcation (Fig. 4). A histopathological analysis confirmed the suspected CBT (grade II according to the Shambling classification). No complications were observed following the surgical procedure and postoperative period.

Discussion

CBTs are very rare, however, they are the most common form of paraganglioma of the head and neck region, with a female predominance in the fifth and sixth decades of life (5, 6). They arise at the bifurcation of the internal and external carotid arteries (7). A CBT often presents as a slow growing (at an estimated rate of 2.0 cm in diameter every 5 years), painless mass located at the side of the neck below the jaw angle (7, 8). They are movable in the horizontal plane, however, their mobility is limited in the vertical plane (Fontaine sign) (9). Other symptoms may include dysphagia, odynophagia or hoarseness of the voice as a result of nerve compression (10). Horner's syndrome due to the invasion or compression of the cervical sympathetic chain and syncope may be seen due to carotid sinus or internal carotid artery (ICA) compression (11). The patients may also have a history of fluctuating hypertension, flushing, palpitations and obstructive sleep apnea as a result of excessive catecholamine production (functional tumors) (7, 11).

Digital subtraction angiography (DSA) is the gold standard for diagnosing a CBT, however, carotid ultrasound is also accepted and is a non-invasive procedure with high sensitivity and specificity; it is recommended as the primary diagnostic investigation by the Joint Vascular Research Group (11, 12). In the present case, carotid ultrasound had an important role in identifying the CBT and differentiating it from other neck masses, such as brachial cysts, solitary lateral aberrant thyroid masses, neurofibromas, mixed parotid tumors, lymph nodes, carotid artery aneurysms and arteriovenous fistulas (13-15). The carotid ultrasound finding was comparable to the CTA and MRI findings, which are also useful modalities for identifying a CBT (16).

According to the tumor size, CBTs are divided into three groups according to the Shambling classification system (17). Despite being a benign and slow growing tumor, surgical resection of CBTs is the treatment of choice (10). In some cases endovascular embolization may be performed prior to surgery, using liquid agents or coils to reduce the tumor size or intraoperative complications, such as bleeding (18). In select cases conventional radiotherapy or stereotactic radiosurgery may be treatment options (13).

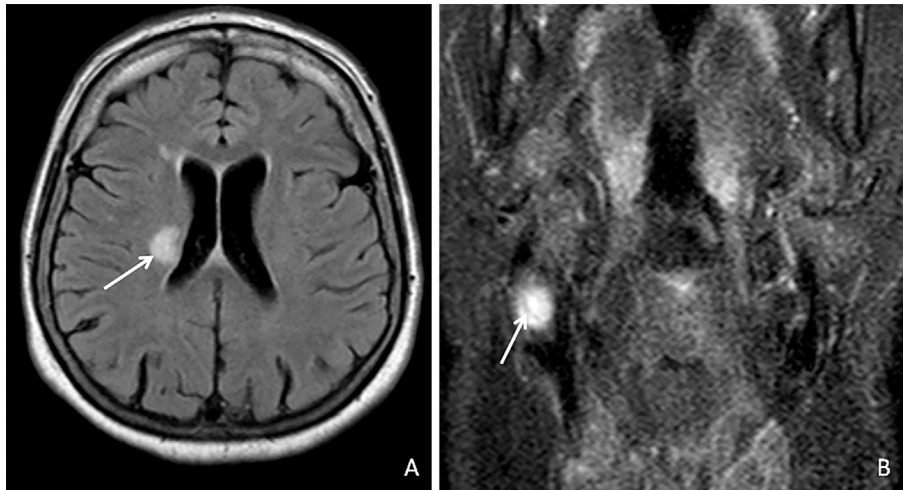


Figure 3. A: Magnetic resonance imaging (MRI) of the brain using the FLAIR technique which shows an acute ischemic lesion located in the right periventricular region (arrow). B: MRI of the neck using the STIR technique which shows a hyperintense signal on the bifurcation of the right common carotid artery (arrow).

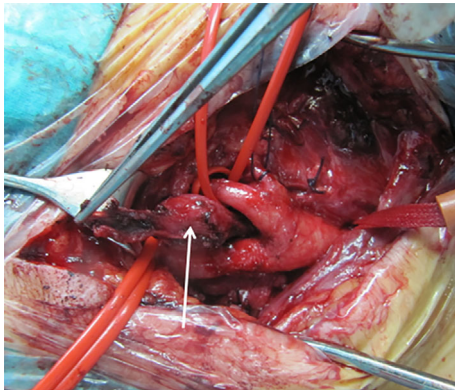


Figure 4. Intraoperative image of the carotid body tumor (arrow).

Regarding postoperative complications, the incidence of stroke with CBT is reported to be as high as 11% (4). The other reported postoperative neurological complications are typically nerve palsies (19). To the best of our knowledge, cerebrovascular incidents are rarely associated with CBTs (8). Chamoro Sanchez et al. and a recent case report from Larrosa et al. suggested the association between cerebrovascular incidents and CBTs (20, 21). Chamoro Sanchez et al. pointed out that the probable cause of a transient ischemic attack was due to the carotid low perfusion state (20). Larrosa et al. suggested that CBTs that completely surround the ICA should be included among the uncommon causes of stroke (21).

In the present case, the CBT was an additional risk factor for stroke, because an older age, a long history of the presence of arterial hypertension and diabetes mellitus are more serious risk factors compared to a CBT. However, even mild compression of the CBT on ICA could cause ischemic symptoms, such as in the present case (Fig. 2). Nevertheless,

a CBT may have a negative effect on uncontrolled arterial hypertension, especially in hormonally active tumors, and may also cause sleep apnea syndrome, which was not observed in our patient.

In conclusion, carotid ultrasound may be used as the primary investigation procedure in suspicion of CBT. CBTs must be promptly treated as they can cause ICA compression and may have an influence on stroke risk factors, such as arterial hypertension and sleep apnea syndrome.

The authors state that they have no Conflict of Interest (COI).

References

1. Avgerinos ED, Moulakakis K, Bruntzos E, et al. Advances in assessment and management of carotid body tumors. *Vascular* **19**: 250-256, 2011.
2. Prasad SC, Thada N, Pallavi, Prasad KC. Paragangliomas of the Head & Neck: the KMC experience. *Indian J Otolaryngol Head Neck Surg* **63**: 62-73, 2011.
3. Mathew BK, Bandgar T, Menon PS, Shah NS. Carotid body tumours: three case reports. *Singapore Med J* **50**: e58-e60, 2009.
4. Sajid MS, Hamilton G, Baker DM. A multicenter review of carotid body tumour management. *Eur J Vasc Endovasc Surg* **34**: 127-130, 2007.
5. Patlola R, Ingraldi A, Walker C, Allie D, Khan IA. Carotid body tumor. *Int J Cardiol* **143**: e7-e10, 2010.
6. Ma D, Liu M, Yang H, Ma X, Zhang C. Diagnosis and surgical treatment of carotid body tumor: A report of 18 cases. *J Cardiovasc Dis Res* **1**: 122-124, 2010.
7. Davidovic LB, Djukic VB, Vasic DM, Sindjelic RP, Duvnjak SN. Diagnosis and treatment of carotid body paraganglioma: 21 years of experience at a clinical center of Serbia. *World J Surg Oncol* **3**: 10, 2005.
8. Ropper AH, Brown RH. Carotid Body Tumor (Paraganglioma). In: Adams and Victor's Principles of Neurology. 8th ed. McGraw-Hill, New York, 2005: 574.
9. Del Guercio L, Narese D, Ferrara D, Butrico L, Padricelli A,

- Porcellini M. Carotid and vagal body paragangliomas. *Transl Med UniSa* **6**: 11-15, 2013.
10. Wieneke JA, Smith A. Paraganglioma: carotid body tumor. *Head Neck Pathol* **3**: 303-306, 2009.
11. Naik SM, Shenoy AM, Nanjundappa, et al. Paragangliomas of the carotid body: current management protocols and review of literature. *Indian J Surg Oncol* **4**: 305-312, 2013.
12. Luo T, Zhang C, Ning YC, Gu YQ, Li JX, Wang ZG. Surgical treatment of carotid body tumor: case report and literature review. *J Geriatr Cardiol* **10**: 116-118, 2013.
13. Erdogan BA, Bora F, Altin G, Paksoy M. Our experience with carotid body paragangliomas. *Prague Med Rep* **113**: 262-270, 2012.
14. Steinke W, Hennerici M, Aulich A. Doppler color flow imaging of carotid body tumors. *Stroke* **20**: 1574-1577, 1989.
15. Matticari S, Credi G, Pratesi C, Bertini D. Diagnosis and surgical treatment of the carotid body tumors. *J Cardiovasc Surg (Torino)* **36**: 233-239, 1995.
16. Carroll W, Stenson K, Stringer S. Malignant carotid body tumor. *Head Neck* **26**: 301-306, 2004.
17. Shamblin WR, ReMine WH, Sheps SG, Harrison EG Jr. Carotid body tumor (chemodectoma). Clinicopathologic analysis of ninety cases. *Am J Surg* **122**: 732-739, 1971.
18. Cvjetko I, Erdelez L, Podvez Z, et al. Coil embolization and surgical removal of carotid body paraganglioma. *J Craniofac Surg* **24**: e242-e245, 2013.
19. Sen I, Stephen E, Malepathi K, Agarwal S, Shyamkumar NK, Mammen S. Neurological complications in carotid body tumors: a 6-year single-center experience. *J Vasc Surg* **57** (Suppl 2): 64S-68S, 2013.
20. Chamorro Sanchez A, Varela de Seijas E, Matesanz Matesanz J, Trapero VL. Carotid body tumor: unusual cause of transient ischemic attacks. *Stroke* **19**: 102-103, 1988.
21. Larrosa D, Vega J, Benavente L, Ramon C, Calleja S, Pascual J. Teaching neuroimages: carotid body tumor as a novel cause of cerebral ischemic stroke. *Neurology* **79**: e58, 2012.