

SOLITAIRE™ 2 4x40 REVASCULARIZATION DEVICE COMPLETE STROKE ZONE COVERAGE¹



DISTAL M2
DEPLOYMENT

OPHTHALMIC
ALIGNMENT

Simplified placement with proximal ophthalmic alignment
providing the most complete STROKE ZONE coverage
from ICA to M2.¹

¹ Solitaire™ 2 IFU, Trevo™ Device IFU. Pai S.B., et. al. Microsurgical Anatomy of the Middle Cerebral Artery. Neurology India. June 2005. Vol 53. Issue 2. Keshelava G. et. al. Surgical anatomy of petrous part of the internal carotid artery. Neuroanatomy (2009) 8: 46-48

© 2015 Medtronic. All Rights Reserved. EU-15-525679 - 12/2015



To contact us, please visit:
www.medtronic.com/covidien/support/emea-customer-service
Use scan app to read

Medtronic
Further, Together

Unique cause of right hemispheric syndrome: Embolism of myocardium after open septal myectomy

Meghan E Murphy¹, Giuseppe Lanzino¹, Aditya Raghunathan²,
Hartzell Schaff³ and Jennifer E Fugate⁴

Abstract

We present a novel case of acute ischemic stroke in the postoperative setting of open septal myectomy. A 24-year-old woman developed acute left hemiparesis and rightward eye deviation the morning after surgery. She underwent emergent endovascular stroke therapy by mechanical embolectomy with successful retrieval of a fragment of myocardium that was obstructing the right middle cerebral artery. To our knowledge there has been no previous case described of a myocardial fragment causing a proximal intracranial artery occlusion with resulting ischemia and infarction.

Keywords

Cerebral ischemia, mechanical embolectomy, endovascular therapy, stroke, septal myectomy, embolism

Introduction

Ventricular septal myectomy is a mainstay therapy for treatment of hypertrophic obstructive cardiomyopathy. For patients with heart failure symptoms refractory to maximal medical therapy, septal myectomy has been shown to be both effective and safe.^{1–4} Data from the US Nationwide Inpatient Sample (NIS) Database show an overall complication rate of 30.2% after myectomy surgery, with the majority of complications being cardiac in nature. Only 2.6% of patients suffered postoperative cerebral ischemia following ventricular septal myectomy though the mechanisms of stroke were not detailed.⁵

Cerebral ischemia secondary to an embolus following myectomy surgery is a known possible cause of stroke in the cardiovascular surgery practice. Almost all cases are due to embolization of thrombus or plaque. We report a case of embolization of a myocardial fragment as a treatable cause of stroke following septal myectomy. Timely endovascular intervention can allow for retrieval of the embolus, subsequent restoration of blood flow, and a full recovery.

Case report

The patient is a 24-year-old female with a history of symptomatic hypertrophic cardiomyopathy referred to the Division of Cardiovascular Surgery for consideration of septal myectomy. She was electively admitted for transaortic septal myectomy and transapical

midventricular myectomy. The intraoperative course was uncomplicated. Routine postoperative studies revealed expected results: normal sinus rhythm with stable left atrial enlargement and left ventricular hypertrophy on an electrocardiogram and a post-bypass echocardiogram revealing complete resolution of the 70 mmHg gradient with a stable ejection fraction.

On the morning of postoperative day one she was found to have left sided weakness. Her initial National Institute of Health Stroke Scale (NIHSS) score was 10 with right gaze deviation, left lower facial weakness, left upper extremity pronator drift, and inability to lift the left lower extremity against gravity. She did not report headache. Noncontrast computed tomography (CT) imaging revealed hypodensity in the right caudate and putamen (Figure 1(a)). CT angiogram demonstrated an occlusion of the proximal M1 segment of the right middle cerebral artery with leptomeningeal collateralization (Figure 1(b)). She was emergently transferred to the angiogram suite and selective catheterization of the right internal carotid artery confirmed a proximal M1 occlusion with delayed reconstitution of distal middle

¹Department of Neurologic Surgery, Mayo Clinic, Rochester, USA

²Department of Pathology, Mayo Clinic, Rochester, USA

³Department of Cardiovascular Surgery, Mayo Clinic, Rochester, USA

⁴Department of Neurology, Mayo Clinic, Rochester, USA

Corresponding author:

Meghan E Murphy, Department of Neurosurgery, Mayo Clinic, 200 1st St SW Rochester, MN 55905, USA.

Email: murphy.meghan@mayo.edu

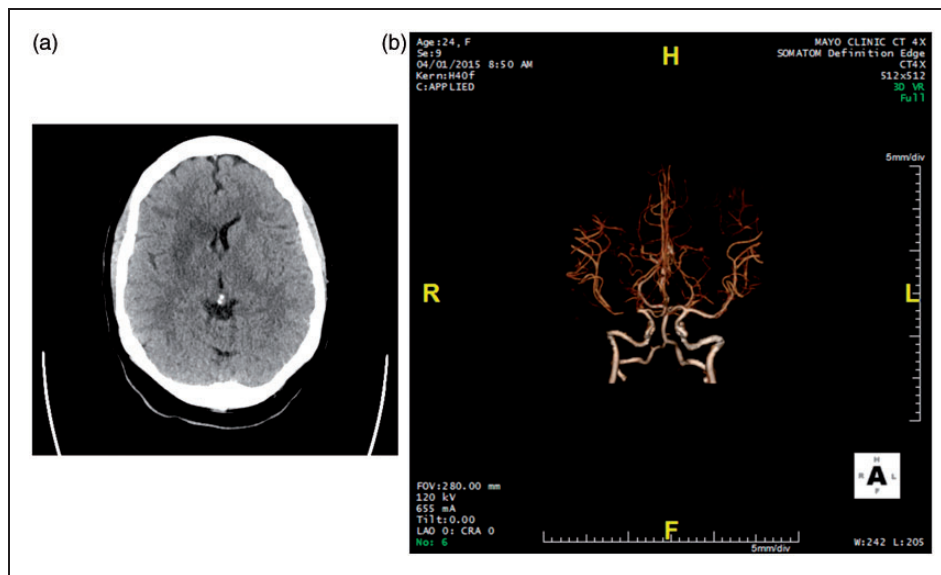


Figure 1. (a) Computed tomography (CT) obtained following onset of symptoms revealing hypodensity. (b) CT angiogram obtained following onset of symptoms revealing a right M1 occlusion.

cerebral artery (MCA) branches through leptomeningeal collaterals (Figure 2(a)). The diagnostic catheter was exchanged for a 6 French Cook Shuttle guide catheter which was placed into the proximal ICA. Through the guide, a 5ACE Penumbra aspiration catheter was advanced over a Rebar 18 Micro Catheter and a Transend soft tip microguidewire. At first try, the microguidewire would not easily negotiate the obstructive embolus. Thus, the aspiration catheter was positioned immediately proximal to the obstruction, but no revascularization occurred after the first pass. A second attempt to cross the obstruction site with the microguidewire was successful and a Solitaire stent-retriever was then deployed across the obstruction and successfully engaged the embolus. The catheter with stent retrieval system was then pulled and a single rubbery embolus was removed (Figure 3). Final angiographic runs revealed complete revascularization of the middle cerebral artery territory (Figure 2(b)). Pathological analysis identified the embolus as myocardium (Figure 4).

Over the ensuing days, the patient experienced progressive improvement of her left-sided weakness. Repeat CT revealed a stable infarct with minimal hyperdensity within the infarct likely reflecting a combination of hemorrhage and contrast. She was initiated on aspirin for potential endothelial injury following deployment of the retrieval device. She was transferred to an acute rehabilitation facility and eventually discharged home. Her NIHSS on post-intervention day two was 3 and at discharge from acute rehabilitation was 1, with only a mild facial droop on the left.

Discussion

Hypertrophic cardiomyopathy (HCM), the most common monogenic cardiovascular disease, is

classically characterized by the pathophysiologic effects of left ventricular outflow obstruction.⁶ Annual mortality rates in patients with HCM range from 3% to 6% secondary to fatal arrhythmias and progressive heart failure. Septal myectomy is now the gold-standard surgical intervention for treatment of symptomatic HCM refractory to maximal medical therapy.⁶ Reduction of the outflow obstruction results in improved hemodynamic parameters, improved functional status, and, consequently, decreased symptoms and decreased incidence of syncope and sudden cardiac death.^{1,2,5,7,8}

Postoperative complications in septal myectomy are most commonly cardiac in nature. Cerebrovascular accidents or transient ischemic attacks are uncommon, reported in only 0.62% to 2.6% of patients.^{5,9} The case presented above demonstrates a possible complication, an acute stroke due to intra-arterial vessel occlusion by embolus. While rare overall, most postoperative embolic strokes are due to thrombus or plaque emboli, but in the case presented here, the embolic material was proven to be a piece of myocardium.

Myocardial fragment embolization should be included in the differential diagnosis of a patient with an acute ischemic stroke in the postoperative setting after myectomy.

The most common embolic etiologies for cerebral ischemia include both cardioembolic and atherothrombotic sources, 71% and 20%, respectively.¹⁰ There are some clinical features that may assist in delineating the mechanism of ischemia; cardioembolic sources typically result in minimal time from onset to maximal deficit, decreased level of consciousness, Valsalva maneuver at onset, and co-occurrence of systemic embolic. This is in contrast to lacunar ischemia and infarction, which can have a stuttering course and multiple infarcts.¹¹ The patient presented here had an extremely short interval between detection of symptoms to maximal deficit of

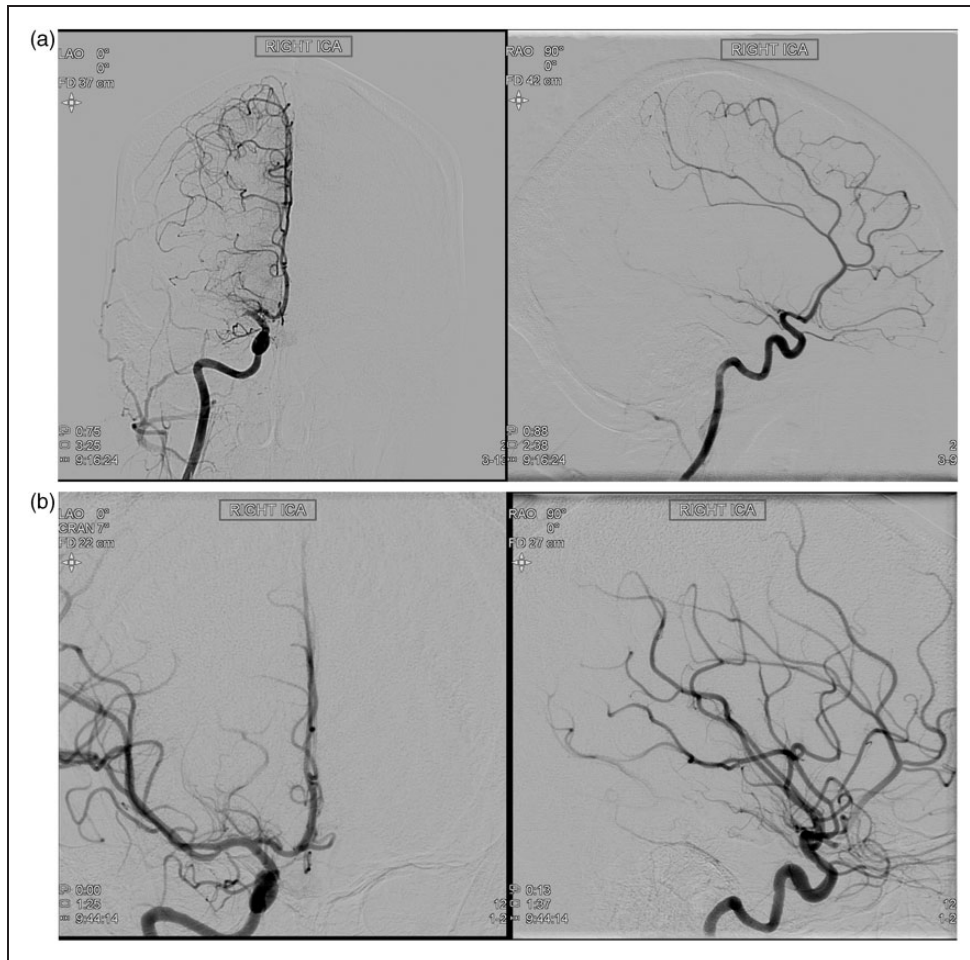


Figure 2. (a) Coronal and sagittal digital subtraction angiography (DSA) of the right internal cerebral artery (ICA) confirming a right M1 occlusion. (b) Coronal and sagittal DSA status post embolus retrieval and revascularization.

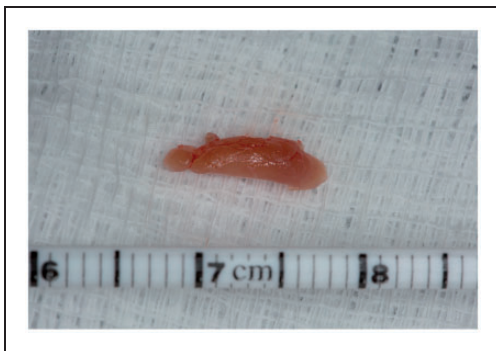


Figure 3. Embolus retrieved via Solitaire device and sent as pathologic specimen.

hemiplegia, fitting a characteristic pattern for cardioembolic etiology. Less common embolic compositions have been reported including cancerous emboli in patients with metastatic disease. Cardiac myxomas and pulmonary neoplasms have been reported as sources for embolic ischemia as well as neoplastic aneurysms.¹² In a series of 402 patients with cardioembolic stroke, structural cardiac defects, valvular disease, and arrhythmias were the disorders associated

with emboli.¹³ No cases identified myocardial fragments as the embolic material. Myocardial emboli would be more expected in the postoperative setting, following surgical manipulation of the myocardium, rather than in patients not undergoing cardiac surgery. Surgeons are well aware of the possibility of myocardial fragment embolization, as in this case, but it remains a rare cause of cardioembolic stroke postoperatively.

While intravenous thrombolysis (i.v. tPA) is the standard of care for eligible patients with acute ischemic stroke, our patient was not eligible for this treatment because of the recent cardiac surgery. In retrospect, knowing that the embolus was composed of myocardium, tPA would not have been successful in recanalizing the vessel regardless. Endovascular therapy (EVT) improves the rates of recanalization and good functional outcomes in patients with proximal large vessel occlusions. EVT is becoming standard of care in patients who fulfill certain clinical criteria after publication of numerous clinical trials proving its efficacy and safety.^{14–22} EVT has improved the rate of favorable functional outcomes, classified as Modified Rankin Scores (mRS) of 2 or less at 90 days, from 19–36% to 33–60% in patients with large vessel occlusion.^{16,18–20} The improvement in outcomes is attributed

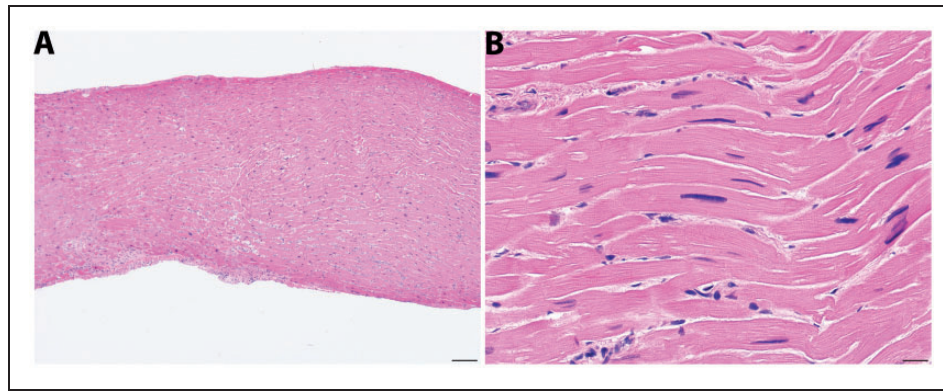


Figure 4. (a) Low power photomicrograph of pathologic specimen revealing myocardium. (b) High power photomicrograph.

to improved rates of recanalization and reperfusion in carefully selected patients who have relatively small infarct cores, large areas of salvageable brain tissue, and favorable ability to rehabilitate. Newer clot retrieval devices achieve recanalization rates of 75–94% in large trials, which is much improved compared with first generation devices.^{16,17,21,22} Endovascular intervention is the treatment of choice in a postoperative patient with large vessel occlusion and a not-yet completed cerebral infarction.^{15,18–20} With EVT, the interventionalist has multiple tools in their armamentarium including aspiration and clot retrieval devices, both of which were utilized in the patient presented, with the stent-retriever successfully removing the embolus and recanalizing the MCA.

To our knowledge, embolization of myocardial fragment as a cause of ischemic stroke has not been described, but, given the nature of the procedure, must be considered in the differential of a patient with an ischemic stroke after myectomy. In our case, myocardium was suspected as the embolic obstruction. The myocardial fragment was not easy to cross with the microguidewire and only after a second careful attempt were we able to negotiate a channel between the embolus and the vessel wall which allowed us to deploy a stent-retriever. The timely intervention with removal of the embolus and recanalization of the MCA allowed our patient to make a full recovery from both her myectomy and her stroke.

Conclusion

This case demonstrates an unusual but potentially treatable etiology of intracranial arterial occlusion that should be considered in a patient with stroke symptoms after septal myectomy. Embolization of a myocardial fragment may be amenable to successful endovascular stroke therapy if recognized in a timely fashion.

Funding

This research received no specific grant from any funding agency in the public, commercial, or not-for-profit sectors.

Conflict of interest

The author(s) declared no potential conflicts of interest with respect to the research, authorship, and/or publication of this article.

References

1. Maron BJ, Maron MS, Wigle ED, et al. The 50-year history, controversy, and clinical implications of left ventricular outflow tract obstruction in hypertrophic cardiomyopathy from idiopathic hypertrophic subaortic stenosis to hypertrophic cardiomyopathy: From idiopathic hypertrophic subaortic stenosis to hypertrophic cardiomyopathy. *J Am Coll Cardiol* 2009; 54: 191–200.
2. Maron BJ, Ommen SR, Semsarian C, et al. Hypertrophic cardiomyopathy: Present and future, with translation into contemporary cardiovascular medicine. *J Am Coll Cardiol* 2014; 64: 83–99.
3. Morrow AG. Hypertrophic subaortic stenosis. Operative methods utilized to relieve left ventricular outflow obstruction. *J Thorac Cardiovasc Surg* 1978; 76: 423–430.
4. Maron BJ, Dearani JA, Ommen SR, et al. Low operative mortality achieved with surgical septal myectomy: Role of dedicated hypertrophic cardiomyopathy centers in the management of dynamic subaortic obstruction. *J Am Coll Cardiol* 2015; 66: 1307–1308.
5. Panaich SS, Badheka AO, Chothani A, et al. Results of ventricular septal myectomy and hypertrophic cardiomyopathy (from Nationwide Inpatient Sample [1998–2010]). *Am J Cardiol* 2014; 114: 1390–1395.
6. Sedehi D, Finocchiaro G, Tibayan Y, et al. Long-term outcomes of septal reduction for obstructive hypertrophic cardiomyopathy. *J Cardiol* 2015; 66: 57–62.
7. Said SM and Schaff HV. Surgical treatment of hypertrophic cardiomyopathy. *Semin Thorac Cardiovasc Surg* 2013; 25: 300–309.
8. Maron BJ, Epstein SE and Morrow AG. Symptomatic status and prognosis of patients after operation for hypertrophic obstructive cardiomyopathy: Efficacy of ventricular septal myotomy and myectomy. *Eur Heart J* 1983; 4 Suppl F: 175–185.
9. Smedira NG, Lytle BW, Lever HM, et al. Current effectiveness and risks of isolated septal myectomy for hypertrophic obstructive cardiomyopathy. *Ann Thorac Surg* 2008; 85: 127–133.
10. Yoshimura S, Sakai N, Okada Y, et al. Efficacy of endovascular treatment for acute cerebral large-vessel

- occlusion: Analysis of nationwide prospective registry. *J Stroke Cerebrovasc Dis* 2014; 23: 1183–1190.
11. Arboix A and Alio J. Acute cardioembolic cerebral infarction: Answers to clinical questions. *Curr Cardiol Rev* 2012; 8: 54–67.
 12. Grisold W, Oberndorfer S and Struhal W. Stroke and cancer: A review. *Acta Neurol Scand* 2009; 119: 1–16.
 13. Pujadas Capmany R, Arboix A, Casanas-Munoz R, et al. Specific cardiac disorders in 402 consecutive patients with ischaemic cardioembolic stroke. *Int J Cardiol* 2004; 95: 129–134.
 14. Birns J, Qureshi S, Chen R, et al. Endovascular stroke therapy. *Eur J Intern Med* 2014; 25: 584–591.
 15. Rai AT, Carpenter JS, Raghuram K, et al. Endovascular therapy yields significantly superior outcomes for large vessel occlusions compared with intravenous thrombolysis: Is it time to randomize? *J Neurointerv Surg* 2013; 5: 430–434.
 16. Berkhemer OA, Fransen PS, Beumer D, et al. A randomized trial of intraarterial treatment for acute ischemic stroke. *N Engl J Med* 2015; 372: 11–20.
 17. Campbell BC, Mitchell PJ, Yan B, et al. A multicenter, randomized, controlled study to investigate EXTending the time for Thrombolysis in Emergency Neurological Deficits with Intra-Arterial therapy (EXTEND-IA). *Int J Stroke* 2014; 9: 126–132.
 18. Goyal M, Demchuk AM, Menon BK, et al. Randomized assessment of rapid endovascular treatment of ischemic stroke. *N Engl J Med* 2015; 372: 1019–1030.
 19. Jovin TG, Chamorro A, Cobo E, et al. Thrombectomy within 8 hours after symptom onset in ischemic stroke. *N Engl J Med* 2015; 372: 2296–2306.
 20. Saver JL, Goyal M, Bonafe A, et al. Solitaire with the Intention for Thrombectomy as Primary Endovascular Treatment for Acute Ischemic Stroke (SWIFT PRIME) trial: Protocol for a randomized, controlled, multicenter study comparing the Solitaire revascularization device with IV tPA with IV tPA alone in acute ischemic stroke. *Int J Stroke* 2015; 10: 439–448.
 21. Smith WS, Sung G, Saver J, et al. Mechanical thrombectomy for acute ischemic stroke: Final results of the Multi MERCI trial. *Stroke* 2008; 39: 1205–1212.
 22. Smith WS, Sung G, Starkman S, et al. Safety and efficacy of mechanical embolectomy in acute ischemic stroke: Results of the MERCI trial. *Stroke* 2005; 36: 1432–1438.