


Accepted Manuscript

Moyamoya disease in a patient with VACTERL association

Christopher S. Hong, B.A., Anthony C. Wang, M.D., Robert H. Bonow, M.D., Isaac J. Abecassis, M.D., Catherine Amlie-Lefond, M.D., Richard G. Ellenbogen, M.D.



PII: S1878-8750(16)00147-9

DOI: [10.1016/j.wneu.2016.01.059](https://doi.org/10.1016/j.wneu.2016.01.059)

Reference: WNEU 3663

To appear in: *World Neurosurgery*

Received Date: 13 December 2015

Revised Date: 13 January 2016

Accepted Date: 14 January 2016

Please cite this article as: Hong CS, Wang AC, Bonow RH, Abecassis IJ, Amlie-Lefond C, Ellenbogen RG, Moyamoya disease in a patient with VACTERL association, *World Neurosurgery* (2016), doi: 10.1016/j.wneu.2016.01.059.

This is a PDF file of an unedited manuscript that has been accepted for publication. As a service to our customers we are providing this early version of the manuscript. The manuscript will undergo copyediting, typesetting, and review of the resulting proof before it is published in its final form. Please note that during the production process errors may be discovered which could affect the content, and all legal disclaimers that apply to the journal pertain.

Moyamoya disease in a patient with VACTERL association

Christopher S. Hong¹, B.A., Anthony C. Wang², M.D., Robert H. Bonow², M.D., Isaac J. Abecassis², M.D., Catherine Amlie-Lefond³, M.D., Richard G. Ellenbogen², M.D.

¹The Ohio State University Wexner Medical Center, College of Medicine, Columbus, OH, 43201

²University of Washington, Department of Neurological Surgery, Seattle Children's Hospital, Seattle, WA, 98105

³University of Washington, Division of Pediatric Neurology, Department of Neurology, Seattle Children's Hospital, Seattle, WA, 98105

Corresponding author

Richard G. Ellenbogen, M.D.

Department of Neurological Surgery, Seattle Children's Hospital

4800 Sand Point Way NE, Seattle, WA 98105

Email: RGE@neurosurgery.washington.edu

Tel: 206-987-2544, Fax: 206-987-3925

Running title: Moyamoya disease in VACTERL association

Keywords: moyamoya, VACTERL, pial synangiosis, indirect bypass

Abstract

Background: VACTERL association is characterized by a group of congenital malformations that tend to occur together. Rarely, concurrent cerebrovascular abnormalities have been reported. In this report, we present the first reported case of moyamoya disease in a patient with VACTERL association.

Case description: The patient presented in the neonatal period with esophageal atresia with distal tracheo-esophageal fistula as well as an imperforate anus. He also had a ventricular septal defect and persistent foramen ovale. At age 11, he developed seizures and was diagnosed with moyamoya disease, for which he underwent bilateral pial synagiosis.

Conclusions: Our report adds moyamoya disease to the spectrum of rare diseases that may occur in the context of VACTERL association. Further studies may reveal whether a common pathophysiology exists between the two conditions. Our patient's congenital heart disease and the association between renovascular and cardiac disease with moyamoya may suggest a systemic vasculopathy. As such, moyamoya should be considered in children with VACTERL association who present with neurological deficits or seizures.

Introduction

VACTERL association is a nonrandom association of birth defects that affects multiple median and para-median structures. The term VACTERL is an acronym with each letter representing the first letter of one of the more common findings seen in affected children: (V) = (costo-) vertebral anomalies, (A) = anal atresia, (C) = cardiac malformations, (TE) = tracheo-esophageal abnormalities including atresia, stenosis, and fistula, (R) = renal and radial anomalies including single umbilical artery, and (L) = limb abnormalities.¹ To date, the etiology of this condition remains unclear. In some patients with VACTERL association, anomalies beyond those described in the acronym may occur. However, cerebral arteriopathies like moyamoya have not been previously described. In this report, we describe a case of moyamoya disease occurring in a patient with VACTERL association.

Case Description

An 11 year-old boy with a history of VACTERL association diagnosed at birth and new-onset seizures that were treated successfully with levetiracetam was found to have moyamoya on brain imaging. Magnetic resonance imaging (MRI) showed bilateral fronto-parietal T2-weighted and fluid-attenuated inversion recovery (FLAIR) signal abnormalities indicative of the leptomenigeal “ivy sign” (Fig. 1A).² Magnetic resonance angiography (MRA) further revealed absent flow in the cavernous internal carotid arteries (ICA) bilaterally with reconstitution of flow in the bilateral terminal ICAs, middle cerebral arteries (MCAs), and anterior cerebral arteries (ACAs) (Fig. 1B). A catheter angiogram showed complete steno-occlusion of

the bilateral ICAs proximal to the carotid siphons with reconstitution of the supraclinoid ICAs through collateralization from the superficial temporal arteries (STA) as well as internal maxillary arteries, and ethmoidal artery branches, and posterior cerebral arteries on the ipsilateral side (Fig. 1C). Angiography of the posterior circulation also demonstrated abundant collaterals extending from the posterior cerebral artery distribution to the MCA distribution.

Thrombophilia screening was negative, and he was started on low-dose daily aspirin therapy. His past medical history was significant for the diagnosis of VACTERL association, including esophageal atresia with a distal tracheo-esophageal fistula, imperforate anus, ventricular septal defect and persistent foramen ovale. He also had a 2-vessel umbilical cord. Renal ultrasound and renal function laboratory values were normal at 4 days of life with no evidence of hypertension.

An indirect revascularization of his left MCA circulation was first performed, using our previously described variation of the pial synangiosis technique.³ In this procedure, the sulcal pia-arachnoid is opened and dissected sharply to expose a length of terminal MCA branches. The STA is laid into the exposed sulci, and the dural leaves, incised in a cruciate fashion, are inverted onto the pial surface beneath the calvaria. The peri-adventitial cuff of the artery is sutured to dura at the superior and inferior poles to hold the vessel in place. A postoperative MRI and MRA, obtained three months after surgery, demonstrated the interval development of collateral flow between the left STA and M3 branches of the ipsilateral MCA at the site of pial synangiosis (Fig. 2A). Six months after his first surgery, a right-sided pial synangiosis was performed with an uncomplicated post-operative course (Fig. 2B).

In the follow-up period of 11 months after his first surgery, he has had no further ischemic events and having been seizure-free, has been weaned from levetiracetam.

Discussion

Moyamoya was first termed by Suzuki and Takaku as a condition of stenosis-occlusion of the terminal ICAs, surrounded by abnormal net-like blood vessel formation.⁴ The appearance of this vasculature was likened to a puff of smoke, loosely translated in Japanese as moyamoya. Subsequently, it has been shown that stenosis of the terminal ICAs and/or proximal ACAs and MCAs leads to collateralization of leptomeningeal vessels at the base of the brain.⁵ Moyamoya is referred to as either a syndrome or a disease, in which the former is secondary to factors like radiation therapy, atherosclerosis, sickle cell disease, neurofibromatosis type 1, and Down syndrome, while the latter occurs as an idiopathic condition likely arising from polygenic factors.⁵ The incidence of moyamoya is bi-modal, with peaks in the first and fourth decades of life. Children usually present with ischemic symptoms, while adults show a greater preponderance of intracerebral hemorrhage.

The only effective treatment is surgical revascularization, through either direct arterial bypass, or indirect bypass techniques including variations of synangiosis between the branches of the external carotid artery and pial or dural layers.⁶ In the case of our patient, a variation of pial synangiosis was performed. In the experience of the senior author, this approach is effective in developing collaterals between the external carotid artery and MCA circulations, and minimizes adverse risk to the cortex associated with conventional pial synangiosis techniques.³

VACTERL association, also known as VATER or VATERL association,⁷ is a group of congenital malformations occurring together by statistically non-random chance in one out of every 10,000 to 40,000 live births.⁸ Although strict diagnostic criteria have not been established, the presence of three or more of the findings present in the acronym is usually sufficient to make the diagnosis. Treatment is primarily targeted at surgical correction of major life-threatening deformities (i.e. tracheo-esophageal fistula, imperforate anus, and severe cardiac defects). While certain genetic alterations have been found in select cases of affected patients, the exact etiology underlying VACTERL association remains unclear, in part due to the variable phenotypes of patients and sporadic nature of the disease. Further adding to the clinical heterogeneity of the condition, additional non-VACTERL anomalies are relatively prevalent in affected individuals, including single umbilical artery, genital defects, and respiratory tract abnormalities.⁹ Rarely, vascular anomalies have been reported such as aberrant subclavian artery causing partial steal phenomenon, fibromuscular dysplasia, agenesis of the ICA, and cavernous malformations.¹⁰⁻¹⁴

To our knowledge, this is the first report of moyamoya disease in an individual with VACTERL association. Previous studies have demonstrated that cerebral arteriopathy in pediatric patients is often accompanied by renovascular disease¹⁵ and that a subset of moyamoya patients have concurrent renal artery stenosis.^{16,17} However, our patient had a normal renal ultrasound at birth, and laboratory evaluation has demonstrated adequate renal function thus far. It is unclear why a progressive disorder like moyamoya may occur as part of a

developmental sequence like VACTERL association. Both moyamoya and VACTERL association have been associated with congenital heart disease (CHD),¹⁸ including ventricular septal defects, which was observed in our patient, as well as other syndromes with congenital heart disease such as trisomy 21 (Down syndrome) and Alagille syndrome, raising the possibility that moyamoya-like pathology may occur as part of a multi-systemic vasculopathy in VACTERL association.^{12,19-21} It is interesting to postulate whether our patient's moyamoya was congenital, and we will continue to follow him for progression of moyamoya disease after treatment.

In summary, this report is the first to document a case of moyamoya in a patient with VACTERL association. Whether a common pathophysiologic mechanism exists between these two conditions is unclear, but mounting reports of vasculopathy in VACTERL association point to a potential link. Surprisingly, an absence of renal anomalies or renal dysfunction in our patient suggests that his moyamoya disease developed independently of any VACTERL-related renal pathology. However, there is a strong association between renovascular and cardiac disease with moyamoya. Our patient's CHD points to a broader systemic vasculopathy, which is likely to have incited development of his moyamoya.

Because of the inherent frequency with which renal, cardiac, and vascular abnormalities are seen in VACTERL patients, moyamoya should be considered whenever a patient with VACTERL presents with an acute neurologic deficit, even if transient, or new onset seizures. Neuroimaging, including brain MRI and MRA, can diagnose parenchymal abnormalities as well as moyamoya arteriopathy.^{22,23} As surgical revascularization is the most effective treatment for stroke prevention in

moyamoya,⁵ early detection has the potential to significantly benefit long-term function in such patients.

Acknowledgements

The authors have no conflicts of interest or sources of funding to disclose.

References

1. Solomon BD, Baker LA, Bear KA, et al. An approach to the identification of anomalies and etiologies in neonates with identified or suspected VACTERL (vertebral defects, anal atresia, tracheo-esophageal fistula with esophageal atresia, cardiac anomalies, renal anomalies, and limb anomalies) association. *The Journal of pediatrics* 2014;164:451-7 e1.
2. Maeda M, Tsuchida C. "Ivy sign" on fluid-attenuated inversion-recovery images in childhood moyamoya disease. *AJNR American journal of neuroradiology* 1999;20:1836-8.
3. Ellenbogen RGS, R. M. Treatment of moyamoya syndrome in children with pial synangiosis. In: Goodrich JT, ed. *Neurosurgical Operative Atlas Pediatric Neurosurgery*. 2 ed. New York: Thieme; 2008:171 - 6.
4. Suzuki J, Takaku A. Cerebrovascular "moyamoya" disease. Disease showing abnormal net-like vessels in base of brain. *Archives of neurology* 1969;20:288-99.
5. Scott RM, Smith ER. Moyamoya disease and moyamoya syndrome. *The New England journal of medicine* 2009;360:1226-37.
6. Sekhar LN, Natarajan SK, Ellenbogen RG, Ghodke B. Cerebral revascularization for ischemia, aneurysms, and cranial base tumors. *Neurosurgery* 2008;62:1373-408; discussion 408-10.
7. Temtamy SA, Miller JD. Extending the scope of the VATER association: definition of the VATER syndrome. *The Journal of pediatrics* 1974;85:345-9.
8. Czeizel A, Ludanyi I. An aetiological study of the VACTERL-association. *European journal of pediatrics* 1985;144:331-7.
9. de Jong EM, Felix JF, Deurloo JA, et al. Non-VACTERL-type anomalies are frequent in patients with esophageal atresia/tracheo-esophageal fistula and full or partial VACTERL association. *Birth defects research Part A, Clinical and molecular teratology* 2008;82:92-7.
10. Alomari AK, Alomari AI. A rare association of fibromuscular dysplasia, renal agenesis, renal arteriovenous fistulae, and vertebral anomalies: expanding the V in VACTERL association. *American journal of medical genetics Part A* 2012;158A:2863-5.
11. Budincevic H, Starcevic K, Bielen I, Demarin V. An aberrant subclavian artery exhibiting the partial steal phenomenon in a patient with VACTERL association. *Internal medicine* 2014;53:1859-61.

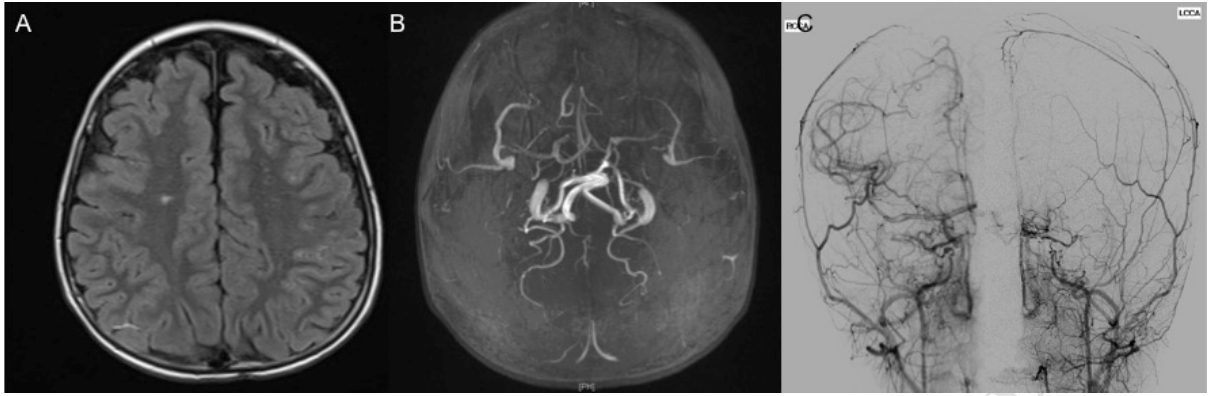
12. Fitzgerald RT, Zuccoli G. Agenesis of the internal carotid artery: associated malformations including a high rate of aortic and cardiac malformations. *Pediatric radiology* 2012;42:1333-8.
13. Raffel C, Litofsky S, McComb JG. Central nervous system malformations and the VATER association. *Pediatric neurosurgery* 1990;16:170-3.
14. Wasserstein ML, Hedges DW. Neurovascular anomaly in a patient with VATER association: coincident or syndromal? *American journal of medical genetics* 1995;58:383.
15. Willsher A, Roebuck DJ, Ng J, Ganesan V. How commonly do children with complex cerebral arteriopathy have renovascular disease? *Developmental medicine and child neurology* 2013;55:335-40.
16. Togao O, Mihara F, Yoshiura T, et al. Prevalence of stenocclusive lesions in the renal and abdominal arteries in moyamoya disease. *AJR American journal of roentgenology* 2004;183:119-22.
17. Yamada I, Himeno Y, Matsushima Y, Shibuya H. Renal artery lesions in patients with moyamoya disease: angiographic findings. *Stroke; a journal of cerebral circulation* 2000;31:733-7.
18. Lutterman J, Scott M, Nass R, Geva T. Moyamoya syndrome associated with congenital heart disease. *Pediatrics* 1998;101:57-60.
19. Baird LC, Smith ER, Ichord R, et al. Moyamoya syndrome associated with Alagille syndrome: outcome after surgical revascularization. *The Journal of pediatrics* 2015;166:470-3.
20. See AP, Ropper AE, Underberg DL, Robertson RL, Scott RM, Smith ER. Down syndrome and moyamoya: clinical presentation and surgical management. *Journal of neurosurgery Pediatrics* 2015;16:58-63.
21. Solomon BD, Bous SM, Bianconi S, Pineda-Alvarez DE. Consideration of VACTERL association in patients with trisomy 21. *Clinical dysmorphology* 2010;19:209-11.
22. Houkin K, Aoki T, Takahashi A, Abe H. Diagnosis of moyamoya disease with magnetic resonance angiography. *Stroke; a journal of cerebral circulation* 1994;25:2159-64.
23. Sawada T, Yamamoto A, Miki Y, et al. Diagnosis of moyamoya disease using 3-T MRI and MRA: value of cisternal moyamoya vessels. *Neuroradiology* 2012;54:1089-97.

Figure Legends

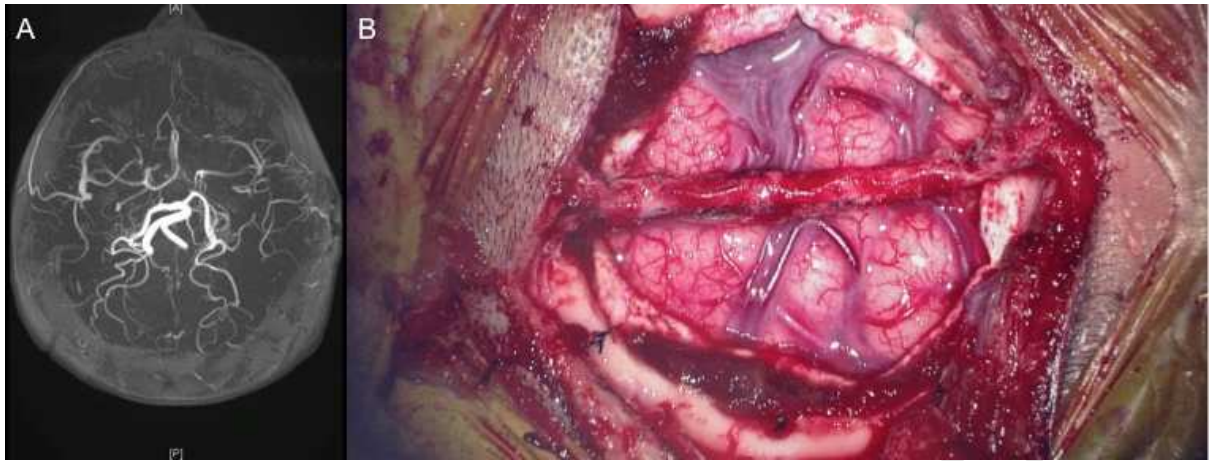Figure 1. (A) Representative axial slice from a T1-weighted FLAIR MRI demonstrating signal abnormalities along the bilateral fronto-parietal cortical leptomeningeal architecture and centrum semiovale suggestive of the leptomeningeal “ivy sign”, as well as signal abnormality in the right and left fronto-

parietal convexity watershed regions suggestive of remote ischemic injury. (B) Reconstructed MRA demonstrating bilateral termination of the ICAs proximal to the carotid siphons. (C) Representative antero-posterior views of common carotid artery injections on the left (left panel) and right (right panel) sides showing bilateral termination of the ICAs proximal to the carotid siphons. There is reconstitution of both supraclinoid ICAs through central and cortical external carotid collaterals.

Figure 2. (A) Reconstructed MRA obtained three months after left pial synangiosis shows notable improvement in bilateral ICA, ACA, and terminal MCA vascular supply, particularly on the left side. (B) A representative intra-operative microscopic view is shown during pial synangiosis on the right side. The right STA has been isolated, the cortical arachnoid layer overlying both frontal and temporal M4 branches and the Sylvian fissure has been dissected open, and the peri-adventitial cuff of the artery has been sutured to the overlying dura at both ends of the operative field.



ACCEPTED MANUSCRIPT



ACCEPTED MANUSCRIPT

Highlights

- This is the first case of moyamoya disease in a patient with VACTERL syndrome
- A common systemic vasculopathy may underlie the pathophysiology of both conditions
- MR angiography may be considered to screen for moyamoya pathology in VACTERL syndrome

Abbreviations

VACTERL: vertebral anomalies, anal atresia, cardiac malformations, tracheo-esophageal abnormalities, renal and radial anomalies, limb abnormalities

MRI: magnetic resonance imaging

MRA: magnetic resonance angiography

ICA: internal carotid artery

MCA: middle cerebral artery

ACA: anterior cerebral artery

STA: superficial temporal artery

CHD: congenital heart disease