

Spontaneous regression and complete disappearance of the vein of Galen aneurysmal malformation

Ramin Mahmoodi¹ · Zohreh Habibi² · Vahid Heidari² · Farideh Nejat²

Received: 5 January 2016 / Accepted: 1 February 2016 / Published online: 11 February 2016
© Springer-Verlag Berlin Heidelberg 2016

Abstract

Introduction Thrombosis is frequently observed in Galen malformation, but propagation of thrombosis resulting in the disappearance of the aneurysmal malformation is a very rare clinical condition.

Case report A rare case of spontaneous regression and disappearance of the vein of Galen aneurysmal malformation (VoGAM) in a pediatric patient with repeated generalized seizure, increased head circumference, and congestive heart failure is recorded. The course of regression from infancy to 8 years of age has been depicted. Radiological studies initially demonstrated VoGAM complicated by an intra-cerebral hemorrhage and hydrocephalus, which later underwent spontaneous regression. Long-term clinical and radiological follow-up is presented.

Discussion Different conditions including hemodynamic alteration, compression of adjacent hematoma, and narrowing of related vascular structures have been described to cause thrombosis of VoGAM. The relevant literature to address possible mechanism is reviewed.

Introduction

The vein of Galen aneurysmal malformations (VoGAMs) are rare intracranial congenital vascular lesions. They are commonly diagnosed during neonatal period or early childhood, when manifest as congestive heart failure and intracranial hypertension, respectively [1, 2]. The patients harboring VoGAM may experience occlusion of the malformation following thrombosis of the vascular lesion. Although thrombosis of the Galen malformation is a common clinical condition and has been frequently reported in the literatures [3–6], complete regression resulting in disappearance of the aneurysmal malformation is a quite rare clinical condition, and to our knowledge, only four cases of spontaneous disappearance were reported previously [7–10]. Here, we present an infant harboring vein of Galen malformation, who experienced spontaneous total regression and disappearance of the vascular pathology confirmed by long-term clinical and neuro-radiological follow-up. Review of the relevant literature has been performed to address the possible mechanisms.

Keywords Galen · Aneurysm · Regression

Historical background

It has been recognized that the vein of Galen malformation, as an arteriovenous connection between primitive choroidal vessels and the median prosencephalic vein of Markowski, develops between the 6th and 11th weeks of gestation [11]. Different classification schemes have been proposed for the vein of Galen malformation. According to the Raybaud and Lasjaunias classification, three types of aneurysmal malformation could be described: (a) choroidal, (b) mural, and (c) vein of Galen dilatation following increased blood inflow due to an arteriovenous malformation. The choroidal type is more severe and usually causes multiple organs failure especially high output

✉ Farideh Nejat
nejat@sina.tums.ac.ir

¹ Brain and Spinal Cord Injury Research Center, Neuroscience Institute, Tehran University of Medical Science, Tehran, Iran

² Department of Neurosurgery, Children's Hospital Medical Center, Tehran University of Medical Science, Tehran, Iran

heart failure in the neonates and characterized by multiple fistulas at the anterior and terminal segment of the median prosencephalic vein. The arterial feeders come from anterior and posterior choroidal arteries and some additional feeders from quadrigeminal and thalamoperforating arteries. The mural type is often slow flow and asymptomatic lesion with the fistula at the lateral-inferior wall of the median prosencephalic vein. The arterial supply is usually from unilateral or bilateral quadrigeminal and/or posterior choroidal arteries. Galen aneurysmal dilatation is a true vein of Galen that drains a dural arteriovenous fistula or a brain arteriovenous malformation accompanied by venous drainage of normal brain parenchyma. It is against to the persistent embryonic vein in the true VoGAM that does not drain the normal brain and drains only the malformation [11–14].

In contrast to the superficial cerebral venous system and venous sinuses, thrombosis of the deep venous system is a rare clinical condition. In the territory of the deep venous drainage, a relatively higher tendency of vein of Galen to thrombose formation has been mentioned [5]. Searching available current literature to catch the first reported cases of thrombosed vein of Galen malformation and excision of the thrombosed aneurysm results in finding two separate reports in 1950 by Davis and 1968 by Weir, respectively [15, 16]. Although several cases of spontaneous thrombosis or successful surgical treatment of thrombosed aneurysm of Galen have been thereafter published, spontaneous disappearance and regression of the malformation is a rare clinical condition.

Clinical presentation

Most symptoms of the VoGAMs are related to the magnitude of the intracranial shunt and differ considerably in neonate from those seen in older ages [17]. In neonates, cardiac decompensation often develops due to high flow systemic shunt. Increased head circumference secondary to venous hypertension and subsequent hydrocephalus is commonly observed in infancy. Obvious signs of intracranial hypertension, intra-cerebral hemorrhage, seizure, and infarcts related to the retrograde venous engorgement or diversion of the blood flow may occur [13, 18].

Since thrombosis of the Galen malformation is an uncommon occurrence, its clinical presentation and symptoms have not been discussed in detailed. Generally, spontaneous thrombosis of the VoGAM has variable clinical course and symptoms from asymptomatic to death [9]. It may be accompanied by seizure, alteration of consciousness, and intracranial hemorrhage [19].

Diagnosis

The diagnosis of the VoGAM is usually obtained in infancy or early childhood, comprising 30 % of the pediatric intracranial vascular lesions [20]. Angiography provides useful detailed

information about the pathology and has become the gold standard diagnostic method. Prenatal detection of the VoGAMs has been facilitated by pulsed and color Doppler ultrasonography in the 2nd or 3rd trimester of pregnancy. The malformation appears in prenatal ultrasound study as a midline posterior third ventricle echogenic mass, associating with dilated cerebral venous sinuses, dilated neck vessels, and cardiomegaly [18, 21, 22]. Regarding the age of developing thrombosis, the detection of a thrombosed VoGAM in prenatal sonography and MRI, later confirmed by autopsy, has been reported as early as 21st weeks of gestation [18].

In case of thrombosed VoGAM, angiography fails to reveal the lesion and demonstrates the absence of flow. The lesion appears in CT scan as a hyperdense lesion with occasionally calcified capsule, and MRI contributes the characteristics of extracellular methemoglobin in the central part and hemosiderin in the peripheral part of lesion [23]. Considering the anatomical location of the lesion and presence of thrombosis or calcification, VoGAMs can mimic radiologic and clinical features of pineal tumors, arachnoid cyst, cavum vergae, or porencephalic cyst in neuroimaging studies [24, 25].

Management

Although the diagnosis of the VoGAM is feasible as early as the prenatal period by utilizing various modalities, optimal management strategy of the patients is still controversial and complex. Since the initial management in less symptomatic patients and low flow variants is a conservative approach through medical management and treating hydrocephalus, several reports exist on spontaneous thrombosis of the vascular pathology in the course of observation. The reported cases of spontaneous thrombosis were usually without significant morbidities, demanding only conservative management. Although surgical treatment of VoGAM has generally poor outcome, limited reports exist on successful operative intervention to manage the thrombosed VoGAM with satisfactory outcome [16, 26–29].

Prognosis and outcome

Although the mechanisms involved in spontaneous thrombosis are not well defined, it is believed that thrombosis occurs as a result of low flow shunt and insufficient venous drainage [29]. Since the shunt is low flow, the spontaneous occlusion of the vascular lesion does not lead to unfavorable clinical conditions, and the thrombosis of VoGAM usually has been described with an excellent or good prognosis in the published articles [30, 31].

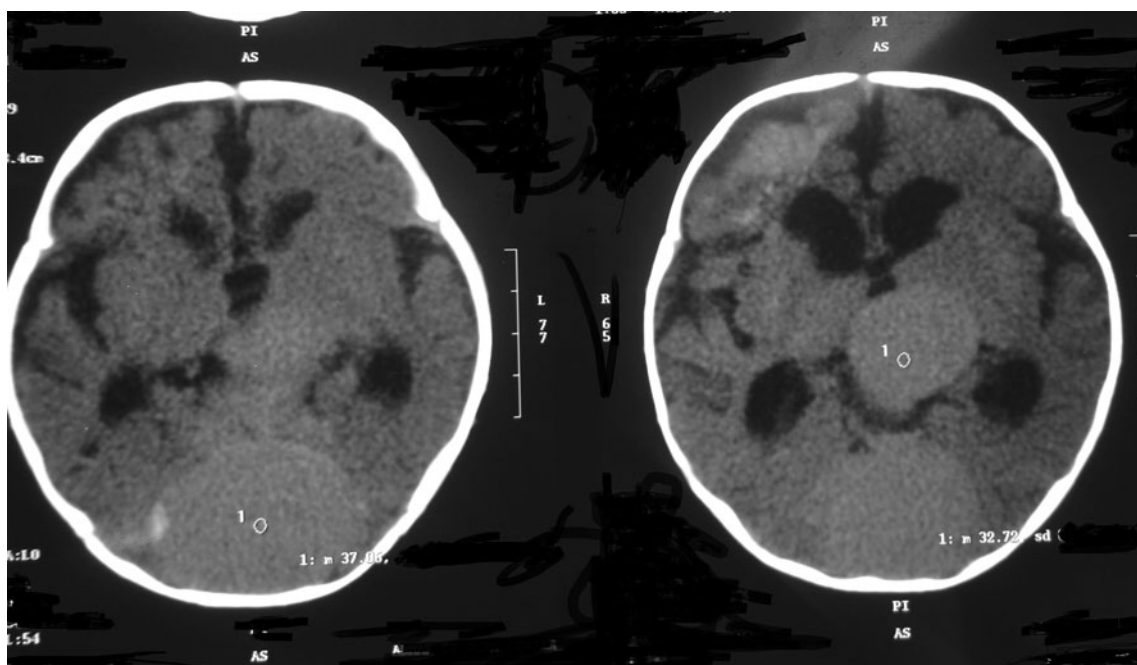


Fig. 1 First brain computed tomography scan shows three ventricular hydrocephalus and severely dilated vein of Galen and torcula herophili

Case description

The patient was a 4-month-old boy admitted to the hospital because of a suddenly decreased level of consciousness and repeated generalized seizures. The child was a product of an uneventful pregnancy and delivery from non-consanguineous parents. The last prenatal ultrasound exam was performed at 20th week of gestational age which confirmed no obvious fetal abnormality.

The head circumference at admission was 4 cm larger than expected value for the age. Anterior fontanel was wide and tense accompanied by right side eye deviation. Clinical evaluations confirmed congestive heart failure with respiratory

distress during feeding. Laboratory tests confirmed normal coagulation status, normal platelet count, and no bleeding diathesis.

The first brain computed tomography (CT) scan revealed right occipital intra-cerebral hemorrhage, brain atrophy, three-ventricular hydrocephalus, and two round isodense midline masses, 3.5 and 5.5 cm in diameter compatible with severely dilated vein of Galen and torcula herophili, respectively (Fig. 1). Brain magnetic resonance imaging (MRI) and magnetic resonance angiography (MRA) confirmed vein of Galen aneurysmal malformation accompanied by thrombosis formation and dilated torcula (Fig. 2). CT angiography confirmed a mural type

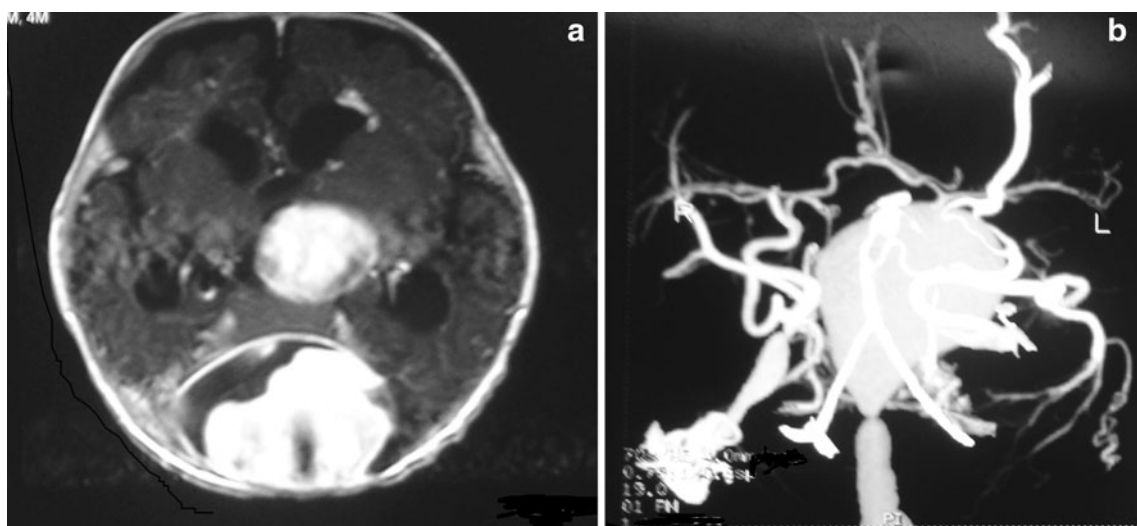


Fig. 2 Brain magnetic resonance imaging (a) and magnetic resonance angiography (b) confirms vein of Galen aneurysmal malformation accompanied by thrombosis formation and dilated torcula

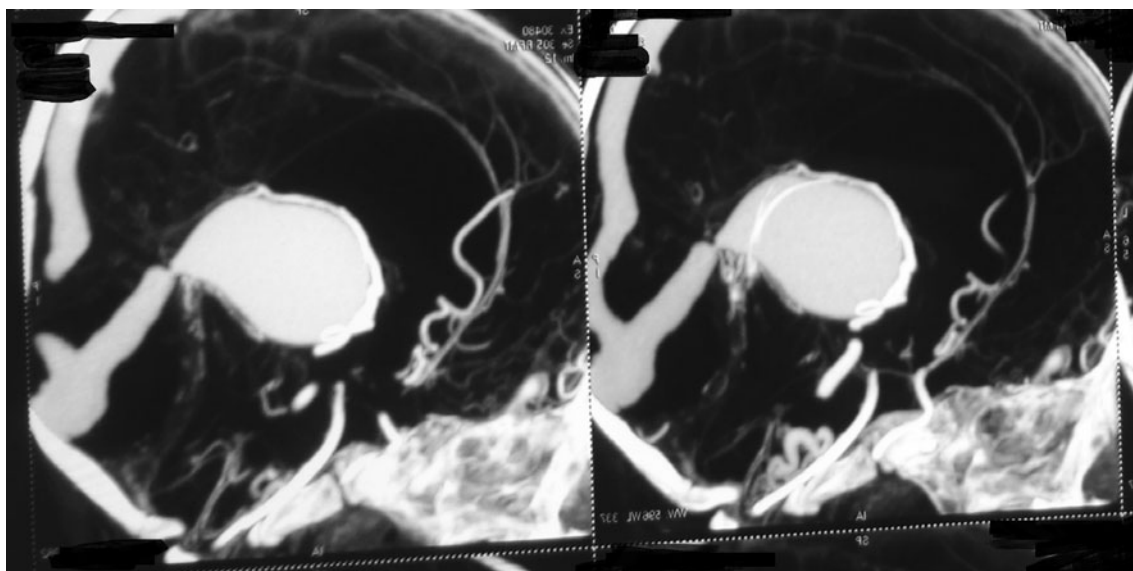


Fig. 3 CT angiography shows Galen aneurysm with severely dilated torcula, straight sinus, which the straight sinus contains a short narrowing segment distal to the Galen

VoGAM with severely dilated torcula, straight and transverse sinus, with the straight sinus being associated with a short narrowing segment distal to Galen (Fig. 3).

Congestive heart failure was managed with diuretics and digoxin. The neurological problems gradually improved over 1 week. The patient was scheduled for digital subtraction angiography, but the parents refused to perform the test and discharged the child with their permission.

The seizure was successfully managed with phenobarbital, but congestive heart failure improved during the next few months without any medication. As the child was stable from neurological and cardiorespiratory aspects, the parents did not seek medical care until he experienced a new seizure attack 3 years later. New brain CT scan revealed a porencephalic cyst at the place of previous intra-cerebral hemorrhage with

calcified thrombosis inside the torcula and Galen which was corresponded to the previous severely dilated torcula and aneurysmal malformation of Galen. Later in follow-up at the age of seven, new brain CT with CT angiography was performed that confirmed complete regression and disappearance of the aneurysmal dilatation of Galen (Fig. 4).

Currently, this healthy 8-year-old child manifests no neurological signs or symptoms except for slight school performance problem. His ventriculomegaly is not associated with headache or papilledema and has been considered as arrested hydrocephalus which was left untreated because of being asymptomatic. Digital subtraction angiography confirms the regression of the aneurysmal lesion and fails to reveal any other vascular abnormalities (Fig. 5).

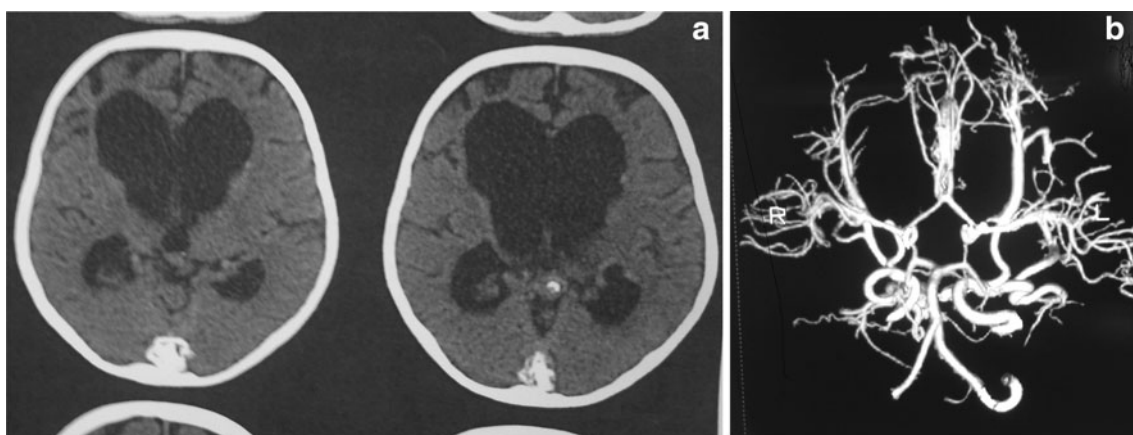


Fig. 4 **a** Brain CT scan after 3 years confirms calcified thrombosis inside the torcula and Galen which corresponds to the previous severely dilated torcula and aneurysmal malformation of Galen. **b** CT angiography reveals complete regression and disappearance of the aneurysmal dilatation of Galen

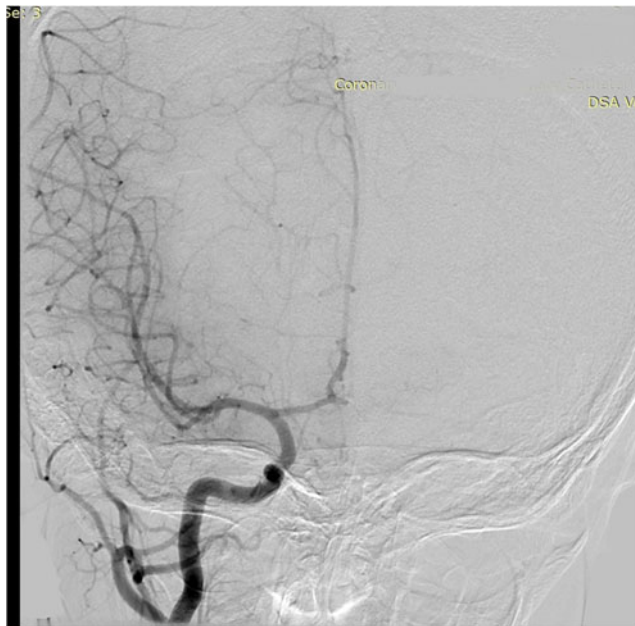

Fig. 5 Digital angiography of right carotid shows normal anteroposterior view of angiogram without any abnormality

Conclusion

Spontaneous thrombosis of an intracranial vascular lesion is a known phenomenon and has been frequently described in arteriovenous malformations, arteriovenous fistula, and aneurysms. The formation and regression of the “flow-related” aneurysm, which is well documented, highlights the role of alteration of hemodynamic in thrombosis and regression of vascular lesions. Although the exact mechanism and clinical conditions resulting in thrombosis of the VoGAM are not clearly understood, it could be postulated that like other vascular lesions, alteration in hemodynamic status may play an important role in developing thrombosis. The possible mechanism which could alter the hemodynamic condition in the VoGAM could be assumed as compression or mass effect caused by the adjacent hematoma or intraaneurysmal clot, posthemorrhagic edema, regressive arteriosclerosis changes in the feeding vessel walls, vascular spasm, and gliosis by fragmentary micro-bleeding [2, 32].

In addition to the abovementioned mechanisms as the possible causes of the thrombosis, the unique shape of straight sinus of our patient could result in thrombosis of the lesion. The narrowing of straight sinus distal to Galen aneurysm may facilitate the thrombosis formation inside the dilated Galen, and thrombosis could propagate distal to narrow part of the sinus. Progressive blood flow stagnation distal to the narrowed part of the sinus caused thrombosis discrete the lesion and induced size decrement of venous sinus system. Thrombosis and aneurysm resorption led to recovery of cardiac problems too.

After all the abovementioned hypotheses, the exact mechanism of complete regression and disappearance of the lesion is still unknown. To describe the exact mechanism of such intralesional thrombosis, a bioengineered modeling of hemodynamic changes inside the VoGAM and associated sinuses, and venous system can be of help.

References

1. Jones BV, Ball WS, Tomsick TA, Millard J, Crone KR (2002) Vein of Galen aneurysmal malformation: diagnosis and treatment of 13 children with extended clinical follow-up. *AJNR American Journal of Neuroradiology* 23:1717–1724
2. Hoang S, Choudhri O, Edwards M, Guzman R (2009) Vein of Galen malformation. *Neurosurg Focus* 27:E8
3. Olin MS, Eltomey AA, Dunsmore RH, Roberts MP (1982) Thrombosed vein of Galen aneurysm. *Neurosurgery* 10:258–262
4. Whitaker JB, Latack JT, Venes JL (1987) Spontaneous thrombosis of a vein of Galen aneurysm. *AJNR American Journal of Neuroradiology* 8:1134–1136
5. Beltramello A, Perini S, Mazza C (1991) Spontaneously healed vein of Galen aneurysms. Clinical radiological features. *Child's Nervous System: ChNS: Official Journal of the International Society For Pediatric Neurosurgery* 7:129–134
6. Shah QA, Qureshi AI (2011) Spontaneous thrombosis of a large vein of galen malformation. *Journal of Neuroimaging: Official Journal of the American Society Of Neuroimaging* 21:87–88
7. Kuroki K, Uozumi T, Arita K, Takechi A, Matsuura R, Fujidaka M (1995) Spontaneous disappearance of an aneurysmal malformation of the vein of Galen. *Neuroradiology* 37:244–246
8. Tawk RG, Mohasseb G, Charbel FT, Debrun GM (2002) Spontaneous disappearance of vein of galen malformation and posterior fossa venous pouch. *Acta Neurochir* 144:1225–1231
9. Mofstakhar P, Danielpour M, Maya M, Alexander MJ (2009) Spontaneous thrombosis of neonatal vein of Galen malformation. *Neurosurg Focus* 27:E12
10. Kumar A, Krishna G, Singh PK, Garg A, Sharma BS (2015) Spontaneously disappearing pineal region mass: a rare manifestation of vein of galen malformation. *Indian J Pediatr* 82:201–202
11. Raybaud CA, Strother CM, Hald JK (1989) Aneurysms of the vein of Galen: embryonic considerations and anatomical features relating to the pathogenesis of the malformation. *Neuroradiology* 31:109–128
12. Litvak J, Yahr MD, Ransohoff J (1960) Aneurysms of the great vein of Galen and midline cerebral arteriovenous anomalies. *J Neurosurg* 17:945–954
13. Lasjaunias P, Ter Brugge K, Lopez Ibor L, Chiu M, Flodmark O, Chuang S, Goasguen J (1987) The role of dural anomalies in vein of Galen aneurysms: report of six cases and review of the literature. *AJNR American Journal of Neuroradiology* 8:185–192
14. Lasjaunias P, Garcia-Monaco R, Rodesch G, Ter Brugge K, Zerah M, Tardieu M, de Victor D (1991) Vein of Galen malformation. Endovascular management of 43 cases. *Childs Nerv Syst* 7(7):360–367
15. Davis PB (1950) Thrombosis of the internal cerebral veins of Galen; report of two cases involving adults. *The Journal of the American Osteopathic Association* 50:21–22
16. Weir BK, Allen PB, Miller JD (1968) Excision of thrombosed vein of Galen aneurysm in an infant. *Case Report Journal of Neurosurgery* 29:619–622

17. Bhattacharya JJ, Thammaroj J (2003) Vein of galen malformations. *Journal of neurology, neurosurgery, and psychiatry* 74 Suppl 1: i42–44
18. Vijayaraghavan SB, Vijay S, Kala MR, Neha D (2006) Prenatal diagnosis of thrombosed aneurysm of vein of Galen. *Ultrasound in Obstetrics & Gynecology: the Official Journal of the International Society Of Ultrasound in Obstetrics and Gynecology* 27:81–83
19. Marques RM, Lobao CA, Sasaki VS, Aguiar LR (2006) Vein of Galen aneurysm in an adult: case report. *Arq Neuropsiquiatr* 64: 862–864
20. Recinos PF, Rahmathulla G, Pearl M, Recinos VR, Jallo GI, Gailloud P, Ahn ES (2012) Vein of Galen malformations: epidemiology, clinical presentations, management. *Neurosurg Clin N Am* 23:165–177
21. Paternoster DM, Manganelli F, Moroder W, Nicolini U (2003) Prenatal diagnosis of vein of Galen aneurysmal malformations. *Fetal Diagn Ther* 18:408–411
22. Busing K, Kilian K, Schaible T, Neff W (2008) Prenatal magnetic resonance imaging of vein of Galen aneurysm associated with congestive heart failure. *Pediatrics International: Official Journal of the Japan Pediatric Society* 50:818–821
23. Abrao GP, Barbosa LA, Sa AT Jr, Caldas JG (2010) Spontaneous thrombosis of a malformation of the vein of Galen. *Arq Neuropsiquiatr* 68:648–650
24. Ahmad M, Mir S, Wahab S, Rizvi I (2012) Vein of Galen malformation. *BMJ Case Reports* 2012. doi:10.1136/bcr-2012-006822
25. Gokhale S, Laskowitz DT (2013) Teaching neuroimages: vein of Galen aneurysm mimicking pineal mass in a young adult. *Neurology* 80:e240
26. Lazar ML (1974) Vein of Galen aneurysm: successful excision of a completely thrombosed aneurysm in an infant. *Surg Neurol* 2:22–24
27. Di Rocco C, Iannelli A, Puca A, Cj C (1983) Spontaneous thrombosis of an aneurysm of the great vein of Galen. *Eur Neurol* 22: 293–299
28. Di Rocco C (1991) Comment on spontaneous healed vein of Galen aneurysm. *Child's Nerv Syst* 7:359
29. Konovalov AN, Pitskhelauri DI, Arutiounov NV (2002) Surgical treatment of the thrombosed vein of galen aneurysm. *Acta Neurochir* 144:909–915 discussion 915
30. Nikas DC, Proctor MR, Scott RM (1999) Spontaneous thrombosis of vein of Galen aneurysmal malformation. *Pediatr Neurosurg* 31: 33–39
31. Hurst RW, Kagetsu NJ, Berenstein A (1992) Angiographic findings in two cases of aneurysmal malformation of vein of Galen prior to spontaneous thrombosis: therapeutic implications. *AJNR American Journal of Neuroradiology* 13:1446–1450
32. Yoshimoto T, Kashiwaba T, Houkin K, Abe H (1996) Spontaneous disappearance of arteriovenous malformation during staged treatment of multiple cerebral arteriovenous malformations—case report. *Neurol Med Chir* 36:812–814