

Neurocase

The Neural Basis of Cognition

ISSN: 1355-4794 (Print) 1465-3656 (Online) Journal homepage: <http://www.tandfonline.com/loi/nncs20>

Potential relationship of self-injurious behavior to right temporo-parietal lesions

Shaina Borah, Brice McConnell, Richard Hughes & Benzi Kluger

To cite this article: Shaina Borah, Brice McConnell, Richard Hughes & Benzi Kluger (2016): Potential relationship of self-injurious behavior to right temporo-parietal lesions, *Neurocase*, DOI: [10.1080/13554794.2016.1147586](https://doi.org/10.1080/13554794.2016.1147586)

To link to this article: <http://dx.doi.org/10.1080/13554794.2016.1147586>



Published online: 16 Feb 2016.



Submit your article to this journal [↗](#)



Article views: 11



View related articles [↗](#)



View Crossmark data [↗](#)

REPORT

Potential relationship of self-injurious behavior to right temporo-parietal lesions

Shaina Borah^a, Brice McConnell^a, Richard Hughes^{a,b} and Benzi Kluger^a

^aDepartment of Neurology, University of Colorado Denver, Aurora, CO, USA; ^bDivision of Neurology, Denver Health Medical Center, Denver, CO, USA

ABSTRACT

Self-injurious behavior (SIB) is associated with several neurologic and psychiatric syndromes but rarely with focal lesions. Two patients with lesions of the right temporo-parietal junction presented to psychiatric inpatient services with SIB in the absence of notable neurologic deficits or suicidal ideation. Right temporo-parietal lesions may be associated with disturbances of agency and body ownership, both of which may facilitate SIB. Misoplegia, or hatred of a limb, may be associated with SIB and has been reported without hemiplegia with a right temporo-parietal lesion. Further study is warranted to improve our understanding of the mechanisms underlying SIB.

ARTICLE HISTORY

Received 15 April 2015
Accepted 22 January 2016

KEYWORDS

Stroke; laterality; parietal lobe; temporal lobe; self-injurious behavior (SIB)

Introduction

Self-injurious behaviors (SIB) refer to a wide-range of behaviors intentionally performed to harm one's own body, typically in the absence of suicidal ideation (Claes et al., 2010; Rao, Sudarshan, & Begum, 2008; Winchel & Stanley, 1991). While uncommon in the general population, these behaviors are described in several psychiatric and pervasive neurological conditions, and are pathognomonic for certain illnesses such as Lesch–Nyhan syndrome where they may be stereotyped and repetitive. When present, SIB can contribute substantially to morbidity and mortality. SIB is less commonly described in association with focal lesions and even more rarely as a presenting symptom (Loetscher, Regard, & Brugger, 2006). SIB associated with focal lesions may be reflective of disturbances of mood (i.e., depression), suicidal ideation, impulsivity, or altered bodily perceptions including misoplegia, a syndrome characterized by hatred of a limb which is often associated with self-injurious acts (Kishi, Kosier, & Robinson, 1996; Loetscher et al., 2006; Pompili, Venturini, & Campi et al., 2012; Stanley et al., 2010). Described are two cases of SIB associated with focal strokes presenting within a few years of each other. These cases both initially presented to psychiatric services for SIB and were notable for the absence of suicidal ideation or focal neurologic deficits. They also demonstrated striking similarities in terms of lesion location (right temporo-parietal junction) with each other, and to a previously reported case of misoplegia presenting without hemiplegia which we have referenced in our discussion for comparison (Loetscher et al., 2006).

Case 1

A 64-year-old man presented to medical attention after intentionally amputating his left hand with a circular saw in his garage. When the man was questioned as to why he amputated his hand, he responded, "still trying to figure out why," and consistently expressed regret for having done so. The

patient had experienced pain and numbness in the fingers on his left hand, as well as mild left face numbness, since a stroke that occurred 6 months prior to the amputation. Both the man and his wife indicated that the patient believed the pain in his left hand was a punishment for hitting his wife in the past, but the patient had not expressed any desire for amputation prior to the incident. The patient was stabilized and admitted to the intensive care unit (ICU) for further management.

The ICU team first consulted psychiatry regarding the patient's SIB, but the psychiatry team felt that primary psychiatric pathology was unlikely given the late age of onset and requested a neurology consult. The patient had a history of two strokes. The first occurred 3 years prior to the current admission and was associated with several seizures and mild speech problems and left-sided neglect, both of which resolved within a few months. Notably, the patient also had some neuropsychiatric symptoms following this stroke including hyper-religiosity with unusual behavior including baptizing himself in a river and being found in what appeared to be an ecstatic religious experience in a neighbor's yard. The second stroke occurred 6 months prior to admission and was associated with mild left face and hand numbness. Both strokes were in right middle cerebral artery territory with associated MRI findings of right temporo-parietal lobe injuries. Prior to his amputation event, he was not thought to have any additional psychiatric or neurologic pathology, and his neurological examination did not reveal focal deficits aside from left hand pain/numbness and left face numbness. After the event, his neurological exam was pertinent for left hand amputation with re-attachment, as well as some impairment of left eye vision which was suspected to be related to hypoperfusive retinal ischemia in the setting of blood loss. Formal neuropsychological testing revealed cognitive deficits in recognition memory, visual memory, visuospatial abilities, and construction ability; however, he did have intact verbal learning,

abstract verbal reasoning, as well as testing of general safety awareness. It is unclear when these cognitive deficits developed in relation to this amputation event, but it was speculated that blood loss due to the amputation may have worsened prior cerebral ischemic injuries. Also of note, the patient had possible hyper-religiosity around the time of the event. He recalled a biblical verse entering his mind, either before or shortly after the amputation, which was thought to be (Mark 9:43): "If your hand causes you to stumble, cut it off and throw it away." An electroencephalography (EEG) was performed and demonstrated slowing under the left parasagittal region, but did not demonstrate seizure or epileptiform activity. MRI imaging revealed an old right temporo-parietal junction stroke with no restricted diffusion to suggest an acute infarction or significant recent seizure activity (Figure 1).

Case 2

A 58-year-old woman was admitted to the ICU after consuming 16 ounces of bleach and then lacerating her neck. While drinking the bleach, she claimed she had the thought "I should drink some water because this is poison." She then began drinking water from a glass cup and when she accidentally broke the cup proceeded to use the glass shards to lacerate her neck. The woman described feeling detached from herself during the incident and was unsure why she did it. Five months earlier, the woman had used a knife to lacerate her neck and her left wrist down to the bone. Notably, she denied any suicidal ideation or planning around these incidents and described them as having a compulsive quality where as soon as she saw the SIB instrument (e.g., the knife)

she felt an immediate and strong need to use it on herself. She had a history of depression, bipolar disorder and cognitive impairment but no prior history of suicidality or suicide attempts outside of these two events. The patient was admitted to the ICU for medical stabilization and management.

Again the ICU team initially consulted the psychiatry service regarding her SIB, but the psychiatry team felt that these events were atypical for a psychiatric etiology given the dissociation between the acts and the apparent lack of suicidal intent, and requested a neurology consult. The neurology team found no focal findings on her neurologic exam and recommended a brain magnetic resonance imaging scan (MRI) and EEG. The patient had a normal awake and asleep EEG. Results from the MRI demonstrated a lesion in her right temporo-parietal region consistent with a small subacute stroke, with apparent restricted diffusion in diffusion-weighted imaging (see Figure 1). Neuropsychological assessment revealed deficits in processing speed, verbal memory, and visuospatial skills. Nevertheless, she demonstrated intact working memory, verbal recall, language skills, and executive functioning. Unlike the patient in case 1, she did not express any hyper-religiosity or aberrant beliefs in relation to her SIB. She was, however, thought to have ongoing depression by inpatient psychiatry.

Discussion

Both of the patients reported had focal neurologic lesions in the right temporo-parietal junction presenting with SIB and no focal neurologic examination findings. As SIB may encompass a wide variety of actions, the similarities between the actions of these patients merit review. Both patients presented with behaviors of a compulsive nature, occurring without premeditated planning and seemingly impromptu in the moment. There was a notable lack of suicidal intent. When unilateral bodily targets were chosen (hand in case 1, wrist in case 2) they were on the left side. These cases also exhibit some similarities to the syndrome of misoplegia, that may occur in the absence of hemiplegia with lesions in the right temporo-parietal junction, and xenomelia, a syndrome characterized by non-acceptance and a desire to amputate one or more limbs, which has been recently associated with structural changes in the right parietal lobe (Hilti et al., 2013). We hypothesize that right temporo-parietal junction lesions contribute to SIB due to this brain area's critical role in networks related to the maintenance of body ownership and agency. We further hypothesize that due to disruption of these functions that SIB associated with these lesions is more likely to be directed at specific body parts and to have a quality of dissociation from one's body and less likely to be driven by mood or suicidal thoughts. We will briefly review the normal functions of the temporo-parietal junction and the results of lesions to this area from the standpoint of potential relationship to SIB.

The right temporo-parietal junction contributes to networks important for several functions potentially relevant to SIB including agency, body schema, moral cognition, belief attribution, attention, and decision weighing (Döhnel et al., 2012; Héту, Taschereau-Dumouchel, & Jackson, 2012;

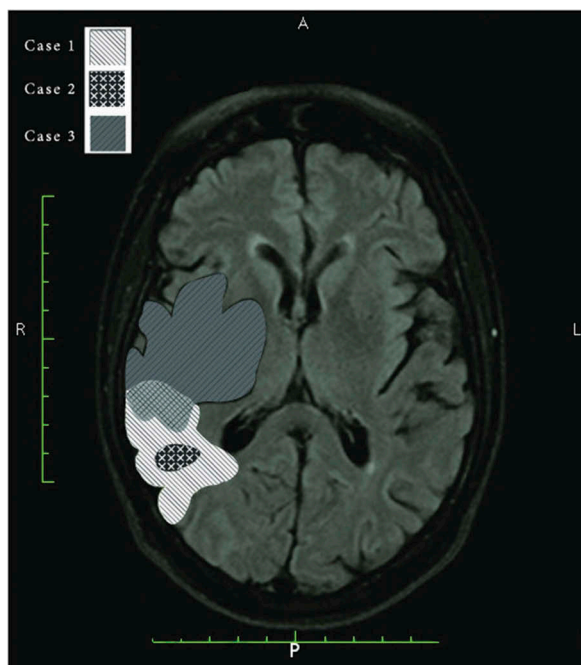


Figure 1. Self-injurious behavior (SIB)-related to right temporo-parietal lesions. Lesion locations superimposed on MRI FLAIR image from case 1 (white) and case 2 (black) presented for the first time in this article and Loetscher, Regard and Brugger's misoplegia without hemiplegia case (case 3; gray). [To view this figure in color, please see the online version of this journal.]

Kahnt & Tobler, 2013; Krall et al., 2015; Young, Camprodon, & Hauser et al., 2010). In looking at the functional networks involving the right temporo-parietal junction, it may be useful to consider those functions that would be expected to inhibit or prevent SIB in healthy individuals. For example, our sense of an integrated self includes body ownership, which may be expected to inhibit SIB through protective aspects of ownership, and agency, which may inhibit self-injurious acts through a feeling of responsibility for one's actions (Feinberg, 2013). It is also expected that social aspects of self and societal expectations of self-care may also serve to inhibit SIB (Turner, Austin, & Chapman, 2014).

Lesions of the right hemisphere, particularly those involving the temporo-parietal junction, are often associated with disturbances of attention, body schema and agency that may be expected to facilitate SIB (Heilman, Watson, & Valenstein, 2013). For example, somatoparaphrenia is a disorder, which is characterized by feelings of disownership toward limbs. It has been hypothesized that somatoparaphrenia occurs due to lesions in a network of the right fronto-tempo-parietal network (Gandola et al., 2012). Xenomelia (or apotemnophilia) is a syndrome characterized by non-acceptance and an intense desire for amputation of one or more limbs typically associated with a sense of the limb as not belonging to them (hence, the term xenomelia indicating hatred of something foreign; Hilti et al., 2013). Notably, xenomelia is typically present from childhood and is not associated with other neurologic or psychiatric pathology. Like somatoparaphrenia, xenomelia appears to be associated with right parietal dysfunction, based on magnetoencephalography and psychometric studies, as well as structural changes detected with MRI comparing cortical thickness and surface area to control subjects (Brang, McGeoch, & Ramachandran, 2008; Hilti et al., 2013; McGeoch, Brang, & Song et al., 2011). As the first case presented following successful amputation of a limb, we may speculate that xenomelia, or at least some characteristics of this syndrome, may have been acquired as a result of his brain lesion. However, religious delusions may have contributed to this patient's act given his prior history of hyper-religiosity, guilt for hitting his wife, and quoting the bible in relation to this act.

Misoplegia is a condition in which a hemiplegic individual feels negative feelings, often described as "hate" toward a limb (Loetscher et al., 2006; Moss & Turnbull, 1996; Van Stralen, Van Zandvoort, & Dijkerman, 2011). Patients with misoplegia typically abuse a limb verbally or physically. When occurring alongside hemiplegia, misoplegia may have indistinguishable presentation between hate for the hemiplegia and inexplicable negative emotions (Longo, Azañón, & Haggard, 2009). For example, in a report of a young boy with misoplegia alongside hemiparesis, the boy would intermittently switch from denying his hemiparesis (anosognosia) and expressing hate toward his limbs (Moss & Turnbull, 1996). In another report, a patient with misoplegia verbally expressed hateful feelings and desires to punish or hurt her arm post-stroke, yet the patient was found stroking her arm affectionately when examined. The patient explained that she was utilizing stroking as a method of maintaining her feeling of ownership over the arm (Longo et al., 2009). Both of these misoplegia cases involved damage localized to the right temporo-parietal junction.

While misoplegia often occurs with hemiplegia, a case report by Loetscher et al. (2006) describes misoplegia-like symptoms in the absence of hemiplegia in a patient with a tumor extending through her right temporo-parietal junction (case 3 in Figure 1). There appears to be overlap in the right temporo-parietal junction between this case and patients reported here, which we have illustrated for comparison (see Figure 1). Intermittently, their patient would switch from caressing her leg to cursing and physically abusing it. This peculiar negative attitude toward the body is compelling, especially without hemiplegia. Alongside hemiplegia, one might justify hate toward the body, due to paralysis making the body unable to function properly. However, in a situation where hemiplegia is absent, one may question what is driving the expression of these negative feelings. Loetscher et al. (2006) suggest that their patient had pre-morbid negative feelings due to the leg being significantly shorter in length than the right due to poliomyelitis. Following stroke or other lesions, the ability of the patient to inhibit impulse and regulate emotion may be lost; releasing repressed hateful feelings toward her limb. In the first case presented, it may be hypothesized that underlying hand numbness and/or delusions about the hand may have been the source of hateful feelings. In case 2, there were no specific bodily aberrations involving targets of her hateful acts (left wrist, neck). It is possible that underlying depression may contribute to more generalized feelings of self-hatred leading to acts aimed at harming the whole body (drinking bleach, lacerating the neck) rather than a specific body area.

While SIB can be seen in epilepsy, as both ictal and post-ictal phenomena, neither of these cases had any evidence of epilepsy by exam or EEG findings. However, SIB is more common in patients with epilepsy than in the general population and may occur as a result of both ictal or post-ictal confusion or psychosis, as well as psychiatric comorbidities (Meyer, Voysey, Holmes, Casey, & Hawton, 2014). The occurrence of injurious behavior and aggression appear bilaterally, and previous reports have found these behaviors alongside post-ictal psychosis predominately with partial seizures emerging from the temporal lobe, often involving the amygdala (Annan, Bartolomei, Biberon, Cottier, & De Toffol, 2015; Hilger et al., 2013; Nadkarni, Arnedo, & Devinsky, 2007). In a case involving left temporal lobe epilepsy, a patient presented with self-mutilating behavior, guilty rumination, and persecutory behavior, raising the possibility that right hemisphere lesions associated with SIB may represent a release phenomenon (Shakya, Shyangwa, & Pandey et al., 2010).

All three of these cases report what appears to be a detachment from their sense of self during their self-injurious incidents. It could be that disruption to a self-regulating system involving the establishment of beliefs, decisions, prospection, or theory of mind could be disrupted, creating disconnect between the self and the experiences. Damage to the right temporo-parietal junction may create a deficit in inhibitory response and judgment, allowing negative affect toward the body to be acted out. In case 1, the patient was reporting the ideation of pain in his hand due to punishment for hitting his wife in the past. The patient could be experiencing inability to inhibit and regulate emotions toward his hand, possibly

brought on by negative feelings toward his hand due to regretful past experiences. Similarly, the patient from case 2 was diagnosed with major depressive disorder; it could be that decreasing the ability to inhibit her negative emotions added to her SIB. While these feelings may have been present prior to strokes, they become amplified post-stroke.

Clearly the majority of patients with lesions involving the right temporo-parietal junction do not present with SIB or even misoplegia. In the cases reviewed above, it appears that a predisposing factor such as disability of a limb (e.g., prior polio, hand numbness), abnormal thoughts such as delusions and hyper-religiosity, and/or a mood disorder can create a priming for the episode of self-injury. Thus right temporo-parietal injury may be hypothesized to release actions related to these negative attributions, and remove normal inhibitions that would otherwise prevent self-injurious acts with a compulsive and non-suicidal character. Indeed, the above cases demonstrate, the SIB may occur in the setting of a temporary state of mind, perhaps through via thoughts and emotions beyond conscious awareness, leading to an apparently compulsive incident of SIB. Unfortunately, due to the clinical nature of these cases and a delay in recognizing their potential links we did not pursue further neuropsychological or neurophysiological studies to confirm or refute our hypotheses. Further studies of SIB may want to consider these qualitative aspects when investigating the contributions of various brain areas and networks to the etiology of these behaviors. These cases also suggest that treatments aimed at increasing the function of right hemisphere networks supporting agency and body ownership may have promise in reducing certain types of self-injurious acts.

Disclosure statement

No potential conflict of interest was reported by the authors.

References

- Annan, M., Bartolomei, F., Biberon, J., Cottier, J.-P., & De Toffol, B. (2015). Appearance of post ictal psychosis after radiosurgical damage in the temporal lobe. *Seizure*, *24*, 140–142. doi:10.1016/j.seizure.2014.09.008
- Brang, D., McGeoch, P. D., & Ramachandran, V. S. (2008). Apotemnophilia: A neurological disorder. *NeuroReport*, *19*, 1305–1306. doi:10.1097/WNR.0b013e32830abc4d
- Claes, L., Muehlenkamp, J., Vandereycken, W., Hamelinck, L., Martens, H., & Claes, S. (2010). Comparison of non-suicidal self-injurious behavior and suicide attempts in patients admitted to a psychiatric crisis unit. *Personality and Individual Differences*, *48*, 83–87. doi:10.1016/j.paid.2009.09.001
- Döhnell, K., Schuwerk, T., Meinhardt, J., Sodian, B., Hajak, G., & Sommer, M. (2012). Functional activity of the right temporo-parietal junction and of the medial prefrontal cortex associated with true and false belief reasoning. *Neuroimage*, *60*, 1652–1661. doi:10.1016/j.neuroimage.2012.01.073
- Feinberg, T. E. (2013). Neuropathologies of the self and the right hemisphere: A window into productive personal pathologies. *Frontiers in Human Neuroscience*, *20*, 472.
- Gandola, M., Invernizzi, P., Sedda, A., Ferrè, E. R., Sterzi, R., Sberna, M., ... Bottini, G. (2012). An anatomical account of somatoparaphrenia. *Cortex: a Journal Devoted to the Study of the Nervous System and Behavior*, *48*, 1165–1178. doi:10.1016/j.cortex.2011.06.012
- Heilman, K., Watson, R., & Valenstein, E. (2003). Chapter 13: Neglect and related disorders. In K. Heilman & E. Valenstein (Eds.), *Clinical neuropsychology* (5th ed., pp. 296–346). New York, NY: Oxford University Press.

- Hétu, S., Tashereau-Dumouchel, V., & Jackson, P. (2012). Stimulating the brain to study social interactions and empathy. *Brain Stimulation*, *5*, 95–102. doi:10.1016/j.brs.2012.03.005
- Hilger, E., Zimprich, F., Jung, R., Pataraja, E., Baumgartner, C., & Bonelli, S. (2013). Postictal psychosis in temporal lobe epilepsy: A case-control study. *European Journal of Neurology*, *20*, 955–961. doi:10.1111/ene.2013.20.issue-6
- Hilti, L. M., Hanggi, J., Vitacco, D. A., Kraemer, B., Palla, A., Luechinger, R., Brugger, P. (2013). The desire for healthy limb amputation: Structural brain correlates and clinical features of xenomelia. *Brain*, *136*, 318–329. doi:10.1093/brain/aws316
- Kahnt, T., & Tobler, P. N. (2013). Salience signals in the right temporo-parietal junction facilitates value-based decisions. *Journal of Neuroscience*, *33*, 863–869. doi:10.1523/JNEUROSCI.3531-12.2013
- Kishi, Y., Kosier, J., & Robinson, R. (1996). Suicidal plans in patients with acute stroke. *The Journal of Nervous and Mental Disorders*, *184*, 274–280. doi:10.1097/00005053-199605000-00002
- Krall, S. C., Rottschy, C., Oberwelland, E., Bzdok, D., Fox, P. T., Eickhoff, S. B., Konrad, K. (2015). The role of the right temporoparietal junction in attention and social interaction as revealed by ALE meta-analysis. *Brain Structure & Function*, *220*, 587–604. doi:10.1007/s00429-014-0803-z
- Loetscher, T., Regard, M., & Brugger, P. (2006). Misoplegia: A review of the literature and a case without hemiplegia. *Journal of Neurology, Neurosurgery & Psychiatry*, *77*, 1099–1100. doi:10.1136/jnnp.2005.087163
- Longo, M. R., Azañón, E., & Haggard, P. (2009). More than skin deep: Body representation beyond primary somatosensory cortex. *Neuropsychologia*, *48*, 655–668. doi:10.1016/j.neuropsychologia.2009.08.022
- McGeoch, P. D., Brang, D., & Song, T., et al. (2011). Xenomelia: A new right parietal love syndrome. *Journal of Neurology, Neurosurgery & Psychiatry*, *82*, 1314–1319. doi:10.1136/jnnp-2011-300224
- Meyer, N., Voysey, M., Holmes, J., Casey, D., & Hawton, K. (2014). Self-harm in people with epilepsy: A retrospective cohort study. *Epilepsia*, *55*, 1355–1365. doi:10.1111/epi.2014.55.issue-9
- Moss, A. D., & Turnbull, O. H. (1996). Hatred of the hemiparetic limbs (misoplegia) in a 10 year old child. *Journal of Neurology, Neurosurgery & Psychiatry*, *61*, 210–211. doi:10.1136/jnnp.61.2.210
- Nadkarni, S., Arnedo, V., & Devinsky, O. (2007). Psychosis in epilepsy patients. *Epilepsia*, *48*, 17–19. doi:10.1111/(ISSN)1528-1167
- Pompili, M., Venturini, P., & Campi, S., et al. (2012). Do stroke patients have an increased risk of developing suicidal ideation or dying by suicide? An overview of the current literature. *CNS Neurosciences & Therapeutics*, *18*, 711–721. doi:10.1111/j.1755-5949.2012.00364.x
- Rao, K. N., Sudarshan, C. Y., & Begum, S. (2008). Self-injurious behavior: A clinical appraisal. *Indian Journal of Psychiatry*, *50*, 288–297. doi:10.4103/0019-5545.44754
- Shakya, D. R., Shyangwa, P. M., & Pandey, A. K., et al. (2010). Self injurious behavior in temporal lobe epilepsy. *JNMA Journal of the Nepal Medical Association*, *49*, 239–242.
- Stanley, B., Sher, L., Wilson, S., Ekman, R., Huang, Y. Y., & Mann, J. J. (2010). Non-suicidal self-injurious behavior, endogenous opioids and monoamine neurotransmitters. *Journal of Affective Disorders*, *124*, 134–140.
- Turner, B. J., Austin, S. B., & Chapman, A. L. (2014). Treating nonsuicidal self-injury: A systematic review of psychological and pharmacological interventions. *Canadian Journal of Psychiatry*, *59*, 576–585.
- van Stralen, H. E., van Zandvoort, M. J. E., & Dijkerman, H. C. (2011). The role of self-touch in somatosensory and body representation disorders after stroke. *Philosophical Transactions of the Royal Society of London. Series B, Biological Sciences*, *66*, 3142–3152. doi:10.1098/rstb.2011.0163
- Winchel, R. M., & Stanley, M. (1991). Self-injurious behavior: A review of the behavior and biology of self-mutilation. *American Journal of Psychiatry*, *148*, 306–317. doi:10.1176/ajp.148.3.306
- Young, L., Camprodon, J. A., & Hauser, M., et al. (2010). Disruption of the right temporoparietal junction with transcranial magnetic stimulation reduces the role of beliefs in moral judgement. *Proceedings of the National Academy of Sciences of the United States of America*, *107*, 6753–6758. doi:10.1073/pnas.0914826107