

## Unique presentation of LHON/MELAS overlap syndrome caused by m.13046T>C in MTND5

Hana Kolarova, Petra Liskova, Marketa Tesarova, Vendula Kucerova Vidrova, Martin Forgac, Josef Zamecnik, Hana Hansikova & Tomas Honzik

To cite this article: Hana Kolarova, Petra Liskova, Marketa Tesarova, Vendula Kucerova Vidrova, Martin Forgac, Josef Zamecnik, Hana Hansikova & Tomas Honzik (2016): Unique presentation of LHON/MELAS overlap syndrome caused by m.13046T>C in MTND5, Ophthalmic Genetics

To link to this article: <http://dx.doi.org/10.3109/13816810.2015.1092045>



Published online: 19 Feb 2016.



Submit your article to this journal [↗](#)



View related articles [↗](#)



View Crossmark data [↗](#)

CASE REPORT

## Unique presentation of LHON/MELAS overlap syndrome caused by m.13046T>C in *MTND5*

Hana Kolarova<sup>a</sup>, Petra Liskova<sup>b,c</sup>, Marketa Tesarova<sup>a</sup>, Vendula Kucerova Vidrova<sup>a</sup>, Martin Forgac<sup>d</sup>, Josef Zamecnik<sup>e</sup>, Hana Hansikova<sup>a</sup>, and Tomas Honzik<sup>a</sup>

<sup>a</sup>Department of Pediatrics and Adolescent Medicine; <sup>b</sup>Laboratory of the Biology and Pathology of the Eye, Institute of Inherited Metabolic Disorders; <sup>c</sup>Department of Ophthalmology; <sup>d</sup>Department of Neurology and Centre of Clinical Neuroscience, First Faculty of Medicine, Charles University in Prague and General University Hospital in Prague, Czech Republic; <sup>e</sup>Department of Pathology and Molecular Medicine, Second Faculty of Medicine, Charles University in Prague and University Hospital Motol in Prague, Czech Republic

### ABSTRACT

**Background:** Leber hereditary optic neuropathy (LHON) and mitochondrial encephalopathy, myopathy, lactic acidosis and stroke-like episodes (MELAS) syndromes are mitochondrially inherited disorders characterized by acute visual failure and variable multiorgan system presentation, respectively.

**Materials and methods:** A 12-year-old girl with otherwise unremarkable medical history presented with abrupt, painless loss of vision. Over the next few months, she developed moderate sensorineural hearing loss, vertigo, migraines, anhedonia and thyroiditis. Ocular examination confirmed bilateral optic nerve atrophy. Metabolic workup documented elevated cerebrospinal fluid lactate. Initial genetic analyses excluded the three most common LHON mutations. Subsequently, Sanger sequencing of the entire mitochondrial DNA (mtDNA) genome was performed.

**Results:** Whole mtDNA sequencing revealed a pathogenic heteroplasmic mutation m.13046T>C in *MTND5* encoding the ND5 subunit of complex I. This particular variant has previously been described in a single case report of MELAS/Leigh syndrome (subacute necrotizing encephalopathy). Based on the constellation of clinical symptoms in our patient, we diagnose the condition as LHON/MELAS overlap syndrome.

**Conclusions:** We describe a unique presentation of LHON/MELAS overlap syndrome resulting from a m.13046T>C mutation in a 12-year-old girl. In patients with sudden vision loss in which three of the most prevalent LHON mitochondrial mutations have been ruled out, molecular genetic examination should be extended to other mtDNA-encoded subunits of *MTND5* complex I. Furthermore, atypical clinical presentations must be considered, even in well-described phenotypes.

### ARTICLE HISTORY

Received 11 April 2015  
Revised 25 August 2015  
Accepted 5 September 2015

### KEYWORDS

LHON; loss of vision; MELAS; mitochondrial DNA; ND5; overlap syndrome

### Introduction

Leber hereditary optic neuropathy (LHON) and mitochondrial encephalopathy, myopathy, lactic acidosis and stroke-like episodes (MELAS) syndromes are mitochondrially inherited diseases characterized by acute vision loss and variable multiorgan system presentation, respectively. Occasionally, vision loss in LHON may have associated features, such as pre-excitation syndromes, perceptual hearing loss or peripheral neuropathy, or may involve the central nervous system with basal ganglia degeneration, a condition previously termed LHON plus.<sup>1</sup> However, only a limited number of such cases have been reported. Interestingly, these are geographically restricted and result from the three common ND1, ND4 or ND6 subunit mutations.<sup>2,3</sup> MELAS usually presents with variable findings, ranging from oligosymptomatic to full phenotypic expression as described by its acronym. The majority of patients present with elevated cerebrospinal fluid (CSF) lactate, a feature that is not found in LHON. In oligosymptomatic MELAS, perceptual hearing loss, diabetes, migraines, psychiatric disturbances and thyroiditis are findings that are frequently

observed (in approximately 75, 50, 25, 15 and 9% of patients, respectively). Conversely, atrophy of the optic nerve resulting in vision loss is present in less than 5% of cases and progresses slowly over years to decades.<sup>4</sup>

In both disease processes, more than 95% of cases are associated with three common mutations: m.11778G>A/*MTND4*, m.3460G>A/*MTND1*, m.14484T>C/*MTND6* and m.3243A>G/*MTTL1*, m.3271T>C/*MTTL1*, m.13513G>A/*MTND5*, in LHON and MELAS, respectively. LHON/MELAS or LHON/MELAS/Leigh overlap syndromes are rare conditions that are often associated with uncommon mitochondrial DNA (mtDNA) mutations.<sup>5</sup> Here, we describe a unique phenotype of LHON/oligosymptomatic MELAS overlap syndrome caused by a rare m.13046T>C mutation in the ND5 subunit of complex I.

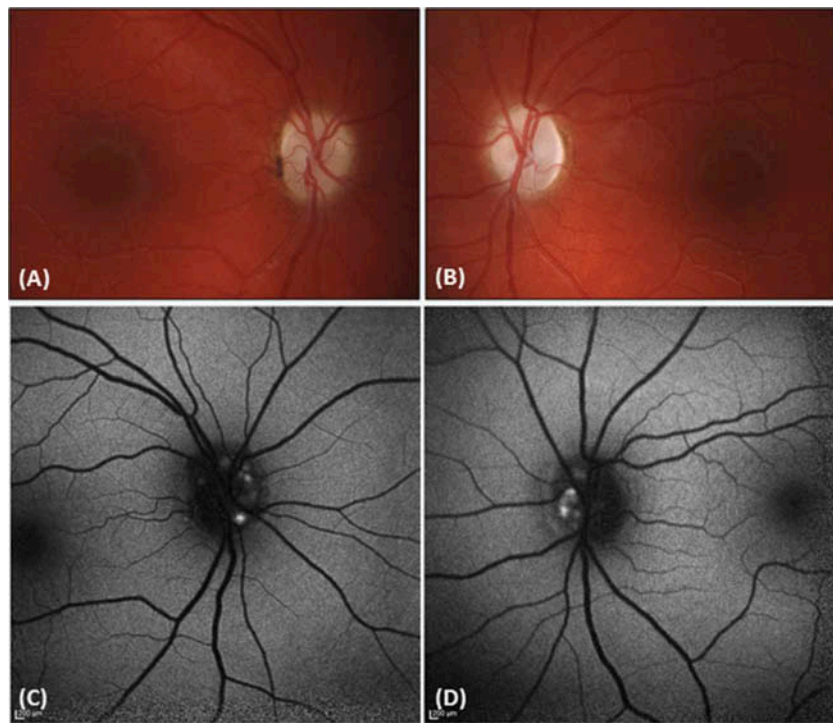
### Case report

A 12-year-old girl with an uneventful perinatal history presented with an abrupt, painless loss of vision in both eyes.

**CONTACT** Tomas Honzik, MD, PhD ✉ [tomas.honzik@vfn.cz](mailto:tomas.honzik@vfn.cz) Department of Pediatrics and Adolescent Medicine, First Faculty of Medicine, Charles University in Prague and General University Hospital in Prague, Ke Karlovu 2, 128 08 Prague 2, Czech Republic.

Color versions of one or more of the figures in the article can be found online at [www.tandfonline.com/iopg](http://www.tandfonline.com/iopg).

© 2016 Taylor & Francis



**Figure 1.** Fundus photography and autofluorescence imaging. Pale optic discs in the right (A) and in the left (B) eye. Optic nerve drusen presenting as focal areas of autofluorescent superficial deposits in the right (C) and in the left (D) eye.

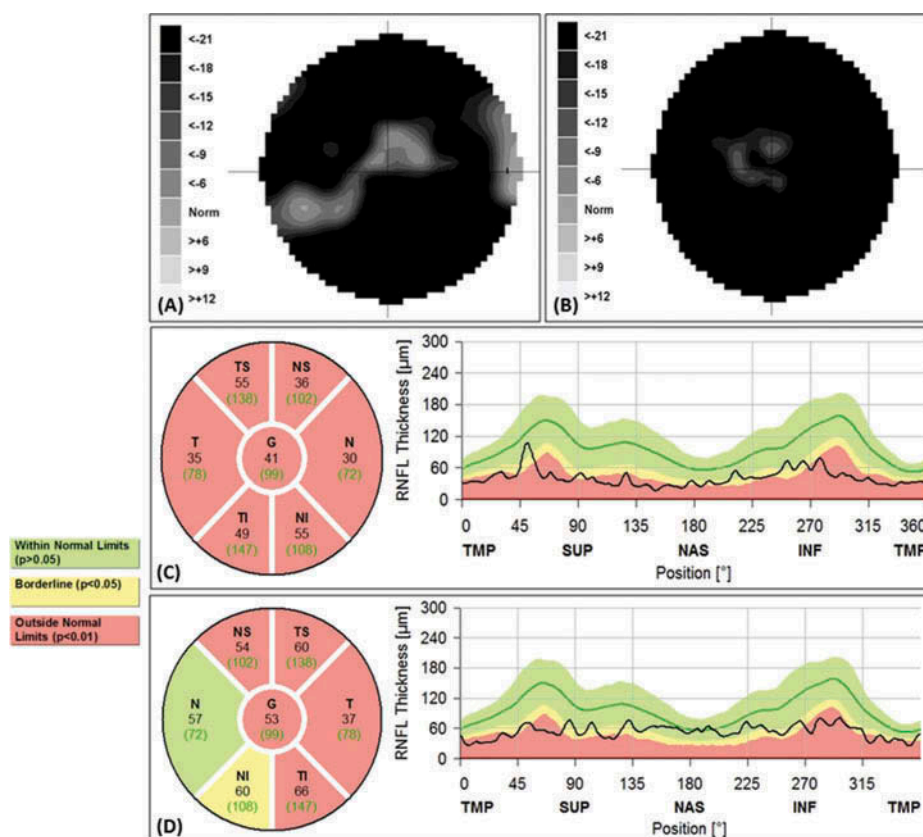
One month later, she developed hearing loss, vertigo and anhedonia. Since then, she has complained of migraine attacks that did not respond to simple analgesics. A year after developing visual symptoms, she presented with struma due to incipient thyroiditis with a negative endocrine workup but confirmed by ultrasound scanning.

One year prior to the onset of visual loss, the patient underwent an ophthalmic examination. Her best corrected visual acuity (BCVA) was 1.0 in both eyes. Two months after the presentation, BCVA was reduced to 0.2 in the right eye and 0.03 in the left eye (per outside clinic records). One and a half years after the disease manifestation, the case was referred to our tertiary care hospital for evaluation, and BCVA was 0.125 in the right eye and 0.02 in the left eye. Both optic nerves appeared pale (Figure 1A, B). As an additional finding, fundus autofluorescence images showed bilaterally hyperfluorescent optic nerve deposits (Figure 1C, D). B-scan ultrasonography confirmed hyperechoic regions over the optic nerve head consistent with a diagnosis of superficial drusen. Standard automated perimetry (M-700, Medmont International, Vermont, Australia) revealed severe bilateral visual field loss (Figure 2A, B). Peripapillary retinal nerve fiber layer (RNFL) measurements were acquired at a diameter of 3.54 mm, targeted around the optic nerve using a spectral-domain device (Spectralis, Heidelberg Engineering GmbH, Heidelberg, Germany). RNFL loss confirmed the presence of bilateral optic neuropathy (Figure 2C, D). Neither ptosis nor ophthalmoplegia were observed. Visual evoked potentials showed overall reduced amplitudes with prolonged P100 wave latencies bilaterally, confirming abnormal neural conduction along the visual pathways pronounced primarily in the retrobulbar portion of the optic nerve. Hearing loss was

classified as moderate sensorineural (30 dB loss in the right ear and 20 dB in the left ear). Electromyography, brain magnetic resonance imaging and cardiovascular examination did not reveal any significant pathology.

Initial genetic analyses ruled out the most common LHON mutations (m.11778G>A, m.3460G>A and m.14484T>C) in mtDNA. Extensive metabolic workup documented only elevated CSF lactate of 4.25 mmol/l (normal <2.1). Muscle biopsy did not show myopathic or neurogenic changes. Enzyme histochemistry revealed focal subsarcolemmal accumulation of succinate dehydrogenase reaction product in up to 5% of muscle fibers (Figure 3A). Cytochrome *c* oxidase-negative fibers were not observed; however, the reaction was weakened focally (Figure 3B). These distinctive histological findings indicate incipient mitochondrial myopathy in our patient. Spectrophotometric analyses of specific activities of respiratory chain complexes were conducted in isolated mitochondria from fresh muscle biopsies. There was a 50% reduction in the activity of complex I of the respiratory chain, while activities of complexes II, III and IV were within the control range. Furthermore, measurements of mitochondrial energy-generating capacity in fresh muscle postnuclear supernatant with various radiolabelled substrates indicated oxidative phosphorylation deficiency.

Mitochondrial DNA sequencing revealed a pathogenic heteroplasmic mutation m.13046T>C in *MTND5* that encodes the ND5 subunit of complex I. Quantification of mutational load in examined tissue showed the following: urine sediment 71%, muscle 70%, hair follicles 44%, fibroblasts 40%, buccal smear 34% and blood 27%. The mutation was not detected in blood, urine sediment, buccal smear or hair follicles from the patient's asymptomatic mother and two younger brothers.



**Figure 2.** Automated perimetry and retinal nerve fibre layer thickness measurements obtained at the age of 13.5 years. Visual field loss within the central 22°; centrocaecal island extending to the nasal inferior region in the right eye (A) and small central island remains in the left eye (B). Reduction in retinal nerve fibre layer thickness and loss of striation pattern in the right eye (C). Relative preservation of the nasal quadrant in the left eye (D).

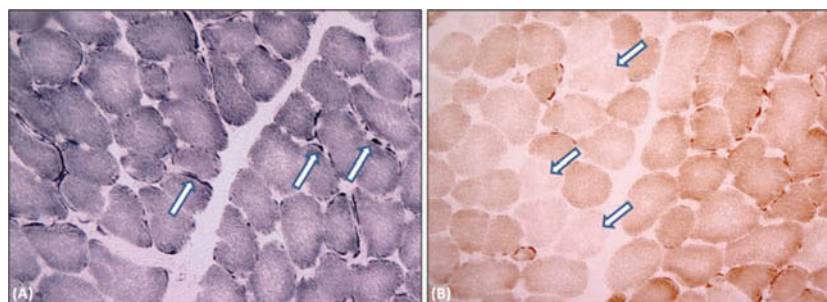
These findings may result from extremely low mutation load in analyzed tissues and/or the limited presence of the mutation in the mother's oocytes.

## Discussion

We present a unique phenotype of LHON/MELAS overlap syndrome caused by a rare mtDNA mutation m.13046T>C, previously described in a single case report. The clinical presentation of sudden vision loss and characteristic changes on ophthalmic examination are fully compatible with the diagnosis of LHON; furthermore, the patient's elevated CSF lactate, perceptual hearing loss, migraines and thyroiditis are

findings frequently associated with oligosymptomatic MELAS. To the best of our knowledge optic nerve head drusen detected in our patient have not been reported in association with LHON and/or MELAS patients. Even though we cannot exclude drusen as an incidental finding, their possible association with LHON warrants further investigation.

The disease-causing mutation m.13046T>C in the *MTND5* encoding the ND5 subunit of complex I was previously detected in a 13-year-old girl with a 2-way overlap syndrome MELAS/Leigh who presented with abnormal gait, stroke-like episodes and characteristic brain MRI imaging.<sup>6</sup> For mitochondrial disorders, it is not unusual for the same mutation



**Figure 3.** In muscle biopsy, focal subsarcolemmal accumulation of succinate dehydrogenase reaction product (exemplified by arrows) was observed in 5% of muscle fibers (A, succinate dehydrogenase histochemistry, original magnification  $\times 200$ ). Cytochrome c oxidase-negative fibers were not observed, nevertheless, the reaction was weakened focally (B, cytochrome c oxidase histochemistry, original magnification  $\times 200$ , exemplified by arrows).

to result in different phenotypes. While several factors are suspected to be responsible for mitochondrial disease manifestations, mutational load remains a hotly debated issue. In our patient, we observed wide-ranging mutational load in examined tissues, a finding that may suggest less compromised mitochondrial function without the involvement of the central nervous system. This hypothesis is supported by the work of Blok and colleagues and Crimi and colleagues who observed similarly high levels of heteroplasmy in examined tissues of patients with Leigh or MELAS/Leigh syndrome, respectively. Furthermore, these studies reported mutations in close proximity to the pathogenetic variant identified in our patient.<sup>7,8</sup>

The amino acid substitution p.Met237Thr caused by the mutation m.13046T>C is located in the loop of the highly conserved domain of subunit ND5, the last and likely rate-limiting component of complex I.<sup>9</sup> In the last two decades, an increasing number of mutations have been identified in the *MTND5* related to mitochondrial disorders. Moreover, it has been previously shown that *MTND5* mutations become relatively prevalent (27%) when the common mutations of mitochondrial disorders are excluded.<sup>7</sup> The most frequent mutation in the *MTND5* is m.13513G>A, which is usually associated with MELAS or MELAS overlap phenotypes including LHON/MELAS.<sup>10,11</sup> The mutations m.3243A>G and m.3271T>C both encode mitochondrial tRNA-leu. Together, these three mutations are responsible for more than 95% of MELAS cases. Three common mutations in the ND1, ND4 and ND6 subunit account for approximately 95% cases of LHON, although there are seven other mutations in the genes encoding mitochondrial complex I that are responsible for the development of this disorder.<sup>12</sup> Nevertheless, only rare cases of isolated LHON have been associated with *MTND5* mutations. Furthermore, it has been suggested that, with *MTND5* base changes, an extended phenotype can be expected rather than a phenotype limited to visual dysfunction.<sup>13</sup>

Vascular dysfunction appears to play an important role in the ethiopathogenesis of mitochondrial disorders. Microangiopathic changes accompanied by dramatic collections of abnormal mitochondria in both endothelial and vascular smooth muscle cells were observed in cases of LHON and MELAS; similar vascular changes also characterize Leigh syndrome.<sup>13–15</sup> Vascular cell loss and blood-brain barrier breakdown could result in multiple ischemic-like lesions occurring in MELAS patients and vasculo-necrotic damage affecting basal ganglia and brainstem in Leigh syndrome. In LHON patients, it was observed that the prelaminar non-myelinated portions of the optic nerve, that are specifically damaged in LHON, are more energy-dependent than the myelinated portions characterized by more efficient saltatory conduction.<sup>13</sup> Moreover, the optic nerve preceding the lamina cribrosa is characterized by an altered blood-brain barrier with non-specific vesicular permeability and thus may be more susceptible to toxic damage.<sup>16</sup> Thus, the pathogenetic sequences that lead to LHON, MELAS and Leigh syndromes may share a common microangiopathic mechanism with varying degrees of central nervous system

involvement.<sup>13</sup> Within this spectrum, LHON would be considered rather a mild disorder, as it is limited to the optic nerve. However, we cannot exclude future progression to Leigh syndrome in our patient, and thus, regular magnetic resonance imaging is recommended.

Here, we have described a unique phenotype, overlap syndrome of LHON and oligosymptomatic MELAS, associated with a rare m.13046T>C mutation in the ND5 subunit of complex I. In cases of vision loss suspected to be due to a mitochondrial disorder, after ruling out the three most common pathogenic changes, mutations in other subunits of complex I must be considered.

## Declaration of interest

The authors report no conflicts of interest. The authors alone are responsible for the content and writing of this article.

## Funding

This work was supported by grants IGA NT 14156/3, IGA NT 13114/4, GAUK 38515/2015 and by institutional research support by Charles University in Prague (PRVOUK P24/LF1/3, RVO-VFN 64165, SVV UK 260148/2015).

## References

- Fraser JA, Biousse V, Newman NJ. The neuro-ophthalmology of mitochondrial disease. *Surv Ophthalmol* 2010;55:299–334.
- Nikoskelainen EK, Martilla RJ, Huoponen K, et al. Leber's plus: neurological abnormalities in patients with Leber's hereditary optic neuropathy. *J Neurol* 1995;59:160–164.
- Wallace DC. A new manifestation of Leber's disease and a new explanation for the agency responsible for this unusual pattern of inheritance. *Brain* 1970;93:121–132.
- Mancuso M, Orsucci D, Angelini C, et al. The m.3243A>G mitochondrial DNA mutation and related phenotypes. A matter of gender? *J Neurol* 2014;261:504–510.
- Blakely EL, de Silva R, King A, et al. LHON/MELAS overlap syndrome associated with a mitochondrial *MTND1* gene mutation. *Eur J Hum Genet* 2005;13:623–627.
- Zhao D, Hong D, Zhang W, et al. Mutations in the mitochondrially encoded complex I enzyme as the second cause in the cohort of Chinese patients with mitochondrial myopathy, encephalopathy, lactic acidosis and stroke-like episodes. *J Hum Genet* 2011;56:759–764.
- Blok MJ, Spruijt L, de Coo IFM, et al. Mutations in the ND5 subunit of complex I of the mitochondrial DNA are a frequent cause of oxidative phosphorylation disease. *J Med Genet* 2007;44:1–5.
- Crimi M, Galbiati S, Moroni I, et al. A missense mutation in the mitochondrial ND5 gene associated with a Leigh-MELAS overlap syndrome. *Neurology* 2000;60:1857–1861.
- Bai Y, Shakeley RM, Attardi G. Tight control of respiration by NADH dehydrogenase ND5 subunit gene expression in mouse mitochondria. *Mol Cell Biol* 2000;20:805–815.
- Shanske S, Eunson L, Patterson V, et al. The G13513A mutation in the ND5 gene of the mitochondrial DNA is a common cause of MELAS or Leigh syndrome: evidence from 12 cases. *Arch Neurol* 2008;65:368–372.
- Pulkes T, Eunson L, Patterson V, et al. The mitochondrial DNA G13513A transition in ND5 is associated with a LHON/MELAS overlap syndrome and may be a frequent cause of MELAS. *Ann Neurol* 1999;46:916–919.
- Mayorov V, Biousse V, Newman J, et al. The role of the ND5 gene in LHON: characterization of a new, heteroplasmic LHON mutation. *Ann Neurol* 2005;58:807–811.

13. Carelli V, Ross-Cisneros FN, Sadun AA. Mitochondrial dysfunction as a cause of optic neuropathies. *Prog Retin Eye Res* 2004;23:53–89.
14. Hasegawa H, Matsuoka T, Goro Y, et al. Strongly succinate dehydrogenase-reactive blood vessels in muscles from patients with mitochondrial myopathy, encephalopathy, lactic acidosis, and stroke-like episodes. *Ann Neurol* 1991;29:601–605.
15. Cavanagh JB, Harding BN. Pathogenetic factors underlying the lesions in Leigh's disease. Tissue responses to cellular energy deprivation and their clinico-pathological consequence. *Brain* 1994;117:1357–1376.
16. Hofman P, Hoyng P, vanderWerf F, et al. Lack of blood-brain barrier properties in microvessels of the prelaminar optic nerve head. *Invest Ophthalmol* 2011;42:895–901.