

Disseminated Intravascular Coagulation in Secondary Glioblastoma due to Excessive Intraoperative Bleeding: Case Report and Review of the Literature

Daniel Pinggera¹, Johannes Kerschbaumer¹, Nicole Innerhofer², Adelheid Woehrer³, Christian Franz Freyschlag¹, Claudius Thomé¹

Key words

- Bleeding
- Disseminated intravascular coagulation
- Glioblastoma

Abbreviations and Acronyms

DIC: Disseminated intravascular coagulation

TF: Tissue factor

From the Departments of ¹Neurosurgery and ²Anesthesiology and Intensive Care Medicine, Medical University Innsbruck, Innsbruck; and ³Institute of Neurology, Medical University of Vienna, Vienna, Austria

To whom correspondence should be addressed:

Christian Franz Freyschlag, M.D.

[E-mail: christian.freyschlag@tirol-kliniken.at]

Citation: *World Neurosurg.* (2016).

<http://dx.doi.org/10.1016/j.wneu.2016.02.077>

Journal homepage: www.WORLDNEUROSURGERY.org

Available online: www.sciencedirect.com

1878-8750/\$ - see front matter © 2016 Elsevier Inc.

All rights reserved.

INTRODUCTION

Disseminated intravascular coagulation (DIC) is a hemorrhagic disorder that can occur as a complication in various diseases and is characterized by a consumptive coagulopathy due to pathologic activation of coagulation mechanisms. It leads to thrombi in various organs, often causing multiple organ failure. However, DIC normally comes to the attention of the neurosurgeon only after brain trauma and is an extremely rare complication during elective brain tumor surgery. We present a patient who developed DIC immediately after operation for a secondary glioblastoma. No report of this disorder associated with pretreated glioblastoma could be found in the literature.

CASE REPORT

We present the case of a 30-year-old female patient who underwent surgery for a secondary glioblastoma. At the age of 27 years a temporoparietal mass was first resected microsurgically, histopathologically proven as a protoplasmatic astrocytoma World

■ **BACKGROUND:** Disseminated intravascular coagulation (DIC) describes a pathologic activation of coagulation mechanisms, leading to thrombi in various organs with contribution to multiple organ failure. In clinical practice, diagnosis of DIC can often be made by laboratory values, including prolonged coagulation times, thrombocytopenia, or high levels of fibrin degradation products. DIC is frequently observed after neurotrauma, but rarely occurs in patients with primary brain tumors. There are only few case reports of DIC in patients with primary brain tumors, all sharing the highly elevated mortality. We report the case of a young patient presenting with secondary glioblastoma, who developed multiorgan failure induced by DIC after extensive intraoperative bleeding.

■ **CASE DESCRIPTION:** A 30-year-old patient was admitted in poor general condition with insomnia, severe headache, and vomiting. She had undergone surgery for secondary glioblastoma twice. Magnetic resonance imaging revealed a left temporoparietal mass lesion with indication for resection. Surgery then was complicated by diffuse intraoperative bleeding due to a high content of microvascular proliferation as shown in the histopathologic workup. Subsequently, an uncontrollable multiorgan failure developed, causing the patient's death 4 days after surgery.

■ **CONCLUSIONS:** Although a rare complication, excessive intraoperative bleeding, especially in surgery for brain tumors located next to the ventricular system, DIC should be kept in mind as a possible diagnosis.

Health Organization II. Two years later the patient had undergone a second surgery due to radiologic progress. The histopathologic workup revealed a highly malignant anaplastic astrocytoma with focal transition to a glioblastoma. Radiochemotherapy was induced postoperatively. The radiotherapy was stopped by the patient after an applied dose of 16 Gy. Subsequently, adjuvant chemotherapy with temozolomide (150 mg/square meters 5/28 days) was administered for at least 9 cycles with stable disease. About 1 year after the second surgery, the patient was admitted in poor general condition. The neurological examination revealed insomnia, severe headache, vomiting, and the known quadrantanopia. Magnetic resonance imaging showed a large left temporoparietal mass with a diameter of 6 cm, crossing the midline (Figure 1). The preoperative laboratory examinations were

unremarkable and the coagulation analysis was without pathologic finding (Table 1).

Surgery was performed using neuro-navigation and 5-aminolevulinic acid. After removing the preexisting bone flap, the brain and dura were pressurized. After opening of the dura, hematoma-like liquid flowed out under high pressure. The tumor presented itself a pulsatile mass, which started to bleed spontaneously after pressure relief. The tumor was meticulously dissected from the surrounding brain tissue, showing a pseudocapsule. It was possible to remove a large part of the black, pulsatile tumor en-bloc after microsurgical blunt dissection and placement of cottonoids. The patient did not present with any signs of coagulation disorder after the operation. Hemostasis could be achieved at any time by coagulation or use of oxidized cellulosis. Soon after removal of the deep part of the tumor, which was adherent

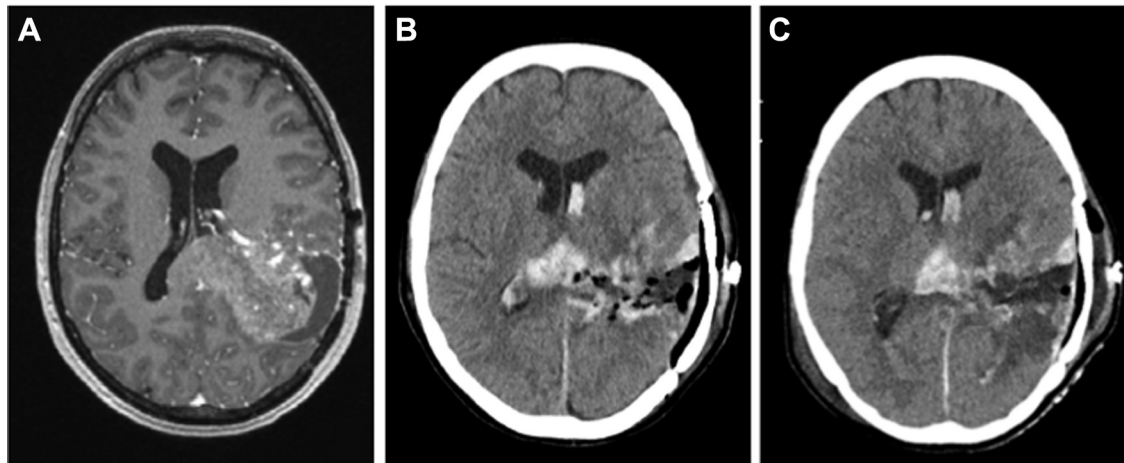


Figure 1. Imaging data. (A) Preoperative magnetic resonance imaging. (B) Postoperative computed tomogram (CT) after surgery. (C) CT Postoperative day 4.

to the choroid plexus, under coagulation by bipolar forceps, the surrounding parenchyma started bleeding diffusely. To compensate for the persistent bleeding, administration of packed red blood cells, fresh frozen plasma, and thrombocyte concentrates were started, as appropriate. To cease the hemorrhage intraoperatively, we used hemostyptic agents like oxidized regenerated cellulose (Tabotamp, Ethicon, Germany), flowable hemostatic matrix (FloSeal, Baxter, USA), and potato starch (Arista, Bard Davol, USA). All agents were combined with compression by cottonoids, electrocoagulation, and constant irrigation. Furthermore, an additional systemic administration of blood products and stabilizing agents (e.g., recombinant factor XIII) was started (Table 2). In the end a sufficient restitution of coagulation was

achieved. At the time of dural closure there were no signs of active bleeding and the patient was stable. She was transferred to the intensive care unit and an early postoperative computer tomography scan showed a discrete hemorrhage within the resection cavity and the ventricular system with no mass effect. Intracranial pressure monitoring was stable (~ 20 mm Hg) and the mean postoperative blood pressure was 125/60 mm Hg (range, 110/40–190/80 mm Hg).

Subsequently, the patient developed anuria with increased serum levels of creatinine, which caused a mandatory start of hemofiltration, which increased the intracranial pressure to 50 mm Hg, which was responsive to hyperventilation. Additional computer tomography scans revealed no new

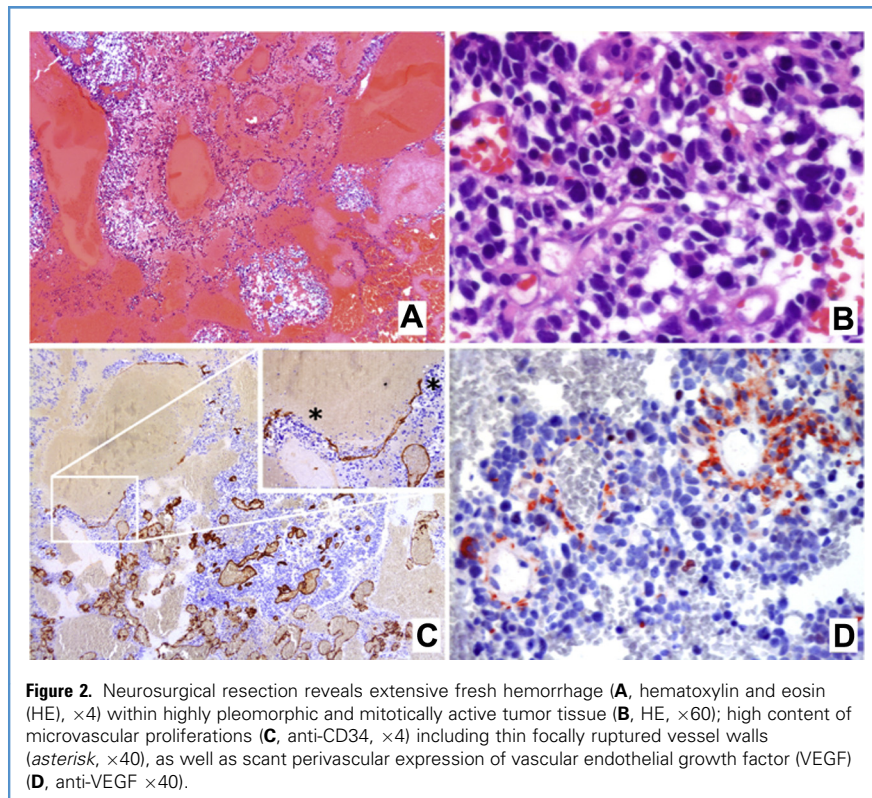
hemorrhages (Figure 1). The patient was managed with hemofiltration and catecholamine infusion. During the next 4 postoperative days the dosage of intravenous catecholamine had to be increased constantly, resulting in a triple therapy with phenylephrine, norepinephrine, and dobutamine. Notwithstanding the massive vasopressive treatment, the patient became circulatory unstable and died 4 days after surgery. During the postoperative course there was no sign of sepsis, with all microbiological findings aseptic and a short postoperative elevation of C reactive protein level with nearly normalization before death.

Table 1. Pertinent Laboratory Data

	Preoperative	Beginning Surgery	End of Surgery	First Postoperative Day
Thrombocytes (150–380 g/L)	228	182	79	83
Erythrocytes (3.80–5.20 T/l)	4.53	3.04	2.85	4.08
Fibrinogen (210–400 mg/dL)	178	193	182	219
Antithrombin III (79%–112%)	109	59	60	71
Partial thromboplastin time (26–37 seconds)	30	37	155	36
Prothrombin time (70%–130%)	78	64	69	73
Clot forming time (52–116 seconds)	—	90	136	99
Creatinine (0.51–0.95 mg/dL)	0.65	—	—	2.45

Table 2. Blood and Pharmacologic Products Administered

	Intraoperative Administration	Postoperative Administration
Thrombocyte concentrates	660 mL	330 mL
Packed red blood cells	3600 mL	—
Fresh frozen plasma	4000 mL	—
Human fibrinogen	4 g	2 g
Tranexamic acid	2000 mg	—
Factor XIII	1250 IE	—
Prothrombin	1 mg	-



The histologic examination (Figure 2) revealed extensive fresh hemorrhage within a highly pleomorphic and mitotically active tumor tissue. A high content of microvascular proliferation including thin spontaneously ruptured vessel walls, as well as scant perivascular expression of vascular endothelial growth factor was found. Overall, the tumor was graded as a secondary glioblastoma (World Health Organization IV). The immunohistochemical examination of the tissue revealed expression of epidermal growth factor receptor, p53, and mutation of isocitrate dehydrogenase 1.

The autopsy showed thrombosis in both kidneys, lung, and liver. The examination of the brain revealed a residual hemorrhage in the resection cavity (Figure 3). The cause of death of the patient was documented as severe shock due to DIC.

DISCUSSION

DIC is a hemorrhagic disorder that can occur in a variety of diseases and is characterized by consumptive coagulopathy and proteolytic degradation products.¹ The laboratory criteria

for DIC diagnosis are thrombocytopenia, decreased fibrinogen, prolonged prothrombin times, and presence of fibrinogen degradation product.^{2,3} Overall it is rare in patients undergoing neurosurgical procedures, but in most cases it is associated with traumatic brain injury.⁴ The pathophysiology of traumatic brain injury-induced coagulopathy remains not fully understood, but is thought to be mediated, among other things, by increased levels of tissue factor (TF), a known initiating step of

the extrinsic blood coagulation. The innately high levels of TF in the healthy brain tissue can be focally or widely overexpressed in glioma and can, in addition, be correlated with the histologic grade. An overexpression is seen in >90% of high grade glioma.⁵ Furthermore, increased intratumoral clotting has been shown to enhance the hypoxic environment and, in turn, lead to further upregulation of TF. TF expression is associated with enhanced vascular endothelial growth factor production, as seen in the histopathologic work-up of our case, suggesting a role of TF in tumor initiation, tumor growth, and angiogenesis.⁶

There exist only few reports about DIC in patients undergoing surgery for brain metastasis and to our knowledge this is the first report about DIC in a patient with secondary glioblastoma. DIC is a very serious condition, as among the few patients previously described in the English literature, most died in the early postoperative phase and only a few of them survived despite neurological deficit (Table 3).⁷⁻¹¹ Similar to the cases of Matjasko and Ducker⁷ and Vardi et al,⁸ our patient was a young woman with a brain tumor in proximity to the ventricular system. Damage to the ventricular system and the choroid plexus could be an initiating event for fibrinolytic diathesis, as the major bleeding started after resection in proximity to the choroid plexus. The brain tissue itself is rich in thromboplastin and high levels of fibrinolytic activity can be found in the choroid plexus.¹² In traumatic patients, high levels of thromboplastin in the CSF have been found and there are also case reports with DIC, associated with ventriculoperitoneal shunt surgery.¹³

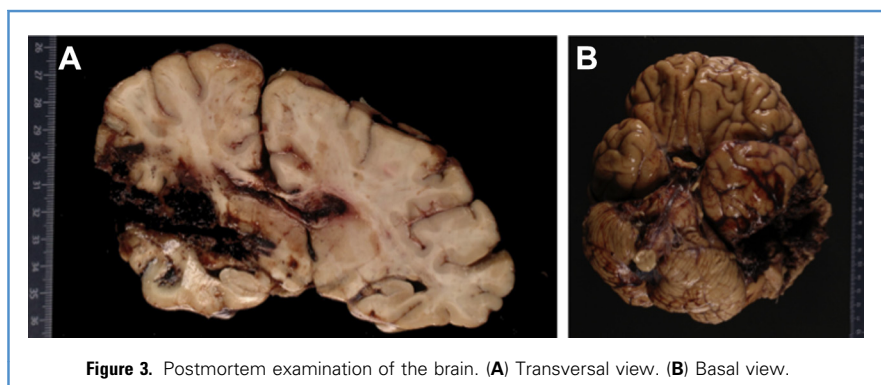


Table 3. Review of Literature

Author/Year	Age (year)/Gender	Location	Histology	Outcome
Matjasko et al, 1977 ⁷	23/female	Third ventricle (contact to ventricle)	Oligodendroglioma	Death
Vardi et al, 1974 ⁸	19/female	Temporal (contact to ventricle)	Oligastrocytoma	Death
Berger et al, 1995 ⁹	54/male	Parieto-occipital	Astrocytoma, WHO III	Neurological worsening
Kawakami et al, 1990 ¹⁰	57/female	Frontal (contact to ventricle)	Glioblastoma (primary)	Death
Velez and Friedmann 2011 ¹¹	62/female	Frontal	Meningeoma	No neurological worsening
Present case	30/female	Temporoparietal (contact to ventricle)	Glioblastoma (secondary)	Death

WHO, World Health Organization.

In contrast to other described cases, our patient underwent a previous resection of a brain tumor without complications. As shown in the histopathologic workup the tumor showed a high amount of microvascular proliferation, including thin spontaneously ruptured vessel walls, suggesting a transformation to a highly malign tumor, suggesting high levels of TF.⁵

In the cases described by Matjasko and Ducker⁷ and Kawakami et al,¹⁰ DIC led to death by intracerebral hemorrhage and/or brain edema, whereas our patient died of multiorgan failure days after surgery. According to literature, acute DIC manifests itself with renal dysfunction in up to 25%, hepatic dysfunction in 19%, whereas only 2% of cases involve the central nervous system.¹⁴

Low fibrinogen concentrations are common in young adults, as it appeared in our patient. The fibrinogen concentration was 178 mg/dL before surgery and thus clearly below the reference range of 210–400 mg/dL. Fibrinogen plays a central role in hemostasis by being a precondition for platelet adhesion and aggregation, and cleavage by thrombin permits fibrin formation, which stabilizes the initially formed platelet plug.¹⁵ Fibrinogen is also called antithrombin I¹⁶ because of its ability to bind excess of thrombin, which otherwise may facilitate development of thrombosis or DIC. Fibrinogen is consumed by the process of clot formation and known as the first coagulation factor that becomes critically reduced during blood loss.¹⁷ The loss and consumption of fibrinogen cannot be compensated by synthesis in the liver, resulting in development of fibrinogen deficiency, whereas platelets can be liberated from the bone marrow and

spleen, and thrombin formation is maintained by the usually high TF levels present, especially in brain surgery.¹⁸ The amount of blood loss needed to reach critically reduced fibrinogen levels clearly depends on initial concentrations. The lower initial fibrinogen concentrations, the faster critically levels <150–200 mg/dL are reached.¹⁹ Available data show that targeted fibrinogen substitution by using fibrinogen concentrate or cryoprecipitate decreases blood loss and transfusion requirements. It is even associated with decreased mortality in trauma patients.^{15,20,21} In contrast, the use of fresh-frozen plasma for restoring sufficient fibrinogen levels is futile because of the known low concentration of fibrinogen and the unavoidable volume expansion that counterbalances the therapeutic aim of increasing fibrinogen levels.^{22–25}

Because of all these reasons and the multiple spontaneous rupturing vessels, it seems conceivable that the administration of fibrinogen concentrate and tranexamic acid were the reason for the final hemostasis. Maybe an earlier administration would have been beneficial in this patient by improving the initial hemostatic competence, thus decreasing blood loss from the beginning and throughout surgery, which also translates into avoidance of massive blood transfusion, as was needed. It seems also logical that sufficient fibrinogen levels could have limited the vicious cycle of huge thrombin formation due to surgery-induced TF liberation, aggravating consumption of all players of the coagulation system and ultimately resulting in severe coagulopathy, massive bleeding, and massive transfusion, conditions that are associated with

development of organ failure and worse outcome.

A limitation in the present case is that the laboratory values do not correspond fully to the diagnostic guidelines provided by Levi et al.² But, in addition to the underlying disorder and the postmortem examination, in our opinion, the data are sufficient to confirm the diagnosis of DIC.

CONCLUSION

The mortality of DIC, in association with primary brain tumor, is very high (3 of 5 patients in the reviewed literature) and only timely diagnosis and immediate treatment offers a narrow window to avert ischemic deficits and severe organ failure. Although it is a rare complication, in excessive intraoperative bleeding, especially in surgery for brain tumors located next to the ventricular system, DIC should be kept in mind as a possible diagnosis. Furthermore, especially in a neurosurgical population, levels of fibrinogen should be in the upper normal range and fibrinogen concentrate and tranexamic acid should be substituted at the first sign of bleeding complications.

REFERENCES

1. Levi M, Ten Cate H. Disseminated intravascular coagulation. *N Engl J Med*. 1999;341:586–592.
2. Levi M, Toh CH, Thachil J, Watson HG. Guidelines for the diagnosis and management of disseminated intravascular coagulation. British Committee for Standards in Haematology. *Br J Haematol*. 2009;145:24–33.
3. Eom KS, Kim JM, Kim TY. Disseminated intravascular coagulation in a patient undergoing removal of metastatic brain tumor. *J Korean Neurosurg Soc*. 2008;44:341–344.

4. Kaufman HH, Hui KS, Mattson JC, Borit A, Childs TL, Hoots WK, et al. Clinicopathological correlations of disseminated intravascular coagulation in patients with head injury. *Neurosurgery*. 1984;15:34-42.
5. Hamada K, Kuratsu J, Saitoh Y, Takeshima H, Nishi T, Ushio Y. Expression of tissue factor correlates with grade of malignancy in human glioma. *Cancer*. 1996;77:1877-1883.
6. Milsom CC, Yu JL, Mackman N, Micallef J, Anderson GM, Guha A, et al. Tissue factor regulation by epidermal growth factor receptor and epithelial-to-mesenchymal transitions: effect on tumor initiation and angiogenesis. *Cancer Res*. 2008;68:10068-10076.
7. Matjasko MJ, Ducker TB. Disseminated intravascular coagulation associated with removal of a primary brain tumor. Case report. *J Neurosurg*. 1977;47:476-480.
8. Vardi Y, Streifler M, Schujman E, Loewenthal M. Diffuse intravascular clotting associated with a primary brain tumour. *J Neurol Neurosurg Psychiatry*. 1974;37:987-990.
9. Berger MM, Ravussin P, Vielle G, Fankhauser H. Life-threatening hemorrhagic diathesis due to disseminated intravascular coagulation during elective brain tumor surgery. *Neurosurg Anesthesiol*. 1995;7:26-29.
10. Kawakami Y, Ueki K, Chikama M, Shimamura Y, Naito T. Intracranial hemorrhage associated with nontraumatic disseminated intravascular coagulation—report of four cases. *Neurol Med Chir (Tokyo)*. 1990;30:610-617.
11. Velez AM, Friedman WA. Disseminated intravascular coagulation during resection of a meningioma: case report. *Neurosurgery*. 2011;68:E1165-E1169 [discussion: E1169].
12. Takashima S, Koga M, Tanaka K. Fibrinolytic activity of human brain and cerebrospinal fluid. *Br J Exp Pathol*. 1969;50:533-539.
13. Frazier JL, Bova GS, Jockovic K, Hunt EA, Lee B, Ahn ES. Disseminated intravascular coagulation associated with ventriculoperitoneal shunt surgery. *J Neurosurg Pediatr*. 2010;5:306-309.
14. Siegal T, Seligsohn U, Aghai E, Modan M. Clinical and laboratory aspects of disseminated intravascular coagulation (DIC): a study of 118 cases. *Thromb Haemost*. 1978;39:122-134.
15. Levy JH, Welsby I, Goodnough LT. Fibrinogen as a therapeutic target for bleeding: a review of critical levels and replacement therapy. *Transfusion*. 2014;54:1389-1405 [quiz 1408].
16. Mosesson MW. Update on antithrombin I (fibrin). *Thromb Haemost*. 2007;98:105-108.
17. Hiippala ST, Myllylä GJ, Vahtera EM. Hemostatic factors and replacement of major blood loss with plasma-poor red cell concentrates. *Anesth Analg*. 1995;81:360-365.
18. Martini WZ. Fibrinogen metabolic responses to trauma. *Scand J Trauma Resusc Emerg Med*. 2009;17:2.
19. Singbartl K, Innerhofer P, Radvan J, Westphalen B, Fries D, Stogbauer R, et al. Hemostasis and hemodilution: a quantitative mathematical guide for clinical practice. *Anesth Analg*. 2003;96:929-935.
20. Rourke C, Curry N, Khan S, Taylor R, Raza I, Davenport R, et al. Fibrinogen levels during trauma hemorrhage, response to replacement therapy, and association with patient outcomes. *Thromb Haemost*. 2012;10:1342-1351.
21. Wikkelsø A, Lunde J, Johansen M, Stensballe J, Wetterslev J, Møller AM, et al. Fibrinogen concentrate in bleeding patients. *Cochrane Database Syst Rev*. 2013;8:CD008864.
22. Nienaber U, Innerhofer P, Westermann I, Schochl H, Attal R, Breitskopf R, et al. The impact of fresh frozen plasma vs coagulation factor concentrates on morbidity and mortality in trauma-associated haemorrhage and massive transfusion. *Injury*. 2011;42:697-701.
23. Chowdary P, Saayman AG, Paulus U, Findlay GP, Collins PW. Efficacy of standard dose and 30 ml/kg fresh frozen plasma in correcting laboratory parameters of haemostasis in critically ill patients. *Br J Haematol*. 2004;125:69-73.
24. Khan S, Brohi K, Chana M, Raza I, Stanworth S, Gaarder C, et al. Hemostatic resuscitation is neither hemostatic nor resuscitative in trauma hemorrhage. *J Trauma Acute Care Surg*. 2014;76:561-567 [discussion: 567-568].
25. Chambers LA, Chow SJ, Shaffer LE. Frequency and characteristics of coagulopathy in trauma patients treated with a low- or high-plasma-content massive transfusion protocol. *Am J Clin Pathol*. 2011;136:364-370.

Conflict of interest statement: The authors declare that the article content was composed in the absence of any commercial or financial relationships that could be construed as a potential conflict of interest.

Received 22 December 2015; accepted 17 February 2016

Citation: World Neurosurg. (2016).

<http://dx.doi.org/10.1016/j.wneu.2016.02.077>

Journal homepage: www.WORLDNEUROSURGERY.org

Available online: www.sciencedirect.com

1878-8750/\$ - see front matter © 2016 Elsevier Inc.

All rights reserved.