

Choreic Syndrome Secondary to a Subdural Hematoma

Michele Pistacchi, MD,* Manuela Gioulis, MD,† and Sandro Zambito Marsala, MD‡

Key Words: choreic syndrome, subdural hematoma, involuntary movements

(*The Neurologist* 2016;21:32–33)

The etiology of chorea is heterogeneous,¹ however, chorea associated with chronic subdural hematoma (SDH) is rare.^{2–5} We report a patient with bilateral chorea associated with chronic SDH which was surgically treated.

CASE REPORT

A 76-year-old woman with previous history of seronegative rheumatoid arthritis treated with hydroxychloroquine was admitted later, with the onset about a month earlier of bilateral involuntary movements and mental confusion. Initially, the patient showed especially fidgeting and irritability that preceded the development of the movement disorders. With time, chorea highlights with hyperkinetic movements, such as myoclonic jerks and dystonia at the head, first left upper and lower limb and then in all extremities. Objective neurological examination performed at the admission in our department showed a good state of space-time orientation, good ability to perform calculations, and no praxis disorders. However, in about a month, we observed severe axial choreic involuntary movements, first left upper and lower limb and then in all 4 limbs. Brain computed tomography (CT) scan showed the presence of a layer of subdural chronic-type hematoma with contralateral shift of the midline of about 12 mm with slight herniation of the right cerebellar tonsil in the right fronto-temporoparietal cortex (Fig. 1). One day later she underwent a small temporoparietal craniotomy, incision of the dura mater with blood leakage at high pressure. At the end of surgery, progressive reexpansion of the brain was rapidly highlighted. Within a few days, involuntary movements were completely regressed to achieve a complete normalization of the clinical neurological examination. Another brain CT scan performed 1 month later was normal (Fig. 2).

DISCUSSION

The presence of choreic syndrome secondary to an SDH is rare but not that uncommon. It is possible that the cause is the high-pressure load to the basal nuclei in a possible anomaly of neurotransmitters and possibly also because of transient ischemia that the high hematoma pressure may cause.^{4,6–9} In fact the high pressure may lead to a severe compression and

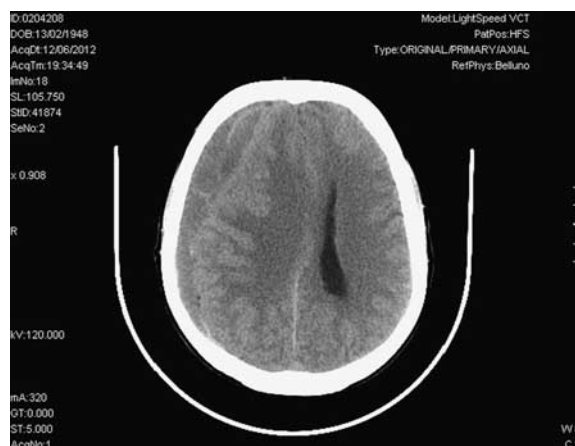

FIGURE 1. First brain computed tomography.

distortion of the encephalon and subcortical structures, in particular, the caudate.

The mechanism responsible of parkinsonism in chronic SDH patients is not well understood. Various hypotheses may be argued including mechanical pressure on the basal ganglia, either directly from the overlying hematoma or indirectly by torsion or displacement of the brain structure¹⁰; midbrain compression caused by the uncus herniation through the tentorial notch¹¹; decreased number of dopaminergic receptors in the striatum secondary to mechanical pressure¹²; and finally, circulatory disorders within the basal ganglia as a consequence of displacement and compression of the anterior choroidal artery.⁴

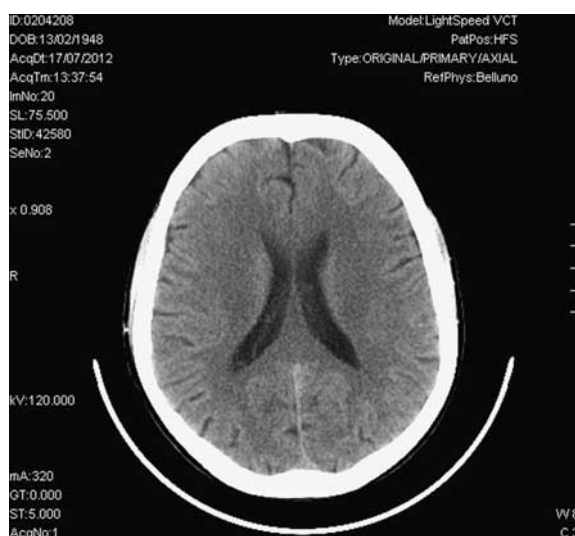


FIGURE 2. Second brain computed tomography.

From the *Neurology Service, Santorso Hospital, Hight Vicentino, Santorso; and †Neurology Service, Department of Neurology, San Martino Hospital, Belluno, Italy.

Informed consent was obtained from all individual participants included in the study.

The authors declare that they acted in accordance with ethical standards laid down in the 1964 Declaration of Helsinki.

The authors declare no conflict of interest.

Reprints: Michele Pistacchi, MD, Neurology Service, Santorso Hospital, via Garziere 73, Santorso 36014, Italy. E-mails: michelepistacchi@yahoo.it; michele.pistacchi@ulss4.veneto.it.

Copyright © 2016 Wolters Kluwer Health, Inc. All rights reserved.

ISSN: 1074-7931/16/2102-0032

DOI: 10.1097/NRL.0000000000000073

We therefore concluded that in our patient irration was decreased to nearly critical level within the right cerebral hemisphere as suggested by brain CT inducing bilateral circulation dysfunction resulting in bilateral hemicorea.

This may be the explanation of the pathophysiological basis of a choreic syndrome secondary to a subdural chronic hematoma whose gravity either unilateral or bilateral, probably depends on the volume and the pressure that the blood exerts on the subcortical structures. Indeed, neuroimaging is always needed to be performed, initially with a simple brain CT scan, to study a choreic syndrome, especially if the clinical picture is characterized by acute or subacute onset without familiarity.

ACKNOWLEDGMENTS

The authors would like to thank San Martino Hospital, Belluno, Italy.

REFERENCES

- Greenhouse A. On chorea, lupus erythematosus, and cerebral arteritis. *Arch Intern Med (Chicago)*. 1966;117:389–393.
- Bae SH, Vates TS Jr, Kenton EJ III. Generalized chorea associated with chronic subdural hematomas. *Ann Neurol*. 1980;8:449–450.
- Bean SC, Ladisch S. Chorea associated with a sub dural hematoma in a child with leukemia. *J Pediatr*. 1977;90:255–256.
- Kotagal S, Shuter E, Horenstein S. Chorea as a manifestation of bilateral subdural hematoma in an elderly man. *Arch Neurol*. 1981;38:195.
- Vincent FM. Chorea: a late complication of a sub dural hematoma. *Neurology (NY)*. 1980;30:335–336. Letter to the editor.
- Young VE, Pickett G, Richardosn PL, et al. Choreathetoid movement as an unusual presentation of subdural haematoma. *Acta Neurochir (Wien)*. 2008;150:733–735.
- Sung YF, Ma HI, Hsu YD. Generalized chorea associated with bilateral chronic subdural hematoma. *Eur Neurol*. 2004;51:227–230.
- Yoshikawa M, Yamamoto M, Shibata K, et al. Hemichorea associated with ipsilateral chronic subdural hematoma—case report. *Neurol Med Chir (Tokyo)*. 1992;32:769–772.
- Gilmore PC, Brenner RP. Chorea: a late complication of a subdural hematoma. *Neurology*. 1979;29:1044–1045.
- Sandyk R, Kahn I. Parkinsonism due to subdural hematoma. Case report. *J Neurosurg*. 1983;58:298–299.
- Schisano G, Cimino R, Schonause M. Ematoma subdurale cronico a sintomatologia extrapiramidale acuta [Chronic subdural hematoma with acute extrapyramidal symptoms]. *Rass Int Clinterap*. 1970;50:898–901.
- Garcia de Yebenes J, Gervas JJ, Iglesias J, et al. Biochemical findings in a case of parkinsonism secondary to brain tumor. *Ann Neurol*. 1982;11:313–316.