

Authors:

Sung Ho Jang, MD
Woo Hyuk Jang, MS

Affiliations:

From the Department of Physical Medicine and Rehabilitation, College of Medicine, Yeungnam University, Daemyungdong, Namku, Daegu, Republic of Korea.

Correspondence:

All correspondence and requests for reprints should be addressed to: Woo Hyuk Jang, MS, Department of Physical Medicine and Rehabilitation, College of Medicine, Yeungnam University 317-1, Daemyungdong, Namku, Daegu, 705-717, Republic of Korea.

Disclosures:

Financial disclosure statements have been obtained, and no conflicts of interest have been reported by the authors or by any individuals in control of the content of this article.

Editor's Note:

Supplemental digital content is available for this article. Direct URL citations appear in the printed text and are provided in the HTML and PDF versions of this article on the journal's Web site (www.ajpmr.com).

0894-9115/16/0000-0000

American Journal of Physical Medicine & Rehabilitation

Copyright © 2016 Wolters Kluwer Health, Inc. All rights reserved.

DOI: 10.1097/PHM.0000000000000483

www.ajpmr.com

Apraxia

CASE REPORT

Ideomotor Apraxia Due to Injury of the Superior Longitudinal Fasciculus

A Case Report

ABSTRACT

Jang SH, Jang WH: Ideomotor apraxia due to injury of the superior longitudinal fasciculus: a case report. *Am J Phys Med Rehabil* 2016;00:00–00.

We report on a patient who showed ideomotor apraxia due to injury of the superior longitudinal fasciculus following brain tumor and tumor bleeding, which was demonstrated by diffusion tensor tractography (DTT). A 60-yr-old, right-handed male patient underwent removal of brain meningioma and drainage of intraventricular hemorrhage and intracerebral hemorrhage in the left fronto-parietal lobe. At the time of DTT scanning (5 wk after onset), he was able to move the right upper extremity against gravity. The patient exhibited an intact ideational plan for motor performance. In addition, he was able to use actual objects (scissors, eraser) using his right wrist and hand. However, he had difficulty in using his right upper extremity for pantomime of object use, imitating gestures (meaningless or meaningful), and movement of his right upper extremity proximal. Score on the ideomotor apraxia test for the right side was 4 (cut-off score < 32). DTTs for the left superior longitudinal fasciculus to the left premotor cortex and left inferior parietal lobule showed partial injury, compared with the right superior longitudinal fasciculus. These injuries appeared to be the reason for ideomotor apraxia in this patient.

Key Words: Diffusion Tensor Imaging, Ideomotor Apraxia, Superior Longitudinal Fasciculus, Premotor Cortex, Inferior Parietal Lobe

Apraxia is defined as failure to correctly perform skilled, purposeful movement.¹ In 1920, Liepmann described three types of limb apraxia: ideational apraxia, ideomotor apraxia (IMA), and limb-kinetic apraxia.^{1–3} Among three types of limb apraxia, IMA is defined as a disturbance in selection of movement elements without a deficit in the conception of movements.⁴ Pathogenetic mechanism of IMA is known to occur when the following area or pathway was injured: the inferior parietal lobule (IPL) in the dominant hemisphere, premotor cortex (PMC) in the dominant hemisphere, corpus callosum to the contralateral PMC from the dominant hemisphere, and the neural connection of the IPL to the PMC in the dominant hemisphere.^{1,5} Among the various neural tracts in the parieto-frontal lobes, injury of the superior longitudinal fasciculus (SLF) is known to be responsible for IMA; however, this has not been clearly elucidated.^{6–8}

Ideomotor Apraxia Due to Injury of the SLF

1

In the current study, we report on a patient who showed IMA due to injury of the SLF following brain tumor and tumor bleeding, which was demonstrated by diffusion tensor tractography (DTT).

CASE REPORT

A 60-yr-old, right-handed male patient underwent removal of brain meningioma and drainage of intraventricular hemorrhage and intracerebral hemorrhage in the left fronto-parietal lobes (Fig. 1A). After 5 wk since the onset, he began to undergo rehabilitation. Brain MRI showed a leukomalactic lesion located in the left hemisphere (particularly frontal and parietal lobe) and centrum semiovale (Fig. 1B).

At the time of DTI scanning (5 wk after onset), the patient was able to move the right upper extremity against gravity. Although the patient showed global aphasia (aphasia quotient [22.4%ile] on Western Aphasia Battery) and severe cognitive impairment with a score of 10 on the Mini-Mental State Exam, he exhibited an intact ideational plan for motor performance and appropriate comprehension skill. In addition, the patient showed the appropriate responses to therapist's humor, and good attention during evaluation. For example, when a scissors was provided, paper cutting was possible using only his right wrist and fingers although the initiation of movement was delayed. However, the patient had

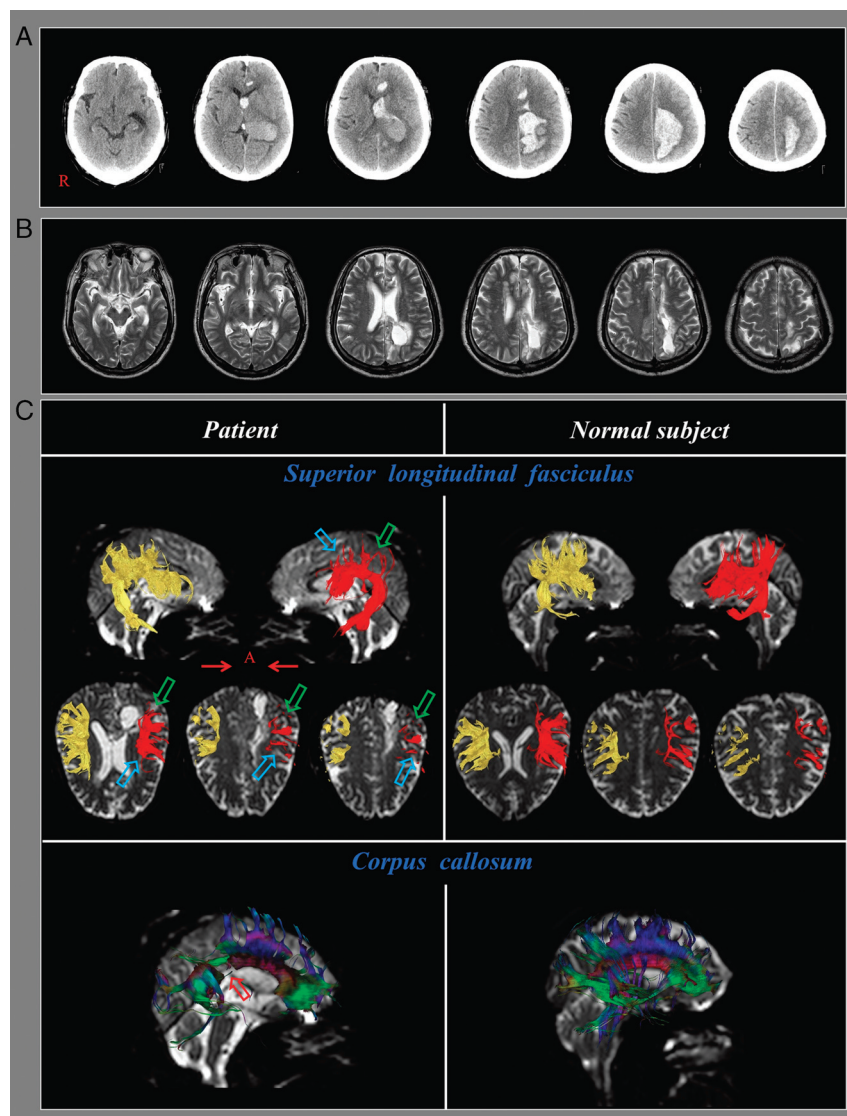


FIGURE 1 A, Brain CT images at the onset show brain meningioma, intraventricular hemorrhage, and intracerebral hemorrhage in the left fronto-parietal lobes. B, T2-weighted brain MR images at 5 wk after onset show a leukomalactic lesion in the left fronto-parietal lobes. C, Diffusion tensor tractography (DTT). The left superior longitudinal fasciculus (red) of the patient shows partial injury in the premotor cortex (sky blue arrow) and inferior parietal lobule (green arrow), and the splenium of the corpus callosum (red arrow) reveals discontinuation compared to a normal subject (58-yr old male patient).

difficulty in using his right upper extremity for pantomime of object use, imitating gestures (meaningless or meaningful), and movement of his right upper extremity proximal part.¹ He was also able to use actual objects (scissors, eraser) using wrist and hand. Score on the ideomotor apraxia test for the right side was 4 (cut-off score < 32).⁹ On the other hand, the patient did not show any abnormality in execution of his left upper extremity. The patient's wife provided signed, informed consent and our institutional review board approved the study protocol.

Diffusion Tensor Imaging

DTI data were acquired one time (5 wk after onset) using a 6-channel head coil on a 1.5 T Philips Gyroscan Intera (Philips, Ltd, Best, the Netherlands) with single-shot echo-planar imaging. For each of the 32 non-collinear diffusion sensitizing gradients, 70 contiguous slices were acquired parallel to the anterior commissure-posterior commissure line. Imaging parameters were as follows: acquisition matrix = 96×96 , reconstructed to matrix = 192×192 matrix, field of view = 240×240 mm², TR = 10,398 ms, TE = 72 ms, parallel imaging reduction factor (SENSE factor) = 2, EPI factor = 59 and $b = 1000$ s/mm², NEX = 1, and a slice thickness of 2.5 mm.

Fiber tracking was performed using the fiber assignment continuous tracking (FACT) algorithm implemented within the DTI task card software (Philips Extended MR Workspace 2.6.3). Each DTI replication was intra-registered to the baseline "b₀" images to correct for residual eddy-current image distortions and head motion effect, using a diffusion registration package (Philips Medical Systems, Netherlands). The termination criteria used for fiber tracking were fractional anisotropy (FA) threshold of >0.15 and a direction threshold of <27°. Affine multi-scale two-dimensional registration was used for correction of head motion effect and image distortion due to eddy current. Fiber tracking was performed using a probabilistic tractography method based on a multifiber model, and applied in the current study utilizing tractography routines implemented in FMRIB Diffusion (5000 streamline samples, 0.5 mm step lengths, curvature thresholds = 0.2). For analysis of the SLF, the seed region of interest (ROI) was placed on the triangular shape just lateral to the corticospinal tract near the anterior horn of the lateral ventricle reticular formation of the medulla, and the target ROI was placed on the triangular shape near the posterior horn of the lateral ventricle.¹⁰⁻¹² Fiber tracts passing through both ROIs were designated as the final tracts of

interest. For analysis of the transcallosal fibers, ROI was placed on the entire corpus callosum on sagittal fractional anisotropy color maps.¹³ The termination criteria used for fiber tracking were fractional anisotropy (FA) threshold of >0.15 and a direction threshold of <27°. The left SLF fibers to the left PMC and left IPL showed partial injury (Fig. 1C). In addition, the transcallosal fibers revealed discontinuation mainly in the splenium of the corpus callosum.

DISCUSSION

Based on the following reasons, it appeared that this patient had IMA: (1) intact ideational plan for object use, (2) clinical features of IMA: difficulty in pantomime of object use, difficulty in imitating gestures (meaningless or meaningful), actual object use easier than pantomime or imitation, and delay in the initiation of movement, and (3) abnormal score on the ideomotor apraxia test: 4 (cut-off score < 32).¹⁻⁵ Previous studies have reported that the PMC and IPL are very relevant to IMA.^{1,14,15} First, the PMC plays an important role in adapting the motor planning so that the upper extremity can perform functional movements, whereas the primary motor cortex is relevant to simple movements. Therefore, the problem of PMC function causes difficulty in production of skillful movement. Second, the IPL is relevant to "representational hypothesis" among hypotheses explaining the IMA.¹ The "representational hypothesis" is that the nervous system stores knowledge of the learned and skilled acts, and when this knowledge is required to program a skilled act, these movement representations are retrieved from storage rather than new learning. As a result, the IPL is regarded as the critical area of movement representation (or praxicon). In this patient, partial injury of the left SLF to the left PMC and IPL was observed on 5-wk DTT. Therefore, these DTT findings appeared to be consistent with the clinical features of the right side IMA. In addition, the injury of the left PMC also might contribute the right side IMA partly. However, the injury of the corpus callosum appeared not to contribute to the right side IMA because the injury of the corpus callosum is known to cause the left unilateral IMA and our patient did not show any symptom of the left side IMA.^{16,17} Furthermore, the lesion location for the left unilateral IMA is known to be located in the trunk of the corpus callosum which was different with the lesion location (the splenium of the corpus callosum) of our patient.^{16,17}

A few studies on the relationship of the SLF and IMA have been reported.⁶⁻⁸ In 2012, Hong et al. demonstrated partial injury of the upper portion of the left SLF in a patient with IMA following cerebral

infarct.⁸ In 2013, Manuel et al. investigated the relationship between the region and two error types of pantomime (configural/spatial and body-part-as-object) in 150 patients with IMA following stroke and brain tumor using voxel-based lesion-symptom mapping.⁶ They found that the “body-part-as-object” pantomime error type was associated with the SLF. In 2015, Watson and Buxbaum, who studied 31 patients with left hemisphere stroke using voxel-based lesion-symptom mapping,⁷ found that lesions of the supramarginal gyrus, inferior frontal gyrus, and SLF resulted in impairment of use action for conflict tools (tools used and grasped with different hand action such as keyboard, syringe, and stapler).

In conclusion, the association of partial injury of the SLF to the PMC and IPL in the dominant hemisphere with IMA was demonstrated in a patient with brain injury. It seems that DTT would be helpful in demonstrating injury of the SLF in patients with IMA. However, because it is a case report, this study is limited; therefore, conduct of additional complementary studies involving larger case numbers is warranted. In addition, limitation of DTT should be considered: regions of fiber complexity and crossing may cause underestimation of reconstruction of a neural tract.¹⁸

ACKNOWLEDGMENTS

This work was supported by the Medical Research Center Program (2015R1A5A2009124) through the National Research Foundation of Korea (NRF) funded by the Ministry of Science, ICT and Future Planning.

Supplementary Checklist

CARE Checklist: <http://links.lww.com/PHM/A219>

REFERENCES

1. Heilman KM, Valenstein E: *Clinical neuropsychology*. 5th ed. New York: Oxford University Press, 2012
2. Leiguarda RC, Marsden CD: Limb apraxias: higher-order disorders of sensorimotor integration. *Brain* 2000;123(Pt 5):860–79
3. Gross RG, Grossman M: Update on apraxia. *Curr Neurol Neurosci Rep* 2008;8:490–6

4. Ochipa C, Gonzalez Rothi LJ: Limb apraxia. *Semin Neurol* 2000;20:471–8
5. Brazis PW, Masdeu JC, Biller J: *Localization in clinical neurology*. 4th ed. Philadelphia, Pa; London: Lippincott Williams & Wilkins, 2001
6. Manuel AL, Radman N, Mesot D, et al: Inter- and intrahemispheric dissociations in ideomotor apraxia: a large-scale lesion-symptom mapping study in subacute brain-damaged patients. *Cereb Cortex* 2013; 23:2781–9
7. Watson CE, Buxbaum LJ: A distributed network critical for selecting among tool-directed actions. *Cortex* 2015;65:65–82
8. Hong JH, Lee J, Cho YW, et al: Limb apraxia in a patient with cerebral infarct: diffusion tensor tractography study. *NeuroRehabilitation* 2012;30: 255–9
9. De Renzi E, Motti F, Nichelli P: Imitating gestures. A quantitative approach to ideomotor apraxia. *Arch Neurol* 1980;37:6–10
10. Rushworth MF, Behrens TE, Johansen-Berg H: Connection patterns distinguish 3 regions of human parietal cortex. *Cereb Cortex* 2006;16:1418–30
11. Newton JM, Ward NS, Parker GJ, et al: Non-invasive mapping of corticofugal fibres from multiple motor areas—relevance to stroke recovery. *Brain* 2006;129: 1844–58
12. Mayka MA, Corcos DM, Leurgans SE, et al: Three-dimensional locations and boundaries of motor and premotor cortices as defined by functional brain imaging: a meta-analysis. *Neuroimage* 2006;31: 1453–74
13. Chang MC, Yeo SS, Jang SH: Callosal disconnection syndrome in a patient with corpus callosum hemorrhage a diffusion tensor tractography study. *Arch Neurol* 2012;69:1374–5
14. Catani M, Thiebaut de Schotten M: *Atlas of human brain connections*. Oxford: Oxford University Press, 2012
15. Ramachandran VS: *Encyclopedia of the human brain*. Amsterdam; London: Academic Press, 2002
16. Heilman KM, Watson RT: The disconnection apraxias. *Cortex* 2008;44:975–82
17. Bogousslavsky J, Caplan LR: *Stroke syndromes*. 2nd ed. Cambridge; New York: Cambridge University Press, 2001
18. Yamada K, Sakai K, Akazawa K, et al: MR tractography: a review of its clinical applications. *Magn Reson Med* 2009;8:165–74