

# Free-floating thrombus in a stenotic supraclinoid left internal carotid artery

Anil Pandurang Karapurkar,<sup>1</sup> Rakesh Singh,<sup>1</sup> Sanjay Maganbhai Teelala,<sup>1</sup> Rakesh Lalla<sup>2</sup>

<sup>1</sup>Department of Endovascular Neurosurgery, Breach Candy Hospital, Mumbai, Maharashtra, India

<sup>2</sup>Department of Neurology, Chhatrapati Shahaji Maharaj Medical University, Lucknow, Uttar Pradesh, India

## Correspondence to

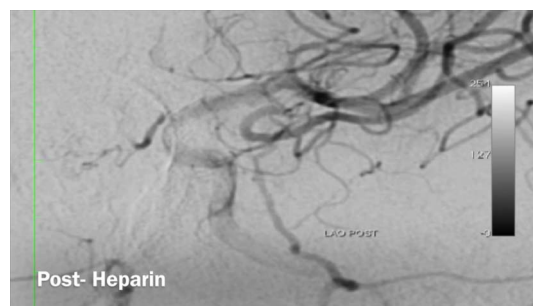
Dr Rakesh Lalla,  
rakesh\_lalla@yahoo.com

Accepted 11 December 2015

## DESCRIPTION

An elderly woman presented with transient ischaemic attack (TIA) followed by aphasia the next day. MRI with angiogram showed watershed infarcts in the left middle and posterior cerebral artery territory and severe focal stenosis of the left supraclinoid internal carotid artery (ICA). She was started on aspirin 150 mg, clopidogrel 75 mg and atorvastatin 40 mg once daily. She persistently had multiple episodes of recurrent TIA despite dual antiplatelet therapy. Hence we planned to carry out digital subtraction angiography (DSA). DSA showed severe focal stenosis in the left supraclinoid ICA with free-floating thrombus (FFT) just distal to stenosis, yo-yoing with each heart beat (video 1). Thus enoxaparin 0.6 mL subcutaneous two times a day was added and continued on a domiciliary basis for 3 weeks. The patient, however, had three episodes of TIA despite being on enoxaparin, dual antiplatelet therapy and statin. DSA repeated at 3 weeks showed complete resolution of the thrombus, with severe residual stenosis, which was finally treated using a Resolute drug-eluting balloon mounted 3 mm×9 mm coronary stent.

FFT is an elongated, pedunculated thrombus with one end attached to the diseased, atherosclerotic arterial wall, and the other end—which keeps yo-yoing inside the artery with each heart beat—free. Most cases of FFT have been diagnosed in cervical ICA and present as medical emergencies. The most common aetiology is atherosclerotic plaque followed by a prothrombotic state, an aneurysm, etc.<sup>1</sup> There are no guidelines for treatment of acute symptomatic intraluminal FFT. There have been some anecdotal reports regarding the use of intravenous heparin in treatment of floating thrombus in cervical ICA.<sup>2</sup>



**Video 1** The video has three parts. (1) Pretreatment showing stenosis of supraclinoid segment of left internal carotid artery (ICA) along with free-floating thrombus (FFT) yo-yoing with each heartbeat. (2) Postheparin showing complete resolution of FFT with stenosis of supraclinoid left ICA. (3) Poststenting, showing complete resolution of stenosis of supraclinoid left ICA.

Ferrero *et al*<sup>3</sup> presented a series of 16 patients with FFT in ICA who were successfully treated with endarterectomy. Tummala *et al*<sup>4</sup> attempted carotid stenting in the presence of thrombus in chronic carotid dissection using flow restriction with the balloon proximal and using overlapping stents to exclude the thrombus from the lumen. La Spada *et al*<sup>5</sup> successfully treated left common carotid thrombus by carotid endarterectomy with Dacron patch angioplasty. In this case, endarterectomy was not possible as the FFT was in the supraclinoid segment. FFT has higher risk of distal embolisation and hence stenting in the acute setting is contraindicated. In our opinion, delayed endovascular intervention for stenosis, once the thrombus is completely resolved, is a safer option in cases of intracranial ICA FFT.

## Learning points

- ▶ There are no clear guidelines in management of free-floating thrombus (FFT), especially intracranial internal carotid artery.
- ▶ In this case, anticoagulation along with aspirin and statin were found to be a safe option for treating FFT.
- ▶ Acute stenting should be avoided as it can lead to distal embolisation during wire, balloon or stent navigation in the vessel.

**Contributors** All the authors contributed to patient management, collection of data and review of the literature and manuscript. The video was prepared by RL and SMT. Revisions of the manuscript were carried out by RL.

**Competing interests** None declared.

**Patient consent** Obtained.

**Provenance and peer review** Not commissioned; externally peer reviewed.

## REFERENCES

- 1 Bhatti AF, Leon LR Jr, Labropoulos N, *et al*. Free-floating thrombus of the carotid artery: literature review and case reports. *J Vasc Surg* 2007;45:199–205.
- 2 Sallustio F, Di Legge S, Marziali S, *et al*. Floating carotid thrombus treated by intravenous heparin and endarterectomy. *J Vasc Surg* 2011;53:489–91.
- 3 Ferrero E, Ferri M, Viazzo A, *et al*. Free-floating thrombus in the internal carotid artery: diagnosis and treatment of 16 cases in a single center. *Ann Vasc Surg* 2011;25:805–12.
- 4 Tummala RP, Jahromi BS, Yamamoto J, *et al*. Carotid artery stenting under flow arrest for the management of intraluminal thrombus: technical case report. *Neurosurgery* 2008;63(1 Suppl 1): ONSE87–8; discussion ONSE88.
- 5 La Spada M, Stilo F, Barilla D, *et al*. A big floating thrombus in the common carotid artery. *J Cardiovasc Med (Hagerstown)* 2011;12:819–20.



**To cite:** Karapurkar AP, Singh R, Teelala SM, *et al*. *BMJ Case Rep* Published online: [please include Day Month Year] doi:10.1136/bcr-2015-213067

Copyright 2016 BMJ Publishing Group. All rights reserved. For permission to reuse any of this content visit <http://group.bmj.com/group/rights-licensing/permissions>.  
BMJ Case Report Fellows may re-use this article for personal use and teaching without any further permission.

Become a Fellow of BMJ Case Reports today and you can:

- ▶ Submit as many cases as you like
- ▶ Enjoy fast sympathetic peer review and rapid publication of accepted articles
- ▶ Access all the published articles
- ▶ Re-use any of the published material for personal use and teaching without further permission

For information on Institutional Fellowships contact [consortiasales@bmjgroup.com](mailto:consortiasales@bmjgroup.com)

Visit [casereports.bmj.com](http://casereports.bmj.com) for more articles like this and to become a Fellow