



Contents lists available at ScienceDirect

Pediatric Neurology

journal homepage: www.elsevier.com/locate/pnu

Topical Review

Hashimoto Encephalopathy Presenting With Stroke-Like Episodes in an Adolescent Female: A Case Report and Literature Review

Brett R. Graham MD^{a,*}, Natalie Shiff MD^b, Munier Nour MD^c, Simona Hasal MD^d, Richard Huntsman MD^d, Salah Almubarak MD^d

^a Department of Medicine, Division of Neurology, University of Saskatchewan, Saskatoon, Saskatchewan, Canada

^b Department of Pediatrics, Division of Rheumatology, University of Saskatchewan, Saskatoon, Saskatchewan, Canada

^c Department of Pediatrics, Division of Endocrinology, University of Saskatchewan, Saskatoon, Saskatchewan, Canada

^d Department of Pediatrics, Division of Neurology, University of Saskatchewan, Saskatoon, Saskatchewan, Canada

ABSTRACT

BACKGROUND: Hashimoto encephalopathy is a rare form of encephalopathy thought to be of autoimmune etiology. Cognitive changes and seizures are the most commonly reported presenting manifestation. Stroke-like episodes have also been documented in these individuals. We describe a rare adolescent with Hashimoto encephalopathy who presented with stroke-like symptoms. **PATIENT DESCRIPTION:** A previously well 15-year-old girl was evaluated after experiencing sudden-onset language disturbance and right hemiparesis. Her symptoms resolved, but weeks later, she began experiencing refractory seizures, episodes of status epilepticus, and cognitive decline. An extensive evaluation was unremarkable, but thyroid peroxidase antibodies were elevated, and a diagnosis of Hashimoto encephalitis was made. Steroid therapy was initiated, and her symptoms resolved with return to baseline cognitive function. **CONCLUSION:** Hashimoto encephalopathy is a highly treatable condition that may be considered in the differential diagnosis of children and adolescents presenting with stroke-like symptoms.

Keywords: Hashimoto encephalopathy, stroke, steroid-responsive encephalopathy, autoimmune encephalopathy, autoimmune thyroiditis

Pediatr Neurol 2016; ■: 1–9

© 2016 Elsevier Inc. All rights reserved.

Introduction

Hashimoto encephalopathy is a rare form of encephalopathy with presumed autoimmune etiology that falls along the spectrum of steroid-responsive encephalopathy associated with autoimmune thyroiditis (SREAT).¹ The first individual with Hashimoto encephalopathy was described by Brain in 1966.² He reported an adult with Hashimoto thyroiditis who experienced fluctuating cognition, refractory epilepsy, and stroke-like episodes. Since

then, most of the documented patients have been adults, but there is a growing literature on Hashimoto encephalopathy in the pediatric population.^{3–5} We describe an adolescent with Hashimoto encephalopathy who presented with stroke-like episodes, presentation that is rare in the pediatric Hashimoto encephalopathy literature. In addition, we present a comprehensive summary of English language full-length reports of pediatric Hashimoto encephalopathy (Table 1).

Patient Description

This 15-year-old previously healthy girl presented to her local hospital with the sudden-onset right hemiparesis and paresthesias accompanied by slurred speech and expressive language difficulties. Sensorimotor symptoms began in the right hand and then, within seconds, progressed to involve the entire right side. All symptoms resolved within 35 minutes. She did not have associated headaches, visual

Conflicts of interest: none.

Article History:

Received December 5, 2015; Accepted in final form February 4, 2016

* Communications should be addressed to: Dr. Graham; Department of Medicine; Division of Neurology; University of Saskatchewan; Room 3544 RUH, 103 Hospital Drive; Saskatoon, Saskatchewan, Canada.

E-mail address: brett.graham@usask.ca

TABLE 1.

Clinical Summary of Hashimoto Encephalopathy in the Pediatric Population

Case Study	Age, Gender	Clinical Onset	Clinical Progression	Investigation	Treatment	Outcome
Hilberath et al. ³	13 F	Weakness, dizziness. Presented with generalized seizure.	Improved rapidly with high-dose steroids and thyroid replacement. EEG normalized with treatment.	Thyroid abs—elevated MRI—normal EEG—slowed background CSF—mild increased protein	IV steroids with oral taper	Favorable
Gul Mert et al. ⁴	13 M	Fatigue, headache, withdrawn. Presented with seizure.	Seizure free after 15 days of steroid therapy.	Thyroid abs—elevated MRI—normal EEG—slowed background and epileptic activity in left occipital area	High-dose oral steroids and thyroid replacement	Favorable
	8 F	Generalized seizure.	Back to baseline at three months with treatment.	Thyroid abs—normal EEG—bioelectric status	IV steroids, plasmapheresis, and IVIG	Favorable
	17 F	Headache and encephalopathy followed by seizures.	Seizure free shortly after treatment initiated.	Thyroid abs—normal MRI—normal EEG—slowed background and epileptiform activity in right occipital region	IV steroids with oral taper, plasmapheresis, and IVIG	Favorable
	11 F	Neuropsychiatric changes, weakness, headache.	Improved quickly after treatment commenced.	Thyroid abs—normal MRI—normal EEG—normal	IV steroids with oral taper	Favorable
Saygi et al. ⁶	12 M	Gradual cognitive decline, acute onset tic disorder		Thyroid abs—elevated MRI—normal EEG—normal	Oral steroids (1 mg/kg) with subsequent taper, thyroid replacement	Favorable
Olmez et al. ⁷	8 F	Neuropsychiatric symptoms, seizure	Improved with treatment but had one relapse.	Thyroid abs—elevated MRI—nonspecific white matter changes EEG—generalized slowing and left temporal epileptiform activity	IV steroids with oral taper, IVIG, and rituximab	Favorable
	2 F	Neuropsychiatric symptoms, confusion	Improved with treatment but had one relapse.	Thyroid abs—elevated MRI—normal EEG—normal	Steroids, IVIG, azathioprine, and rituximab	Favorable
Mamoudjy et al. ⁸	13 F	Neuropsychiatric symptoms	Initially improved but had relapse requiring escalated treatment.	Thyroid abs—elevated MRI—FLAIR hyperintensities in hippocampi	Oral steroids, IV steroids, and cyclophosphamide	Unfavorable Persistent learning disability
	11 F	Tremor, dystonia, seizure		Thyroid abs—elevated MRI—normal	IVIG	
	13 F	Headache, tremor, seizure, encephalopathy		Thyroid abs—elevated MRI—normal	IV steroids and cyclophosphamide	
	10 F	Cerebellar symptoms, behavioral changes		Thyroid abs—elevated MRI—white matter lesions involving the brainstem and deep gray matter	IV steroids and cyclophosphamide	Unfavorable Persistent cognitive changes and tremor
	12 F	Seizures, confusion, left motor deficit		Thyroid abs—elevated MRI—normal	IV steroids and azathioprine	
	15 F	Seizure, confusion, hallucinations		Thyroid abs—elevated MRI—FLAIR hyperintensities in hippocampi	IV steroids	Unfavorable Persistent cognitive changes
	9 F	Seizures		Thyroid abs—normal MRI—FLAIR juxtacortical white matter hyperintensities		
	11 F	Seizures, encephalopathy, hallucinations		Thyroid abs—elevated MRI—normal	IV steroids, methotrexate, rituximab, and azathioprine	Unfavorable Persistent hand tremors and headaches
Arya et al. ⁹	11 F	Myoclonus, encephalopathy, seizures		Thyroid abs—elevated MRI—mild cerebral atrophy EEG—generalized slowing and	High-dose oral steroids with taper	Favorable Back to baseline

(continued on next page)

TABLE 1. (continued)

Case Study	Age, Gender	Clinical Onset	Clinical Progression	Investigation	Treatment	Outcome
Salpietro et al. ¹⁰	13 F	Fever, headache, sleepiness	Started having hallucinations and developed a peripheral polyneuropathy before treatment.	generalized spike and wave discharges CSF—normal Thyroid abs—elevated MRI—initially normal but repeat showed multiple T2/FLAIR lesions in the deep gray matter EEG—diffuse background slowing CSF—oligoclonal bands positive	IV steroids, IVIG	Favorable
Zimmermann and Stranzinger ¹¹	11 F	Headache, sensory disturbance, and left-sided weakness	Symptoms resolved 5 days after treatment.	Thyroid abs—elevated MRI—diffusion restriction in right thalamus and internal capsule CSF—normal	IV steroids with oral taper	Favorable
Bektas et al. ¹²	12 M	Headache, right focal seizure	Continued seizure activity until plasmapheresis initiated.	Thyroid abs—elevated MRI—normal CSF—normal EEG—burst suppression and focal and generalized epileptiform discharges	IVIG, plasmapheresis, and oral prednisone	Favorable
Erol et al. ¹³	9 F	Confusion, ataxia	Experienced relapse with initial tapering of steroids.	MRI—normal EEG—slow background	IV steroids with oral taper	Favorable
	15 F	Seizure, encephalopathy		MRI—normal EEG—slow background	High-dose oral steroids	Favorable
	14 F	Seizure, tremor, psychosis		MRI—normal EEG—slow background	IV steroids with oral taper	Favorable
	12 F	Breath-holding spells, behavioral changes		MRI—normal EEG—normal	High-dose oral steroids	Favorable
Shah et al. ¹⁴	13 M	Focal seizure	Experienced relapse with initial tapering of steroids.	Thyroid abs—elevated MRI—normal EEG—background suppression CSF—normal	IV steroids with oral taper	Favorable
Berger et al. ¹⁵	11 M	Seizures, cognitive decline	Responded well to IVIG. Will have recurrent seizures if a dose of IVIG missed.	Thyroid abs—elevated MRI—normal EEG—right temporal epileptiform discharges	IV steroids with oral taper, IVIG	Favorable
Castro-Gago et al. ¹⁶	2.8 F	Language deterioration, ataxia	Complete recovery after 4 weeks of steroids	Thyroid abs—elevated MRI—normal EEG—diffuse slowing CSF—normal	IV steroids with oral taper	Favorable
Hoffmann et al. ¹⁷	6 F	Generalized seizure, neuropsychiatric symptoms	Quick response to steroid therapy.	Thyroid abs—elevated MRI—normal EEG—electrographic seizures CSF—elevated protein	IV steroids with oral taper	Favorable
Bismilla et al. ¹⁸	11 F	Seizure, encephalopathy	Continued to have relapses until steroids initiated.	Thyroid abs—elevated MRI—FLAIR white matter hyperintensities EEG—generalized slowing CSF—elevated protein	Oral steroids and risperidone	Favorable
Ray et al. ¹⁹	12 M	Confusion, hyperkinetic behavior	Started having generalized seizures before the start of treatment.	Thyroid abs—elevated MRI—normal EEG—slow background with bitemporal spikes CSF—normal	Thyroid replacement and carbamazepine	Favorable
Mancardi et al. ²⁰	11 F	Confusion, psychomotor instability	Initially improved with mannitol but relapsed thereafter	Thyroid abs—elevated MRI—initially normal but then showed contrast-enhancing lesion in left nucleus accumbens EEG—diffuse slowing CSF—normal	High-dose corticosteroids (route not mentioned) with taper	Favorable
Byrne et al. ²¹	14 F	Confusion, memory problems, generalized	Had multiple relapses before the start of steroids	Thyroid abs—elevated MRI—normal	Oral steroids (1 mg/kg) with taper	Favorable

(continued on next page)

TABLE 1. (continued)

Case Study	Age, Gender	Clinical Onset	Clinical Progression	Investigation	Treatment	Outcome
Sybesma et al. ²²	12 F	seizure with subsequent hemiplegia Headaches, emotionally labile, seizure	Had one relapse with steroid taper	EEG—diffuse slowing CSF—elevated protein Thyroid abs—elevated MRI—normal	Oral steroids with taper	Unfavorable Persistent cognitive difficulties and right hemiparesis
	12 F	Unconsciousness, headache, status epilepticus	Clinical picture initially deteriorated on thyroid replacement therapy.	EEG—diffuse slowing but more prominent in left hemisphere CSF—normal Thyroid abs—elevated MRI—normal EEG—generalized slowing CSF—mild elevation of protein	Thyroid replacement	Favorable
Vasconcellos et al. ²³	16 F	Generalized seizure	Intractable seizures and hallucinations prior to treatment.	Thyroid abs—elevated MRI—normal EEG—routine normal but telemetry showed bitemporal seizures CSF—normal	IV steroids with oral taper Carbamazepine	Favorable
Balestri et al. ²⁴	8 F	Attention deficit, hyperactivity, cognitive decline	Symptoms progressively worsened before the treatment	Thyroid abs—elevated	Oral steroids with subsequent taper	Unfavorable Symptoms have improved but not back at cognitive baseline
	14 M	Fever, confusion, seizure, alternating hemiplegia	Symptoms slowly improved with treatment.	Thyroid abs—elevated MRI—normal EEG—generalized slowing CSF—normal	Flunarizine (for query alternating hemiplegic migraine) and levothyroxine	Favorable

Abbreviations:

CSF = Cerebrospinal fluid

EEG = Electroencephalography

IVIG = Intravenous immunoglobulin

MRI = Magnetic resonance imaging

changes, nausea, or vomiting. She denied any stimulus sensitivity. There was no history of preceding head or neck trauma, associated head or neck pain, or preceding infections.

Past medical history was unremarkable. Specifically, she denied previous episodes of migraine headache, stroke, seizure, or venous thrombosis. She was taking no medications, and immunizations were up-to-date. Family history was not significant for neurological disease or thrombophilias. There were no developmental concerns, and she had excellent school performance before the onset of symptoms.

She was transferred to a tertiary care pediatric center, where she was normothermic and her vital signs were stable. Neurological examination, including fundoscopy, was normal. Cardiac and general examinations were normal. A noncontrast cranial computed tomography (CT) performed shortly after arrival did not show any intracranial pathology. The result of computed tomography angiography was normal. Brain magnetic resonance imaging (MRI), including diffusion-weighted and gradient echo sequences, was normal the following day. Heart rhythm was sinus, and heart structure and function were normal as assessed by transthoracic echocardiography. Thrombophilia workup was negative. A diagnosis of transient ischemic attack was given, and the patient was discharged on antithrombotic medication.

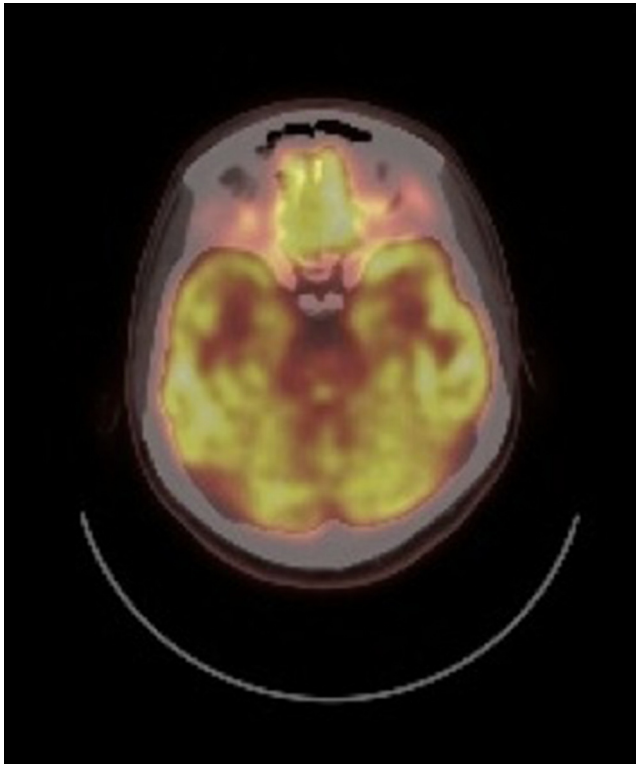
Two weeks later the patient experienced headache, nausea, vomiting, and bilateral lower extremity weakness while at school. The episode was short lived but was followed by a generalized tonic-clonic seizure. She did not have focal or lateralizing findings on neurological examination. Treatment included intravenous benzodiazepines, phenytoin, and eventual intubation and sedation for refractory generalized seizures. The results of another noncontrast cranial CT and brain MRI and MRV were normal. Routine blood work including coagulation factors was normal. Repeat transthoracic echocardiogram with agitated saline bubble test showed no right-to-left shunt. Thyroid-stimulating hormone was elevated at 5.29 mIU/L (N 0.44 to 3.98 mIU/L) with a normal free T4 of 15.4 pmol/L (N 10.0 to 17.1 pmol/L), consistent with subclinical hypothyroidism. Lipid profile was normal. Vasculitic workup was negative including testing for antinuclear antibodies, antidouble-

stranded DNA, extractable nuclear antigens, antineutrophil cytoplasmic antibodies, rheumatoid factor, complements (C3 and C4), and lupus anticoagulant. Erythrocyte sedimentation rate and c-reactive protein were normal. Cerebrospinal fluid (CSF) analysis revealed a slightly elevated protein at 0.77 g/L with only one lymphocyte. Oligoclonal bands were negative. CSF evaluation for infections yielded no positive results. A paraneoplastic panel including PNMA, CV2.1, Ri, Recoverin, SOX1, Titan, Yo, and Hu was negative. An autoimmune limbic encephalitis panel including NMDA, VGKC, GAD65, and AMPA was negative. Routine electroencephalography (EEG) did not show epileptiform activity, and EEG telemetry did not show seizures or epileptiform activity. The patient was discharged home on levetiracetam with a normal neurologic examination.

Repeat thyroid function tests as an outpatient demonstrated worsening thyroid function (thyroid-stimulating hormone, 11.85 mIU/L; free T4, 9.6 pmol/L), and the patient was initiated on levothyroxine replacement.

A subsequent outpatient brain and body positron emission tomography scan showed decreased fludeoxyglucose uptake in the visual cortices bilaterally (Fig 1), which was deemed nonspecific by nuclear medicine. There was no evidence to suggest a body teratoma. A thyroid ultrasound was also performed that showed a heterogeneously enlarged gland with diffuse hyperemia but no focal hypoechoic nodules, consistent with a diagnosis of Hashimoto thyroiditis.

Over the next few months she continued to have generalized tonic-clonic seizures despite the addition of valproic acid and clobazam to her antiepileptic medication regimen. She was again admitted after an episode of prolonged seizure activity that required intubation and sedation. Serum thyroid peroxidase antibody was found to be elevated (>1000 IU/mL; N < 34 IU/mL) with thyroglobulin antibody normal at 37.5 IU/mL (N < 40 IU/mL). Paraneoplastic and autoimmune limbic encephalitis panels were repeated and again were negative. A neuropsychologic assessment at this time showed mild-to-moderate impairment in virtually all domains of functioning including general intellectual ability, language, attention and concentration, visual-spatial

**FIGURE 1.**

PET computed tomography (CT) head showing decreased fludeoxyglucose (FDG) uptake in both occipital lobes. PET = positron emission tomography. (The color version of this figure is available in the online edition.)

ability, learning and memory, visual–spatial integration and processing speed, and executive functioning. A repeat EEG showed mild slowing of background activity and several brief nocturnal episodes of generalized rhythmic activity thought to be suspicious for electrographic seizure (see Fig 2A–E for a chronological summary of EEGs).

She was given a working diagnosis of Hashimoto encephalopathy and methylprednisolone 1 g IV daily was given for five days followed by oral prednisone at 1 mg/kg with subsequent taper. There was no further overt seizure activity, and she was eventually discharged home on valproic acid, clobazam, phenytoin (eventually discontinued), and levothyroxine.

After the initiation of steroids the patient has had no further stroke-like episodes or seizures. She continues on valproic acid and clobazam with hopes of eventual discontinuation. An informal report from her school roughly 2 months after discharge indicated that her school performance was improving. Repeat neuropsychologic testing performed approximately four months after starting steroids showed normal functioning in all domains. She returned to school and community activities and reports no limitations in her abilities when compared with her functioning before the onset of her illness.

Literature review

MEDLINE and PubMed were searched for full case English language Hashimoto encephalopathy reports using the terms “Hashimoto or autoimmune thyroiditis,” “encephalopathy,” and “child/children.” We did not include cases only described in abstracts or with limited clinical information. In addition, cases with unclear diagnoses were excluded. Twenty articles describing 36 patients were found, and clinical summaries of these cases are provided in Table 1.

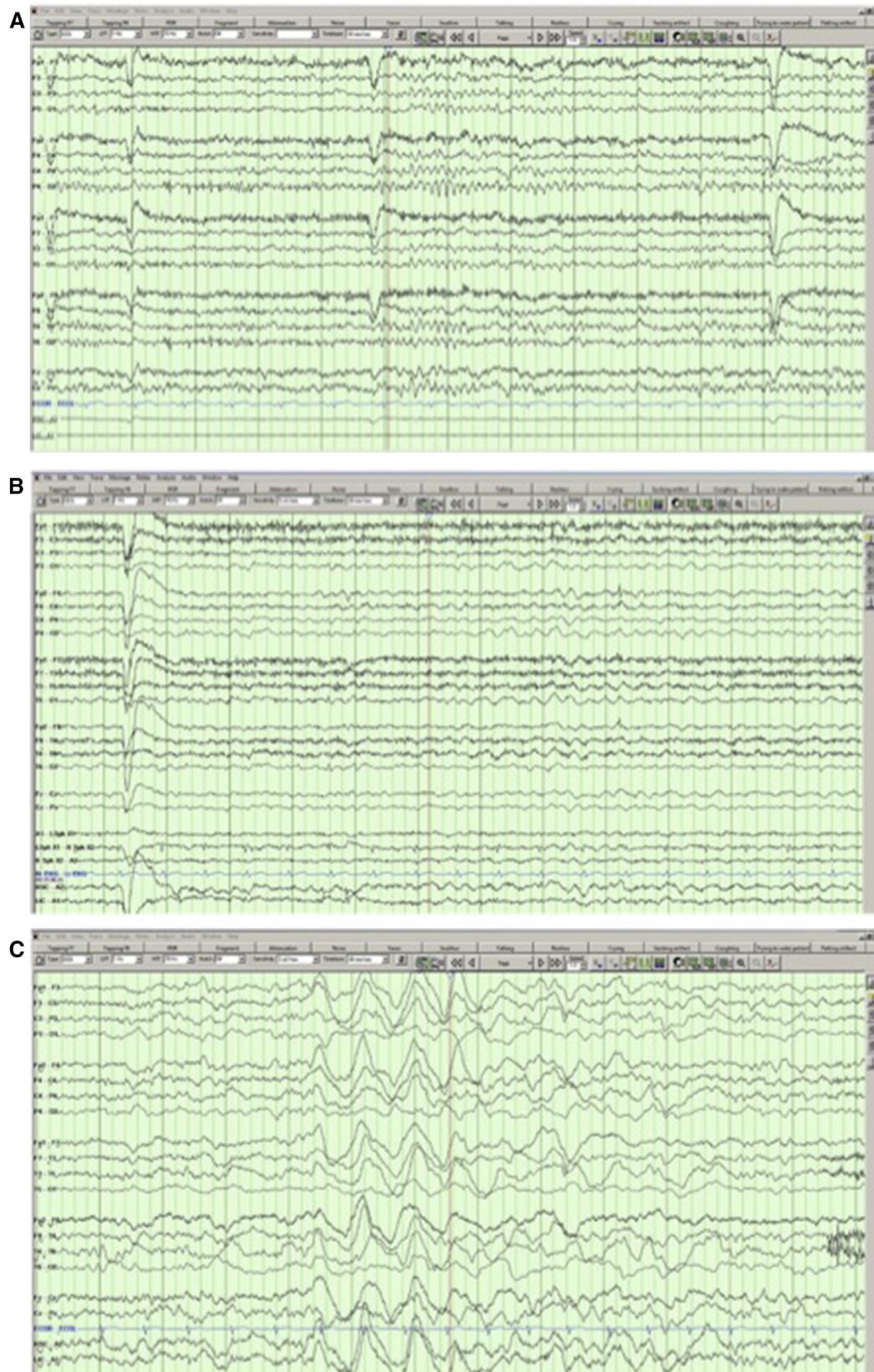
Discussion

Hashimoto encephalopathy is a rare form of acquired autoimmune encephalopathy. The overall incidence of the disease is reported at 2.2/100,000.²⁵ A female preponderance is found in both the adult and pediatric literature, with recorded cases occurring up to five times more commonly in females than that in males.²⁶ The average age of onset is 45 to 55 years,²⁷ but the youngest reported patient was age two years and ten months.²⁸

Clinically, Hashimoto encephalopathy can present with a myriad of symptoms, the most frequent being cognitive changes and seizures.²⁶ This is true in both the adult and pediatric populations.^{5,27} Stroke-like episodes are present in 25% of adult cases²⁹ but are less frequent in the pediatric population²¹ and as evident by the clinical summaries in Table 1 very rarely as a presenting feature. Seizures tend to be refractory to treatment and episodes of status epilepticus have been reported in a minority of cases.³⁰ Two distinct clinical presentations have been described: a “vasculitic” subtype and an indolent progressive subtype.³¹ The vasculitic subtype is characterized by intermittent acute to subacute onset of symptoms, including stroke-like episodes, seizures, and confusion, usually with some degree of improvement between episodes. The indolent progressive subtype is characterized by gradually worsening cognitive and neuropsychiatric performance and without any definite relapses.

Zimmerman and Stranzinger¹¹ described an 11-year-old girl with sudden-onset headache and left-sided sensorimotor symptoms who also exhibited a diffusely enlarged thyroid gland and elevated thyroid peroxidase antibodies. MRI brain with diffusion-weighted imaging showed a hyperintense lesion in the right thalamus. The patient was treated with an antiplatelet agent and high-dose steroid regimen with resolution of all symptoms in five days after treatment initiation. The authors attribute the ischemic stroke to SREAT and resolution of symptoms due to steroid therapy. However, the enlarged thyroid and antibodies were found incidentally, and no note is made of clinical encephalopathy. Furthermore, an extensive workup to rule out any other underlying etiology of the stroke was not reported; therefore, a diagnosis of SREAT in this case was not conclusive.

The pathogenesis of Hashimoto encephalopathy remains poorly understood. In spite of being associated with anti-thyroid antibodies, there is no relationship between thyroid function and disease course in this condition.^{4,5,26} Indirect evidence supports autoimmunity as a possible mechanism of Hashimoto encephalopathy. First, autoantibodies to thyroid antigens are present and may have some degree of cross-reactivity in the central nervous system³²; however, these antibodies are found without associated neurological manifestations in approximately 10% of the general population.³ Second, response to immunosuppressive medications, such as steroids and IVIG,³³ is common. Third, antithyroid antibodies have been found in the CSF³⁴ of Hashimoto encephalopathy patients as have oligoclonal bands,³⁵ suggesting intrathecal immunoglobulin production. Fourth, females are more frequently affected, an observation consistent with other autoimmune diseases.³ Finally, Hashimoto encephalopathy is commonly associated with other autoimmune conditions such as Behcet’s disease.³⁶

**FIGURE 2.**

(A) The first electroencephalography (EEG) performed during wakefulness when the patient was not encephalopathic. Notice the normal background and lack of epileptiform activity. (B) The second EEG performed during wakefulness showing diffuse slowing of background but no epileptiform activity. The patient was becoming intermittently encephalopathic at this stage. (C) EEG performed during an acute confusional state. Notice the diffusely slow background and burst of high amplitude rhythmic delta. (D) EEG performed during sleep. Predominantly frontal, rhythmic activity can be observed in the second half of the epoch that is suspicious for an electrographic seizure. (E) Repeat EEG during wakefulness performed 6 months after the initiation of steroids. Notice the normal background and lack of epileptiform activity. (The color version of this figure is available in the online edition.)

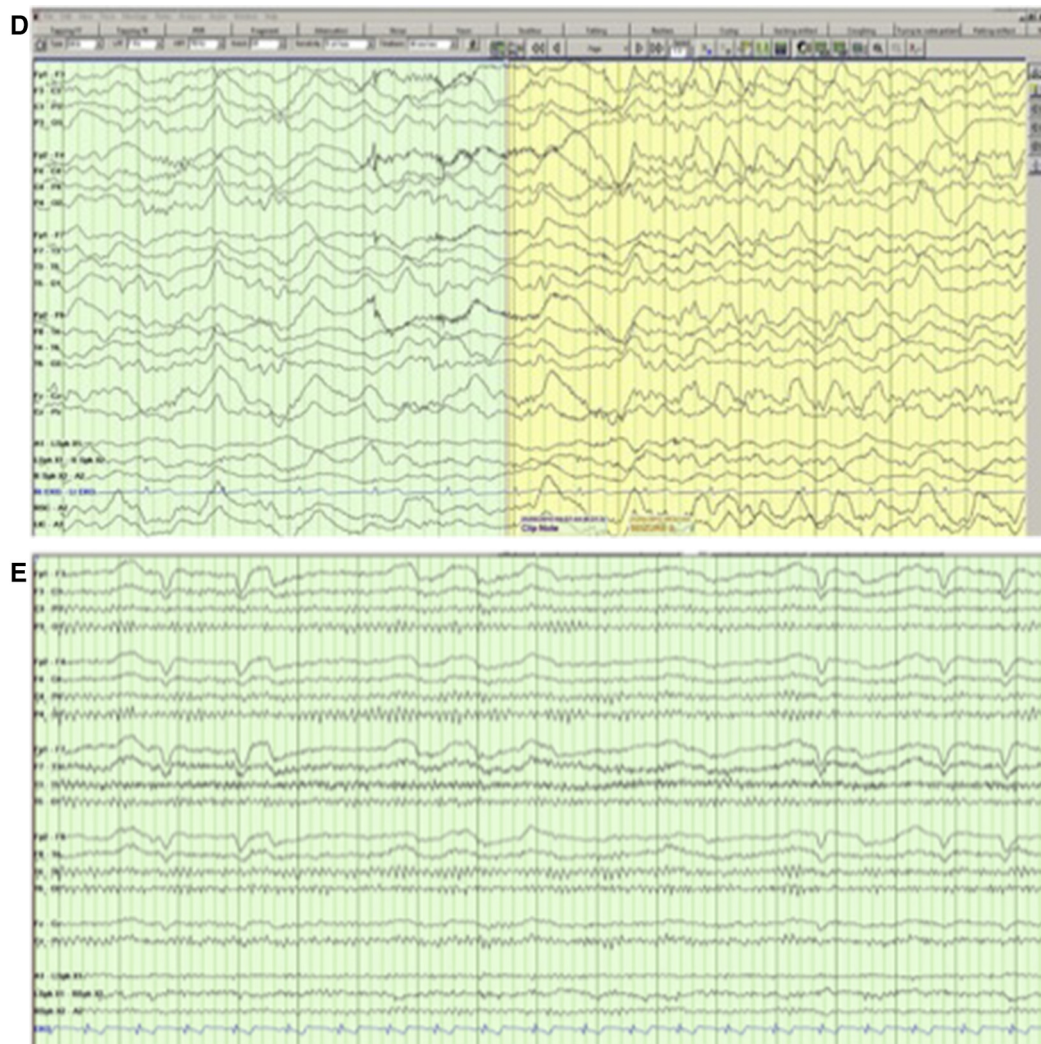


FIGURE 2. (CONTINUED).

A vasculitic etiology has also been proposed as lymphocytic infiltration has been found in brainstem veins³⁷ and arterial walls³⁸ on autopsy and brain biopsy, respectively. Interestingly, the autoantigen alpha-enolase has been found in the serum of patients with Hashimoto encephalopathy and may represent a possible pathogenic mechanism.⁵ Alpha-enolase cross-reacts with both thyroid and brain tissue and is expressed by endothelial cell walls, which potentially could lead to damage or disruption of cerebral vasculature.^{3,5} However, alpha-enolase has been found in patients with other types of encephalitis and autoimmune disorders and therefore may not be specific to Hashimoto encephalopathy.³⁹

The diagnosis of Hashimoto encephalopathy is one of exclusion. The differential diagnosis of fluctuating encephalopathy is broad,²⁷ as is the case for stroke-like episodes and seizures. Owing to the heterogeneity of presentation, Hashimoto encephalopathy is thought to be underdiagnosed in the pediatric population.³ However, in the right clinical setting with exclusion of other potential etiologies, a diagnosis can be suspected. Diagnostic criteria have been purposed by Chong et al.²⁶ and

Mocellin et al.²⁷ and include the presence of neuropsychiatric disturbances, abnormally elevated serum thyroid antibodies (the presence of these antibodies in the CSF can also be helpful), exclusion of other possible etiologies, and good response to steroid therapy. Interestingly, serum antibody levels do not coincide with disease activity or severity.^{5,33}

Aside from abnormally elevated thyroid antibodies, laboratory, neuroimaging, and neurophysiologic investigations are usually nonspecific. Elevated protein can be found in the CSF in a majority of patients,^{5,26} and mild lymphocytic pleocytoses have been reported.^{5,40} Thyroid antibodies have also been found in the CSF.³⁴ EEG is almost always abnormal, with generalized slowing being the rule in the pediatric population.^{3-5,26,27} The degree of background slowing appears to correlate with the severity of encephalopathy clinically.²⁷ Focal slowing and periodic lateralized epileptiform discharges have rarely been described in pediatric cases.⁵ Neuroimaging is normal in approximately two thirds of pediatric cases and when abnormal is nonspecific.^{3,5} SPECT can show different degrees of hypoperfusion but in no consistent pattern.^{3,5}

Immunosuppressive therapy with corticosteroids is the mainstay of the treatment of Hashimoto encephalopathy. Indeed, responsiveness to steroids has been included in the diagnostic criteria.^{3,5} High-dose steroid regimens are usually implemented followed by tapering of the medication.³¹ No randomized control trials have been performed, though, so the best steroid dosage and duration are not known.³ Improvement is usually seen between four and six weeks,^{3,27} and steroids are continued for one to two years.⁵ Other immunosuppressive agents have been used in addition to or instead of corticosteroids and include azathioprine, cyclophosphamide, and methotrexate.^{3,27} Intravenous immunoglobulin and plasmapheresis have also been used in both the adult and pediatric populations with clinical benefit.^{12,15,27} Relapses occur in approximately one third of pediatric patients and may prompt medication dosage escalation or change.³ Thyroid hormone replacement may be indicated.^{4,5} Interestingly, we noticed that our patient was exquisitely sensitive to the adverse effects of IV benzodiazepines, leading to intubation and intensive care monitoring. In light of this, we suggest that further observation and precaution is indicated in similar patients before administering parenteral benzodiazepines.

Conclusion

We describe an unusual child with Hashimoto encephalopathy who presented with stroke-like symptoms and later developed fluctuating encephalopathy, refractory seizures, and multiple episodes of status epilepticus. Serum thyroid antibodies were elevated, and a myriad of other potential structural, infectious, autoimmune, metabolic, and neoplastic causes were ruled out. Other tests, including CSF analysis, brain imaging, and positron emission tomography scan, were nonspecific. Treatment with antiepileptic medications was only temporarily successful in abating seizure activity. It was only with the addition of corticosteroids that we saw the cessation of stroke-like episodes and seizures and complete resolution of cognitive issues as evident by repeat neuropsychologic testing. Electroencephalography became progressively more encephalopathic before steroid therapy and normalized thereafter. Given the excellent therapeutic response to immunosuppression, Hashimoto encephalopathy should be included in the differential diagnosis of children and young adults presenting with stroke-like episodes.

References

- Mahmud FH, Lteif AN, Renaud DL, Reed AM, Brands CK. Steroid-responsive encephalopathy associated with Hashimoto's thyroiditis in an adolescent with chronic hallucinations and depression: case report and review. *Pediatrics*. 2003;112(3 Pt 1):686-690.
- Brain L, Jellinek EH, Ball K. Hashimoto's disease and encephalopathy. *Lancet*. 1966;2:512-514.
- Hilberath JM, Schmidt H, Wolf GK. Steroid-responsive encephalopathy associated with autoimmune thyroiditis (SREAT): case report of reversible coma and status epilepticus in an adolescent patient and review of the literature. *Eur J Pediatr*. 2014;173:1263-1273.
- Gul Mert G, Horoz OO, Herguner MO, et al. Hashimoto's encephalopathy: four cases and review of literature. *Int J Neurosci*. 2014;124:302-306.
- Waternberg N, Greenstein D, Levine A. Encephalopathy associated with Hashimoto thyroiditis: pediatric perspective. *J Child Neurol*. 2006;21:1-5.
- Saygi S, Ozkale Y, Erol I. Tic disorder probably associated with steroid responsive encephalopathy with autoimmune thyroiditis (SREAT). *Indian J Pediatr*. 2014;81:1105-1107.
- Olmez I, Moses H, Sriram S, Kirshner H, Lagrange AH, Pawate S. Diagnostic and therapeutic aspects of Hashimoto's encephalopathy. *J Neurol Sci*. 2013;331:67-71.
- Mamoudjy N, Korff C, Maurey H, et al. Hashimoto's encephalopathy: identification and long-term outcome in children. *Eur J Paediatric Neurol*. 2013;17:280-287.
- Arya R, Anand V, Chansoria M. Hashimoto encephalopathy presenting as progressive myoclonus epilepsy syndrome. *Eur J Paediatric Neurol*. 2013;17:102-104.
- Salpietro V, Mankad K, Polizzi A, et al. Pediatric Hashimoto's encephalopathy with peripheral nervous system involvement. *Pediatr Int*. 2014;56:413-416.
- Zimmermann P, Stranzinger E. Steroid-responsive encephalopathy associated with Hashimoto thyroiditis. *Pediatr Radiol*. 2012;42:891-893.
- Bektas O, Yilmaz A, Kendirli T, Siklar Z, Deda G. Hashimoto encephalopathy causing drug-resistant status epilepticus treated with plasmapheresis. *Pediatr Neurol*. 2012;46:132-135.
- Erol I, Saygi S, Alehan F. Hashimoto's encephalopathy in children and adolescents. *Pediatr Neurol*. 2011;45:420-422.
- Shah SD, Murali H. Steroid-responsive encephalopathy and autoimmune thyroiditis in a young boy. *Pediatr Neurol*. 2011;45:132-134.
- Berger I, Castiel Y, Dor T. Paediatric Hashimoto encephalopathy, refractory epilepsy and immunoglobulin treatment—unusual case report and review of the literature. *Acta Paediatr*. 2010;99:1903-1905.
- Castro-Gago M, Gomez-Lado C, Maneiro-Freire M, Eiris-Punal J, Bravo-Mata M. Hashimoto encephalopathy in a preschool girl. *Pediatr Neurol*. 2010;42:143-146.
- Hoffmann F, Reiter K, Kluger G, et al. Seizures, psychosis and coma: severe course of Hashimoto encephalopathy in a six-year-old girl. *Neuropediatrics*. 2007;38:197-199.
- Bismilla Z, Sell E, Donner E. Hashimoto encephalopathy responding to risperidone. *J Child Neurol*. 2007;22:855-857.
- Ray M, Kothur K, Padhy SK, Saran P. Hashimoto's encephalopathy in an adolescent boy. *Indian J Pediatr*. 2007;74:492-494.
- Mancardi MM, Fazzini F, Rossi A, Gaggero R. Hashimoto's encephalopathy with selective involvement of the nucleus accumbens: a case report. *Neuropediatrics*. 2005;36:218-220.
- Byrne OC, Zuberi SM, Madigan CA, King MD. Hashimoto's thyroiditis—a rare but treatable cause of encephalopathy in children. *Eur J Paediatric Neurol*. 2000;4:279-282.
- Sybesma CA, v Pinxteren-Nagler E, Sinnige LG, van Oostrom JC, de Vries TW. Hashimoto encephalopathy in a 12-year-old girl. *Eur J Pediatr*. 1999;158:867-868.
- Vasconcellos E, Pina-Garza JE, Fakhoury T, Fenichel GM. Pediatric manifestations of Hashimoto's encephalopathy. *Pediatr Neurol*. 1999;20:394-398.
- Balestri P, Grosso S, Garibaldi G. Alternating hemiplegia of childhood or Hashimoto's encephalopathy? *J Neurol Neurosurg Psychiatry*. 1999;66:548-549.
- Ferracci F, Bertiato G, Moretto G. Hashimoto's encephalopathy: epidemiologic data and pathogenetic considerations. *J Neurol Sci*. 2004;217:165-168.
- Chong JY, Rowland LP, Utiger RD. Hashimoto encephalopathy: syndrome or myth? *Arch Neurol*. 2003;60:164-171.
- Mocellin R, Walterfang M, Velakoulis D. Hashimoto's encephalopathy: epidemiology, pathogenesis and management. *CNS Drugs*. 2007;21:799-811.
- Alink J, de Vries TW. Unexplained seizures, confusion or hallucinations: think hashimoto encephalopathy. *Acta Paediatr*. 2008;97:451-453.
- Chaudhuri A, Behan PO. The clinical spectrum, diagnosis, pathogenesis and treatment of Hashimoto's encephalopathy (recurrent acute disseminated encephalomyelitis). *Curr Med Chem*. 2003;10:1945-1953.
- Ferlazzo E, Raffaele M, Mazzu I, Pisani F. Recurrent status epilepticus as the main feature of Hashimoto's encephalopathy. *Epilepsy Behav*. 2006;8:328-330.
- Kothbauer-Margreiter I, Sturzenegger M, Komor J, Baumgartner R, Hess CW. Encephalopathy associated with hashimoto thyroiditis: diagnosis and treatment. *J Neurol*. 1996;243:585-593.

32. Blanchin S, Coffin C, Viader F, et al. Anti-thyroperoxidase antibodies from patients with Hashimoto's encephalopathy bind to cerebellar astrocytes. *J Neuroimmunol.* 2007;192:13–20.
33. Cook MK, Malkin M, Karafin MS. The use of plasma exchange in Hashimoto's encephalopathy: a case report and review of the literature. *J Clin Apher.* 2015;30:188–192.
34. Ferracci F, Moretto G, Candeago RM, et al. Antithyroid antibodies in the CSF: their role in the pathogenesis of Hashimoto's encephalopathy. *Neurology.* 2003;60:712–714.
35. Yoneda M Hashimoto's encephalopathy and autoantibodies. *Brain & Nerve/Shinkei Kenkyu no Shinpo.* 2013;65:365–376.
36. Marshall GA, Doyle JJ. Long-term treatment of Hashimoto's encephalopathy. *J Neuropsychiatry Clin Neurosci.* 2006;18:14–20.
37. Nolte KW, Unbehaun A, Sieker H, Kloss TM, Paulus W. Hashimoto encephalopathy: a brainstem vasculitis? *Neurology.* 2000;54:769–770.
38. Shibata N, Yamamoto Y, Sunami N, Suga M, Yamashita Y Isolated angiitis of the CNS associated with Hashimoto's disease. *Rinsho Shinkeigaku.* 1992;32:191–198.
39. Lee JH, Cho SB, Bang D, et al. Human anti-alpha-enolase antibody in sera from patients with Behcet's disease and rheumatologic disorders. *Clin Exp Rheumatol.* 2009;27(2 Suppl 53):S63–S66.
40. Seipelt M, Zerr I, Nau R, et al. Hashimoto's encephalitis as a differential diagnosis of Creutzfeldt-Jakob disease. *J Neurol Neurosurg Psychiatry.* 1999;66:172–176.