

## Case Studies

## Occipital Sinus Thrombosis: An Exceptional Case Report

Rahma Beyrouiti, MD, PhD,\* Malek Mansour, PhD,\* Amel Kacem, PhD,†  
 Jamel Zaouali, PhD,\* and Ridha Mrissa, PhD\*

*Background:* Variations of the dural venous sinuses may result in inaccurate imaging interpretation or complications during surgical approaches. One variation of the dural venous sinuses reported infrequently in the literature is the occipital sinus. We report an exceptional case of occipital sinus thrombosis. *Case report:* A 48-year-old right-handed man with a 5-month history of hypertension and chronic renal failure presented with cephalalgia, vomiting, and blurred vision evolving over 48 hours. Neurological examination revealed papillary edema stage 1 with no others abnormalities. An initial brain computed tomography (CT) scan performed was normal. The opening pressure of cerebrospinal fluid (CSF) was 35 cmH<sub>2</sub>O with normal level of protein and no hypercellularity in CSF analysis. The evolution was marked by the occurrence of generalized tonic-clonic seizure. A second CT scan performed showed a hyperdensity of the occipital sinus. Magnetic resonance imaging and magnetic resonance venography studies confirmed the diagnosis with highlighting the thrombosis of the occipital sinus in association to an ectasia of the torcular. The patient received adequate anticoagulation for 6 months in association to antiepileptic drugs with a good evolution. *Discussion:* According to our review, such a thrombosis must be a rare condition, because our literature search has shown a lack of any report describing this condition. Herein, we review the anatomy of the occipital sinus and we illustrate the characteristics of this unusual thrombosis with multiple imaging modalities. *Conclusion:* Understanding of the cerebral venous anatomy and recognition of venous variations essentially help when dealing with a pathology, which presents along with a particular venous variation, no matter how rare this combination is. **Key Words:** Occipital sinus—dural venous sinuses—thrombosis—venography.

© 2016 National Stroke Association. Published by Elsevier Inc. All rights reserved.

## Introduction

The occipital sinus is the smallest of the dural venous sinuses.<sup>1</sup> It is situated near the attachment of the falx cerebella communicating with the torcular herophili, superiorly, and with the vertebral venous plexus and marginal sinus, inferiorly.<sup>2</sup> On magnetic resonance venography (MRV), they are demonstrated in about 20% of patients,<sup>3</sup> despite being demonstrated in 65% of cadavers.<sup>4</sup> Occipital sinus may be complicated by thrombosis, hemorrhage, or air embolism with surgical intervention of the posterior cranial fossa. We report a unique case of occipital sinus thrombosis, the first reported case in the literature.

From the \*Department of Neurology, Military Hospital of Tunis, Sfax, Tunisia; and †Department of Medicine, Hospital of Jendouba, Jendouba, Tunisia.

Received November 11, 2015; accepted February 4, 2016.

Address correspondence to Rahma Beyrouiti, MD, PhD, Department of Neurology, Military Hospital of Tunis, Route de Teniour km 1.5, Sfax 3002, Tunisia. E-mail: [rahma.beyrouiti@gmail.com](mailto:rahma.beyrouiti@gmail.com).

1052-3057/\$ - see front matter

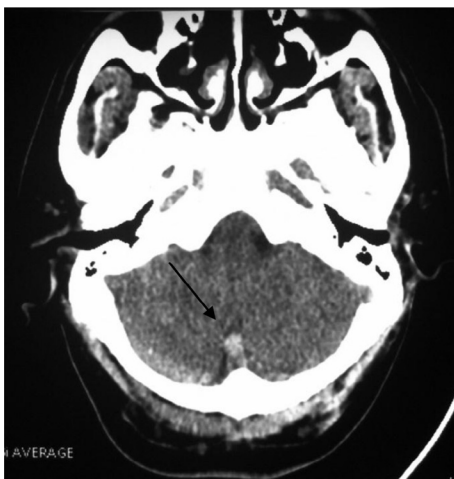
© 2016 National Stroke Association. Published by Elsevier Inc. All rights reserved.

<http://dx.doi.org/10.1016/j.jstrokecerebrovasdis.2016.02.006>

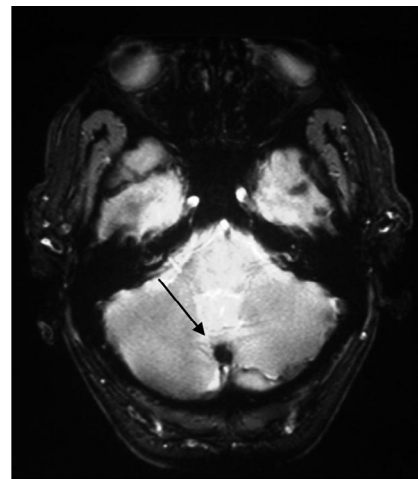
## Case Report

A 48-year-old right-handed man with a 5-month history of hypertension and chronic renal failure presented with cephalalgia, vomiting, and blurred vision evolving over 48 hours. On examination, the patient was alert, and had a blood pressure of 120/70 mmHg, a regular heart rate of 95 beats/minute, a temperature of 39°C, and an infection of the dialysis catheter. Neurological examination revealed papillary edema stage 1 with no other abnormalities. An initial brain computed tomography (CT) scan performed was normal. The opening pressure of cerebrospinal fluid (CSF) was 35 cmH<sub>2</sub>O with normal level of protein and no hypercellularity in CSF analysis. The patient was treated initially with antibiotics for 24 hours. The evolution was marked by the occurrence of generalized tonic-clonic epileptic crisis. A second CT scan performed showed a hyperdensity of the occipital sinus (Fig 1). Magnetic resonance imaging and MRV studies confirmed the diagnosis with highlighting the thrombosis of the occipital sinus in association to an ectasia of the torcular (Figs 2, 3). There were no parenchymal abnormalities. In laboratory studies, blood cell counts, liver and thyroid functions, serum cholesterol and blood glucose levels, arterial blood gasses, and coagulation systems were normal.

Etiological investigations did not find a prothrombotic condition: testing for thrombophilia, including protein C, protein S, antithrombin deficiency, antiphospholipid syndrome, prothrombin G20210A mutation, and factor V Leiden, was normal. Thoracoabdominal CT showed no abnormalities. Tumor markers including carcinoembryonic antigen and alpha-fetoprotein were normal. Ear, nose, and throat examination and stomatologic examination did not find a locoregional infection. The patient received adequate anticoagulation initially with nonfractionated heparin



**Figure 1.** Noncontrast computed tomography head scan showed spontaneous hyperdensity of the occipital sinus.



**Figure 2.** Gradient echo axial MRI demonstrating a thrombosis in the occipital sinus. Abbreviation: MRI, magnetic resonance imaging.

continued with vitamin K antagonists for 6 months in association to antiepileptic drugs with a good evolution.

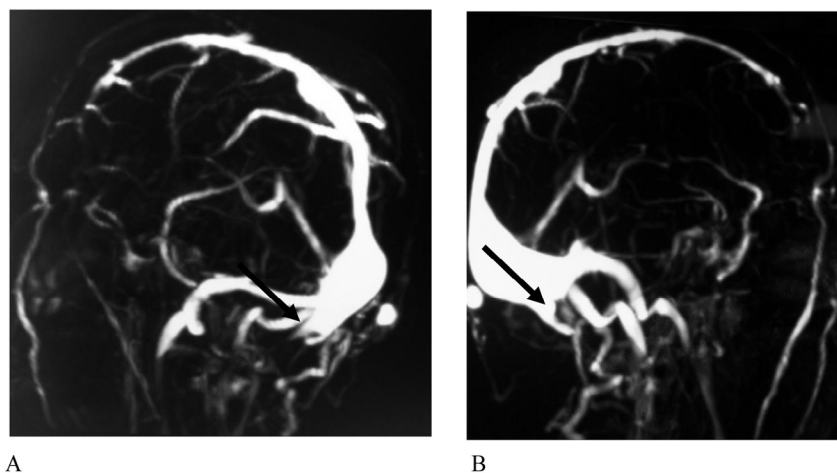
## Discussion

The occipital sinus is the smallest of the dural venous sinuses and lies in the attached margin of the falx cerebelli.<sup>5</sup> It usually communicates cranially with the confluence of sinuses, and caudally with the vertebral venous plexus or the marginal sinus at the foramen magnum.<sup>2,6</sup> Tributaries may include veins of the hypoglossal canal, basilar plexus, occipital emissary, and diploic veins.<sup>5</sup> Also in the posterior cranial fossa, one finds the transverse, sigmoid, inferior, and superior petrosal sinuses.<sup>7</sup>

It should be noted that the occipital venous network is thought to become involuted once most of the venous flow passes through the large dural sinuses as the child achieves an upright position. This contention is supported by a study of 108 children by Rollins et al<sup>8</sup> in which persistent occipital sinuses were seen in 13% of patients less than 25 months of age but in only 2% of children older than 5 years. As greater than 50% of the occipital sinuses were seen in children less than 25 months of age, an age-related regression in the occipital sinuses may occur.<sup>8</sup> Therefore, regression in the size of the occipital sinus with increased age should not be mistaken as an indicator of pathology.

In another study, occipital sinuses were shown on MR venograms in 10% of the cases, obtained from 100 patients ranging in age from 9 days to 83 years.<sup>9</sup> Other authors have reported the presence of occipital sinuses in 35.5% of the cases,<sup>10</sup> but the age group was not mentioned. Ruiz et al<sup>11</sup> reported the presence of occipital sinus in 1 of 12 cadavers with an average age at time of death of 85 years. The occipital sinuses have been found to be relatively wider in neonates than in adults.<sup>10</sup>

**Figure 3.** (A and B): MRV of the cerebral sinuses showing the thrombosis of the occipital sinus in association to an ectasia of the torcular. Abbreviation: MRV, magnetic resonance venography.



In their study, Dora and Zileli<sup>12</sup> assessed the clinical significance of anatomic variations of the occipital sinus with regard to the sinus thrombosis. Furthermore, Dora and Zileli<sup>12</sup> contended that, in contrast to the claim of many anatomy books, the formation and variation of the occipital sinus play an important role in the dilatation of the lateral sinuses, as seen in our case rather than the radius of the internal jugular vein.

Intracranial venous drainage has been evaluated by angiography, yet simultaneous visualization of the venous structures is often not obtained by selective angiography.<sup>2</sup> On an enhanced CT scan, it is often difficult to differentiate the dural sinuses from surrounding bony structures. Two-dimensional time-of-flight MRV has the disadvantage of a long scan time. However, enhanced fast gradient echo three-dimensional contrast-enhanced MR angiography and MRV have a number of advantages, including a short scan time, reproducibility, and a relatively short postprocessing time, and can demonstrate detailed intracranial vascular anatomy and several pathologies in vivo especially thrombosis.<sup>2</sup> In an imaging study of 555 patients, Kobayashi et al<sup>2</sup> found that the occipital sinus had communication with the sigmoid sinus in 11.9%. Lang<sup>5</sup> stated that these may be large (oblique occipital sinus) and are more frequently observed in newborns and small children.

### Conclusion

Understanding of the cerebral venous anatomy and recognition of venous variations essentially help when dealing with a pathology, which presents along with a particular venous variation, no matter how rare this combination

is. Our case describes a rare but important variation of the venous system.

### References

1. Patel N. Venous anatomy and imaging of the first centimeter. *Semin Ultrasound CT MR* 2009;30:513-524.
2. Kobayashi K, Suzuki M, Ueda F, et al. Anatomical study of the occipital sinus using contrast-enhanced magnetic resonance venography. *Neuroradiology* 2006;48:373-379.
3. Widjaja E, Griffiths PD. Intracranial MR venography in children: normal anatomy and variations. *AJNR Am J Neuroradiol* 1557;25:1562-2004.
4. Das AC, Hasan M. The occipital sinus. *J Neurosurg* 1970;33:307-311.
5. Lang J. *Clinical anatomy of the posterior cranial fossa and its foramina*. New York: Thieme, 1991.
6. Srijit D, Abd Latiff A, Suhaimi FH, et al. An anatomico-radiological study of the grooves for occipital sinus in the posterior cranial fossa. *Bratisl Lek Listy* 2008;109:520-524.
7. Tubbs RS, Bosmia AN, Shoja MM, et al. The oblique occipital sinus: a review of anatomy and imaging characteristics. *Surg Radiol Anat* 2011;33:747-749. doi:10.1007/s00276-011-0831-9.
8. Rollins N, Ison C, Booth T, et al. MR venography in the pediatric patient. *AJNR Am J Neuroradiol* 2005;26:50-55.
9. Ayanzen RH, Bird CR, Keller PJ, et al. Cerebral MR venography: normal anatomy and potential diagnostic pitfalls. *AJNR Am J Neuroradiol* 2000;21:74-78.
10. Lang J. The floor of the posterior cranial fossa. In: *Clinical anatomy of the posterior cranial fossa and its foramina*. New York: Thieme, 1991:6-9.
11. San Millan Ruiz D, Gailloud P, Rufenacht DA, et al. The craniocervical venous system in relation to cerebral venous drainage. *AJNR Am J Neuroradiol* 2002;23:1500-1508.
12. Dora F, Zileli T. Common variations of the lateral and occipital sinuses at the confluens sinuum. *Neuroradiology* 1980;20:23-27.