

Hyperdensity of the Basilar Artery on Postmortem CT

A Potential Indicator for Basilar Artery Thrombosis

Jack Garland,* Rexson Tse, BSc, MB, BS,† Raymond J. Beh, BSc,†
Timothy J. Lyons, MB ChB, MD, FRCS, FRCPath, DMJ(Path), FRCPA, Dip Av Med,†
and Allan D. Cala, MB, BS, FRCPA†

Abstract: Basilar artery thrombosis constitutes 1% of all types of stroke, carries a mortality rate of up to 90%, and is one of the rarer causes of sudden death. It leads to brain stem ischemia and commonly presents with impaired consciousness, cranial nerve palsy, hemiplegia or quadriplegia, and sudden collapse. Clinically, the diagnosis of basilar artery thrombosis is made on clinical symptoms, along with a hyperdense basilar artery in antemortem computed tomography (CT) scan. To our knowledge, whether a hyperdense basilar artery indicates basilar artery thrombosis on postmortem CT scan is not documented in the literature. We present a case report of a 55-year-old man who on postmortem CT scan showed a hyperdense basilar artery and was subsequently confirmed to be a fatal basilar artery thrombosis. We suggest that a hyperdense basilar artery on postmortem CT should prompt the pathologist to consider basilar artery thrombosis.

Key Words: basilar artery thrombosis, postmortem CT

(*Am J Forensic Med Pathol* 2016;37: 64–66)

Basilar artery thrombosis is uncommon and can cause sudden death through brain stem ischemia. Basilar artery thrombosis can cause a stroke involving the pons, mesencephalon, and/or thalamus. Clinical manifestations include impaired consciousness, cranial nerve palsy, and hemiplegia or quadriplegia.^{1,2} It constitutes approximately 1% of all strokes^{1,3} and has a mortality rate of up to 90% in untreated patients.⁴

In the clinical setting, the major computed tomography (CT) finding suggestive of a basilar artery thrombosis is hyperdensity of the basilar artery.^{1,4,5} The use of postmortem CT (PMCT) scan by forensic departments as an adjunct to autopsy is a developing area. The difference in postmortem and antemortem scans is still being evaluated.⁶ In particular, unenhanced PMCT imaging of blood vessels can be challenging^{6,7} partly because of the difficulty of distinguishing between antemortem and postmortem clotting.⁷ The literature on PMCT on basilar artery thrombosis is scant, so we present a case of autopsy-confirmed basilar artery thrombosis where an unenhanced PMCT demonstrated hyperdensity of the basilar artery. We recommend that close examination of the cerebral vascular supply is warranted when the PMCT shows a hyperdense basilar artery.

CASE REPORT

Case History

A 55-year-old man, who had a history of type 2 diabetes mellitus and was a heavy smoker and drinker, complained of severe headaches in the days before his death and was found dead in the kitchen overnight by his mother.

Postmortem Findings

An unenhanced PMCT scan was performed before autopsy. The most striking finding was a prominent hyperdense basilar artery (Fig. 1). Other significant findings included focal calcification of the coronary arteries and a degenerative vertebral spinal column.

Macroscopic examination of the brain showed thrombosis of the intracranial segment of the right vertebral artery and full length of the basilar artery (Fig. 2), which was confirmed to be a luminal thrombus histologically (Fig. 3). There was associated recent cerebral infarct in the occipital lobe. There were no microscopic ischemic changes recognized in the brain stem. Without any evidence of trauma or mural thrombus in the heart, the thrombosis was considered to be spontaneous in nature.

Other pathology recognized during autopsy was 50% to 75% (moderate to severe) atherosclerotic narrowing of all main branches of the coronary arteries.

Toxicological analysis showed the presence of metformin and paracetamol but was otherwise negative for alcohol, opiates, cannabinoids, benzodiazepines, cocaine metabolites, and other commonly screened drugs.

The vitreous humor showed a mildly elevated glucose level (9.1 mmol/L) in keeping with a history of type 2 diabetes mellitus; otherwise, the biochemical analysis performed on the vitreous humor showed postmortem changes and was negative.

Cause of Death

The cause of death was from basilar artery thrombosis causing ischemia to the brain stem resulting in sudden collapse. Autopsy was unable to recognize any predisposing disorder that may cause the basilar artery thrombosis.

DISCUSSION

The basilar artery is formed by the 2 vertebral arteries and provides blood supply to much of the posterior portion of the brain.^{1,2,8} Thrombotic occlusion to the basilar artery can lead to significant ischemic damage to the brain stem and death,^{1,8} often with virtually no prodromal symptoms. Basilar artery thrombosis often occurs in conjunction with atherosclerosis or rarely an underlying coagulopathy, and as such, the prodromal signs in the patient history are often nonspecific.¹

Diagnosis of basilar artery thrombosis in the postmortem setting is done at autopsy, with direct visualization of the thrombosed

Manuscript received November 2, 2015; accepted January 19, 2016.

From the *School of Medicine and Public Health, Faculty of Health and Medicine, University of Newcastle, Callaghan; and †Department of Forensic Medicine, Newcastle, Forensic & Analytical Science Service, NSW Health Pathology, John Hunter Hospital, Newcastle, New South Wales, Australia.

The authors report no conflict of interest.

Reprints: Rexson Tse, BSc, MB, BS, Newcastle Department of Forensic Medicine, John Hunter Hospital, Lookout Rd, New Lambton Heights, Newcastle, NSW, 2305, Australia.

E-mail: rexson.tse@hnehealth.nsw.gov.au.

Copyright © 2016 Wolters Kluwer Health, Inc. All rights reserved.

ISSN: 0195-7910/16/3702-0064

DOI: 10.1097/PAF.0000000000000227

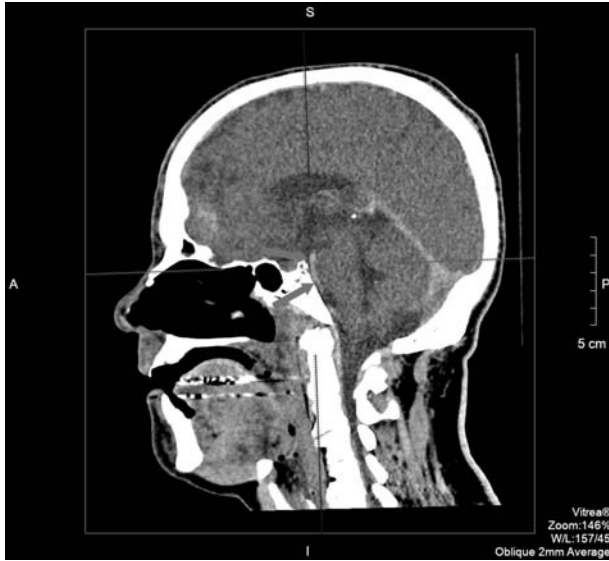

FIGURE 1. Unenhanced PMCT of the head showing a hyperdense basilar artery (arrowheads, Hounsfield units: 65 ± 10 HU) on sagittal view.

artery and subsequent microscopic evaluation.^{9,10} In the antemortem setting, a diagnosis is made via CT scan, of which the key finding is hyperdensity of the basilar artery.^{1,4,5} There is limited information in the literature on the PMCT findings of basilar artery thrombosis.

Postmortem CT is becoming an increasingly used adjunct to autopsy in many forensic pathology departments, and its place in forensic pathology is still being explored. A major role of the

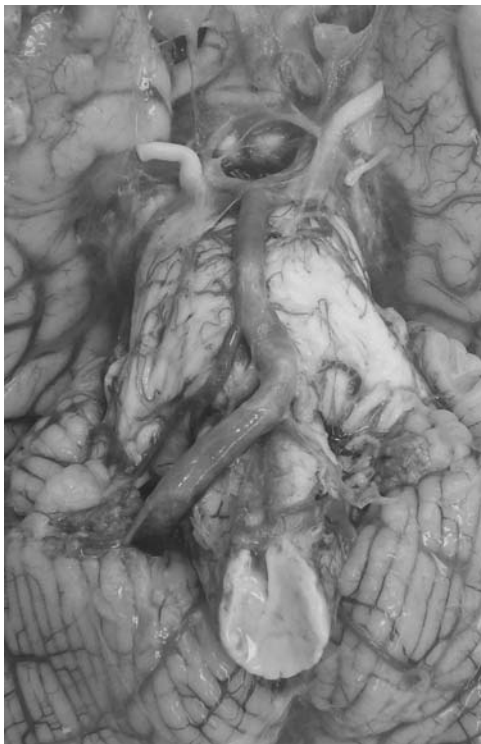

FIGURE 2. Photograph of the base of the brain showing thrombosis of the intracranial segment of the right vertebral artery and full length of the basilar artery.

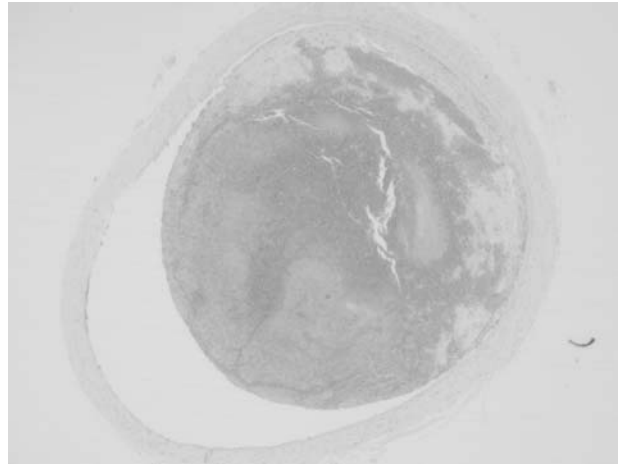


FIGURE 3. Histological section of the basilar artery ($\times 4$ magnification, hematoxylin and eosin) showing a luminal thrombus.

PMCT is to guide the autopsy approach and to act as a means of increasing the accuracy and time efficiency of the process.^{11,12} Findings from the PMCT can guide the forensic pathologist to perform certain specific dissections to establish a cause of death.¹¹

In our case, the unenhanced PMCT showed hyperdensity of the basilar artery, in which the subsequent autopsy revealed a thrombosed basilar artery. To our knowledge, this is the first case report of PMCT findings of basilar artery thrombosis. Our findings suggest that hyperdensity of the basilar artery on PMCT may be a potential indicator of basilar artery thrombosis, and examination of the brain should occur.

CONCLUSIONS

We report a case of basilar artery thrombosis in which an unenhanced PMCT demonstrated hyperdensity of the basilar artery. We suggest that hyperdensity of the basilar artery on PMCT should be closely looked for especially in cases of sudden death. This may be a potential indicator of basilar artery thrombosis, and examination of the brain should occur. Our findings provide additional evidence on the potential utility of PMCT as a supplement to autopsy.

REFERENCES

1. Mattle HP, Arnold M, Lindsberg PJ, et al. Basilar artery occlusion. *Lancet Neurol.* 2011;10(11):1002–1014.
2. Archer CR, Horenstein S. Basilar artery occlusion: clinical and radiological correlation. *Stroke.* 1977;8(3):383–390.
3. Israeli-korn SD, Schwammenthal Y, Yonash-Kimchi T, et al. Ischemic stroke due to acute basilar artery occlusion: proportion and outcomes. *Isr Med Assoc J.* 2010;12(11):671–675.
4. Connell L, Koerte IK, Laubender RP, et al. Hyperdense basilar artery sign—a reliable sign of basilar artery occlusion. *Neuroradiology.* 2012;54(4):321–327.
5. Mortimer AM, Saunders T, Cook JL. Cross-sectional imaging for diagnosis and clinical outcome prediction of acute basilar artery thrombosis. *Clin Radiol.* 2011;66(6):551–558.
6. Thomsen AH, Jurik AG, Uhrenholt L, et al. An alternative approach to computerized tomography (CT) in forensic pathology. *Forensic Sci Int.* 2009;183(1–3):87–90.

7. Ross SG, Bolliger SA, Ampanozi G, et al. Postmortem CT angiography: capabilities and limitations in traumatic and natural causes of death. *Radiographics*. 2014;34(3):830–846.
8. De Decker K, Van Havenbergh T, D'Archambeau O, et al. Basilar artery thrombosis in a trauma patient. Case report and review of the literature. *Resuscitation*. 2003;59(1):147–154.
9. Shaqiri E, Vyshka G, Sinamati A, et al. Fatal basilar thrombosis possibly related to minor cervical trauma: a case report. *Case Rep Med*. 2010;2010: pii: 401978 doi: 10.1155/2010/401978. Epub 2010 Aug 8.
10. Sprogøe-Jakobsen S, Falk E. Fatal thrombosis of the basilar artery due to a minor head injury. *Forensic Sci Int*. 1990;45(3):239–245.
11. Le Blanc-Louvry I, Thureau S, Duval C, et al. Post-mortem computed tomography compared to forensic autopsy findings: a French experience. *Eur Radiol*. 2013;23(7):1829–1835.
12. Flach PM, Gascho D, Schweitzer W, et al. Imaging in forensic radiology: an illustrated guide for postmortem computed tomography technique and protocols. *Forensic Sci Med Pathol*. 2014;10(4): 583–606.