

Juvenile Cerebral Infarction Caused by Bow Hunter's Syndrome during Sport: Two Case Reports

Hiroto KAGEYAMA,¹ Shinichi YOSHIMURA,¹ Tomoko IIDA,¹ Manabu SHIRAKAWA,¹
Kazutaka UCHIDA,¹ Yusuke TOMOGANE,¹ and Yuki MIYAJI¹

¹Department of Neurosurgery, Hyogo College of Medicine, Nishinomiya, Hyogo

Abstract

We report two cases of juvenile cerebral infarction caused by bow hunter's syndrome (BHS) during sport. Case 1 was a 17-year-old male who developed a partial visual field defect after playing basketball. BHS was diagnosed because cervical ultrasonography demonstrated occlusion of the vertebral artery when the neck was rotated. After C1–2 posterior fixation was performed, his symptoms resolved. Case 2 was an 18-year-old male with recurrent visual disturbance after playing handball. Cerebral infarction occurred repeatedly despite antiplatelet therapy. After 3 years, vertebral artery dissection was diagnosed and stenting was performed, but his symptoms did not resolve. BHS was diagnosed when he was examined at our department. C1–2 posterior fixation was performed and his symptoms resolved. In these two cases, BHS was caused by sporting activity. For accurate diagnosis and treatment of BHS, neuroimaging with cervical rotation is mandatory.

Key words: bow hunter's syndrome, dissection, sport, cerebral infarction, surgery

Introduction

Vertebral artery dissection (VAD) can be caused by various external factors, including sporting activities, and can lead to cerebral infarction. It is sometimes difficult to diagnose recurrent cerebral infarction associated with VAD and identify the cause in young patients. Here we report two juvenile patients with symptomatic VAD caused by bow hunter's syndrome (BHS), leading to cerebral infarction.

Case Reports

I. Case 1: a 17-year-old male

The patient complained of partial visual field defects after playing basketball. Right upper quadrantanopia was diagnosed by a local ophthalmologist and he was referred to our hospital. The location of the visual field defect, as well as the side of nystagmus and hemilateral numbness, changed each time the patient's symptoms occurred. Head magnetic resonance imaging (MRI) showed multiple high intensity spots in the cerebellar hemispheres and occipital lobes on diffusion-weighted images (DWIs) (Fig. 1A, B). Cervical ultrasonography demonstrated occlusion of the vertebral artery (VA) when the neck was rotated. Magnetic resonance angiography (MRA) clearly demonstrated VA occlusion during neck rotation (Fig. 1C, D), so BHS

was diagnosed. Cerebral angiography showed dissection of the right VA just distal to the transverse foramen (Fig. 1E). Although his symptoms resolved temporarily due to wearing a neck collar, repeat angiography after 3 months showed extension of dissection of the right VA (Fig. 1F). Therefore, the patient underwent C1–2 posterior fixation (Fig. 1G). Postoperative angiography showed improvement of VAD (Fig. 1H) and the patient's symptoms have not recurred.

II. Case 2: an 18-year-old male

The patient had recurrent severe headaches associated with visual disturbance. Cerebral infarction was diagnosed by a local neurologist, but the cause was unknown. He had repeated episodes of cerebral infarction even after starting antiplatelet therapy (Fig. 2A, B). When he was 18 years old, disturbance of consciousness occurred suddenly in hospital and MRI showed occlusion of the right VA. Mechanical thrombectomy was performed and a stent was placed in the right VA at the site of dissection. However, he still had recurrent ischemic events. After he presented to our hospital, BHS and VAD were diagnosed because angiography showed occlusion of the right VA during leftward rotation of neck (Fig. 2D). There was stenosis and dilatation of the right VA just distal to the transverse foramen of C2 (Fig. 2C), suggesting dissection. The patient underwent C1–2 posterior fixation (Fig. 2E, F). Postoperative

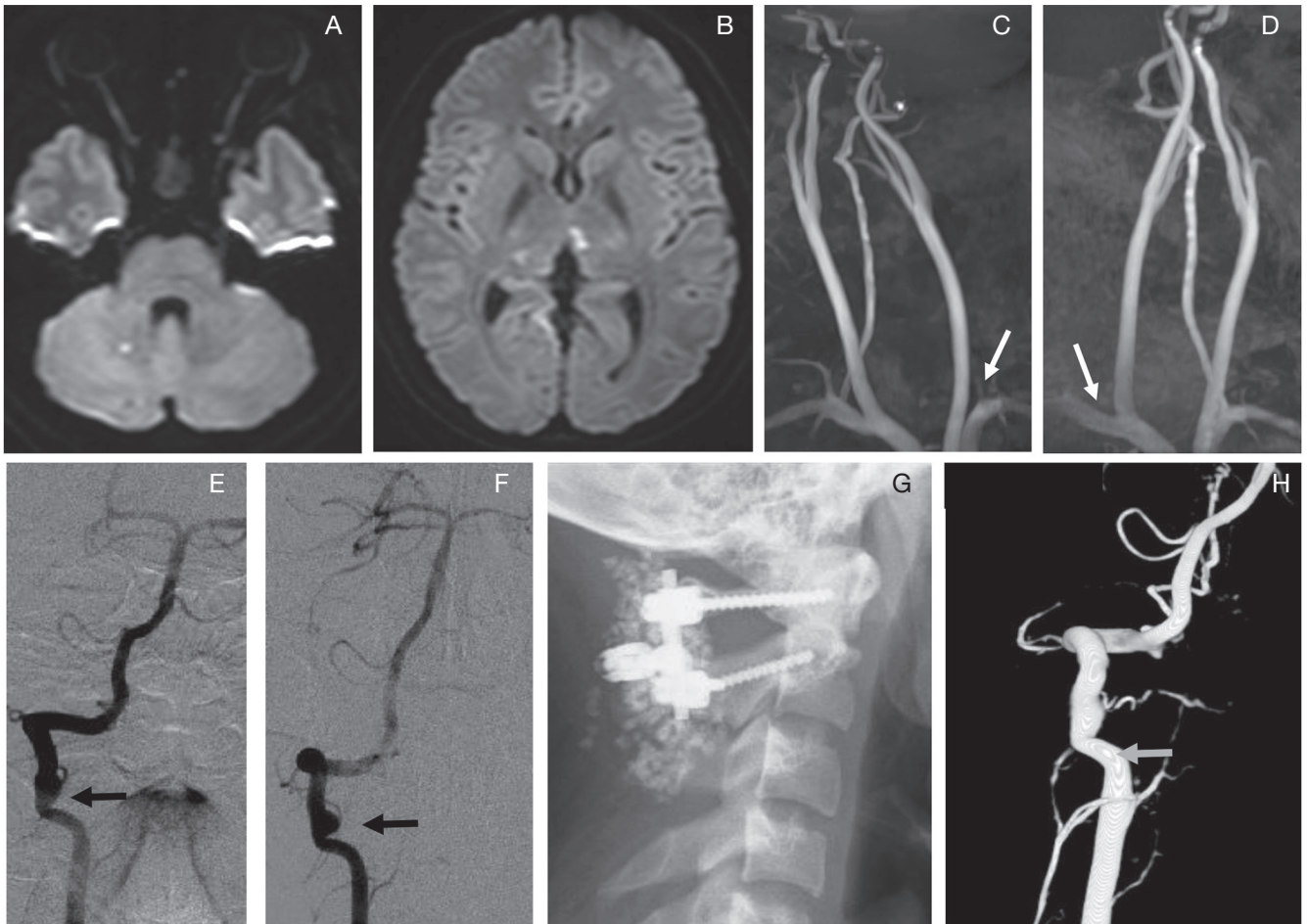


Fig. 1 Neuroimaging in case 1. A, B: Magnetic resonance imaging showing multiple high signal intensity spots on a diffusion-weighted image. C, D: Magnetic resonance angiography demonstrated occlusion of the total course of the contralateral vertebral artery (VA) during neck rotation (*arrows*). E: Angiography shows right VA dilatation just distal to the axis of the transverse foramen, suggestion dissection (*arrow*). F: Repeat angiography after 3 months shows exacerbation of VA dissection (*arrow*). G: Postoperative cervical X-ray film demonstrating screws inserted for C1–2 posterior fixation. H: Postoperative vertebral angiography showing improvement of dissection.

angiography showed improvement of VA dissection (Fig. 2G, H) and the ischemic events resolved.

Discussion

VAD is a common cause of cerebral infarction in young adults.¹⁾ It has been reported to be caused by hyperextension or hyper-rotation during sports such as yoga, golf, American football, and Kung-fu.^{2–4)} Sorensen initially reported BHS, in which Wallenberg syndrome occurred due to right VA occlusion caused by head rotation during the bow drawing action.⁵⁾ In the 1950s, it was reported that VAD can be caused by neck rotation in cadavers,⁶⁾ and the ipsilateral, contralateral, and bilateral development of VAD has been reported in previously healthy persons.^{7,8,13)} Although these findings are broadly recognized, it is still often difficult to diagnose cerebral infarction in young persons and identify the cause. Our two patients were

teenagers who had recurrent cerebral infarction associated with playing sport, which was caused by BHS associated with VAD.

Regarding mechanisms of the cerebral infarction, we speculated cerebral embolism due to vessel injury, rather than hemodynamic ischemia due to vessel occlusion, was the main cause in both cases, because collateral flow from contralateral VA was observed on MRA in case 1, and mechanical thrombectomy of the thrombus was performed in case 2.

The patients were young males (17 and 18 years old) and they belonged to an age group in which cerebral infarction is rarely observed. The sports they played were basketball in case 1 and handball in case 2, respectively. During ball games, players may rotate the neck extensively and rapidly. Because the VA is fixed by fibrous tissue around the C1–2 transverse foramen, it can be subjected to severe traction by repeated hyper-rotation, resulting

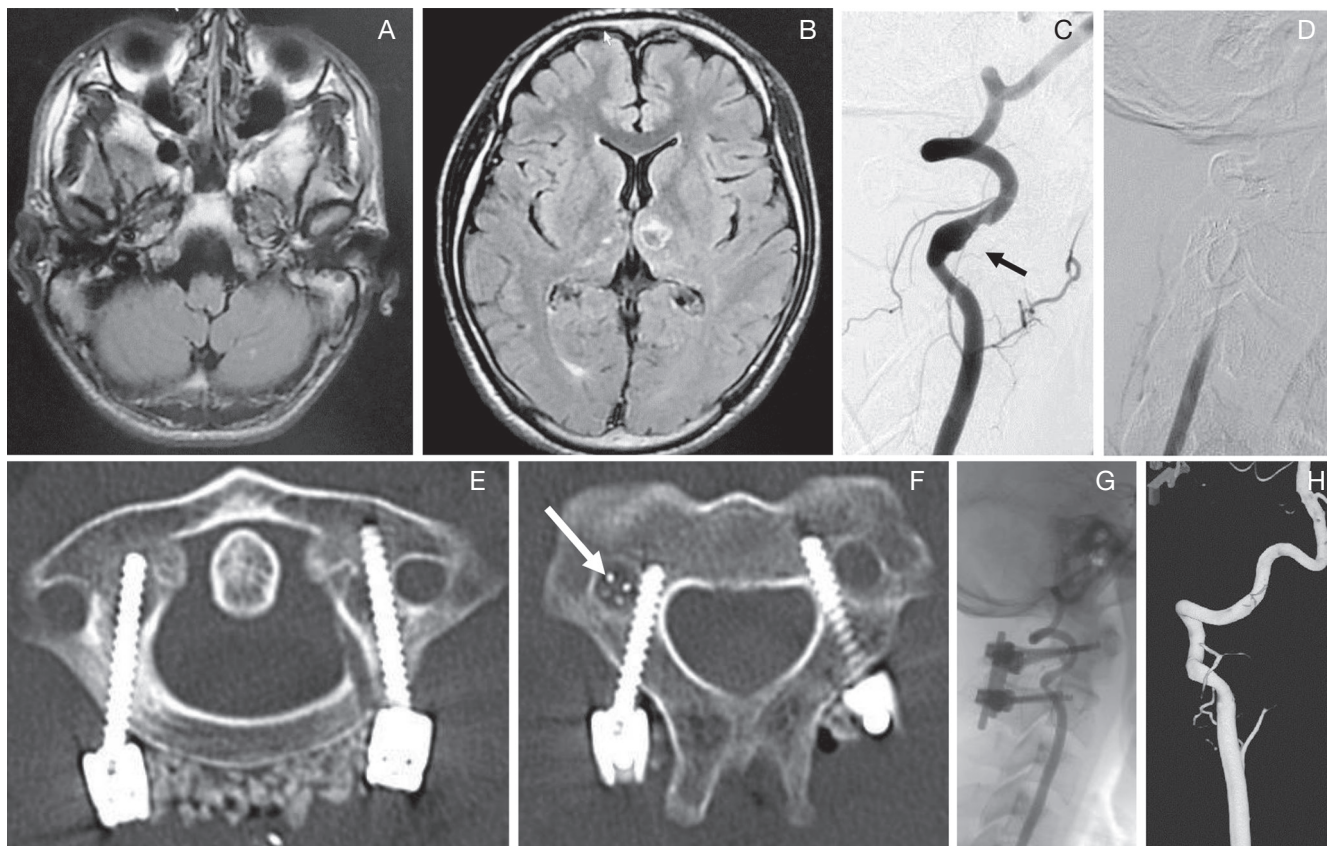


Fig. 2 Neuroimaging in case 2. **A, B:** Magnetic resonance imaging showing multiple high intensity spots in the cerebellum and thalamus on a fluid-attenuated inversion recovery image. **C:** Vertebral angiography demonstrating stenosis and dilatation of the right vertebral artery (VA) just distal to the C2 transverse foramen after stenting (*arrow*). **D:** Angiography shows right VA occlusion during leftward rotation of the neck. **E, F:** Postoperative cervical X-ray film showing screws inserted for C1–2 posterior fixation and a stent in the right VA at the C2 level (*arrow*). **G, H:** Postoperative angiography showing resolution of VA dissection.

in injury to the vessel wall that can lead to embolic cerebral infarction.

Leftward neck rotation when throwing is similar to the mechanism of bow hunter's stroke that occurs in archery.⁵⁾ Various symptoms have been reported due to impairment of VA circulation.^{5,9–11)} Yamaguchi et al. reported a case of cerebral infarction caused by BHS associated with VAD.¹²⁾ Subsequently, Takeshima et al. suggested that the pathological mechanism of cerebral embolism in BHS was VA dissection, although they also mentioned that embolism and subintimal injury have not been definitely demonstrated.¹³⁾ It is important to suspect the possibility of BHS and perform angiography during neck rotation in addition to diagnosis of VAD by standard angiography.^{14,15)} Surgical treatment of VAD is still controversial. In the present two cases, C1–2 posterior fixation was selected and improvement of symptoms was achieved in both patients postoperatively. Although stenting of the VA has been reported as minimally invasive surgery for BHS,¹⁶⁾ stent placement failed to stop ischemic events in our case 2. Posterior decompression at the C1 transverse foramen^{13,17)} and anterior decompression at the C2 transverse foramen¹⁸⁾

have also been reported as treatments for VAD. However, Matsuyama et al. reported that posterior fixation achieved a better outcome than posterior decompression.¹⁹⁾ Jost et al. suggested a treatment and management algorithm for rotational vertebrobasilar insufficiency without VAD from their review of 124 cases.¹¹⁾ They recommended decompression without fusion for the BHS caused by isolated uncarthrosis or by tissue adhesion. On the other hand, they recommended fusion with or without decompression for BHS caused by degenerated joints such as instability and recurrence cases. Decompression without fusion is simple, less invasive, and physiological, so that it is more appropriate if degenerative change is limited. Fusion procedure decreases postoperative recurrence or patient's symptom, but limits neck rotation by 50%–70%.^{11,19)}

Both our patients had VAD around the C2 transverse foramen, and strong local fixation was considered necessary because they were young and wanted to continue playing sports. Thus, we selected C1–2 posterior fixation, and both patients had a good postoperative course without recurrence. In these patients, the period from onset of apparent ischemic symptoms to diagnosis was 4 months

and 3 years, respectively. Antiplatelet therapy was not effective, which indicates that it is difficult to treat this disease by medication alone. Based on our experience with these two patients, surgical fixation might be a reasonable option for VA dissection due to BHS.

Conclusion

We reported two cases of juvenile cerebral infarction caused by BHS and associated with sporting activity. For accurate diagnosis and treatment of BHS, neuroimaging with cervical rotation is mandatory.

Conflicts of Interest Disclosure

The authors declare no conflicts of interest. This report did not receive any funding from the public or from any commercial agencies.

References

- 1) Gottesman RF, Sharma P, Robinson KA, Arnan M, Tsui M, Ladha K, Newman-Toker DE: Clinical characteristics of symptomatic vertebral artery dissection: a systematic review. *Neurologist* 18: 245–254, 2012
- 2) McCrory P: Vertebral artery dissection causing stroke in sport. *J Clin Neurosci* 7: 298–300, 2000
- 3) Maroon JC, Gardner P, Abila AA, El-Kadi H, Bost J: "Golfer's stroke": golf-induced stroke from vertebral artery dissection. *Surg Neurol* 67: 163–168; discussion 168, 2007
- 4) Pacei F, Valvassori L, Bet L: Vertebral artery dissection during Kung-Fu training. *Neurol Sci* 35: 331–332, 2014
- 5) Sorensen BF: Bow hunter's stroke. *Neurosurgery* 2: 259–261, 1978
- 6) Tissington Tatlow WF, Bammer HG: Syndrome of vertebral artery compression. *Neurology* 7: 331–340, 1957
- 7) Faris AA, Poser CM, Wilmore DW, Agnew CH: Radiologic visualization of neck vessels in healthy men. *Neurology* 13: 386–396, 1963
- 8) Toole JF, Tucker SH: Influence of head position upon cerebral circulation. Studies on blood flow in cadavers. *Arch Neurol* 2: 616–623, 1960
- 9) Rastogi V, Rawls A, Moore O, Victorica B, Khan S, Saravananpavan P, Midivelli S, Raviraj P, Khanna A, Bidari S, Hedna VS: Rare etiology of bow hunter's syndrome and systematic review of literature. *J Vasc Interv Neurol* 8: 7–16, 2015
- 10) Anene-Maidoh TI, Vega RA, Fautheree GL, Reavey-Cantwell JF: An unusual case of pediatric bow hunter's stroke. *Surg Neurol Int* 4: 148, 2013
- 11) Jost GF, Dailey AT: Bow hunter's syndrome revisited: 2 new cases and literature review of 124 cases. *Neurosurg Focus* 38: E7, 2015
- 12) Yamaguchi Y, Nagasawa H, Yamakawa T, Kato T: Bow hunter's syndrome after contralateral vertebral artery dissection. *J Stroke Cerebrovasc Dis* 21: 916.e7–e9, 2012
- 13) Takeshima Y, Nishimura F, Park YS, Nakase H: Fusion surgery for recurrent cerebellar infarctions due to bilateral atlantoaxial rotational vertebral artery occlusion. *Spine (Phila Pa 1976)* 39: E860–E863, 2014
- 14) Hanakita J, Miyake H, Nagayasu S, Nishi S, Suzuki T: Angiographic examination and surgical treatment of bow hunter's stroke. *Neurosurgery* 23: 228–232, 1988
- 15) Zaidi HA, Albuquerque FC, Chowdhry SA, Zabramski JM, Ducruet AF, Spetzler RF: Diagnosis and management of bow hunter's syndrome: 15-year experience at barrow neurological institute. *World Neurosurg* 82: 733–738, 2014
- 16) Sugiu K, Agari T, Tokunaga K, Nishida A, Date I: Endovascular treatment for bow hunter's syndrome: case report. *Minim Invasive Neurosurg* 52: 193–195, 2009
- 17) Shimizu T, Waga S, Kojima T, Niwa S: Decompression of the vertebral artery for bow-hunter's stroke. Case report. *J Neurosurg* 69: 127–131, 1988
- 18) Seki T, Hida K, Akino M, Iwasaki Y: Anterior decompression of the atlantoaxial vertebral artery to treat bow hunter's stroke: technical case report. *Neurosurgery* 49: 1474–1476, 2001
- 19) Matsuyama T, Morimoto T, Sakaki T: Comparison of C1-2 posterior fusion and decompression of the vertebral artery in the treatment of bow hunter's stroke. *J Neurosurg* 86: 619–623, 1997

Address reprint requests to: Shinichi Yoshimura, MD, PhD, Department of Neurosurgery, Hyogo College of Medicine, Mukogawa, Nishinomiya, Hyogo 663-8501, Japan.
e-mail: s-yoshi@hyo-med.ac.jp