

NOTE

INFARCT OF THE ANTERIOR LIMB OF THE RIGHT INTERNAL CAPSULE CAUSING LEFT MOTOR NEGLECT: CASE REPORT AND CEREBRAL BLOOD FLOW STUDY

V. de la Sayette¹, G. Bouvard², F. Eustache¹, F. Chapon¹,
F. Rivaton³, F. Viader¹, B. Lechevalier¹

(¹Service de Neurologie Dejerine; ²Service des Radioisotopes; ³Service de
Neuro-radiologie, CHU Côte de Nacre, Caen Cédex)

INTRODUCTION

Unilateral motor neglect (MN) has been described with a variety of cerebral lesions involving the pre-rolandic cortex, striatum, thalamus or internal capsule. It can occur with a syndrome of unilateral multimodalities neglect or as an isolated entity, suggesting relationships between global hemispheric activation and a more specific involvement of motor function. We report a case of MN caused by an anterior internal capsule infarct with cerebral blood flow (CBF) measurements before and after motor activation.

CASE PRESENTATION

A right handed 69 year old hypertensive man suddenly presented occipital headache and ataxia. He was noted to have facial asymmetry and difficulty walking. Admitted on the same day, he was found to be alert, well oriented, complaining of a left-sided weakness. His blood pressure was 240/120. The examination showed no spontaneous movement of the left hemibody, a facial asymmetry (left facial weakness) and a mild dysarthria. The gait was disturbed by dragging of the left leg and non balance of the left arm, causing the patient to deviate to the left and to fall frequently. These signs disappeared after verbal stimulation, that is when the patient was asked with insistence to use his arm and leg. Under these conditions, no segmental motor deficit was noted. Deep tendon reflexes were brisk and symmetrical and the plantar reflexes were downgoing. Examinations performed at different periods never showed sensory deficit. However, nociceptive stimuli caused a slower withdrawal motor reaction on the left than on the right side. In bimanual motor activities, for example when the patient was eating, he failed also spontaneously to use his left hand or took the knife but did not use it. A definite left motor extinction was present since the patient raised correctly the left or the right arm upon unilateral tactile stimulation but when bilaterally stimulated, the right arm was initially raised shortly followed by the left arm. There was no hemianopsia, visual neglect or extinction. Visuo-spatial tests were correctly executed: clock drawing, complex image description, room drawing, placement of cities on a map, itinerary description. Body scheme perception and face recognition were normal. Copies of Rey figure and tridimensional constructive praxia showed mild alteration. Gestural series, dressing and small objects manipulation were correctly executed. No frontal signs or memory impairment were detected. Calculation and speech were normal.

Verbal dichotic listening showed a left sided extinction and the audiogram a mild bilateral and symmetrical hypoacusia.

Cortical auditory evoked potentials recorded over the temporal and parietal lobes after stimulation with 95 db at 1000 Hz were normal, including the early and late potentials. The somato-sensory evoked potentials after stimulation of the median nerves were normal. The EEG showed moderate signs of right frontal damage.

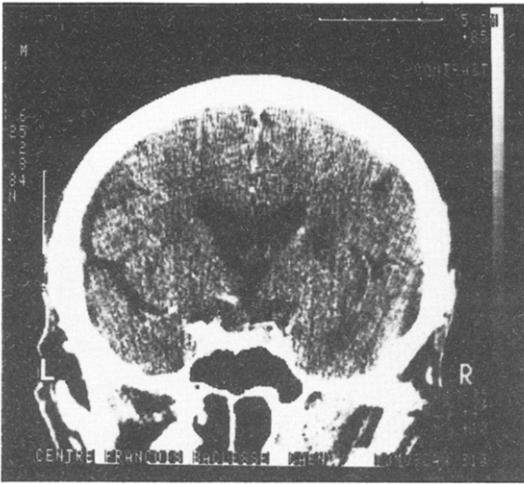


Fig. 1 - CT scan (axial slice).

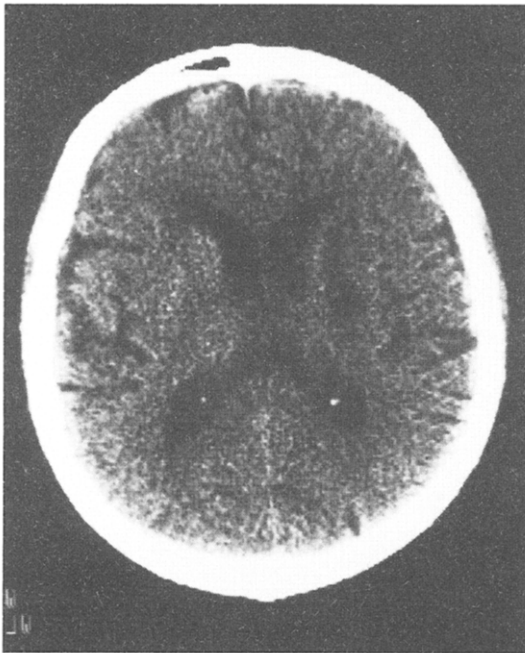


Fig. 2 - CT scan (coronal slice).

The CT scan (Figures 1 and 2) done four days after the onset of symptoms, showed a small hypodense infarct in the anterior half of the right internal capsule with no obvious involvement of the caudate nucleus. No cortical lesions were shown before and after contrast-enhanced CT scan.

The motor symptoms regressed markedly over the next three weeks. Three months later the patient still complained of left sided weakness but the clinical examination as well as the constructive praxia were normal; only a left extinction was still demonstrated on the verbal dichotic listening test.

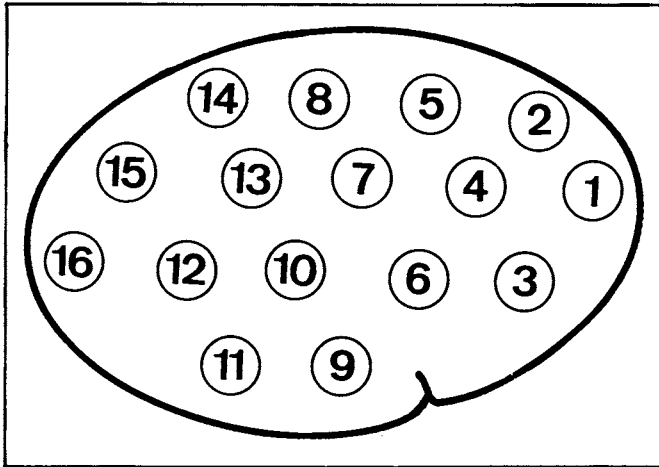


Fig. 3 - Position of the scanning probes.

In summary, this patient presented on the left side: (1) A reduction of the spontaneous motricity without any motor deficit. (2) A decreased withdrawal motor reaction to pain. (3) A reversibility of these symptoms after verbal stimulation. (4) A left motor extinction.

The present case is not a pure MN since mild constructive apraxia and left sided extinction on the verbal dichotic listening test were also demonstrated.

MEASUREMENTS OF CEREBRAL BLOOD FLOW (CBF)

Material and Methods

CBF was measured four weeks after the onset of the symptoms by the Xenon 133 (^{133}Xe) inhalation technique (Obrist, Thompson, Hsioh Shan Wang and Wilkinson, 1975; Risberg, 1980). The equipment used (novocerebrograph) has 32 detectors positioned over both hemispheres. After informed consent, the patient was initially scanned over a 30 seconds period for a baseline study. Then, the patient inhaled a gaseous mixture containing ^{133}Xe (10^8 Bq/l) during one minute. The exhaust circuit was then opened and the patient breathed the room air for 10 minutes. The pCO_2 and the radioactivity were recorded. The curve of arterial blood radioactivity was deducted from the end-tidal air curve and served to compute the tracing of the 32 cerebral activity curves. CBF was measured from the washout curves by estimation of the initial slope index (ISI) as described by Risberg (1980).

The positioning of the scanning probes is illustrated on Figure 3.

Protocol

The patient was submitted to three CBF measurements: rest, right hand activation, left hand activation, interrupted by one hour each. The resting measurement was done in a supine position with the eyes closed and the ears occluded. The activation measures were made over 11 minutes by having the patient feel different objects with the same hand for 30 seconds each for a total of 22 objects. The left hand was used first, followed by the right hand one hour later. Adequate palpation of the objects was ascertained by having the patient enumerate the objects felt after the measurement had been completed and by direct observation of the patient contact during the examination.

TABLE I

Patient; ISI Values at Rest and During Activation: ISI Increases During Activation vs. Rest

Condition	Rest		Activation right hand		Activation left hand	
pCO ₂ (mmHg)	39		38		38.4	
	LH	RH	LH	RH	LH	RH
Mean CBF	34.3	32.1	36.4	34.6	35.8	35.4
1	41	38	35	37	34	37
2	38	33	38	34	34	34
3	34	35	41**	40*	44*	42*
4	37	30	36	34	37	35*
5	35	32	36	33	35	30
6	31	33	32	33	34	34
7	32	30	36	32	36	30
8	32	33	39*	33	36	33
9	28	28	33*	32	39**	35**
10	32	31	35	35	36	34
11	34	32	35	37*	34	37
12	37	32	35	36	37	39**
13	34	30	35	33	37	34
14	28	31	39**	34	35**	35
15	36	32	35	34	33	33
16	41	33	40	37	39	46*

* .01 < p < .05.

** p < .01.

LH = Left hemisphere; RH = Right hemisphere.

TABLE II

Controls (same remarks as Table I)

Condition	Rest		Activation right hand		Activation left hand	
pCO ₂ (mmHg)	42 ± 2.1		40.9 ± 4.2		41.1 ± 3.6	
	LH	RH	LH	RH	LH	RH
Mean CBF	43.4	44.6	49.4**	49.7**	49.2**	50.1**
1	44.2	44.8	48.8	48.8*	47	49.4*
2	42.2	43.2	47.8	46.4	46.8	48.2
3	44.2	46.6	50.8*	49.8	50.4*	50.8*
4	44.4	45.8	50.8*	52.4*	49.4*	50.6*
5	43.3	44.6	51*	51*	48.6	49*
6	44.2	45.4	49.6*	49.4	48.8	50.4*
7	44	44.2	50.2*	50.6*	49.2*	50.4*
8	41.8	43.2	49.6**	49.4*	46.6*	49.6*
9	42.6	43.4	47.6*	46.6	49*	48.4
10	43	44.8	49.4	50.6**	50*	50.6**
11	44.6	48.4	51.8	50.8	54*	53.2
12	45.6	44.4	50.6*	52.4**	52.2**	52.6**
13	41.8	44.6	50.4*	51.4*	49.4*	50.6*
14	40.4	41.8	45	47	46*	48.4
15	42	43.8	49*	47.8	48.8**	47.6*
16	46	43.8	48.4	51.4	50.6*	51.8

Five healthy right handed controls, three men and two women aged from 37 to 75 year old (mean: 56 y.o) underwent the same protocol for comparison.

Results

The results are shown in Table I for our patient and in Table II for the controls. For the patient, the ISI differences between baseline vs-activation were considered significant $p < 0.05$ if above 14.5% and $p < 0.01$ if above 19%. Controls were studied using the Student *t* test on matched series.

Comments

In control subjects, CBF at rest was slightly higher in the frontal and temporal regions when compared to the rolandic and parietal areas; a significant asymmetry existed in the postero-inferior region (probe 11), the flow being lower on the left side. During activation studies, the increase in CBF in the hemisphere contralateral to the hand used was similar on the left and right side. This increase bore both on the mean hemispheric CBF and regional CBF (rCBF) in the following territories: orbito-frontal and inferior pre-rolandic (probes 3, 4), superior pre-rolandic (probe 5), rolandic (probes 6, 7, 8), parietal (probes 13, 15) and temporal.

The mean and regional CBF of the hemisphere ipsilateral to the hand used were rather similar to the contralateral values. The small series of controls could explain this lack of interhemispheric asymmetry by a "crosstalk" phenomenon, a probe recording activity contralateral to its position.

In our patient, the mean CBF at rest was slightly lower than in controls in both hemispheres (ISI of 32.1 on the right, and 34.3 on the left, no significant difference), with no localized hypoperfusion area.

During activation studies of the right hand, the left hemisphere showed a similar increase of CBF when compared to controls, but in a smaller area: orbito-frontal (probe 3), temporal (probe 9) and very high activation on the high rolandic cortex (probe 8) above the primary sensori-motor cortex of the hand and also of the superior parietal cortex (probe 14). There was no superior pre-rolandic activation.

During activation studies of the left hand, significant increases of regional CBF occurred in the following right hemispheric areas: orbito-frontal (probe 3), inferior pre-rolandic (probe 4), temporal (probe 9, 11, 12) and occipital (probe 16). There was however no change in CBF of the rolandic (probe 6, 7, 8) and superior pre-rolandic (probe 5) areas.

The patient thus showed a low flow at rest without regional hypoperfusion nor inter-hemispheric asymmetry. During manipulation studies of the left hand, there was no significant activation of neither the rolandic nor the superior pre-rolandic cortex whereas the activation of the remaining cortex was similar to controls.

DISCUSSION

Usually part of the non dominant hemisphere syndrome (Cambier, Elghozi and Strube, 1980; Cambier, Masson, Graveleau and Elghozi, 1982; Watson, Valenstein and Heilman, 1981), pure MN is quite rare and the lesions described have numerous locations, most of them in the right subcortical areas: parieto-temporal or mid-frontal (Castaigne, Laplane and Degos, 1970; Castaigne, Laplane and Degos, 1972), thalamic (Schott, Laurent, Mauguière and Chazot, 1981; Laplane, Escourolle, Degos, Sauron and Massion, 1982), anterior limb of the internal capsule (Viader, Cambier and Pariser, 1982), internal capsule and lenticulostriate structures (Valenstein and Heilman, 1981).

Considering CBF, an increase in regional CBF (rCBF) in the contralateral primary sensori-motor cortex after activation of the hand was first demonstrated by Olesen (1971) and further confirmed by subsequent studies done either with an intracarotid injection or inhalation of Xe133 (Roland and Larsen, 1976; Ingvar and Philipson, 1977; Orgogozo and Larsen, 1979; Roland, Skinhoj, Lassen and Larsen, 1980; Gelmers, 1980; Meric, Luft, Seylaz and Mamo, 1983). This constant activation is directly proportional to the strength

(vs. intensity) of the movement. When the executed movement comprises a minimum of complexity, the rCBF increase may also involve bilaterally the pre-frontal area including the supplementary motor area (SMA) (Ingvar and Philipson, 1977; Halsey, Blauenstein, Wilson and Wills, 1979; Orgogozo and Larsen, 1979; Roland, Larsen, Lassen and Skinhoj, 1980; Roland, Skinhoj, Lassen and Larsen, 1980; Eccles, 1982). This activation seems to be directly related to the movement itself since Larsen, Skinhoj and Lassen (1978) have shown it in subjects counting out but not when counting mentally. We can then consider in our patient the failure of activation of the right rolandic area during left hand movements normally performed as definitely abnormal. No lesion was seen on CT scan in the rolandic area to explain this failure and if such a lesion existed, abnormalities in the resting rCBF probably would have been demonstrated. The infarct in the anterior internal capsule could not explain such a defect by itself since its recording probe is lower situated than the superior rolandic probe. This could then be a "functional deficit" restricted to the right primary motor cortex, demonstrated only during movement without lack of activation of the other areas. Such a hemodynamic deficit despite correct motor performance suggests either a partial cortical inactivation enabling a sufficient level of function for motor execution, or involvement of different activating circuits.

In other respects, the possible lack of activation of the superior pre-rolandic area and presumably of the SMA cannot be regarded as definitely abnormal: Roland and Larsen (1976) found a high inter-subjects variability in this activation during a somesthetic discrimination protocol being the closest to the one we used (manipulation of prisms of different sizes). The lesion in the anterior limb of the internal capsule which causes an interruption of motor thalamic projection to the pre-frontal cortex, could be responsible for the inactivation of rCBF in the right superior pre-rolandic and then rolandic areas and therefore set up the physiopathological basis of the MN in our patient. Indeed the SMA is considered as the motor programming area initiating and supervising the execution of voluntary movements (Orgogozo and Larsen, 1979; Roland et al., 1980a; Roland et al., 1980b) and its removal in animal creates a picture of transient MN (Eccles, 1982). In addition experimental MN in the monkey has been ascribed to a break in a specific activating motor system which integrates the mesencephalic reticular formation, central structures of the thalamus and the ventrolateral and ventroanterior nuclei, the basal ganglia, the prefrontal cortex and anterior cingulum (Watson and Heilman, 1979; Watson, Valenstein and Heilman, 1981; Rizzolatti, Matesi and Pavesi, 1983; Watson, Valenstein, Day and Heilman, 1984). Finally we did not find any preferential rCBF increase of speech areas while the left hand was stimulated, making unlikely interference by interior speech when this hand was moving. Actually, the left hemisphere dominance for both speech and voluntary movement is thought to explain the dissociation between spontaneous motor function and intentional movement. This dissociation is the clue to MN, which is observed more frequently with right sided lesions, and could explain the reversible deficit under verbal stimulation (Laplante, Escourrolle, Degos, Sauron and Massion, 1982) and its transient nature.

Regarding the present case, the association between auditory extinction and MN possibly reflects the interrelations of different mechanisms for hemispheric activation. Even though a specialized loop for the motor activation exists, the functional and anatomical relationships with the system conducting one's attention and integrating sensory informations are numerous. Thus "the thalamo-frontal connections can be seen as the true activation pathway for the motor response in a hemisphere already activated by sensory inputs" (Viader et al., 1982). This would explain why MN is usually observed when a complete sensory neglect is present. This observation is not absolute since Dehen and Cambier (1980) reported a case of somatosensory, auditory and visual neglect without any MN.

In conclusion CBF studies in our patient give a hemodynamic and functional correlation to the MN syndrome. In a study of patients with permanent motor deficit after capsular lesions, Takano, Kimura, Nakamura et al. (1985) have demonstrated, using the intra-carotid ^{133}Xe technique, areas of hypoperfusion limited to the central cortex, which were present at rest. Our study, on the contrary, shows a dissociation between a normal resting flow and a localized hypoperfusion restricted to a specific cortical area which

appears only upon activation of this specific area. This dissociation reflects a dynamic phenomenon which correlates well with the neglect entity.

ABSTRACT

A sixty-nine year old hypertensive man had left motor neglect following an infarct of the anterior limb of the right internal capsule. He also had left auditory extinction on verbal dichotic listening and a slight constructional apraxia. Regional cerebral blood flow (CBF) was measured at rest with Xenon 133 inhalation and was found to be slightly decreased in a diffuse fashion. Motor activation of the right hand resulted in an increase of CBF in the contralateral superior rolandic area, whereas no such increase was found during motor activation of the left hand. This lack of cortical CBF increase on contralateral motor activation is interpreted as a consequence of the failure of some corticocortical connexions involved in motor arousal. The specifically dynamic appearance of regional CBF abnormalities, i.e. during selective activation as opposed to rest measurements, is consistent with the functional character of neglect.

Acknowledgement. We thank Ernst Meyer and Gilles Marshall from Montreal Neurological Institute and Hospital for their support help and advices and Carole Levert for typing the manuscript.

REFERENCES

- CAMBIER, J., ELGHOZI, D., and STRUBE, E. Lésions du thalamus droit avec syndrome de l'hémisphère mineur. Discussion du concept de négligence thalamique. *Revue Neurologique*, 136: 105-116, 1980.
- CAMBIER, J., MASSON, M., GRAVELEAU, Ph., and ELGHOZI, D. Sémiologie de négligence motrice lors des lésions ischémiques dans le territoire de l'artère cérébrale postérieure droite. Rôle de la lésion thalamique. *Revue Neurologique*, 138: 631-648, 1982.
- CASTAIGNE, P., LAPLANE, D., and DEGOS, J.D. Trois cas de négligence motrice par lésion rétro-rolandique. *Revue Neurologique*, 122: 233-242, 1970.
- CASTAIGNE, P., LAPLANE, D., and DEGOS, J.D. Trois cas de négligence motrice par lésion pré-rolandique. *Revue Neurologique*, 128: 5-15, 1972.
- DEHEN, H., and CAMBIER, J. Négligence somesthésique, visuelle, auditive et impersistence motrice par lésion ischémique limitée hémisphérique droite. *Nouvelle Presse Médicale*, 10: 249, 1980.
- ECCLES, J.C. The inhibition of voluntary movements by the supplementary motor area. *Archiven für Psychiatrie und Nervenkrankheit*, 321: 423-441, 1982.
- GELMERS, H.J. Cortical organization of voluntary motor activity as revealed by measurement of regional cerebral blood flow. *Journal of Neurological Sciences*, 52: 149-161, 1981.
- HALSEY, J.H., BLAUNSTEIN, U.W., WILSON, E.M., and WILLS, E.H. Regional cerebral blood flow comparison of right and left hand movement. *Neurology*, 29: 24-28, 1978.
- HEILMAN, K.M., and WATSON, R.T. Mechanisms underlying the unilateral neglect syndrome. *Advances in Neurology*, 18: 93-106, 1977.
- INGVAR, D.H., and PHILIPSON, L. Distribution of cerebral blood flow in the dominant hemisphere during motor ideation and motor performance. *Annals of Neurology*, 2: 230-237, 1977.
- LAPLANE, D., ESCOUROLLE, R., DEGOS, J.D., SAURON, B., and MASSION, H. La négligence motrice d'origine thalamique. A propos de deux cas. *Revue Neurologique*, 138: 201-211, 1982.
- LARSEN, B., SKINHOJ, E., and LASSEN, N.A. Variation in regional cortical blood flow during automatic speech. *Brain*, 101: 193-209, 1978.
- MERIC, Ph., LUFT, A., SEYLAZ, J., and MAMO, H. Analysis of reproducibility and sensitivity of atraumatic measurements of regional blood flow in cerebrovascular diseases. *Stroke*, 14: 82-87, 1983.
- OBRIST, W.D., THOMPSON, H.K., HSIOH, SHAN WANG, and WILKINSON, W.E. Regional cerebral blood flow estimated by 133 Xenon inhalation. *Stroke*, 6: 245-247, 1975.
- OLESEN, J. Contralateral focal increase of cerebral blood flow in man during arm work. *Brain*, 94: 635-646, 1971.
- ORGOGOZO, J.M., and LARSEN, B. Activation of the supplementary motor area during voluntary movement in man suggests it works as a supramotor area. *Science*, 206: 847-850, 1979.

- RISBERG, J. Regional cerebral blood flow measurement by 133 Xenon. Inhalation methodology and application in neuropsychology and psychiatry. *Brain and Language*, 9: 9-34, 1980.
- RIZZOLATTI, G., MATELI, M., and PAVESI, G. Deficit in attention and movement following the removal of postarcuate (area 6) and prearcuate (area 8) cortex in macaque monkeys. *Brain*, 106: 655-673, 1983.
- ROLAND, P.E., and LARSEN, B. Focal increase of cerebral blood flow during stereognostic testing in man. *Archives of Neurology*, 33: 551-558, 1976.
- ROLAND, P.E., LARSEN, B., LASSEN, N.A., and SKINHOJ, E. Supplementary motor area and other cortical areas in organization of voluntary movements in man. *Journal of Neurophysiology*, 43: 118-136, 1980.
- ROLAND, P.E., SKINHOJ, E., LASSEN, N.A., and LARSEN, B. Different cortical areas in man in organization of voluntary movements in extrapersonal space. *Journal of Neurophysiology*, 43: 137-150, 1980.
- SCHOTT, B., LAURENT, B., MAUGUIÈRE, F., and CHAZOT, G. Négligence motrice par hématome thalamique droit. *Revue Neurologique*, 137: 447-455, 1981.
- TAKANO, T., KIMURA, K., NAKAMURA, M., FUKUNAGA, R., KUSUNOKI, M., ETANI, H., MATSUMOTO, M., YONEDA, S., and ABE, H. Effect of small deep hemispheric infarction on the ipsilateral cortical blood flow in man. *Stroke*, 16: 64-69, 1985.
- VALENSTEIN, E., and HEILMAN, K.M. Unilateral hypokinesia and motor extinction. *Neurology*, 31: 445-448, 1981.
- VIADER, F., CAMBIER, J., and PARISER, P. Phénomène d'extinction motrice gauche. Lésion ischémique du bras antérieur de la capsule interne. *Revue Neurologique*, 138: 213-217, 1982.
- WATSON, R.T., MILLER, B., and HEILMAN, K.M. Non sensory neglect. *Annals of Neurology*, 3: 505-508, 1978.
- WATSON, R.T., and HEILMAN, K.M. Thalamic neglect. *Neurology*, 29: 690-694, 1979.
- WATSON, R.T., VALENSTEIN, E., and HEILMAN, K.M. Thalamic neglect possible role of the medial thalamus and nucleus reticularis in behavior. *Archives of Neurology*, 38: 501-506, 1981.
- WATSON, R.T., VALENSTEIN, E., DAY, A.L., and HEILMAN, K.M. The effect of corpus callosum lesions on unilateral neglect in monkeys. *Neurology*, 34: 812-815, 1984.