

# Multiple Intracranial Aneurysms in HIV Infection

Sumeet R. Dhawan<sup>1</sup> · Anju Gupta<sup>1</sup> · Vivek Gupta<sup>2</sup> · Pratibha D Singhi<sup>1</sup>

Received: 6 October 2015 / Accepted: 17 February 2016  
© Dr. K C Chaudhuri Foundation 2016

**Abstract** Neurological findings in HIV are common and include cognitive impairment, microcephaly, nonspecific white matter lesions and seizures. Cerebral vasculopathy and stroke are uncommon and may be due to primary HIV vasculopathy or opportunistic infections such as tuberculosis and cryptococcal meningitis. The authors describe a 7-y-old boy who presented with severe headache and was detected to have aneurysmal bleed due to intracranial aneurysm.

**Keywords** AIDS · Vasculitis · Intracranial hemorrhage · Subarachnoid hemorrhage

## Introduction

Almost half of the children with HIV have neurological manifestations [1]. These clinical features may include progressive loss of acquired milestones or stagnation of development. In a study, 89 % of children with HIV showed abnormalities in CT scan like cerebral atrophy (86 %), basal ganglia calcification (34 %), calcification at other sites, non-specific white matter changes, hemorrhage and infarction [1]. Intracranial vasculitis is seen in 1.6 % of patients with HIV [2]. The authors hereby describe a 7-y-old child who presented with catastrophic intracranial bleed secondary to intracranial aneurysms.

✉ Pratibha D Singhi  
doctorpratibhasinghi@gmail.com

<sup>1</sup> Department of Pediatrics, Postgraduate Institute of Medical Education and Research, Chandigarh 160012, India

<sup>2</sup> Department of Radiodiagnosis, Postgraduate Institute of Medical Education and Research (PGIMER), Chandigarh, India

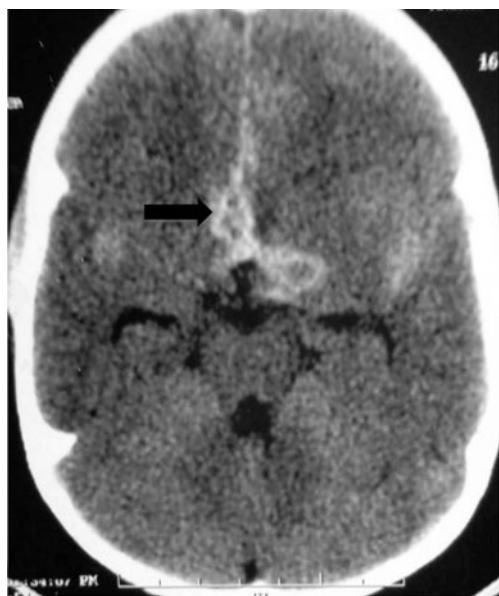## Case Report

A 7-y-old boy presented with low grade fever, severe headache and vomiting of 9 d duration. Headache was occipital and severe, causing difficulty in sleep. He also complained of dyspnea on exertion, progressive weight loss and low grade fever for 6 mo. Four years ago, he was treated for abdominal tuberculosis with anti-tubercular drugs for 9 mo. On examination, he had stunting, wasting, microcephaly (head circumference 46.5 cm), oral candidiasis, bald tongue, pallor, grade 2 clubbing, hepatosplenomegaly and neck stiffness. A possibility of tuberculosis reactivation with intracranial complications was suspected.

Fundus showed blurring of disc margins. He underwent computerised tomography which showed serpiginous hyperdense area in bilateral sylvian fissures extending into interhemispheric fissure and sulco-gyral space of frontal lobe with hyperdense area in basilar cistern suggestive of subarachnoid hemorrhage (Fig. 1). Magnetic resonance imaging (MRI) angiography showed dilatation of left internal carotid artery (ICA) in its supraclinoid portion extending into A1 segment and M1 segment of left middle cerebral artery (MCA) with small fusiform aneurysm from A2 segment of right ACA (Fig. 2a, b).

Other investigations revealed mild transaminitis, hemoglobin 8 g/dl, platelets 1,34,000/mm<sup>3</sup> and total leukocyte count 3900/mm<sup>3</sup> (65 % polymorphs, 31 % lymphocytes). Fine needle aspirate from cervical lymph node was normal. Contrast enhanced computerised tomography of chest showed collapse-consolidation and traction bronchiectasis in right middle lobe and lingula with pulmonary artery hypertension. Patchy areas of mosaic attenuation were seen in bilateral upper lobes. Ultrasonography of abdomen was normal.

Within 12 h, he developed generalised seizures with decerebrate posturing and shock for which he was intubated and put



**Fig. 1** CT head (axial) at the level of basal cisterns showing subarachnoid hemorrhage (arrow)

on manual ventilation; however he succumbed to his illness. Cerebrospinal fluid analysis (post mortem) was normal. Cerebrospinal fluid (CSF) analysis for *mycobacterium tuberculosis* (polymerase chain reaction, PCR), cryptococcus (India ink staining), herpes (PCR) and fungus (microscopy) was negative. Toxoplasma IgM and IgG antibodies were negative by ELISA. Blood and urine cultures were sterile. Postmortem lung biopsy did not show any granulomas or acid fast bacilli. Human Immunodeficiency Virus (HIV) ELISA was positive during the current illness. Both parents were also diagnosed as HIV positive subsequently.

## Discussion

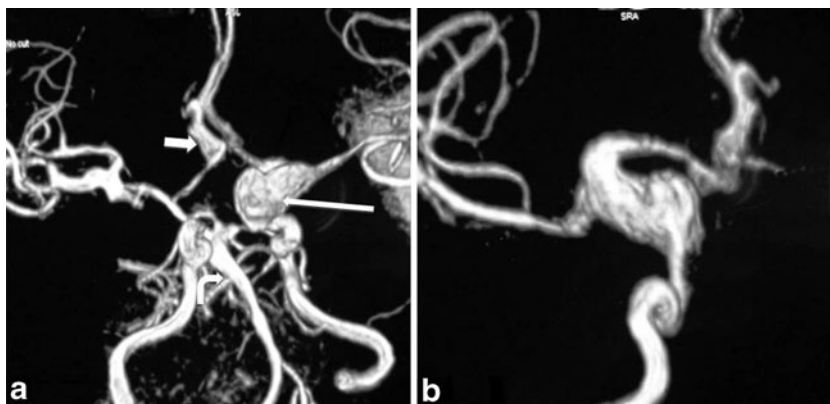
Intracranial vasculitis and aneurysms are rare and more common in children with HIV infection compared to adults [2]. Majority of aneurysms are asymptomatic until

they develop subarachnoid hemorrhage. Other extracranial aneurysms involving small, medium and large arteries may co-exist. Major branches of aorta and superficial and deep femoral arteries are commonly involved. HIV related aneurysms are frequently associated with high viral load and low CD4 counts and aneurysms may improve spontaneously with anti-retroviral therapy alone [2, 3]. In one study, one third of aneurysms were associated with varicella zoster virus [4]. Almost half of the children have 2 or more aneurysms [5].

Pathogenesis of intracranial vasculitis is not clearly understood [2]. Damage to internal elastic lamina is probably the initial event. This may lead to intimal hyperplasia, loss of muscularis and fibrosis of media. Damage to vascular tissue is indirect, through viral toxic factors or proteins. Secondary bacterial infections may lead to weakening of vascular wall, predisposing to rupture [6]. Rarely granulomatous angiitis may occur due to human-T-lymphotropic virus [7]. Inflammation of adventitia or interstitial edema involving vasa vasorum or leucoclastic vasculitis of vasa vasorum causes ischemia of intima leading to weakening of vascular wall. Aneurysms in HIV often affect the base of brain and spare the distal circulation. Co-existing systemic vasculitis such as polyarteritis nodosa, leucocytoclastic vasculitis and Henoch-Schonlein purpura has also been reported in one-fifth of patients with HIV [8].

Other opportunistic infections such as tuberculosis, toxoplasmosis, syphilis, herpes, and cryptococcus can also cause vasculitis and should always be excluded. The index child showed no meningeal enhancement and evaluation of above entities was unremarkable. CD4 lymphocyte count could not be done in the index child because of short hospital stay; however he had advanced clinical stage of disease. Though it would be difficult to differentiate if the vasculopathy is due to HIV or sequelae of previous infection, it is important to remember that acute neurological worsening in a child with HIV infection can also occur due to intracranial vasculopathy besides infection.

**Fig. 2** **a** Volume rendered (VR) MR angiography image showing fusiform dilatation of left internal carotid artery (ICA) extending into A1-anterior cerebral artery (ACA) and M1-middle cerebral artery (MCA) (long arrow). Also, the right proximal A2-ACA shows fusiform dilatation (short arrow). Distal basilar artery in posterior circulation also shows similar finding (curved arrow). **b** Oblique zoomed view of left ICA showing fusiform dilatation



**Contributions** SRD prepared the initial draft of the manuscript and was involved in management of the child, AG and VG were involved in management of the child and edited the initial draft and approved the final draft of manuscript for publication, PDS critically reviewed the draft and approved the final draft and will act as the guarantor.

**Compliance with Ethical Standards**

**Conflict of Interest** None.

**Source of Funding** None.

## References

1. Kauffman WM, Sivit CJ, Fitz CR, Rakusan TA, Herzog K, Chandra RS. CT and MR evaluation of intracranial involvement in pediatric HIV infection: a clinical-imaging correlation. *AJNR Am J Neuroradiol.* 1992;13:949–57.
2. Martinez-Longoria CA, Morales-Aguirre JJ, Villalobos-Acosta CP, Gomez-Barreto D, Cashat-Cruz M. Occurrence of intracerebral aneurysm in an HIV-infected child: a case report. *Pediatr Neurol.* 2004;31:130–2.
3. Mazzoni P, Chiriboga CA, Millar WS, Rogers A. Intracerebral aneurysms in human immunodeficiency virus infection: case report and literature review. *Pediatr Neurol.* 2000;23:252–5.
4. Dubrovsky T, Curless R, Scott G, et al. Cerebral aneurysmal arteriopathy in childhood AIDS. *Neurology.* 1998;51:560–5.
5. Chetty R, Batitang S, Nair R. Large artery vasculopathy in HIV-positive patients: another vasculitic enigma. *Hum Pathol.* 2000;31:374–9.
6. Bulsara KR, Raja A, Owen J. HIV and cerebral aneurysms. *Neurosurg Rev.* 2005;28:92–5.
7. Shah SS, Zimmerman RA, Rorke LB, Vezina LG. Cerebrovascular complications of HIV in children. *AJNR Am J Neuroradiol.* 1996;17:1913–7.
8. Gherardi R, Belec L, Mhiri C, et al. The spectrum of vasculitis in human immunodeficiency virus-infected patients. A clinicopathologic evaluation. *Arthritis Rheum.* 1993;36:1164–74.