

# Illustrative Teaching Case

Section Editors: Scott Silverman, MD, and Sophia Sundararajan, MD, PhD

## Cardioembolic Stroke in Adults With a History of Congenital Heart Disease

Hatim Attar, MD; Alok Sachdeva, MD; Sophia Sundararajan, MD, PhD

A 47-year-old right-handed white woman with a history of congenital heart disease (CHD) had witnessed onset of aphasia. She was taken to a nearby emergency department where laboratory values, ECG, and a computed tomography of the head were normal. She had a right hemiparesis and aphasia with an National Institutes of Health stroke score (NIHSS) of 20; however, her examination improved and she was not given recombinant tissue-type plasminogen activator. Aspirin was administered for suspected ischemic stroke, and she was transferred to a comprehensive stroke center. On arrival, her NIHSS worsened to 16 and intravenous recombinant tissue-type plasminogen activator was administered 3 hours and 44 minutes after onset. Emergent magnetic resonance imaging showed diffusion restriction within the left basal ganglia and occlusion of the left middle cerebral artery. Because of a large perfusion/diffusion mismatch, embolectomy was performed using a retrievable stent with complete revascularization (thrombolysis in cerebral infarction revascularization score: 2b). After the procedure, her NIHSS reduced to 8. She had no other stroke risk factors other than her CHD.

At birth, she was diagnosed with a double-inlet left ventricle with dextro-transposition of the great arteries. A hybrid procedure with bilateral pulmonary artery banding and bilateral arterial duct stenting was performed at 6 weeks of age. She underwent a Glenn operation at the age of 12 years, which was complicated by transient postoperative left hemiparesis. She had a Fontan operation at age 25 years after which she recovered to New York Heart Association functional class I. No antithrombotic medications were prescribed.

Work up for her current stroke included transthoracic echocardiogram and cardiac magnetic resonance imaging, which showed a double-inlet left ventricle with D-transposition of the great arteries. There was a hypoplastic right ventricular chamber. A right to left shunt via the Fontan fenestration (artificially created between venous circulation and atrium) or veno-venous collateral could not be ruled out. She had a complete cardiopulmonary anastomosis with an intracardiac baffle (surgically created tunnel or channel directing blood from the inferior vena cava to the pulmonary arteries). No atrioventricular valve regurgitation was noted. The left atrium

was enlarged and the ejection fraction was 55%. No thrombus was visualized.

Telemetry monitoring revealed frequent premature ventricular complexes but no persistent arrhythmia and prolonged outpatient monitoring also failed to show atrial fibrillation. Lower extremity ultrasound was negative for deep vein thrombosis. Because her cardiac anatomy predisposed her to atrial arrhythmia and paradoxical emboli, cardiologists recommended therapeutic anticoagulation. Her NIHSS score was 4 at discharge and 3 at 3 months. Unfortunately, 5 months later, she had a recurrent mild stroke with a subtherapeutic international normalized ratio (INR).

CHD is the most common birth defect, affecting 8 of every 1000 newborns. Defects range from simple asymptomatic defects to complex, life-threatening conditions. CHD may be broadly classified into cyanotic and acyanotic heart disease, both of which increase stroke risk because of the original structural abnormalities and indirectly via compensatory mechanisms and new structural abnormalities created by surgical correction. Diagnosis can be made by echocardiography (transthoracic or transesophageal) or, increasingly, by cardiac magnetic resonance imaging. Mechanisms for stroke include paradoxical embolism, arrhythmias, hyperviscosity, dilated cardiac chambers, and surgical correction leading to in situ thrombosis (Figure).

### Types of CHD

CHDs are categorized as cyanotic or acyanotic. Cyanotic CHD has reduced flow through the pulmonary circulation with right to left shunting of blood resulting in cyanosis and compensatory erythrocytosis. Cyanotic CHD predisposes to ischemic stroke by allowing paradoxical embolization and hyperviscosity. Cyanotic CHDs include Tetralogy of Fallot, total anomalous pulmonary venous connection, hypoplastic left heart syndrome, transposition of the great arteries, truncus arteriosus (persistent), and Eisenmenger syndrome (Table). Most of these anomalies share common physiology, with pulmonary stenosis and venous blood bypassing the lungs leading to deoxygenated blood in the systemic circulation. An exception is Eisenmenger syndrome, in which pulmonary vascular resistance increases with time, resulting in reversal

Received March 14, 2016; final revision received March 14, 2016; accepted March 16, 2016.

From the Neurological Institute, University Hospitals Case Medical Center, Cleveland, OH.

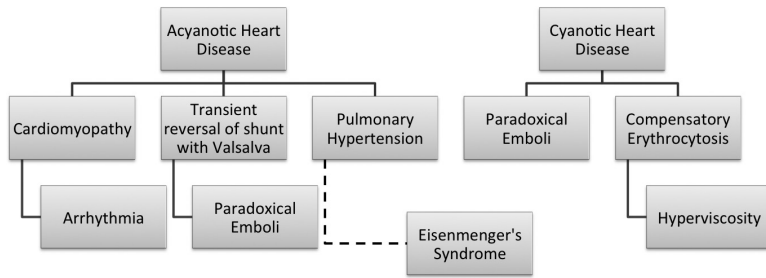
Correspondence to Sophia Sundararajan, MD, PhD, Neurological Institute, University Hospitals/Case Medical Center, 11100 Euclid Ave, Cleveland, OH 44106. E-mail [sophia.sundararajan@UHhospitals.org](mailto:sophia.sundararajan@UHhospitals.org)

(*Stroke*. 2016;47:e79-e81. DOI: 10.1161/STROKEAHA.116.012882.)

© 2016 American Heart Association, Inc.

*Stroke* is available at <http://stroke.ahajournals.org>

DOI: 10.1161/STROKEAHA.116.012882



**Figure.** Mechanisms of ischemic stroke in acyanotic and cyanotic heart disease.

of left to right shunts. Tetralogy of Fallot and Eisenmenger syndrome are the most common cyanotic CHDs and are both associated with stroke.

Acyanotic CHDs have normal flow through the pulmonary circulation and normal oxygenation. The most common forms are ventricular septal defects followed by atrial septal defects. Seventy percent of ventricular septal defects are located in the membranous interventricular septum and 20% in the muscular septum.<sup>1</sup> About 40% of septal defects close spontaneously by age 2 years and 90% by age 10 years.<sup>2,3</sup> Small defects are likely to be clinically silent but large defects can increase pulmonary vascular pressure and cause reversal of left to right shunting with subsequent cyanosis.

### Stroke Pathogenesis and Management

#### Paradoxical Embolism

In normal circumstances, the pulmonary capillary bed acts as a filter, preventing venous embolic material from reaching the arterial circulation. However, right to left shunts allow emboli to cross into the arterial circulation without traversing the lungs. This phenomenon, called paradoxical embolism, is one of the most common mechanisms of stroke in patients with CHD.

Right to left shunts can be detected by a bubble test. Echogenic microbubbles, created by agitated saline or echo contrast, are injected intravenously. Bubbles entering the pulmonary circulation would normally be filtered by the lungs but with a shunt can cross into the left heart and arterial circulation where they can be detected by echocardiography or transcranial Doppler. If no bubbles are detected, having the patient cough or strain increases intrathoracic pressure and may provoke right-to-left shunting. Transesophageal echocardiography is superior to transthoracic echocardiography for identifying both embolic material within the left atrium and potential shunts.<sup>4</sup>

Treatment of paradoxical emboli should consider both clot prevention and shunt correction. Anticoagulation is indicated if patients develop deep vein thrombosis, pulmonary embolism, or atrial fibrillation.<sup>5</sup> Patients without clear indication for anticoagulation should be treated with antiplatelet agents. Most atrioventricular defects are small and do not increase pulmonary arterial pressures. In these cases, pulmonary vascular disease is unlikely to develop and patients do not require surgical closure. In contrast, large defects can result in left ventricular failure and pulmonary hypertension, leading to right ventricular failure in adulthood.<sup>2</sup> Surgical closure is then recommended. Of note, paradoxical

embolism is not entirely eliminated by surgical repair of a cyanotic congenital malformation<sup>5</sup> and additional therapy is often indicated.

**Table.** Congenital Heart Disease: Variants and Anatomic Features

CHD Variants	Anatomic Features
Acyanotic conditions	
VSD	Structural defect in interventricular septum
ASD	Structural defect in interatrial septum
PDA defect	Persistent communication between pulmonary artery and aorta via ductus arteriosus
Atrioventricular septal defect	Endocardial cushion defect resulting in communication between all 4 chambers
Ebstein anomaly	Low-riding tricuspid valve into right ventricle, resulting in enlarged right atrium
Cyanotic conditions	
Tetralogy of Fallot	VSD, right ventricular hypertrophy, pulmonary stenosis, overriding aorta
Total anomalous pulmonary venous connection	Abnormal pulmonary vein drainage into right atrium, requires ASD to feed systemic circulation, otherwise fatal
Persistent truncus arteriosus	Failure of division of pulmonary arteries and aorta, resulting in common venous and arterial trunk
Hypoplastic left heart syndrome	Significantly underdeveloped left ventricle, requires PDA for survival otherwise fatal
Eisenmenger syndrome	Reversal of left-to-right shunt accordingly development of pulmonary hypertension
d-TGA	Parallel circulations consisting of aorta arising from right ventricle and pulmonary artery arising from left ventricle without communication, noncompatible with life

ASD indicates atrial septal defect; CHD, congenital heart disease; d-TGA, transposition of great arteries; PDA, patent ductus arteriosus; and VSD, ventricular septal defect.

### Hyperviscosity

Cyanotic CHD is associated with polycythemia and compensatory erythrocytosis with hematocrits at times over 70%. This can lead to hyperviscosity reducing oxygen delivery and increasing thrombotic events. Most thrombosis tends to occur in the venous system. Although phlebotomy is routinely used to prevent hyperviscosity for other diseases with erythrocytosis, in CHD it can cause iron deficiency with microcytic erythrocytes and secondary spherocytosis, which exacerbate viscosity and stroke risk.<sup>6-9</sup> Hydroxyurea has been tried as an alternative to phlebotomy, but it is not routinely used.<sup>6</sup>

### Infective Endocarditis

CHD also increases risk of infective endocarditis and resultant stroke. The altered cardiac anatomy may predispose to formation of infectious vegetations. In addition, infection may be introduced into the arterial circulation via a shunt if blood bypasses the lungs. American Heart Association guidelines recommend consideration of antibiotic prophylaxis in high-risk patients with CHD including unrepaired cyanotic CHD, repaired defects with prosthetic material/devices for 6 months after the procedure, and repaired CHD with residual defects at or adjacent to prosthetic patches or devices which may inhibit endothelialization.<sup>10</sup>

### Dilation of Cardiac Chambers

Patients with CHD may develop dilation of the cardiac chambers because of abnormal flow patterns. This allows stasis and thrombus formation within the chamber or may distort the conducting system and predispose to arrhythmias including atrial fibrillation. Stroke prevention in these cases relies on anticoagulation to prevent thrombus formation.

### Surgical Correction/Implanted Devices

Surgical correction of CHD may be a 2-edged sword with respect to ischemic stroke prevention. Although surgical procedures can serve to minimize shunts preventing paradoxical embolization and hyperviscosity, they may also expose and introduce thrombogenic surfaces into the heart. For example, prosthetic valves have been associated with a higher incidence of thrombotic events when compared with native valves. In addition, scarred tissue in the atria may dispose to the development of arrhythmias.

In summary, although CHD is an uncommon cause of ischemic stroke, patients who have CHD are at higher risk. Consideration of both traditional stroke risk factors such as dyslipidemia, hypertension, and diabetes mellitus as well as the individual characteristics of their CHD must be considered when developing treatment plans.

### Take-Home Points

- Adults with CHD have an increased risk of stroke.
- The most common mechanism of stroke associated with CHD is paradoxical embolism.
- Other mechanisms of cerebral infarction in CHD include hyperviscosity, septic emboli, intracardiac thrombus, and arrhythmias.
- Management including antiplatelets, anticoagulation, and surgical correction should be individualized.

### Acknowledgments

We acknowledge Krishnan Sundararajan for critical review of the article.

### Disclosures

None.

### References

1. Brickner ME, Hillis LD, Lange RA. Congenital heart disease in adults. First of two parts. *N Engl J Med*. 2000;342:256–263. doi: 10.1056/NEJM200001273420407.
2. Perloff JK. Survival patterns without cardiac surgery or interventional catheterization: a narrowing base. In: Perloff JK, Childs JS, eds. *Congenital Heart Disease in Adults*. 2nd ed. Philadelphia, PA: WB Saunders; 1998:15–53.
3. Weidman WH, DuShane JW, Ellison RC. Clinical course in adults with ventricular septal defect. *Circulation*. 1977;56(suppl):178–179.
4. Droste DW, Lakemeier H, Ritter M, Dittrich R, Stypmann J, Wichter T, et al. The identification of right-to-left shunts using contrast transcranial Doppler ultrasound: performance and interpretation modalities, and absence of a significant side difference of cardiac micro-emboli. *Neurol Res*. 2004;26:325–330. doi: 10.1179/016164104225014067.
5. Hirsch R, Streifler JY. Congenital heart disease and stroke. *Semin Cerebrovasc Dis Stroke*. 2005;5:13–20.
6. DeFilippis AP, Law K, Curtin S, Eckman JR. Blood is thicker than water: the management of hyperviscosity in adults with cyanotic heart disease. *Cardiol Rev*. 2007;15:31–34. doi: 10.1097/01.crd.0000214959.82120.97.
7. Rose SS, Shah AA, Hoover DR, Saidi P. Cyanotic congenital heart disease (CCHD) with symptomatic erythrocytosis. *J Gen Intern Med*. 2007;22:1775–1777. doi: 10.1007/s11606-007-0356-4.
8. Perloff JK, Marelli AJ, Miner PD. Risk of stroke in adults with cyanotic congenital heart disease. *Circulation*. 1993;87:1954–1959.
9. Perloff JK, Rosove MH, Child JS, Wright GB. Adults with cyanotic congenital heart disease: hematologic management. *Ann Intern Med*. 1988;109:406–413.
10. Wilson W, Taubert KA, Gewitz M, Lockhart PB, Baddour LM, Levison M, et al. Prevention of infective endocarditis: guidelines from the American Heart Association: a guideline from the American Heart Association Rheumatic Fever, Endocarditis, and Kawasaki Disease Committee, Council on Cardiovascular Disease in the Young, and the Council on Clinical Cardiology, Council on Cardiovascular Surgery and Anesthesia, and the Quality of Care and Outcomes Research Interdisciplinary Working Group. *Circulation*. 2007;116:1736–1754.

KEY WORDS: aphasia ■ cardiomyopathy ■ congenital ■ heart surgery ■ paradoxical embolism