

Transient Ischemic Attack After Foam Sclerotherapy in a Woman With a Patent Foramen Ovale

Michael Kim, OMS III
 Mehrdad Niroumandpour, OMS III
 Brian Poustinchian, DO

From the Midwestern
 University Chicago College
 of Osteopathic Medicine in
 Downers Grove, Illinois.

Financial Disclosures:
 None reported.

Support: None reported.

Address correspondence to
 Michael Kim, OMS III,
 Midwestern University
 Chicago College of
 Osteopathic Medicine,
 406 Woods Ln,
 Mailbox 1551,
 Downers Grove, IL
 60515-1269.

E-mail:
 mkim66@midwestern.edu

Submitted
 November 30, 2015;
 revision received
 February 9, 2016;
 accepted March 8, 2016.

Sclerotherapy is an increasingly popular treatment modality for patients with chronic venous insufficiency and varicose veins. Potential complications of foam sclerotherapy include cerebrovascular accidents and transient ischemic attacks (TIAs). We report the case of a 55-year-old woman who had a TIA shortly after undergoing foam sclerotherapy. She had presented for treatment with no confirmed risk factors for microemboli formation or thrombus. After the procedure, however, she had transient visual loss, dysarthria, confusion, and frontal headache, which resolved within 30 minutes of onset. A subsequent diagnosis of a patent foramen ovale was thought to have put her at risk for TIA in the setting of foam sclerotherapy. Osteopathic physicians should be aware of the potential for neurologic sequelae after foam sclerotherapy and inform patients prior to consent.

J Am Osteopath Assoc. 2016;116(5):320-323
 doi:10.7556/jaoa.2016.063

Sclerotherapy is a venous ablation technique used to manage chronic venous insufficiency, particularly in varicose veins, reticular veins, and telangiectasias. Although liquid-injection sclerotherapy is the criterion standard, foam sclerotherapy is becoming a popular alternative because of its efficacy and success rate.¹ A potential complication of foam sclerotherapy is the formation of gas microemboli in the brain, which can lead to neurologic deficits.^{2,3} In a study of 1025 patients who underwent sclerotherapy, 2.6% reported visual disturbances, migraines, or transient ischemic attacks (TIAs) developing after the procedure.¹ A study of 500 patients reported the incidence of transient visual disturbances after sclerotherapy as 0.09% to 2.0%, with most cases involving foam sclerotherapy.³

We present a case of neurologic sequelae after foam sclerotherapy in a patient with an undiagnosed patent foramen ovale (PFO). In patients with PFO, when the pressure in the right atrium increases, such as with the Valsalva maneuver, an asymptomatic PFO may open, thus increasing the risk of microemboli traveling into the left atrium and then traveling systemically.

Report of Case

A 55-year-old woman presented to the emergency department with visual disturbances, confusion, and dysarthria. Earlier in the day, she had undergone foam sclerotherapy, with no apparent complications. She noticed her symptoms while driving home after the procedure, which prompted her to return to the hospital. All of the symptoms

resolved within 30 minutes of onset. Before the procedure, her medical and social history were found to be unremarkable aside from self-reported migraines. Her family history did not indicate that she was at risk for thrombus formation or other contraindications for the procedure. She was taking ibuprofen as needed and levothyroxine for hypothyroidism.

In the emergency department, the patient was evaluated for a potential stroke, including computed tomography of the head, the results of which were unremarkable. She denied any chest pain, shortness of breath, palpitations, photophobia, phonophobia, or calf pain. She reported taking ibuprofen and levothyroxine. Osteopathic examination showed no cervical tenderness or tissue texture changes. Findings from the remainder of the physical examination, including cardiac and neurologic examinations, were unremarkable. T2-Fluid-attenuated inversion recovery magnetic resonance imaging showed no signs of an acute infarction, but multiple scattered areas of hyperintense white matter signal abnormalities in the periventricular left parietal lobe measuring 12 mm were observed and interpreted as nonspecific findings (Figure 1). The Neurology Department also performed magnetic resonance imaging of the cervical and thoracic spine to rule out any acute abnormalities. Transthoracic echocardiographic imaging while performing the Valsalva maneuver revealed a PFO (Figure 2). Electrocardiographic telemetry showed a normal sinus rhythm, and carotid Doppler ultrasonography did not show plaque formation.

Consultation with a neurologist led to a diagnosis of TIA due to a microembolism caused by the foam sclerotherapy in the setting of a PFO. Given the timing of the symptoms arising shortly after the procedure, her self-diagnosed migraines were not thought to contribute to her symptoms. The patient followed up with a cardiologist several months later and reported no recurrent episodes.

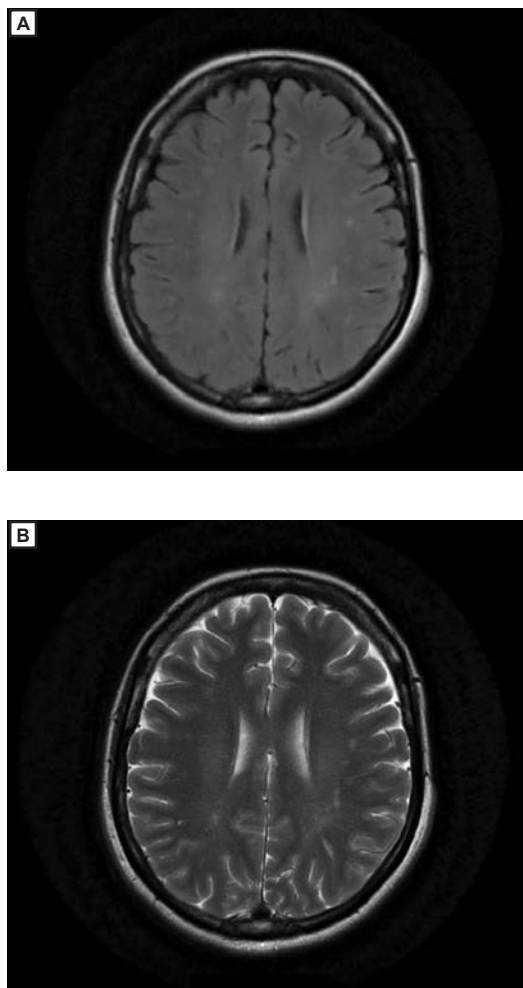


Figure 1.

Magnetic resonance image (A) and T2-fluid-attenuated inversion recovery image (B) of a patient presenting with neurologic symptoms after foam sclerotherapy. Image B shows multiple scattered areas (12 mm) of hyperintense white matter signal abnormalities in the periventricular left parietal lobe.

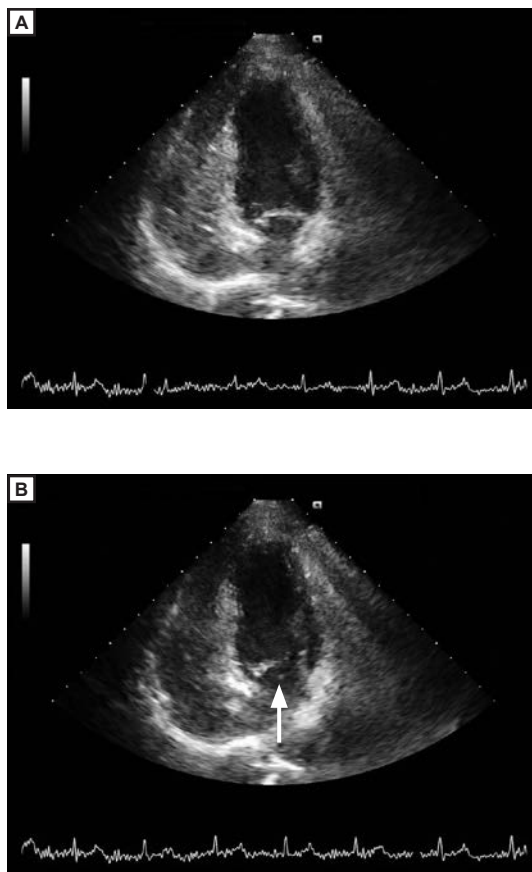


Figure 2. Transthoracic echocardiographic image (A) and while performing the Valsalva maneuver (B) shows a patent foramen ovale (arrow) in a patient presenting with neurologic symptoms after foam sclerotherapy.

Discussion

Assessing contraindications for sclerotherapy is vital given the potential complications of this procedure. *Figure 3* lists conditions in which patients should avoid foam sclerotherapy because of a hypercoagulable state that could lead to thrombus or microemboli formation. Migraine headaches and heart defects, such as a PFO, put patients at risk for microembolisms leading to TIAs or other neurologic conditions.⁴

The existence of a PFO could be unknown in a large number of patients, as it is largely asymptomatic.⁵ An autopsy study of 965 hearts from cadavers evenly distributed in age and sex showed the existence of a PFO in 25% to 30% of the hearts.⁵ The rather high incidence of PFO suggests the need to screen patients for PFO before sclerotherapy given the risks for neurologic sequelae.

A systematic review examined 69 studies to assess the risks for complications of sclerotherapy in the management of varicose veins. The median rates of pulmonary embolism and deep venous thrombosis were less than 1.0%. Rates for visual disturbances were 1.4%; headaches, 4.2%; thrombophlebitis, 4.7%; skin pigmentation or matting, 17.8%; and pain at injection site, 25.6%.⁶ *Figure 3* lists the potential complications of sclerotherapy, most of which are consequences of thrombus or emboli formation.

The patient in the current case did not meet any contraindications for sclerotherapy on presentation for treatment, and her reported headaches did not meet the clinical criteria for migraine. The undiagnosed PFO created a right-to-left shunt, which allowed microemboli to escape into the left atrium and enter the cerebral vasculature. One study⁶ examined cerebrovascular gas microemboli in 82 patients undergoing foam sclerotherapy. The patients were monitored with transcranial Doppler ultrasonography, and within 15 minutes of the procedure, a right-to-left shunt developed in 61 patients, allowing gas microemboli to flow into the middle cerebral artery.⁷ Knowledge of a PFO would allow proper guidance for patients who are consid-

Contraindications
Acute thrombosis
Acute thrombophlebitis
Pregnancy
Diabetes
Peripheral arterial occlusive disease
Migraines
Patent foramen ovale
Complications
Superficial thrombophlebitis
Deep venous thrombophlebitis
Pulmonary embolism
Transient ischemic attacks
Cerebrovascular accident
Anaphylaxis

Figure 3. Contraindications and complications of foam or liquid sclerotherapy.

ering sclerotherapy. For patients with a known PFO, liquid sclerotherapy may be the preferred method of treatment because it has fewer complications.

Conclusion

With the rise in popularity of foam sclerotherapy, it benefits physicians and patients to understand the risks of neurologic sequelae after this procedure. Our patient did not have obvious risk factors for complications of the procedure; however, she had visual and neurologic disturbances shortly after the procedure. It may be beneficial, therefore, to monitor patients for any symptoms before discharge from the medical office. Because neurologic complications are relatively rare, screening all patients for PFO may not be justified; however, a discussion with patients about potential complications may be warranted. Educating patients on stroke signs and symptoms and contraindications such as a PFO as a part of informed con-

sent, for example, should be communicated in case a patient has an undiagnosed PFO or another undiagnosed risk factor that could lead to complications from foam sclerotherapy.

References

1. Gillet JL, Guedes JM, Guex JJ, et al. Side-effects and complications of foam sclerotherapy of the great and small saphenous veins: a controlled multicenter prospective study including 1,025 patients. *Phlebology*. 2009;24(3):131-138. doi:10.1258/phleb.2008.008063.
2. Wong M. Should foam made with physiologic gases be the standard in sclerotherapy? *Phlebology*. 2015;30(9):580-586. doi:10.1177/0268355514560275.
3. Willenberg T, Smith PC, Shepherd A, Davies AH. Visual disturbance following sclerotherapy for varicose veins, reticular veins, and telangiectasias: a systematic literature review. *Phlebology*. 2013;28(3):123-131. doi:10.1177/0268355513486745.
4. Sarvanathan T, Shepherd AC, Willenberg T, Davies AH. Neurological complications of sclerotherapy for varicose veins. *J Vasc Surg*. 2012;55(1):243-251. doi:10.1016/j.jvs.2011.05.093.
5. Hagen PT, Scholz DG, Edwards WD. Incidence and size of patent foramen ovale during the first 10 decades of life: an autopsy study of 965 normal hearts. *Mayo Clin Proc*. 1984;59(1):17-20. doi:10.1016/S0025-6196(12)60336-X.
6. Jia X, Mowatt G, Burr JM, Cassar K, Cook J, Fraser C. Systematic review of foam sclerotherapy for varicose veins. *Br J Surg*. 2007;94(8):925-936.
7. Regan JD, Gilbson KD, Rush JE, Shortell CK, Hirsch SA, Wright DD. Clinical significance of cerebrovascular gas emboli during polidocanol endovenous ultra-low nitrogen microfoam ablation and correlation with magnetic resonance imaging in patients with right-to-left shunt. *J Vasc Surg*. 2011;53(1):131-137. doi:10.1016/j.jvs.2010.06.

© 2016 American Osteopathic Association