

Lacunar Infarct of the Tegmentum of the Lower Lateral Pons

C. Miller Fisher, MD

● A stroke with a somewhat unusual neurologic formula was correlated with a small linear high-intensity T₂ focus in the lateral tegmentum of the lower third of the pons. The clinical features included dysarthria, staggering gait, incoordination of handwriting, right facial weakness, nystagmus, ocular overshoot, right appendicular ataxia, and left-sided dissociated sensory loss for pain and temperature. Lacunar lesions of the tegmentum in the region of the pontomedullary junction, while not uncommon, have not been studied pathologically and have not been reported in the magnetic resonance imaging literature, to my knowledge.

(Arch Neurol 1989;46:566-567)

The literature on lacunar infarction has perhaps been overburdened with a plethora of clinical syndromes, which at times are confusing in their subtle complexities.^{1,2} It is therefore not easy to justify attempting to add still another, one involving the lateral tegmentum of the lower pons. This step is possibly warranted on two counts: first, it illustrates the essential role of magnetic resonance imaging (MRI) in the vascular field, and, second, it provides an opportunity to emphasize the point that small infarcts in the tegmentum of the lower pons or the pontomedullary junction have never (to my knowledge) been studied pathologically, are not detected by computerized tomography (CT), and have not been recognized by MRI.

REPORT OF A CASE

A right-handed hypertensive man, aged 64 years, noted slurred speech and a wobbly drunken gait one morning three hours after arising. He refrained from talking all

Accepted for publication June 15, 1988.
From the Neurology Service, Massachusetts General Hospital, Boston.

Reprint requests to Neurology Service, Massachusetts General Hospital, Boston, MA 02114 (Dr Fisher).

day and was able to sculpt normally. Next morning, speech and walking were unchanged, but handwriting was incoordinated. Later that day, on sitting back against the seat of his car, he experienced coolness in the right side of his back and his right leg but not in his left side. There was no change in the symptoms the next day. There had been no headache, diplopia, dizziness, numbness, or hiccups. His antihypertensive medication consisted of atenolol and captopril.

Examination 72 hours from the onset revealed normal intellect and memory. His speech was slightly slurred. His pupils were exactly equal and reactive to light. The ocular movements were full in all directions. Conjugate lateral gaze to the left evoked horizontal nystagmus of 1-mm amplitude. There was no vertical nystagmus. On conjugate gaze from the left lateral position to center, there was a 0.5-mm overshoot to the right. On conjugate gaze from the upper position to center, there was a 0.5-mm deviation to the left with correction. Optokinetic nystagmus was described as "not well organized." There was a slight right facial weakness and a delayed blink on that side. Sensation on the face was normal. Rapid *la la la* and *mi mi mi* sounds were well performed. The tongue was placed in each cheek with good strength. There was no dysphagia. Sweating was equal on the two sides of the face.

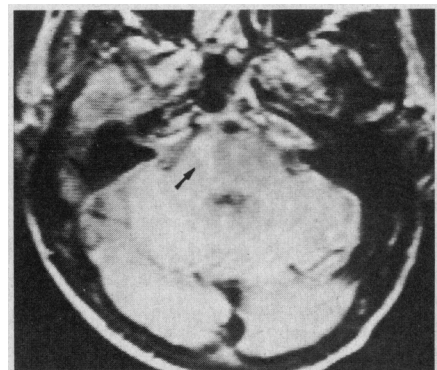
Motor power in the limbs was normal except for questionable weakness at the right shoulder. The tendon reflexes were equal on the two sides, and the plantar responses were flexor bilaterally. The jaw jerk was not increased. The abdominal reflex response to pinscratch was strikingly greater on the right side. There was a slight cerebellar ataxia on the finger-nose and heel-knee-tibia tests on the right side. Handwriting was slow and irregular. Finger tapping and toe tapping were slowed on the right. Sensation to pinprick and temperature was clearly impaired over the arm, trunk, and leg on the left side. Sensation for vibration and joint position was normal. Light touch was better perceived on the right side. The sole of the left foot was less ticklish than the right sole. The patient walked briskly with good stride, reporting he had to concentrate to prevent

staggering. With his eyes open, he could stand on each foot, although with much gyration. With the eyes closed, he could not stand on each foot. On walking a straight-line tandem, heel to toe, he sometimes toppled to the right, other times to the left. (His personal physician had by chance earlier in the day observed the patient staggering and lurching on the sidewalk.) His blood pressure was 160/100 mm Hg.

Relevant laboratory studies of the blood were not remarkable. An electrocardiogram was normal. A CT scan showed a low-density lacunar infarct in the right putamen, probably unrelated to the present illness. Magnetic resonance imaging showed a hyperintense T₂ focus in the right putamen and three hyperintense foci in the cerebral white matter. In addition, there was a linear focus of T₂ hyperintensity in the anterolateral aspect of the lower third or fourth of the pons on the right side, consistent with a small infarct (Figure). The abnormality was present on only one cross section. This lesion was not seen by CT. Flow voids were well demonstrated in the upper vertebral arteries and the lower basilar artery. An angiogram was not obtained.

CLINICAL COURSE

The patient was not reexamined but reported that in approximately two weeks, speech, balance, and handwriting



Magnetic resonance image at lower pontine level showing focus of T₂ hyperintensity in right lateral aspect of pons (arrow).

ing had become normal, and the sensory abnormality was less noticeable.

COMMENT

It was concluded that the lesion in the anterolateral part of the lower pons demonstrated on MRI satisfactorily explained the clinical picture. In that position, the right facial nerve could be involved (right facial weakness), as could the spinothalamic tract, which lies just lateral to the medial lemniscus (contralateral sensory loss). Damage to the nearby vestibular nuclei would account for the nystagmus and ocular instability. The right-sided appendicular cerebellar ataxia was attributed to involvement of the inferior cerebellar peduncle, which is immediately adjacent to the above-mentioned structures. The cerebellum itself was not affected, judging from the MRI, and it is unlikely that a small lesion of the middle cerebellar peduncle would cause such a widespread cerebellar deficit. The lesion lay lateral to the corticospinal

system and had to occupy a very low position in the pons to affect the ipsilateral facial nerve. Apparently, the auditory system, trigeminal complex, and sympathetic pathway were spared. The MRI showed no involvement of the lateral medulla. The elongated abnormality seen by MRI suggested an infarction of the lacunar type, probably caused by occlusion of a small penetrating artery, arising from the upper portion of the right vertebral artery or the lowermost basilar artery or a major branch of either of these arteries. The literature contains no report of the clinical-MRI correlation of a stroke at this particular site.

Strokes whose clinical features suggest infarction limited to the brainstem tegmentum in the region of the pontomedullary junction, ie, without corticospinal involvement, are by no means rare, yet, to my knowledge, there has never been a clinicopathologic study of such a case, and CT does not have the capability of demonstrat-

ing such lesions. Magnetic resonance imaging is the requisite tool. The stroke picture is usually complex, despite the small size of the lesion. When the infarct is close to the midline, there is usually vertigo, diplopia, internuclear ophthalmoplegia, horizontal gaze palsy, skew deviation, horizontal and vertical nystagmus, and sometimes numbness of the ipsilateral side of the face. When the lesion is further laterally, the symptomatology should resemble that of the case described in this article. A clinicopathologic study that bears on the present case³ involved the lateral tegmentum of both the medulla and the lower pons, but in the present case, the lesion seemed clearly to spare the medulla.

References

1. Mohr JP: Lacunes. *Stroke* 1982;13:3-11.
2. Fisher CM: Lacunar strokes and infarcts: A review. *Neurology* 1982;32:871-876.
3. Fisher CM, Tapia J: Lateral medullary infarction extending to the lower pons. *J Neurol Neurosurg Psychiatry* 1987;50:620-624.

Loss of Spontaneous Blinking in a Patient With Balint's Syndrome

Robert T. Watson, MD, Steven Z. Rapcsak, MD

● A patient with Balint's syndrome caused by bilateral parieto-occipital lesions lost spontaneous blinking, suggesting that humans, like nonhuman primates, have parietal lobe neurons that are important for blinking. Although the functions of spontaneous blinking are not known, they may help initiate some saccades and, like saccades, be involved in the cancellation of thalamic inhibitory postsynaptic potentials, thereby facilitating processing of new foveal targets. Spontaneous blinking may also facilitate sensory relay during sustained attention and, therefore, help prevent fading of a retinal image.

(*Arch Neurol* 1989;46:567-570)

Accepted for publication July 27, 1988.

From the Department of Neurology, University of Florida, Gainesville (Dr Watson); and the Department of Neurology, University of Arizona, Tucson (Dr Rapcsak).

Presented in part at the 20th Annual Winter Conference on Brain Research, Vail, Colo, Jan 28, 1987.

Reprint requests to Department of Neurology, Box J-236, J. Hillis Miller Health Center, University of Florida, Gainesville, FL 32610 (Dr Watson).

Balint's syndrome has three characteristic features: (1) optic ataxia, (2) disturbance of spatial attention (visual disorientation), and (3) psychic paralysis of gaze (ocular apraxia).¹ Spatial attention is concentrically narrowed, so that only objects in foveal vision are attended despite intact visual fields. In addition, patients with Balint's syndrome report that they see only one object in a simultaneous visual display of multiple objects, a defect that has been called *simultanagnosia*.² It has been proposed that restricted visual attention and simultanagnosia occur after bilateral damage to the ambient visual system,² sparing the foveal system. The ambient visual system functions to signal the presence of peripheral visual stimuli and shift attention from an object that is being viewed by the foveal system. Psychic paralysis of gaze refers to an inability to look toward a peripheral target even though eye movements can be shown to be intact. Psychic paralysis of gaze may also result from an inability to

attend to peripheral targets.³ Alternatively, it may be caused by a loss of parietal neurons that are involved in visually guided eye movements.^{4,5} A recent report of simultanagnosia without psychic paralysis of gaze suggests that these signs are dissociable.⁶

In addition to these core features, patients with Balint's syndrome do not blink to a peripheral visual threat. To our knowledge, a loss of spontaneous blinks (SBs) has not previously been reported either in Balint's syndrome or as a result of cortical lesions. We describe a loss of SBs in a patient with Balint's syndrome and explore possible relationships among SBs, attention, and psychic paralysis of gaze.

REPORT OF A CASE

A 41-year-old left-handed woman was treated for hypertensive encephalopathy. When discharged, her blood pressure was normal as were the results of her neurological examination. Three days later, she