


# Accepted Manuscript



A Case of Successful Manual Aspiration Thrombectomy in a Pediatric Patient

Gregory M. Weiner, M.D., Rafey A. Feroze, Nitin Agarwal, M.D., David M. Pancykowski, M.D., William J. Ares, M.D., Ali Kooshkabadi, M.D., Dana D. Cummings, M.D., Ph.D., Vincent Carson, M.D., Amin Aghaebrahim, M.D., Brian T. Jankowitz, M.D.

PII: S0887-8994(15)30216-2

DOI: [10.1016/j.pediatrneurol.2016.02.006](https://doi.org/10.1016/j.pediatrneurol.2016.02.006)

Reference: PNU 8852

To appear in: *Pediatric Neurology*

Received Date: 2 October 2015

Revised Date: 7 February 2016

Accepted Date: 14 February 2016

Please cite this article as: Weiner GM, Feroze RA, Agarwal N, Pancykowski DM, Ares WJ, Kooshkabadi A, Cummings DD, Carson V, Aghaebrahim A, Jankowitz BT, A Case of Successful Manual Aspiration Thrombectomy in a Pediatric Patient, *Pediatric Neurology* (2016), doi: 10.1016/j.pediatrneurol.2016.02.006.

This is a PDF file of an unedited manuscript that has been accepted for publication. As a service to our customers we are providing this early version of the manuscript. The manuscript will undergo copyediting, typesetting, and review of the resulting proof before it is published in its final form. Please note that during the production process errors may be discovered which could affect the content, and all legal disclaimers that apply to the journal pertain.

## **A Case of Successful Manual Aspiration Thrombectomy in a Pediatric Patient**

Gregory M. Weiner, M.D.<sup>1</sup>, Rafey A. Feroze<sup>2</sup>, Nitin Agarwal, M.D.<sup>1</sup>, David M. Pancykowski, M.D.<sup>1</sup>, William J. Ares, M.D.<sup>1</sup>, Ali Kooshkabadi, M.D.<sup>1</sup>, Dana D. Cummings, M.D.Ph.D.<sup>3</sup>, Vincent Carson, M.D.<sup>3</sup>, Amin Aghaebrahim, M.D.<sup>1</sup>, Brian T. Jankowitz, M.D.<sup>1</sup>

<sup>1</sup>Department of Neurological Surgery, University of Pittsburgh Medical Center, Pittsburgh, Pennsylvania, United States of America

<sup>2</sup>University of Pittsburgh School of Medicine, Pittsburgh, Pennsylvania, United States of America

<sup>3</sup>Division of Child Neurology, Department of Pediatrics, Children's Hospital of Pittsburgh, University of Pittsburgh Medical Center, Pittsburgh, Pennsylvania, United States of America

### **Funding Statement**

This research received no specific grant from any funding agency in the public, commercial or not-for-profit sectors.

### **Competing Interests Statement**

The authors have no personal or institutional interest with regards to the authorship and/or publication of this manuscript.

### **Contributorship Statement**

GMW, RAF, NA, and BTJ were involved the design and writing of the paper. DMP, AK, DC, VC, AA were involved in review of the report.

### **Corresponding Author**

Brian Jankowitz, M.D.  
University of Pittsburgh Medical Center  
Department of Neurological Surgery  
200 Lothrop Street, Suite B-400  
Pittsburgh, PA 15213-2582  
P: 412-471-4772  
F: 412-647-0989  
E: jankbt@upmc.edu

**RUNNING TITLE:** Mechanical Aspiration Thrombectomy for Pediatric Stroke**ABSTRACT**

**INTRODUCTION:** Timely recognition of pediatric stroke at major medical centers is improving and while treatment guidelines for pediatric stroke exist, no extensive study establishing the efficacy of surgical or thrombolytic treatment has been completed. Extrapolation of adult guidelines to pediatric patients remains the mainstay of treatment without adequate information available regarding safety and efficacy in children. Recent trials have demonstrated revascularization and clinical improvement following endovascular retrieval therapy in adults with acute large vessel occlusive stroke. Furthermore, mechanical thrombectomy using a variety of techniques has been successful in numerous pediatric stroke cases reported in the literature.

**CLINICAL PRESENTATION:** We present a patient with altered mental status and left hemiparesis diagnosed with acute ischemic stroke due to blockage of the right ICA terminus most likely precipitated by end stage heart failure and cardio-embolism. Mechanical Aspiration Thrombectomy (MAT) using the Penumbra Aspiration catheter without any adjunct surgical equipment or thrombolytic therapy was used to remove thrombus and treat the patient's acute ischemic stroke. Complete recanalization with a TICI score of 2C was observed following the procedure. The Patient exhibited an 8 point improvement in pediatric NIHSS score within 24 hours.

**CONCLUSIONS:** MAT is commonly used in hospitals but not usually applied in the setting of pediatric arterial ischemic stroke. Given its efficacy as described in this study, we encourage a larger systematic trial to evaluate the use of mechanical thrombectomy in pediatric cases of acute ischemic stroke.

**KEY WORDS:** Pediatric; Acute Ischemic Stroke; Middle Cerebral Artery; Thrombectomy; Endovascular; Penumbra; Aspiration

## INTRODUCTION

Pediatric cerebrovascular disorders constitute one of the ten most common causes of death in children. An incidence of 1.2 to 13 stroke cases per 100,000 children has been reported.<sup>1</sup> In addition, pediatric stroke is associated with high morbidity and life-long neurologic deficits<sup>2</sup>. Increased awareness of pediatric stroke lead to an NINDS-sponsored panel workshop that recommended development of systematic pediatric stroke registries and studies leading to clinical trials.<sup>2,3</sup>

Approximately 87% of strokes in adults are ischemic, while only about 13% are hemorrhagic in nature. In contrast, only about 50% of pediatric strokes are ischemic. A 3-6% mortality and 70% risk of lifetime morbidity has been reported for pediatric patients following acute ischemic stroke (AIS).<sup>4</sup> Currently approved acute pharmacologic treatments are limited to heparin, aspirin, and vitamin K antagonists.<sup>6,7</sup>

Recent studies in adults, such as the ESCAPE, EXTEND IA, and MR. CLEAN trials, have demonstrated successful revascularization and improved clinical outcomes following endovascular treatment of AIS.<sup>8</sup> Extending such treatment to pediatric stroke is expected to be promising. Mechanical thrombectomy using a variety of methods has been attempted successfully for pediatric AIS with large vessel occlusion (LVO) in case reports but no clinical trials have been conducted to prove efficacy. In Class IIb recommendations on endovascular treatment of pediatric acute ischemic stroke by Ellis et al.,<sup>9</sup> mechanical approaches alone or augmented with tPA are suggested over solitary thrombolytic treatment due to a reduced hemorrhage rate. As such, we present the case of a 15 year old patient with AIS caused by a right ICA terminus occlusion treated successfully with mechanical aspiration thrombectomy (MAT).

## CLINICAL PRESENTATION

### Clinical History

A 15 year old male patient with a history of hypoplastic left heart syndrome and listed Status 1A for orthotopic heart transplant presented with right sided MCA syndrome. Stroke symptoms developed while patient was at home, 5 hours prior to arriving at the hospital. While bending over to pick up his glasses, the patient developed dizziness, a headache, and left extremity weakness. A family member discovered him on the ground unable to move his left arm and leg. On examination, the patient was found to have altered mental status, decreased left sided sensation, left sided hemiparesis, and right sided gaze preference. He suffered from loss of spontaneous movement and light touch discrimination in the left arm (3/5) along with left lower extremity weakness (4/5). His pediatric National Institutes of Health Stroke Scale (NIHSS) score was 9 at time of presentation. Magnetic resonance imaging (MRI) of the brain revealed ischemic stroke in the right middle cerebral artery (MCA) distribution (Figure 1A, C, E). Magnetic resonance perfusion imaging indicated significantly reduced blood flow in the right hemisphere (Figure 1G). A catheter based cerebral angiogram indicated the presence of thrombus at the right

internal carotid artery (ICA) terminus (Figure 2A). After consultation with neurology, the patient was deemed appropriate for endovascular management. The unestablished nature of the procedure along with associated risks of incomplete thrombus removal and hemorrhagic conversion were discussed with the pediatric transplant cardiologist and patient's parents. Informed consent was obtained. Approximately 8 hours following estimated symptom onset, mechanical aspiration thrombectomy (MAT) of the ICA terminus and M1 segment was performed. He returned to the pediatric intensive care unit (ICU) intubated for further management.

### **Surgical Technique**

Arterial access was gained using a 5 French (F) micropuncture kit to place a 6F sheath in the right common femoral artery. The sheath was exchanged for a Penumbra 6F 088 NeuronMax base catheter which was advanced over a 5F diagnostic catheter into the right ICA. A triaxial system consisting of a 064 Penumbra ACE aspiration catheter, a microcatheter and a microwire were advanced into the right ICA occlusion. The microcatheter and wire were removed and the ICA thrombus was removed by direct manual aspiration thrombectomy (MAT) through the ACE with a 20cc syringe. Repeated runs revealed a residual right M1 occlusion. The procedure was repeated in the M1 resulting in, TIMI II/TICI 2Cflow (Figure 2b). The aspiration system was removed and manual pressure at the groin puncture site was held for 20 minutes. Revascularization was achieved 8 hours from onset of the patient's symptoms.

### **Postoperative Course**

At the pediatric ICU, 5 hours following thrombectomy, the patient was allowed to awaken to the point where a limited neurologic exam was possible and subsequently extubated. The patient was able to move all 4 extremities on command. Examination by neurology 8 hours after intervention revealed Pediatric NIHSS score of 1 point for leg weakness. Follow-up MRI was performed 5 hours following thrombectomy revealing shrinkage of infarcts (Figure 1B, D, F). The final volume of the patient's infarct based upon diffusion weighted imaging was 21 cc. A 24 hour post procedure head CT revealed no hemorrhagic conversion. While there is limited evidence in the pediatric literature regarding restarting anticoagulation following thrombectomy for cardioembolic stroke, the current patient was thought to be at risk for another thrombotic episode. To mitigate this risk, aspirin and low dose heparin were restarted 24 hours after the thrombectomy. On post procedure day 1, the initial neurological deficits were again noted to be resolved, except for minimal left sided weakness, corresponding with a pediatric NIHSS score of 1. Milrinone, sotalol, spironolactone, and sildenafil were continued for the patient's heart condition and he was discharged. On follow-up neurology evaluation 6 weeks after presentation, he had pediatric NIHSS score of 0, a left orbit sign, 5-/5 Medical Research Council (MRC) strength in left arm and leg, and subtle left leg limp on walking. The patient remained healthy enough to receive a heart transplant 7 weeks later.

## DISCUSSION

We present a pediatric case of AIS due to LVO treated successfully with MAT, resulting in recanalization of the right ICA terminus and almost complete resolution of neurologic symptoms. It has been recommended that patients with LVO be considered for endovascular treatment.<sup>9</sup> Our choice of thrombectomy was based on these criteria as well as the patient's altered mental status, hemiplegia, and presence of ischemia caused by occlusion as revealed by magnetic resonance angiography. This intervention was only offered to the family after thoughtful discussions with the patient's transplant cardiologists who concluded that thrombectomy offered the best chance for improved clinical outcome and maintaining the health of the patient until a heart became available for transplant. The present article is the third report demonstrating the use of MAT without any adjunct devices, to successfully treat pediatric stroke.<sup>10, 11</sup> Successful revascularization with MAT in the present case qualifies it as a potential treatment for AIS in children.

Successful endovascular intervention in a number of cases from the literature and the present report are testament to the potential of mechanical thrombectomy in pediatric AIS treatment. Table 1 contains a summary of published cases employing mechanical endovascular techniques for treating pediatric strokes. Twenty seven cases with an age range from 2-17 years have been included, with regions of occlusion in the anterior and posterior circulation.

Most cases feature the use of stent retrievers and balloon angioplasty with aspiration platforms used to a much lesser degree. While all these methods have been successful in providing complete recanalization and improvement in neurologic symptoms, our use of MAT without any additional devices and adjunct thrombolytic treatment offers a more cost effective and straightforward treatment method. The Penumbra Pivotal Stroke Trial demonstrated safe and effective revascularization for adult AIS secondary to LVO by MAT in patients presenting within 8 hours of symptom onset.<sup>12</sup> Although this trial failed to show improved clinical outcome, recent studies including the MR-CLEAN, Extend IA, and ESCAPE trials have demonstrated better clinical outcomes following endovascular stroke management in adults.<sup>8</sup> These studies indicate endovascular pediatric stroke management as a promising potential treatment for pediatric stroke but systematic trials are needed to establish efficacy and pediatric specific treatment criteria.

The time from symptom onset to treatment is a crucial factor in determining the type of treatment method to use in AIS.<sup>7</sup> Unfortunately the window of time after onset of AIS in which thrombolytic or endovascular therapy is safe in children has not been established. In the absence of better information, adult guidelines are being extrapolated to pediatric stroke. Intravenous therapy with tissue plasminogen activator (tPA) has been anecdotally effective for pediatric AIS but examination of outcomes in the form of clinical trials is necessary to quantify risk for

intracranial hemorrhage and establish safe dosing protocols. Such studies have been stymied by difficulties in enrolling patients with delays in clinical presentation to healthcare facilities and delays in diagnosis by healthcare providers. The Thrombolysis in Pediatric Stroke (TIPS) study, aimed at determining safe dosing protocols and establishing efficacy of tPA administration in pediatric stroke, was discontinued due to the difficulty in identifying and enrolling patients within 4.5 hours of symptom onset,<sup>13</sup> the therapeutic window for tPA administration in adults. The average time to treatment in published reports of pediatric AIS is 14 hours.<sup>14</sup> In such a time frame, most patients do not qualify for intravenous tPA based on the adult guidelines.

In contrast, mechanical thrombectomy may be effective in a more prolonged therapeutic window compared to tPA administration. Dubedout et al. and Maza et al. have demonstrated effectiveness of thrombectomy at 6 and 8 hours from symptom onset respectively.<sup>15,16</sup> Moreover, Taneja et al. achieved complete recanalization and neurological improvement at 24 hours following symptom onset.<sup>17</sup> In our study, the ischemic stroke was confirmed at approximately 5 hours following initial presentation and was outside the recommended time for intravenous tPA administration. This along with the risk of hemorrhage contributed to selecting mechanical thrombectomy over thrombolytic therapy.

The patient described is from a subgroup of pediatric stroke cases with a heart failure etiology. Cerebral arteriopathy, including arterial dissection, is a common cause of pediatric stroke and accounts up to 80% of pediatric stroke in children with no other predisposing conditions.<sup>18</sup> However, the presence of thrombus as the cause of stroke in this case increases the likelihood that the patient suffered from an embolic stroke in the setting of decompensated congenital heart disease. The suspicion of cardioembolic stroke as opposed to arteriopathy indicated thrombectomy via aspiration for the described case.

Grunwald et al., Rhee et al., and Alnaami et al., have also demonstrated mechanical thrombectomy as a treatment for AIS of the anterior circulation in the setting of chronic heart failure.<sup>10-19</sup> With the significantly improved treatment of congenital heart disease, embolic strokes to large vessels in the anterior cerebral circulation are likely to be more frequently encountered at busy pediatric heart centers. As in this case, these patients may benefit from endovascular management of AIS, preventing morbidity and improving survival until a heart transplant is possible. However, the paucity of such cases makes it challenging to evaluate the benefit of endovascular treatment in this patient population.

## CONCLUSION

This case report provides support for mechanical thrombectomy using a lone aspiration platform for effective treatment of embolic stroke precipitated by decompensated heart failure in a pediatric patient. The approach provides a simple and effective alternative to thrombolytic therapy or more complicated thrombectomy devices. Pediatric neurologists and neuro-

interventionists will have to continue working together to validate endovascular treatment in the pediatric population.

ACCEPTED MANUSCRIPT



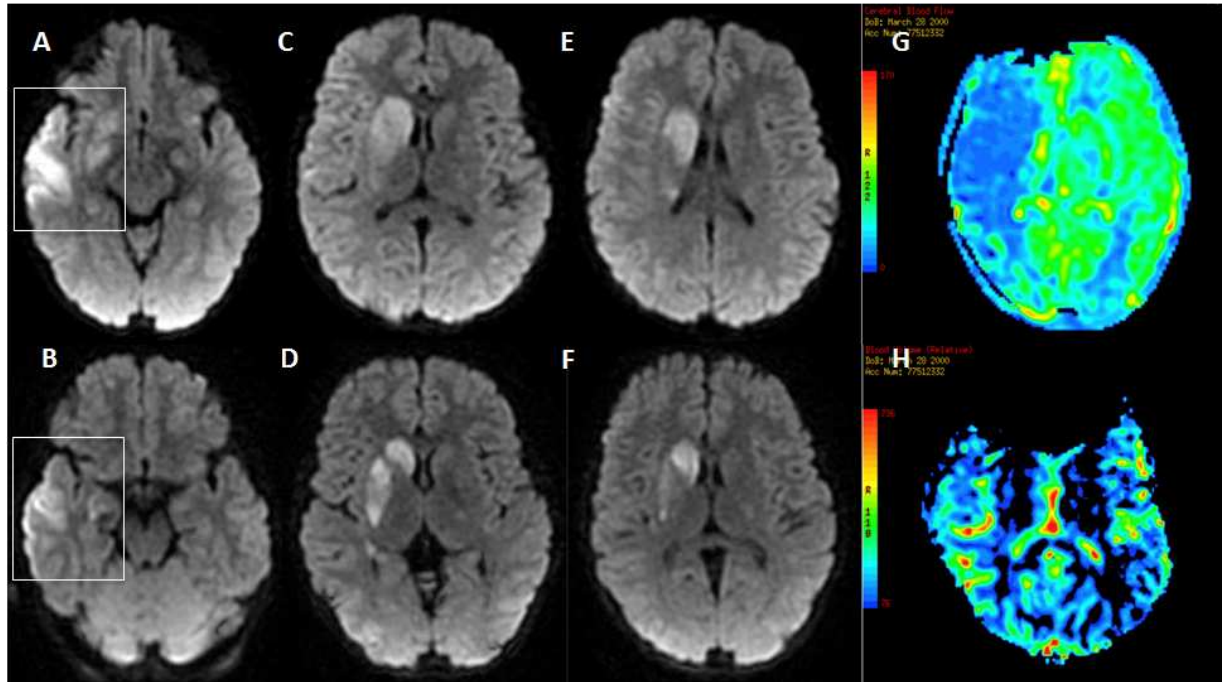
## REFERENCES

1. Fullerton HJ, Wu YW, Zhao S, Johnston SC. Risk of stroke in children: ethnic and gender disparities. *Neurology*. Jul 22 2003;61:189-194.
2. Ganesan V, Hogan A, Shack N, Gordon A, Isaacs E, Kirkham FJ. Outcome after ischaemic stroke in childhood. *Developmental medicine and child neurology*. Jul 2000;42:455-461.
3. Lynch JK, Hirtz DG, DeVeber G, Nelson KB. Report of the National Institute of Neurological Disorders and Stroke workshop on perinatal and childhood stroke. *Pediatrics*. Jan 2002;109(1):116-123.
4. deVeber GA, MacGregor D, Curtis R, Mayank S. Neurologic outcome in survivors of childhood arterial ischemic stroke and sinovenous thrombosis. *Journal of child neurology*. May 2000;15:316-324.
5. Fullerton HJ, Elkind MS, Barkovich AJ, et al. The vascular effects of infection in Pediatric Stroke (VIPS) Study. *Journal of child neurology*. Sep 2011;26(9):1101-1110.
6. Roach ES, Golomb MR, Adams R, et al. Management of stroke in infants and children: a scientific statement from a Special Writing Group of the American Heart Association Stroke Council and the Council on Cardiovascular Disease in the Young. *Stroke; a journal of cerebral circulation*. Sep 2008;39(9):2644-2691.
7. Guyatt GH, Norris SL, Schulman S, et al. Methodology for the Development of Antithrombotic Therapy and Prevention of Thrombosis Guidelines: Antithrombotic Therapy and Prevention of Thrombosis, 9th ed: American College of Chest Physicians Evidence-Based Clinical Practice Guidelines. *Chest*. 01/2308/31/accepted 2012;141(2 Suppl):53S-70S.
8. Chen CJ, Ding D, Starke RM, et al. Endovascular vs medical management of acute ischemic stroke. *Neurology*. Nov 4 2015.
9. Ellis MJ, Amlie-Lefond C, Orbach DB. Endovascular therapy in children with acute ischemic stroke: review and recommendations. *Neurology*. Sep 25 2012;79(13 Suppl 1):S158-164.
10. Grunwald IQ, Walter S, Shamdeen MG, et al. New mechanical recanalization devices - the future in pediatric stroke treatment? *The Journal of invasive cardiology*. Feb 2010;22:63-66.
11. Fujimoto M, Tateshima S, Ali L, Raychev R, Vinuela F. Direct thrombus aspiration using the Penumbra system for the treatment of pediatric intracranial dissection. *Journal of neurointerventional surgery*. Nov 2012;5(6):e43.
12. The penumbra pivotal stroke trial: safety and effectiveness of a new generation of mechanical devices for clot removal in intracranial large vessel occlusive disease. *Stroke; a journal of cerebral circulation*. Aug 2009;40:2761-2768.
13. Rivkin MJ, deVeber G, Ichord RN, et al. Thrombolysis in pediatric stroke study. *Stroke; a journal of cerebral circulation*. Mar 2015;46:880-885.
14. Rafay MF, Pontigon AM, Chiang J, et al. Delay to diagnosis in acute pediatric arterial ischemic stroke. *Stroke; a journal of cerebral circulation*. Jan 2008;40(1):58-64.
15. Dubedout S, Cognard C, Cances C, Albucher JF, Cheuret E. Successful clinical treatment of child stroke using mechanical embolectomy. *Pediatric neurology*. Nov 2013;49:379-382.

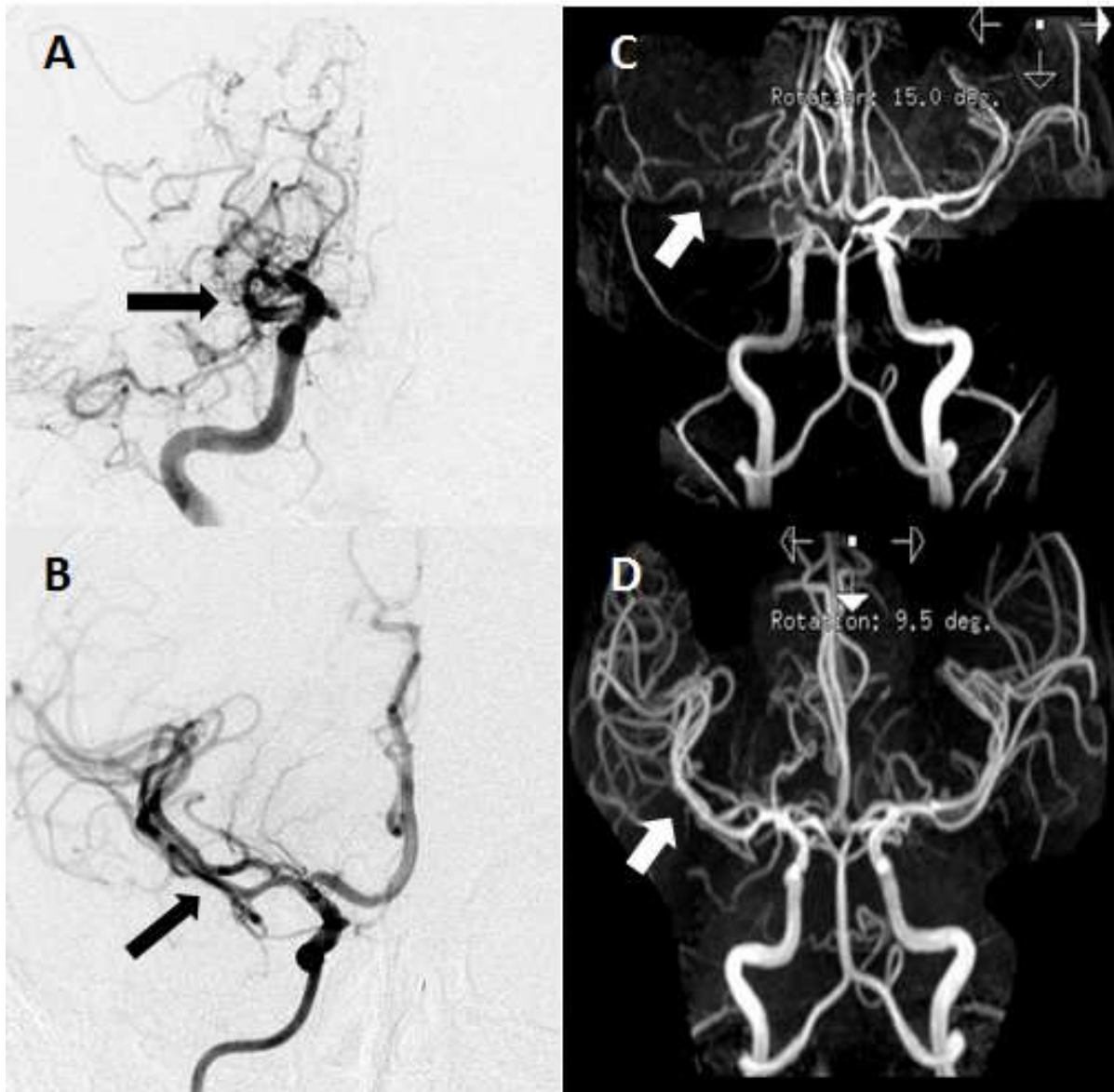
16. Sainz de la Maza S, De Felipe A, Matute MC, et al. Acute ischemic stroke in a 12-year-old successfully treated with mechanical thrombectomy. *Journal of child neurology*. Feb 2013;29:269-273.
17. Taneja SR, Hanna I, Holdgate A, Wenderoth J, Cordato DJ. Basilar artery occlusion in a 14-year old female successfully treated with acute intravascular intervention: case report and review of the literature. *Journal of paediatrics and child health*. Jul 2011;47:408-414.
18. Beslow LA, Jordan LC. Pediatric Stroke: The Importance of Cerebral Arteriopathy and Vascular Malformations. *Childs Nerv Syst*. Oct 2010;26(10):1263-1273.
19. Alnaami I, Buchholz H, Ashforth R, et al. Successful use of Solitaire FR for stroke in a pediatric ventricular assist device patient. *The Annals of thoracic surgery*. Sep 2013;96:e65-67.

ACCEPTED MANUSCRIPT

## FIGURE LEGENDS



**Figure 1.** A,C,E) Magnetic resonance imaging (MRI) with diffusion weighted imaging (DWI) confirms acute ischemic infarction in the right MCA territory (restriction marked by rectangle) pretreatment. B,D,F) MRI DWI sequences 8 hours post treatment. G) Magnetic resonance perfusion imaging (MRP) indicates markedly reduced blood flow in the right hemisphere prior to thrombectomy. H) Pre-thrombectomy MRP indicating corresponding cerebral blood volume.



**Figure 2.** A) Catheter angiography showing obstruction of the right ICA terminus (postero-anterior view). B) Post-treatment follow up of catheter angiography illustrates recanalization of right MCA after thrombectomy (postero-anterior view). C) Coronal view of magnetic resonance angiogram showing occluded right MCA (arrow). D) Follow up 8 hours later showing restoration of blood flow.

Author Name/Year	NIHSS	Patient Age	Patient Sex	Location	Treatment Device	Clinical Outcome
Current Report		9	15 M	Right ICA terminus	Penumbra	Restoration of flow with resolution of left sided neurological deficits; NIHSS of 1
Vega et al. (2015)		16	11 M	Proximal M1 Segment of right MCA	Trevo Stent and Penumbra System	Complete recanalization of the M1 segment with 90-95% of all distal branches; Significant improvement in left lower extremity and modest improvement in left facial droop, NIHSS of 7
Huded V, et al. (2015)		15	6 M	Bilateral Vertebral	Solitaire Stent Retriever	Complete recanalization of the basilar with faint flow in the posterior cerebral artery; NIHSS of 0
Savastano L, et al. (2015)			22 months F	Basilar Artery	Solitaire Stent Retriever	Successful recanalization with TIC1 3 flow in basilar artery; neurologically intact
Stidd DA, et al. (2014)			2 M	Right MCA and ACA	Trevo Stent	Partial reperfusion of MCA and complete reperfusion of ACA; improvement in left hemiplegia with mild motor deficit in left hand and slight facial droop
Rhee et al. (2014)	6,10		9 M	Proximal and Distal left MCA	Solitaire Stent Retriever	Patient had two strokes 1 month apart and both were treated endovascularly; mild residual right sided weakness with NIHSS of 3
Ladner et al. (2014)		22	5 M	Basilar Artery	Solitaire Stent Retriever	Successful recanalization with persistent thrombus in the left P2 segment, NIHSS of 0
Maza et al. (2014)		18	12 F	Right ICA	Solitaire Stent Retriever	Successful recanalization with NIHSS of 1
Bodey et al. (2014)		27	10 M	Basilar Artery	Revive Solitaire Stent Retriever	Complete removal of the clot with impaired cognition and left hemiparesis at 6 months
Bodey et al. (2014)		29	5 M	Basilar Artery	Solitaire Stent Retriever	Complete restoration of flow with some ataxia at 6 months
Bodey et al. (2014)		28	6 M	Basilar Artery	Solitaire Stent Retriever	Residual small clot in the distal left posterior cerebral artery and left proximal superior cerebellar artery with good flow reestablished in basilar and posterior circulation; no motor deficits or speech problems at 6 months
Bodey et al. (2014)			15 M	Left MCA	Solitaire Stent Retriever	Normal mobility with mild weakness of right upper limb with impairment of fine motor tasks at 6 months
Alnami et al. (2013)			8 M	M1 Segment of right MCA	Solitaire Stent Retriever	Complete recanalization of M1 MCA segment with small amount of residual thrombus within one or two distal M2 branches; patient regained normal speech and motor strength with mild degree of left hemiparesis
Dubedout et al. (2013)		20	7 M	Basilar Artery	Capture System	Complete recanalization of Basilar artery with NIHSS of 0 at discharge
Hu et al. (2013)		17	7 M	Right ICA	Solitaire Stent and Penumbra	NIHSS of 2 at 90 days
Hu et al. (2013)		16	9 F	Left ICA	Solitaire Stent and Penumbra	NIHSS of 6 at 90 days
Xavier et al. (2012)		11	16 M	Right ICA	Penumbra and Wingspan	NIHSS of 1 at 90 days
Fink et al. (2012)		6	11 M	Basilar Artery	Solitaire Stent	Successful recanalization of flow in basilar artery with slight dysarthria at 3 month follow-up
Tatum et al. (2012)		17		Right ICA and Basilar Artery	Basilar artery; Merci and Penumbra for Right ICA	Successful recanalization, NIHSS of 16
Tatum et al. (2012)		12		Right M1 segment	Merci and Penumbra	Successful recanalization, NIHSS of 3
Tatum et al. (2012)		2		Basilar Artery	Merci	Successful recanalization, NIHSS of 0
Tatum et al. (2012)		5		Basilar Artery	Merci	Successful recanalization, NIHSS of 3
Taneja et al. (2011)			14 F	Basilar Artery	Solitaire Stent Retriever	Complete recanalization with no lasting neurological deficits
Felker et al. (2010)			14 M	Left M1 Segment	Merci	Merci device broke resulting in M1 occlusion; aphasia and hemiplegic gait
Grunwald et al. (2010)		36	16 F	Basilar Artery	Penumbra	Successful recanalization, NIHSS of 23
Grunwald et al. (2010)		26	7 M	Left ICA	Penumbra	Successful recanalization, NIHSS of 0
Grunwald et al. (2010)		26	16 F	Left M1 Segment	Phenox device	Partial recanalization, NIHSS of 0
Tsivgoulis et al. (2008)		17	6 M	Right ICA	Merci	Unable to remove embolus; embolus pushed into the proximal A1 segment to save the MCA; total recanalization of the MCA with occlusion of the right A1 ACA; NIHSS score of 2 with lasting facial droop and mild sensory deficit

**Table 1.** Review of pediatric stroke cases treated with mechanical thrombectomy.