

# Accepted Manuscript

5-Aminolevulinic acid accumulation in a cerebral infarction mimicking high-grade glioma, a case report

Felix Behling, M.D, Florian Hennersdorf, M.D., Ph.D, Antje Bornemann, M.D., Ph.D,  
Marcos Tatagiba, Ph.D, Marco Skardelly, M.D., Ph.D

PII: S1878-8750(16)30271-6

DOI: [10.1016/j.wneu.2016.05.009](https://doi.org/10.1016/j.wneu.2016.05.009)

Reference: WNEU 4070

To appear in: *World Neurosurgery*


Received Date: 24 March 2016

Revised Date: 3 May 2016

Accepted Date: 4 May 2016

Please cite this article as: Behling F, Hennersdorf F, Bornemann A, Tatagiba M, Skardelly M, 5-Aminolevulinic acid accumulation in a cerebral infarction mimicking high-grade glioma, a case report, *World Neurosurgery* (2016), doi: 10.1016/j.wneu.2016.05.009.

This is a PDF file of an unedited manuscript that has been accepted for publication. As a service to our customers we are providing this early version of the manuscript. The manuscript will undergo copyediting, typesetting, and review of the resulting proof before it is published in its final form. Please note that during the production process errors may be discovered which could affect the content, and all legal disclaimers that apply to the journal pertain.





1 Key Words: 5-ALA, Cerebral infarction, Fluorescence-guided surgery

2

3 Abbreviations: 5-ALA (5-Aminolevulinic acid), ACE (Angiotensin converting enzyme), CNS

4 (Central nervous system), MIB-1 (Mindbomb E3 ubiquitin protein ligase 1), MRI (Magnetic

5 resonance imaging)

6

7

8

9

10

11

12

13

14

15

16

17

18

19

20

21

22

23

24

1 **Abstract:**

2

3 **Background:**

4 5-Aminolevulinic acid (5-ALA) has become an integral part in the neurosurgical treatment of  
5 malignant glioma. Over time, several other tumour entities have been identified to metabolize 5-  
6 ALA and show a similar fluorescence pattern during surgical resection. This case report is the  
7 first description of 5-ALA accumulation in post-ischaemic cerebral tissue. This evidence  
8 questions the assumption that 5-ALA accumulation in glioma is exclusively attributed to tumour  
9 infiltration. Instead, 5-ALA accumulation may also occur beyond the tumour borders and may be  
10 partially ascribed to inflammatory changes in the surrounding brain tissue.

11 **Case Description:**

12 A 64-year old female patient presented with episodes of apraxia and a ring-enhancing lesion in  
13 post-contrast T1-weighted MRI-sequences suggestive of high grade glioma. During 5-ALA-  
14 guided resection strong fluorescence was observed. However, while the frozen section was  
15 inconclusive, the final histopathological examination revealed a stage II cerebral infarction.

16 **Conclusions:**

17 5-ALA accumulation in post-ischemic cerebral tissue should be considered for intended  
18 supramarginal resections near eloquent brain regions. Therefore, sufficient preoperative imaging  
19 should regularly include MRI-spectroscopy and perfusion sequences to ascertain the proper  
20 diagnosis. Moreover, further research is warranted to determine the role of 5-ALA accumulation  
21 in post-ischaemic and inflammatory brain tissue.

22

23

24

## 1 **Background and Importance:**

2 Fluorescence microscopy of 5-aminolevulinic acid (5-ALA) is an established technique in  
3 glioblastoma surgery. It enables supramarginal resection of tumour infiltration beyond  
4 radiographic contrast enhancement, resulting in prolonged progression-free and overall survival.<sup>1-</sup>  
5 <sup>4</sup> With the increasing use of 5-ALA in neurosurgical practice, several non-glial tumour entities  
6 have also been described to accumulate fluorescent porphyrin. In particular, intracranial  
7 meningiomas have been reported to repeatedly show fluorescence during surgical resection.<sup>5,6</sup>  
8 Millesi et al. analysed 5-ALA in the resection of 55 spinal neoplasms, which revealed  
9 intraoperative fluorescence in meningiomas, ependymomas and hemangiopericytomas as well as  
10 drop metastases of primary CNS tumours.<sup>7</sup> Recently, the accumulation of 5-ALA in a primary  
11 cerebral lymphoma has been reported.<sup>8</sup> Intraoperative fluorescence of the surrounding tissue of  
12 radiation necrosis has also been shown in two cases.<sup>9</sup> However, fluorescent activity in cerebral  
13 tissue after a cerebrovascular ischaemic event has not yet been described.

## 15 **Clinical Presentation:**

### 16 **Patient History:**

17 We report the case of a 64-year old female who presented with headaches and hearing  
18 impairment for approximately two months. She also suffered from one attack of vertigo and  
19 multiple episodes of apraxia in which she was suddenly unable to operate a stove, a task that she  
20 was otherwise quite familiar with performing. These symptoms lasted for a few days and  
21 regressed spontaneously. In the previous year, she experienced a similar event that lasted only a  
22 few minutes. At this first event, no medical service was consulted. She did not experience any  
23 sensory or motor deficits. The patient had a past medical history of arterial hypertension, which  
24 was treated with an ACE inhibitor and surgically decompressed lumbar spinal canal stenosis four

1 years prior with residual pain that was managed with metamizole on demand. She led an active  
2 life and had a brief smoking history, from which she accumulated several pack-years. On the  
3 basis of her age, previous smoking habit and hypertension, she was on low-dose aspirin at 75 mg  
4 daily. She did not recall experiencing any other neurological deficits or other abnormalities  
5 indicating cerebral ischaemia.

6 After she had recovered from the latest episode of apraxia, a cranial MRI scan was performed,  
7 which revealed a ring-enhancing lesion of approximately 2.2 cm × 2.3 cm located in the left  
8 precuneus with suspicious small bleeds and local surrounding oedema. Diffusion imaging  
9 demonstrated no clear signs of ischaemia (see Figure 1 A-F).

10

#### 11 Intervention and post-operative course

12 With the suspicion of a high-grade glioma, we indicated fluorescence-guided surgical resection of  
13 the ring-enhancing mass. The patient underwent a navigated left-sided parietal craniotomy and a  
14 fluorescence-guided supramarginal resection of the lesion with preservation of sensory-evoked  
15 and motor-evoked potentials under continuous intraoperative electrophysiological monitoring.  
16 The suspicious tissue showed typical characteristics of a high-grade glioma and partially strong  
17 fluorescence, in some areas exceeding the boarder of the tissue abnormalities seen under white-  
18 light. The intraoperative frozen section was inconclusive. Due to the suspicious intraoperative  
19 aspects and the non-eloquent location of the lesion the decision was made to complete the  
20 resection. We did not take intraoperative images neither of the white-light characteristics nor of  
21 the fluorescence since the unusualness of the case was revealed later with the final  
22 histopathological diagnosis.

23

1 The patient recovered quickly, did not show any obvious post-operative neurological deficits and  
2 was discharged after a few days. She reported back to our outpatient clinic six months later. The  
3 MRI scan did not show any signs of tumour recurrence or new demarcated ischaemic areas (see  
4 Figure 1 G-H). However, the patient complained of behavioural changes, fatigue, lethargy and  
5 vertigo. She also described a pressure sensation in both ears with declining hearing ability. A  
6 duplex sonography of the carotid arteries and an echocardiogram were both within normal limits.  
7 Other than the reported risk factors, a clear underlying cause of the ischemic infarction could not  
8 be identified.

9

#### 10 Neuropathology

11 The intraoperative frozen section was inconclusive. It showed necrosis with accompanying  
12 astrocytosis and pigment-laden macrophages (Figure 2 A). No viable tumour tissue could be  
13 identified. The definite histopathological diagnosis revealed stage II of a cerebral infarction with  
14 reactive, altered brain tissue with scattered reactive astrocytes and numerous macrophages on a  
15 necrotic background (Figure 2 B). It also showed the presence of single inflammatory infiltrating  
16 leucocytes and vessel conglomeration; however, no relevant mitotic activity (MIB-1 proliferation  
17 index < 1%) was observed.

18

#### 19 Discussion:

20 Even though the clinical presentation was unspecific, the preoperative MRI scan was highly  
21 suggestive of a high-grade glioma and there was no clear indication for an ischemic event.  
22 However, we did not conduct a spectroscopy or perfusion MRI, which would have been helpful  
23 in assessing the pathology of the lesion correctly. As the frozen section was inconclusive and

1 strong fluorescence and typical white-light characteristics were observed, a complete resection  
2 was performed.

3 This case report presents the first description of 5-ALA fluorescence in a cerebral infarction.

4 The reason for the unexpected accumulation of 5-ALA and consecutive clear intraoperative  
5 fluorescence cannot be explained substantively. To date, an accumulation of 5-ALA after  
6 cerebral infarction has not yet been described. Non-specific 5-ALA accumulation has been  
7 attributed to leakage into peritumoural oedema and reactive astrocytic infiltration.<sup>10,11,12</sup> It is  
8 possible that inflammatory reactions, which are regularly observed after an infarction,<sup>13</sup> result in  
9 the increased accumulation of 5-ALA. This mechanism has also been hypothesized in two cases  
10 of radiation necrosis and one case of neurodegenerative demyelinating disease<sup>9</sup> and could  
11 potentially underlie the observed fluorescence in this case of cerebral infarction. Recently Lau et  
12 al. analysed the correlation of tumour cellularity with intraoperative fluorescence after 5-ALA  
13 administration in high-grade gliomas. Biopsies that were tumour free histologically showed  
14 fluorescence in approximately one third of the cases. Reactive changes of the surrounding  
15 cerebral tissue were discussed as possible reason for this false-positive fluorescence.<sup>14</sup> Masubuchi  
16 et al. recently showed fluorescence of normal brain tissue after systemic administration of 5-ALA  
17 in rats with disrupted blood brain barriers<sup>15</sup>. However, it is still unclear whether 5-ALA is  
18 accumulating in reactive astrocytes, microglia or other non-tumourous cells. This case raises the  
19 question of whether fluorescing brain tissue that is marked by 5-ALA exclusively reflects tumour  
20 infiltration during the resection of high-grade glioma. This is of particular clinical interest  
21 because, despite the great advantages of 5-ALA-guided resection in terms of radicality,  
22 supramarginal resection also harbours the danger of creating new neurological deficits. Because  
23 high-grade gliomas are associated with necrosis<sup>16</sup> and perifocal immune reactions<sup>17</sup>, one may  
24 speculate that adjacent 5-ALA accumulation can also occur due to surrounding inflammatory



1 processes. Thus, further basic research is necessary to obtain deeper insight into the physiological  
2 mechanism of 5-ALA in ischaemic cerebral tissue and other non-tumourous lesions.

#### 3 4 **Conclusions:**

5 This reported case underlines the importance of being aware of the differential diagnoses of  
6 malignant glioma. Nowadays, MRI perfusion and spectroscopy should be part of the diagnostic  
7 work-up in brain tumour imaging. Moreover, this case calls into question of whether 5-ALA  
8 accumulation in high-grade glioma is exclusively due to tumour infiltration, and if it can also be  
9 partially due to adjacent inflammation. Thus, further investigation of the role of 5-ALA  
10 accumulation in post-ischaemic and inflammatory brain tissue is warranted.

#### 11 12 **Conflicts of interest:**

13 None.

#### 14 **References:**

- 15 1. Aldave G, Tejada S, Pay E, Marigil M, Bejarano B, Idoate MA et al. Prognostic value of  
16 residual fluorescent tissue in glioblastoma patients after gross total resection in 5-  
17 aminolevulinic Acid-guided surgery. *Neurosurgery*. 2013;72(6):915-20.
- 18 2. Stummer W, Reulen H-J, Meinel T, Pichlmeier U, Schumacher W, Tonn J-C, et al. Extent  
19 of resection and survival in glioblastoma multiforme: identification of and adjustment for  
20 bias. *Neurosurgery*. 2008;62(3):564–76–discussion564–76.
- 21 3. Stummer W, Pichlmeier U, Meinel T, Wiestler OD, Zanella F, Reulen H-J, et al.

- 1 Fluorescence-guided surgery with 5-aminolevulinic acid for resection of malignant glioma:  
2 a randomised controlled multicentre phase III trial. *Lancet Oncol.* 2006;7(5):392–401.
- 3 4. Zhao S, Wu J, Wang C, Liu H, Dong X, Shi C, et al. Intraoperative fluorescence-guided  
4 resection of high-grade malignant gliomas using 5-aminolevulinic acid-induced  
5 porphyrins: a systematic review and meta-analysis of prospective studies. *PLoS ONE.*  
6 2013;8(5):e63682.
- 7 5. Coluccia D, Fandino J, Fujioka M, Cordovi S, Muroi C, Landolt H. Intraoperative 5-  
8 aminolevulinic-acid-induced fluorescence in meningiomas. *Acta Neurochir.*  
9 2010;152(10):1711–9.
- 10 6. Kajimoto Y, Kuroiwa T, Miyatake S-I, Ichioka T, Miyashita M, Tanaka H, et al. Use of 5-  
11 aminolevulinic acid in fluorescence-guided resection of meningioma with high risk of  
12 recurrence. *Case report. J Neurosurg.* 2007;106(6):1070–4.
- 13 7. Millesi M, Kiesel B, Woehrer A, Hainfellner JA, Novak K, Martínez-Moreno M, et al.  
14 Analysis of 5-aminolevulinic acid-induced fluorescence in 55 different spinal tumors.  
15 *Neurosurg Focus.* 2014;36(2):E11.
- 16 8. Grossman R, Nossek E, Shimony N, Raz M, Ram Z. Intraoperative 5-aminolevulinic acid-  
17 induced fluorescence in primary central nervous system lymphoma. *J Neurosurg.*  
18 2014;120(1):67–9.
- 19 9. Miyatake S-I, Kuroiwa T, Kajimoto Y, Miyashita M, Tanaka H, Tsuji M. Fluorescence of  
20 non-neoplastic, magnetic resonance imaging-enhancing tissue by 5-aminolevulinic acid:  
21 case report. *Neurosurgery.* 2007;61(5):E1101–3–discussionE1103–4.

- 1 10. Stummer W, Stocker S, Novotny A, Heimann A, Sauer O, Kempf O, et al. In vitro and  
2 in vivo porphyrin accumulation by C6 glioma cells after exposure to 5-aminolevulinic  
3 acid. *J Photochem Photobiol B, Biol.* 1998;Sep;45(2-3):160–9
- 4 11. Utsuki S, Oka H, Sato S, Shimizu S, Suzuki S, Tanizaki Y, et al. Histological examination  
5 of false positive tissue resection using 5-aminolevulinic acid-induced fluorescence  
6 guidance. *Neurol Med Chir (Tokyo).* 2007;May;47(5):210–3–discussion213–4.
- 7 12. Nabavi A, Thurm H, Zountsas B, Pietsch T, Lanfermann H, Pichlmeier U, et al. Five-  
8 aminolevulinic acid for fluorescence-guided resection of recurrent malignant gliomas: a  
9 phase ii study. *Neurosurgery.* 2009;Dec;65(6):1070–6–discussion1076–7.
- 10 13. Amantea D, Nappi G, Bernardi G, Bagetta G, Corasaniti MT. Post-ischemic brain damage:  
11 pathophysiology and role of inflammatory mediators. *FEBS J.* 2009;276(1):13-26.
- 12 14. Lau D, Hervey-Jumper SL, Chang S, Molinaro AM, McDermott MW, Phillips JJ, et al. A  
13 prospective Phase II clinical trial of 5-aminolevulinic acid to assess the correlation of  
14 intraoperative fluorescence intensity and degree of histologic cellularity during resection  
15 of high-grade gliomas. *J Neurosurg. American Association of Neurological Surgeons.*  
16 2015;Nov 6;:1–10.
- 17 15. Masubuchi T, Kajimoto Y, Kawabata S, Nonoguchi N, Fujishiro T, Miyatake S-I, et al.  
18 Experimental study to understand nonspecific protoporphyrin IX fluorescence in brain  
19 tissues near tumors after 5-aminolevulinic acid administration. *Photomed Laser Surg.*  
20 2013;31(9):428–33.
- 21 16. Louis DN, Ohgaki H, Wiestler OD, Cavenee WK, Burger PC, Jouvett A et al. The 2007

1 WHO classification of tumours of the central nervous system. *Acta Neuropathol.*  
2 2007;114(2):97-109.

- 3 17. Sowers JL, Johnson KM, Conrad C, Patterson JT, Sowers LC. The role of inflammation in  
4 brain cancer. *Adv Exp Med Biol.* 2014;816:75-105.

5  
6  
7  
8 Figure Legends:

9  
10 Figure1: 5-ALA infarction mimicking high grade glioma:

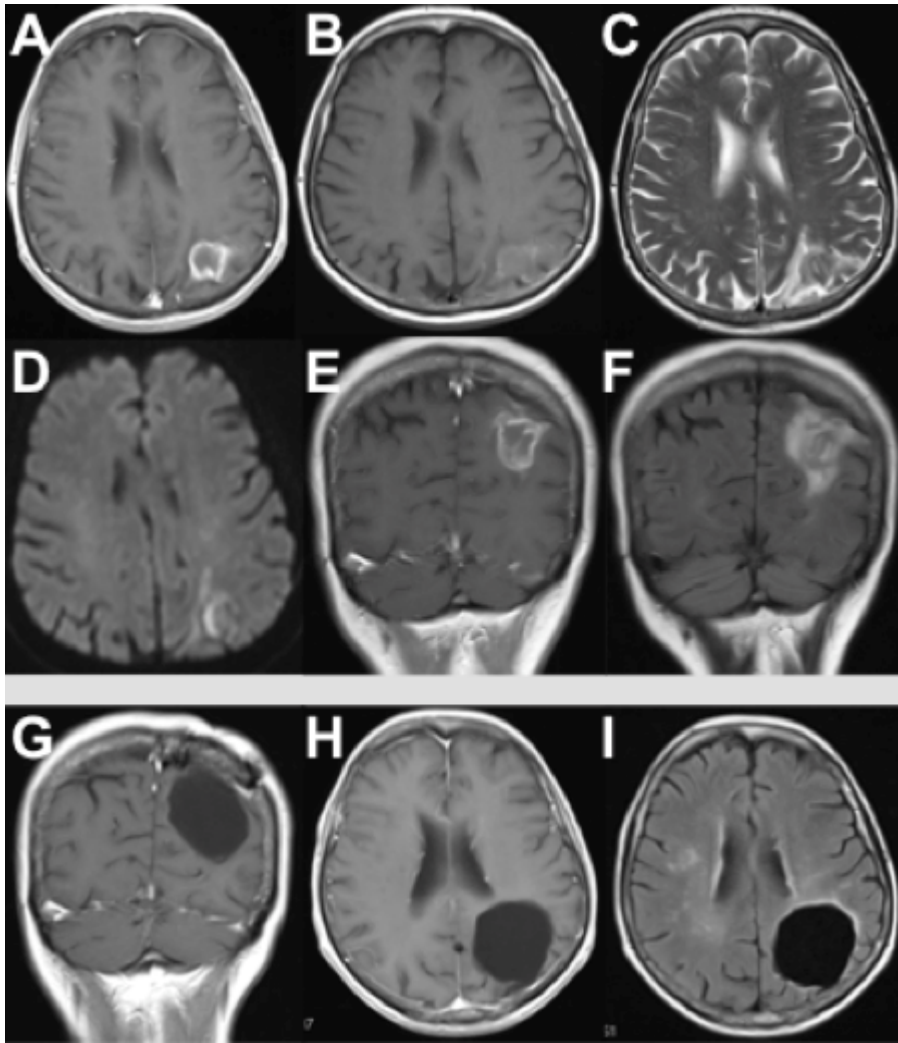
11 Preoperative and 6-month post-operative MRI: Preoperative postcontrast T1-weighted images (A  
12 and E) showed a ring-enhancing lesion of the left precuneus with perifocal oedema on  
13 preoperative T2-weighted (C) and FLAIR sequences (F). Preoperative T1-weighted images (B)  
14 demonstrated small bleeds, and diffusion images did not show clear signs of ischaemia (D). Post-  
15 operative images after 6 months were unremarkable (G and H: coronal and axial postcontrast  
16 MRI, respectively; I: axial FLAIR sequence).

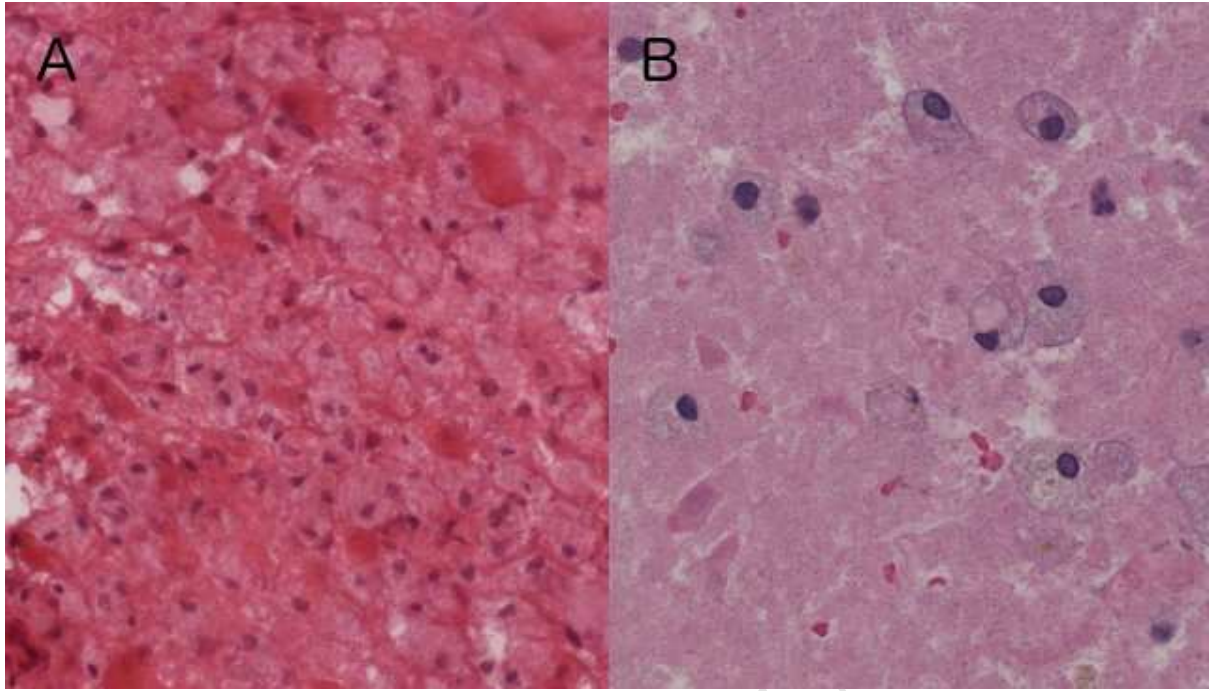
17  
18 Figure2: Hematoxylin-Eosin stain:

19 The frozen section (A) shows scattered reactive astrocytes in a background of macrophages. The  
20 final histopathological evaluation (B) reveals necrotic brain tissue infiltrated by macrophages  
21 typical for a stage II cerebral infarction. There is no sign of tumour tissue.

22

23





ACCEPTED MANUSCRIPT

**Research highlights:**

- This case report presents a 64-year old female patient who suffered episodes of apraxia and showed a cerebral lesion suggestive of a high-grade glioma, which was surgically resected using 5-ALA and turned out to be a cerebral infarction.
- This is the first description of 5-aminolevulinic acid accumulation in cerebral infarction.
- It emphasizes that intraoperative fluorescence after 5-ALA administration can be misleading since it is not exclusively attributed to tumor infiltration but may also be caused by inflammation.