

Accepted Manuscript

Globus pallidus internus deep brain stimulation for traumatic hemidystonia following penetrating head injury

Churl-Su Kwon, MBBS MPH, Harutomo Hasegawa, FRCS, Giannis Sokratous, MBBS, Jean-Marie U-King-Im, FRCR, Michael Samuel, FRCP, Keyoumars Ashkan, FRCS

PII: S1878-8750(16)30276-5

DOI: [10.1016/j.wneu.2016.05.014](https://doi.org/10.1016/j.wneu.2016.05.014)

Reference: WNEU 4075

To appear in: *World Neurosurgery*

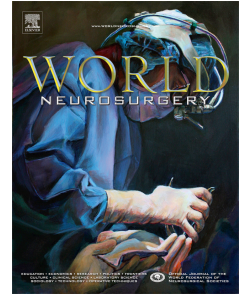
Received Date: 18 January 2016

Revised Date: 6 May 2016

Accepted Date: 7 May 2016

Please cite this article as: Kwon C-S, Hasegawa H, Sokratous G, U-King-Im J-M, Samuel M, Ashkan K, Globus pallidus internus deep brain stimulation for traumatic hemidystonia following penetrating head injury, *World Neurosurgery* (2016), doi: 10.1016/j.wneu.2016.05.014.

This is a PDF file of an unedited manuscript that has been accepted for publication. As a service to our customers we are providing this early version of the manuscript. The manuscript will undergo copyediting, typesetting, and review of the resulting proof before it is published in its final form. Please note that during the production process errors may be discovered which could affect the content, and all legal disclaimers that apply to the journal pertain.



Globus pallidus internus deep brain stimulation for traumatic hemidystonia following penetrating head injury

Churl-Su Kwon MBBS MPH¹, Harutomo Hasegawa FRCS¹, Giannis Sokratous MBBS¹, Jean-Marie U-King-Im FRCR², Michael Samuel FRCP³, Keyoumars Ashkan FRCS¹

Department of Neurosurgery, King's College Hospital, London, UK1

Department of Neuroradiology, King's College Hospital, London, UK2

Department of Neurology, King's College Hospital, London, UK3

Correspondence to:

Churl-Su Kwon

King's College Hospital

Denmark Hill

SE5 9RS

Phone: 02032993285

Fax: 02032993280

Email: churlsu.kwon@gmail.com

Keywords: secondary hemidystonia, penetrating head injury, globus pallidus internus, deep brain stimulation

ABSTRACT**Background**

DBS has been a major advance in the treatment of dystonias. Outcomes are, however, less predictable for secondary dystonias, predominantly due to progression of disease or specific brain lesions. There are very few cases reported of GPi-DBS for post-traumatic dystonia. We describe the successful use of unilateral GPi-DBS in a patient with hemidystonia following penetrating head injury. To our knowledge, this is the first description of the use of DBS following penetrating head injury.

Case Description

We present the case of a 47 year-old man with phasic hemidystonia. At the age of 3 years he suffered a penetrating head injury from a welding needle. The patient developed dystonic and phasic right-sided movements. Pre-operative BFM score was 26. MRI showed a linear encephalomalacic track extending from the cortex in the left parieto-occipital region, traversing just superolateral to the left trigone into the left thalamus and ending in the region of left cerebral peduncle and subthalamic nucleus. There was no left GPi lesion. A left GPi-DBS electrode was inserted. At six months follow-up, the patient's arm was more relaxed and his spasms lessened in their severity and frequency. Although BFM score 21 had improved modestly by 20%, pain and comfort levels had significantly improved with 50% improvement in VAS score, translating in better quality of life. There were no complications. The clinical benefit persists at 5 years post-surgery.

Conclusion

Selected patients with post-traumatic hemidystonia, including following penetrating head injury, represent one group of secondary dystonias who might benefit from DBS surgery.

Keywords

secondary hemidystonia, penetrating head injury, globus pallidus internus, deep brain stimulation

INTRODUCTION

Movement disorders are relatively common following severe head injury and have been reported in 13% to 66% of patients (7). Patient series have shown that head injury accounts for 7% to 9% of cases in symptomatic hemidystonia (11). In the largest collected series to date of 190 cases of hemidystonia, the most common aetiologies were stroke, trauma and perinatal injury (3). Basal ganglia lesions were identified in up to 60% of cases, most commonly involving the putamen. Patients experienced benefit from medical therapy in only 26% to 35% of cases. It concluded that hemidystonia responded poorly to medical treatment, though some patients may benefit from benzodiazepines or anticholinergic drugs. A meta-analysis of patients who underwent GPi-DBS for dystonia showed significant improvement in Burke-Fahn-Marsden (BFM) scores in a variety of dystonic conditions (5). Clinically significant improvements in outcomes were seen for most aetiologies with the notable exception of encephalitis.

The effectiveness of DBS for post-traumatic secondary dystonia remains to be established. However, single case-reports have demonstrated amelioration of dystonic movements, posture and pain with DBS for non-penetrating (closed/blunt) post-traumatic hemidystonia (Table 1). In this study, we report a unique case of a patient presenting with right-sided hemidystonia post penetrating head injury, with grossly improved clinical benefit following unilateral left sided GPi DBS. Literature regarding posttraumatic hemidystonia treated with DBS is also discussed.

CASE DESCRIPTION

We present the case of a 47 year-old man with phasic hemidystonia. At the age of 3 years he suffered a penetrating head injury from a welding needle, which had entered the right medial canthus and traversed the right frontal lobe across to the left parietal lobe. Following surgical removal the patient developed meningitis and subsequently right sided weakness and minor dysphasia.

The deficits were progressively improving and in transition to adulthood the patient developed dystonic and phasic right-sided movements in lieu of the hemiparesis. These abnormal movements, which could be painful, embarrassing and disturbed his balance, greatly limited his ability to perform his day-to-day activities including his job as a supermarket worker. Following a long term of medical management that failed to alleviate his symptoms the patient was referred for consideration of DBS at the age of 47. At that stage, his (pre-operative) BFM score was 26.

MRI of his brain (Figure 1) showed a linear encephalomalacic track (arrows) extending from the cortex in the left parieto-occipital region, traversing just superolateral to the left trigone into the left thalamus and ending in the region of left cerebral peduncle and subthalamic nucleus. Axial gradient echo sequence (C) showing evidence of haemosiderin staining (arrowhead) in the region of the substantia nigra in left cerebral peduncle. There was no left GPi lesion.

Because of poor response to medical therapy, the decision was made in favour of surgery. Following satisfactory completion of a full multidisciplinary review, including neurological, neuropsychological and neuropsychiatric assessments, a left GPi-DBS electrode was inserted. For surgery, a Leksell G stereotactic frame (Elekta Instruments AB) was applied to the

patient's shaved head. Pre-operative stereotactic MRI was performed. A direct targeting technique was employed with single-track impedance recording before inserting to the target a Medtronic Model 3389 quadripolar electrode with 1.5mm contacts spaced 0.5mm apart. Post-operative stereotactic CT was performed. Final electrode position was determined by fusion of preoperative and postoperative images. A rechargeable ACTIVA RC battery (Medtronic) was inserted in the left chest wall pocket and connected to the electrodes under the same anaesthetic. Stimulation settings were case +, contact 2-, pulse width 60 microseconds, frequency 130 Hz, with threshold for clinical improvement at 0.7 volts, and a final setting of 1.3 volts.

At six months following DBS, the patient's arm was more relaxed and his spasms lessened in their severity and frequency. Although the BFM score (21) had improved modestly by 20%, his pain and comfort level had significantly improved, translating in a better quality of life and social function. Visual analog scale (VAS) score improved from 5/10 moderate pain pre-operatively to 0/10 no pain post-operatively. At five years VAS score has remained at 0. There were no complications or side effects. The clinical benefit persists at 5 years post-surgery (Video 1). BFM score post-operatively on yearly follow-up has remained stable at 21.

DISCUSSION

Hemidystonia is the most characteristic presentation of post-traumatic dystonia (8). Since 1928 when it was first reported by Austregesilo and Marques, several patients with post-traumatic hemidystonia have been described. Here, we presented the successful use of unilateral GPi-DBS in a patient with hemidystonia following penetrating head injury.

Post-traumatic dystonia has been correlated with injury to the basal ganglia and thalamus with analogous radiological and patho-anatomic associations to other causes of secondary dystonia (3,7,11). Secondary dystonia has been observed with lesioning of structures including the striato-pallido complex, ventral posterolateral thalamus and mesencephalon (1,9).

The efficacy of GPi-DBS in primary generalised dystonia is established. This is, however, less so in secondary dystonia; more variable results are observed with less impressive outcomes compared to primary dystonias (14). Due to aetiology, anatomic and physiologic heterogeneity, differing clinical signs and prognosis, the secondary dystonia patient group is diverse. Not infrequently other neurological comorbidities such as seizures, cognitive dysfunction and cerebrovascular disease coexist, restricting the patient's potential response to surgery. Occasional dramatic or no improvements can occur (2,14).

There have only been a few reports detailing the effects of DBS in non-penetrating (closed/blunt) posttraumatic secondary hemidystonia (Table 1). Depending on the location, size of lesion, pattern of injury, movement disorder and symptoms of the patient, effects of DBS may vary. In our patient, given the penetrating nature of the injury, the structures involved could clearly be defined. Thus the patient had no GP injury but sustained pathology in the thalamus, STN, cerebral peduncle and the parietal lobe. Unilateral left sided GPi-DBS significantly improved his upper limb dystonia and pain symptoms even though BFMDRS improved modestly by 20%. Although the exact structures injured in this patient are not

clearly seen elsewhere in literature, a patient has been described with lesions in cortical, subcortical, upper brain stem and dentatothalamic nucleus areas who exhibited four years of sustained amelioration of dystonic movement, posture and pain after unilateral right-sided GPi-DBS (10). Most recently, four successful GPi-DBS cases of secondary hemidystonia associated with posttraumatic brain injury with limited GP lesion or small confined lesions within the pallidal circuit have been described (6). Average BFMDRS (movement) improvement was 73.2 % and BFMDRS (disability) improvement was 75% in this group. GPi-DBS has also been seen to only give transient improvement in a patient with post-traumatic hemidystonia; the first 48 hours post operation showed remarkable improvement of functional gain through a suggested 'stun' effect possibly due to the initial oedema that later resolved.

Although the largest body of literature concerns the efficacy of GPi-DBS for dystonia, other targets have also been utilized. Thalamic stimulation has provided improvement in focal dystonia and myoclonus in myoclonus dystonia (4,13). One of the first reports on post-traumatic hemidystonia DBS involved VPL thalamic stimulation in a patient with a thalamic lesion. The patient showed marked improvement in dystonic postures and right upper limb movement (12). More recently STN-DBS has been used to treat dystonia and has been corroborated in a patient with post-traumatic hemidystonia sustaining thalamic injury, showing 90% improvement of BFMDRS with STN-DBS (15).

In our patient the track of the penetrating injury involved both the thalamus and the STN, disrupting the basal ganglia-thalamic pathways and resulting in the hemidystonia. In the absence of normal thalamic or STN targets for DBS, we chose the GPi. Five years following the surgery, the patient continues to experience sustained improvement in his dystonia.

CONCLUSION

DBS has been a major advance in the treatment of dystonias. Outcomes are, however, less predictable for secondary dystonias, predominantly due to the progression of disease or specific brain lesions. Selected patients with post-traumatic hemidystonia, including following penetrating head injury, may represent one group of secondary dystonias who might benefit from DBS surgery.

ACKNOWLEDGEMENTS

None.

DISCLOSURES

Keyoumars Ashkan and Michael Samuel have received educational grants from Medtronic and St Jude.

REFERENCES

1. Bhatia KP, Marsden CD: The behavioural and motor consequences of focal lesions of the basal ganglia in man. *Brain* 117:859-876, 1994
2. Chang JW, Choi JY, Lee BW, Kang UJ, Chung SS: Unilateral globus pallidus internus stimulation improves delayed onset post-traumatic cervical dystonia with an ipsilateral focal basal ganglia lesion. *J Neurol Neurosurg Psychiatry* 73:588-590, 2002
3. Chuang C, Fahn S, Frucht SJ: The natural history and treatment of acquired hemidystonia: report of 33 cases and review of the literature. *J Neurol Neurosurg Psychiatry* 72:59-67, 2002
4. Goto S, Shimazu H, Matsuzaki K, Tamura T, Murase N, Nagahiro S, Kaji R: Thalamic Vo-complex vs pallidal deep brain stimulation for focal hand dystonia. *Neurology* 70:1500-1501, 2008
5. Holloway KL, Baron MS, Brown R, Cifu DX, Carne W, Ramakrishnan V: Deep brain stimulation for dystonia: a meta-analysis. *Neuromodulation* 9:253-261, 2006
6. Kim JP, Chang WS, Chang JW: The long-term surgical outcomes of secondary hemidystonia associated with post-traumatic brain injury. *Acta Neurochir (Wien)* 154:823-830, 2012
7. Krauss JK, Jankovic J: Head injury and posttraumatic movement disorders. *Neurosurgery* 50:927-940, 2002
8. Lee MS, Rinne JO, Ceballos-Baumann A, Thompson PD, Marsden CD: Dystonia after head trauma. *Neurology* 44:1374-1378, 1994
9. Lehericy S, Vidailhet M, Dormont D, Pierot L, Chiras J, Mazetti P, Marsault C, Agid Y: Striatopallidal and thalamic dystonia. A magnetic resonance imaging anatomoclinical study. *Arch Neurol* 53:241-250, 1996
10. Lohr TJ, Hasdemir MG, Burgunder JM, Krauss JK: Long-term follow-up of chronic globus pallidus internus stimulation for posttraumatic hemidystonia. *J Neurosurg* 92:457-460, 2000
11. Pettigrew LC, Jankovic J: Hemidystonia: a report of 22 patients and a review of the literature. *J Neurol Neurosurg Psychiatry* 48:650-657, 1985
12. Sellal F, Hirsch E, Barth P, Blond S, Marescaux C: A case of symptomatic hemidystonia improved by ventroposterolateral thalamic electrostimulation. *Mov Disord* 8:515-518, 1993
13. Trottenberg T, Meissner W, Kabus C, Arnold G, Funk T, Einhaupl KM, Kupsch A: Neurostimulation of the ventral intermediate thalamic nucleus in inherited myoclonus-dystonia syndrome. *Mov Disord* 16:769-771, 2001
14. Yianni J, Bain PG, Gregory RP, Nandi D, Joint C, Scott RB, Stein JF, Aziz TZ: Post-operative progress of dystonia patients following globus pallidus internus deep brain stimulation. *Eur J Neurol* 10:239-247, 2003
15. Zhang JG, Zhang K, Wang ZC, Ge M, Ma Y: Deep brain stimulation in the treatment of secondary dystonia. *Chin Med J (Engl)* 119:2069-2074, 2006

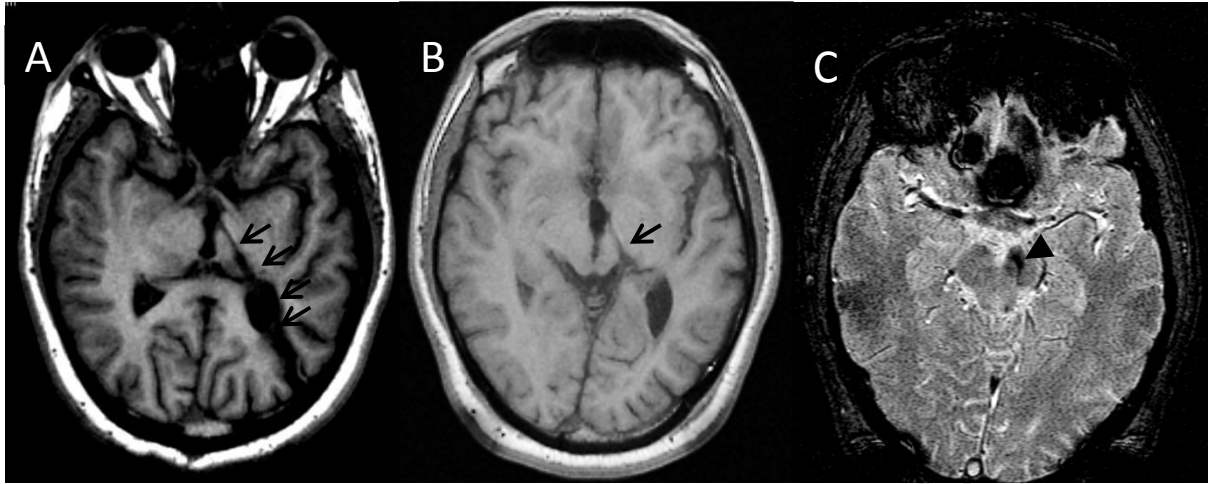


Figure 1: Reformatted axial T1 images (A), axial T1 (B) showing a linear encephalomalacic track (arrows) extending from the cortex in the left parieto-occipital region, traversing just superolateral to the left trigone into the left thalamus and ending in the region of left cerebral peduncle and subthalamic nucleus. Axial gradient echo sequence (C) showing evidence of haemosiderin staining (arrowhead) in the region of the substantia nigra in left cerebral peduncle.

Table 1. Individual DBS outcome data on patients with post-traumatic secondary hemidystonia

Author, Year of publication	Study n	Age at surgery (years)	Disease Duration (years)	MRI lesion features	DBS Surgery	Stimulation parameters, Mean/Range	Pre-op severity score	Post-op severity score	% improvement at last follow-up	Follow-up (months)
Sellal et al. 1996	1	16	1	L Thalamus	L VPL Thalamic nucleus	1.75 V, 210 ms, 60 Hz	NA (Incapacitating R hemidystonia)	NA (Spectacular improvement of dystonic postures and movement)	NA (Due to lesion at implant site, electrode taken out. Reverted back to pre-op state)	8
Loher et al. 2000	1	24	9	L Frontal subcortical and cortical, likely upper brain stem dentatothalamic	R GPi	0.75-1.25 V, 150-180 μ s, 130 Hz	NA (Incapacitating L hemidystonia)	NA (Amelioration of phasic dystonic movement, posture, pain)	NA	48
Yianni et al. 2003	1	41	24	NA	Bil GPi	2.8-3.8 V, 110-165 μ s, 125-165 Hz	AIMS 20 (L hemidystonia)	AIMS 20	0	12
Zhang et al. 2006	1	21	4	R Thalamus	Bil STN	NA	BFMDRS 76 (R hemidystonia)	BFMDRS 7	90.8	6
Kim et al. 2012	4	23 32 26 40	3 12 3 37	R GP, Putamen R Peritrigone R GP R GP	L GPi L GPi L GPi L GPi	3.05 V, 180 μ s, 70 Hz	BFMDRS: 21 (m), 6 (d) 16 (m), 5 (d) 14 (m), 4 (d) 8.5 (m), 2 (d)	BFMDRS: 13 (m), 2 (d) 4 (m), 2 (d) 2 (m), 1 (d) 0.5 (m), 0 (d)	38.1 (m), 66.7 (d) 75 (m), 60 (d) 85.7 (m), 75 (d) 94.1 (m), 100 (d)	30 70 31 51
Kwon et al. 2016	1	47	44	L cerebral peduncle, STN, Thalamus, Parietal lobe	L GPi	0.7-1.3 V, 60 μ s, 130 Hz	BFMDRS 26 (R hemidystonia)	BFMDRS 21	20	60

AIMS, Abnormal Involuntary Movement Scale; VPL Ventroposterolateral; STN, Subthalamic Nucleus; BFMDRS, Burke-Fahn-Marsden Dystonia Rating Scale; NA, None Available; GP, Globus Pallidus; GPi, Globus Pallidus Internus; m, movement; d, disability; V, Volts; Hz, Hertz; R, right; L, Left.

HIGHLIGHTS

- Movement disorders are common post severe head injury and have been reported in 13%-66% of patients
- This is the first description of the use of DBS following penetrating head injury
- We present a patient with right-sided hemidystonia post penetrating head injury
- Right inferior frontal lobe and left cerebral peduncle, STN, thalamus and parietal lobe injured
- Improved clinical benefit with left sided GPi DBS, although BFM score improved modestly by 20%

ABBREVIATIONS

GPI - Globus pallidus internus

DBS - Deep brain stimulation

BFMDRS - Burke-Fahn-Marsden Dystonia Rating Score

STN - Subthalamic nucleus

VPL - Ventroposterolateral