

## Subdural Hemorrhage in a Military Aviator

Gordon G. Cable

**BACKGROUND:** The occurrence of any intracranial bleeding is highly significant from an aeromedical risk perspective and potentially career-ending for a military aviator. Where it arises from head trauma, there is always concern regarding ongoing risk of post-traumatic epilepsy.

**CASE REPORT:** A 26-yr-old male military aviator with persistent headache was found to have small right frontal and parietal subacute subdural hematomas, most likely precipitated by minor head trauma and possibly exacerbated by other concurrent physiological stressors. The hematomas resolved with conservative management and the aviator made a full recovery.

**DISCUSSION:** The association between traumatic subdural hematomas and the occurrence of post-traumatic epilepsy is well documented, and this, together with the possibility of recurrent bleeding, must be considered the significant aeromedical risks. However, this case presents an unusual situation of small subdural hematomas in isolation with no other features suggestive of significant traumatic brain injury. Relevant medical literature was found to be substantially lacking, and no other similar case reports of aviators could be found. An aeromedical decision-making process is discussed in relation to returning the aviator to flying duties in a restricted capacity.

**KEYWORDS:** head injury, post-traumatic epilepsy, aeromedical decision-making, intracranial hematoma.

Cable GG. *Subdural hemorrhage in a military aviator*. *Aerosp Med Hum Perform*. 2016; 87(6):575–579.

A subdural hematoma (SDH) is a collection of blood between the dura and the arachnoid layers around the brain and is the most common type of traumatic intracranial mass lesion.<sup>14</sup> Acute subdural hematomas (ASDH) are those less than 72 h old.<sup>14</sup> They are seen commonly in cases of severe traumatic brain injury (TBI) where there have been high-energy acceleration forces.<sup>10</sup> A subdural hematoma that is not associated with an underlying brain injury is sometimes termed a simple or pure subdural hematoma. Subacute subdural hematomas (SSDH) present from 3 to 20 d after acute injury,<sup>1,18</sup> and should also be suspected with a history of head trauma. These are a rarer entity and much less is known about them, but they seem to be associated with lower rates of mortality and morbidity.<sup>10</sup> Chronic subdural hematomas (CSDH) tend to be a disease of the very young and the very old, but are relatively rare in young adults.<sup>12</sup> CSDH develop over the course of weeks.<sup>14</sup> In younger patients they are likely to be a much smaller size due to normal brain volume and thinner subdural space, with head trauma and a defect of hemostasis the most common causes in this group.<sup>15</sup> Both SSDH and CSDH have been linked to seemingly trivial or noncontact forms of head trauma where the mechanism underlying the subdural hemorrhage may be unclear. Examples include non-contact martial arts and vigorous dance,<sup>8</sup> bungee rides,<sup>6</sup> and riding rollercoasters.<sup>4,22</sup> In some cases they are considered spontaneous with hypothesized causes such as increased intravenous pressure (forced exhalation against a closed glottis, lifting heavy weights) and intracranial hypotension (as seen in acute dehydration).<sup>20</sup> Natural and iatrogenic volume depletion has been found to be prevalent in elderly subjects presenting spontaneous CSDH;<sup>24</sup> however, no association has been found with heat-related hypohydration and changes in brain volume which might lead to intracranial hypotension.<sup>21</sup> In younger patients, alcoholism is a more likely association.<sup>14</sup> SDH associated with TBI carries with it a risk of post-traumatic epilepsy (PTE). PTE is a recurrent seizure disorder due to brain injury following trauma, and in 90% of cases this presents within 2 yr of the initial injury.<sup>2</sup> Unfortunately, EEG is not useful for predicting the likelihood of PTE developing in any given patient.<sup>11</sup> The seminal paper by Annegers et al.<sup>3</sup> in 1998

From the RAAF Institute of Aviation Medicine, RAAF Base Edinburgh, South Australia, Australia.

This manuscript was received for review in February 2016. It was accepted for publication in March 2016.

Address correspondence to: Gordon G. Cable, PG.Dip.Av.Med., FACAsM, Royal Australian Air Force Institute of Aviation Medicine, RAAF Base Edinburgh, South Australia 5070, Australia; gordon.cable1@defence.gov.au.

Reprint & Copyright © by the Aerospace Medical Association, Alexandria, VA.

DOI: 10.3357/AMHP.4570.2016

defined severe traumatic brain injury as being characterized by brain contusion, intracranial hematoma, or loss of consciousness (LOC) or post-traumatic amnesia (PTA) more than 24 h; moderate brain injury was characterized by LOC or PTA of 30 min to 24 h or skull fracture; and mild traumatic brain injury was characterized by absence of fracture and LOC or PTA less than 30 min. The difference in PTE risk between the mild and severe categories of TBI is substantial. In the first 12 mo after injury, Annegers reports a standardized incidence ratio for PTE of 3.1 (1.0–7.2) for mild and 95.0 (58.4–151.2) for severe traumatic brain injuries. For the severe group an increased risk was found to persist beyond 10 yr post-injury. The univariate ratio of PTE arising from SDH only was calculated to be 9.8 (3.6–27.1), with brain contusion alone and SDH alone being the strongest risk factors. A more recent retrospective population-based study by Yeh et al. found that the risk of PTE after TBI was significantly higher than a control population of non-TBI patients, even in those with mild head injury, and persisted in both mild and severe TBI groups for 4 yr.<sup>25</sup> The adjusted hazard ratio calculated for subdural hemorrhage was 4.1 (CI 2.2–7.4) compared to brain contusion.

Studies that categorize subdural hematomas by requirement for surgical intervention have found that those requiring neurosurgical evacuation carry the greatest risk of late seizure (cumulative 27.8–44% by 2 yr) compared to no surgery (15.3–19% by 2 yr),<sup>5,19</sup> but it is clear that the nonoperated groups still show a significant cumulative incidence. Studies assessing the risk of developing PTE commonly cite the presence of blood in brain tissue as the underpinning pathophysiology. For example, in the case of cerebral contusion, extravasated blood is hemolyzed, resulting in the deposition of hemoglobin in the neuropil. Liberated iron from hemoglobin and transferrin is sequestered as hemosiderin, which has been found to be a prominent histopathological feature of PTE.<sup>23</sup> Iron in the tissues is toxic due to the formation of oxygen free radicals and lipid peroxidation. Presence or absence of hemosiderin on brain MRI may, therefore, be used to guide prognosis and assessment of risk.

Recurrence of bleeding in the future must also be considered. The reported incidence in the literature of 9–33% relates mostly to surgically treated SDH, ignoring the fact that many SDH patients are treated conservatively. Schmidt et al. conducted a retrospective cohort study of 10,158 patients with SDH and found that the vast majority of recurrences occurred within the first 12 mo, after which the risk was very modest.<sup>17</sup> The 1-yr cumulative risks were 17.7% and 10.4% for surgically and conservatively treated patients, respectively. The overall risk of recurrence increased from 14% at 1 yr to only 15% at 5 yr. Predictors for recurrence included male gender, older age, alcohol addiction, surgical treatment, trauma, and diabetes.

The occurrence of any intracranial bleeding is highly significant from an aeromedical risk perspective and potentially career-ending for a military aviator. Where it arises from head trauma, there is always concern regarding the ongoing risk of post-traumatic epilepsy. This paper reports an unusual case of multiple small subdural hemorrhages arising from seemingly minor head trauma in a young and otherwise fit aviator. The medical literature directly relevant to this case was found to be either

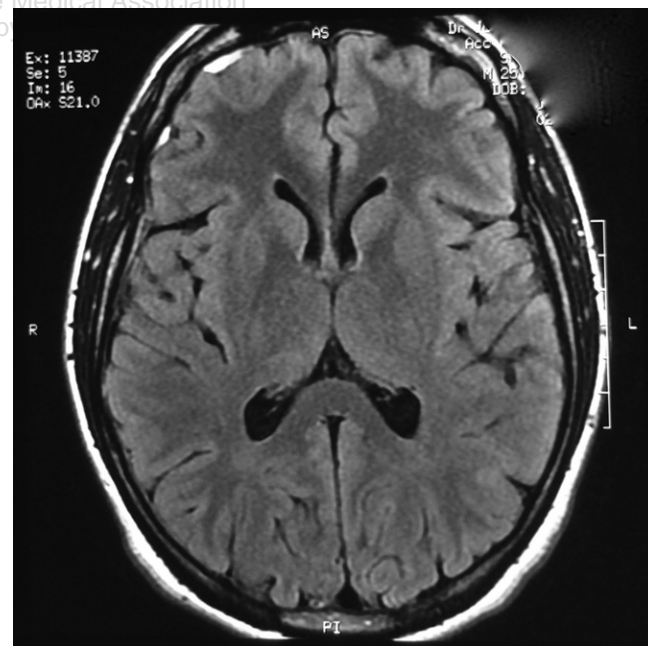
nonexistent or unhelpful, and no other similar case reports of aviators could be found. A first-principles discussion of the aeromedical decision-making process and analysis, as far as possible, of the aeromedical risks based on available literature is presented.

## CASE REPORT

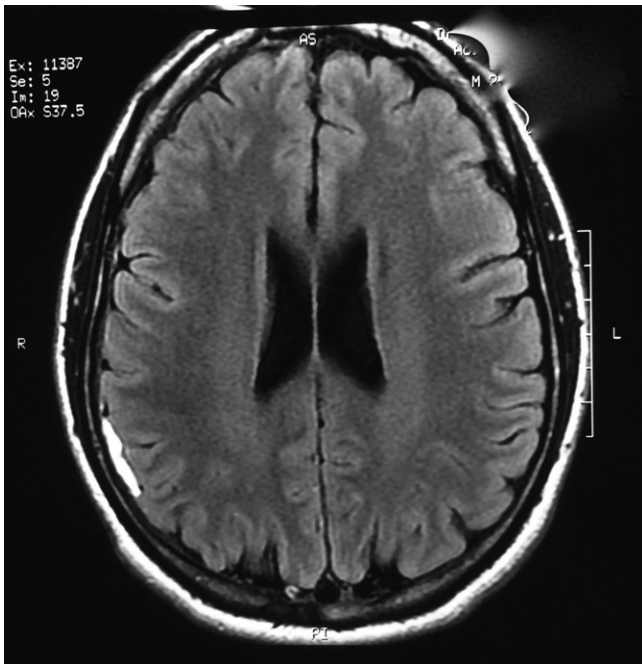
The patient was a 26-yr-old Air Force Airborne Electronics Analyst and crewmember of the P3-C Orion maritime patrol aircraft. This is a large multicrew, multi-engine turboprop aircraft with low levels of  $\pm G_z$  exposure. He had been previously fit and well, on no prescribed or self-medication, in particular anticoagulants. He had no family history of epilepsy, intracranial aneurysm, or bleeding.

In mid-June 2015, the patient embarked on a European holiday, including a 7-d cruise on a small passenger vessel. The weather during the trip was considered unusually hot for the time of year, above 30°C. The patient was physically very active during the holiday, but endeavored to maintain fluid intake in the warm conditions. His consumption of alcohol was moderate and consistent with that of young man on vacation with friends. A thorough review of the history revealed no significant head trauma or fall; however, the patient recalled that at the beginning of the sailing cruise on 27 June, he was involved in a drinking game in a pub that involved wearing an old military-style metal helmet while being struck with considerable force on the top of the head by the bartender with the full shot glass.

The cruise progressed uneventfully, except for bumping his head against an upper bunk. He considered it to be a mild bump, with no bruising or swelling or headache, and thought nothing more of it. He could recall no other episodes of either contact or noncontact head trauma, such as vigorous shaking.



**Fig. 1.** MRI showing right frontal subdural hematomas.



**Fig. 2.** MRI showing right parietal subdural hematoma.

In the days following disembarkation, he continued to consume a moderate amount of alcohol daily and, while traveling by train for 7 h in hot conditions, felt he became quite dehydrated with limited access to water.

During the day of 6 July, 9 d after the drinking game, he noticed the onset of a mild dull right parietal headache, which became persistent although never severe, rated generally at 2 out of 10 on a visual analog pain scale. It was not associated with photophobia, phonophobia, nausea, or vomiting, although it was exacerbated by bending down and head-shaking. At the conclusion of the vacation he returned to Australia on 9 July and finally sought medical advice about the persistent headache on 12 July. A CT head scan ordered on 14 July was initially reported as normal; however, retrospective review much later by a neurologist reported the presence of a “small acute subdural hematoma.” The headache was still present a week later so a further MRI brain scan was arranged on 21 July which revealed hyperintense foci overlying the right frontal and parietal lobes to a maximal radial depth of 3.5 mm, consistent with small subacute subdural hemorrhages, as shown in **Fig. 1** and **Fig. 2**. On 23 July, 17 d after symptom onset, he was reviewed by a neurosurgeon, who found him to be neurologically intact despite the presence of the SDH. Conservative management was advised. He felt the bleed had occurred as a result of dehydration and/or minor trauma, although at that time the patient did not report the drinking game and did not report any trauma

significant enough to result in a hemorrhage other than bumping his head on the bunk bed. By 4 August the headache had resolved and MRI/MRA showed no vascular abnormalities or other underlying lesion, with almost complete resolution of the subdural blood. The patient was assessed by a neurologist on 18 August, who found no focal neurological signs and felt the mechanism of injury could be related to a combination of dehydration, alcohol intake, and minor head trauma tearing a small intracerebral vein. On the basis of a normal EEG, he felt the risk of seizure activity was negligible, as was the risk of a recurrent subdural. The neurosurgeon expressed a similar opinion. Medical investigations excluded coagulopathic disorders and alcohol-related issues. INR, APTT, and platelets were normal. LFTs and CDT were normal with an AUDIT score of 5 (low risk). The aviator’s case was presented to the RAAF Institute of Aviation Medicine for a waiver at 6 mo following the initial injury.

## DISCUSSION

There are two problems in determining the aeromedical risk in this case with any precision. Firstly, there is a definitional problem in categorizing the injury as mild, moderate, or severe. It is an unusual presentation of a small SDH in isolation with no other features typical of closed head injury of sufficient severity to cause subdural bleeding, such as LOC, PTA, skull fracture, or, most importantly, intracerebral contusion. Nonetheless, the presence of intracranial hematoma places him into the severe category according to Annegers’ oft quoted reference, noting that SDH is generally considered to be a significant independent risk factor for late seizures following head injury.<sup>3,7</sup> Consistent with that, the U.S. Air Force would classify this degree of head injury as severe based on the presence of SDH and would disqualify for between 2 and 5 yr depending on role. Airborne Mission Systems crew are eligible for early waiver at 2 yr post severe TBI.<sup>13</sup> The U.S. Navy would permanently disqualify any aviator with any history of intracranial bleeding.<sup>16</sup>

Secondly, available literature pertinent to this patient was found to be imperfect or nonexistent. The majority of the literature relevant to ASDH and SSDH involves moderate to severe head trauma and, in the majority of cases, the SDH requires surgical evacuation, which is understood to increase the risk of PTE substantially.<sup>5</sup> The energy of impact is enough to cause cerebral contusion in 83% of patients with ASDH, axonal injury in many, and, therefore, damage to underlying brain parenchyma.<sup>10</sup> So the risk of PTE estimated in many studies is not really relevant to this case, where the energy of impact was relatively low and no surgical intervention was required.

Applying the strict definitions of TBI to this case, the presence of SDH categorizes the injury as “severe” and aeromedical risk can then be calculated

**Table 1.** Risk of PTE Less Than 12 mo and 1–4 yr Post-Injury (Based on Annegers et al.<sup>3</sup>).

	<12 MO		1-4 YR	
	SIR* (CI)	SEIZURE RISK %	SIR (CI)	SEIZURE RISK %
Mild TBI	3.1 (1.0–7.2)	0.19 (0.06–0.44)	2.1 (1.1–3.8)	0.55 (0.07–0.23)
Severe TBI	95.0 (58.4–151.2)	5.8 (3.6–9.2)	16.7 (8.4–32.0)	1.02 (0.51–2.01)

\* Standardized incidence ratio.

**Table II.** Risk of PTE <12 mo and 1–2 yr Post-Injury (Based on Yeh et al.<sup>25</sup>).

	<12 MO		1-2 YR	
	HR† (CI)	SEIZURE RISK %	HR (CI)	SEIZURE RISK %
Mild TBI	9.01(5.99–13.5)	0.55 (0.36–0.82)	5.20 (3.02–8.94)	0.32 (0.12–0.54)
Severe TBI	23.9 (18.9–30.2)	1.46 (1.15–1.84)	7.08 (4.73–10.6)	0.43 (0.29–0.65)

† Hazard ratio.

from the available population data. However, mitigating factors include that the acceleration force was relatively small and insufficient to cause cerebral contusion, there were no hemosiderin deposits reported in the brain substance, and the SDH resolved fully without surgical treatment. Using Annegers' data and using a population risk of single unprovoked seizure of 61 per 100,000 person-years (0.061% per year),<sup>9</sup> **Table I** examines the risk of PTE for both mild and severe TBI at less than 12 mo post-injury and from 1–4 yr post-injury. It can be seen that for severe head injury, within 12 mo of injury the risk of seizure is approximately 5.8% (3.6 to 9.2%). This drops to 1.02% (0.51–2.10%) 1 to 4 yr after injury. SDH alone carries a rate ratio of 9.8 (3.6–27.1) after TBI, giving a overall risk of seizure of 0.6% (0.22–1.65%) per year.<sup>3</sup>

Using the data from Yeh et al.,<sup>25</sup> even mild head injuries carry a risk of PTE out to 4 yr post-injury. **Table II** uses this data to examine annualized risk. Here the risk of PTE after severe TBI is approximately 1.46% (1.15–1.84%) in the first year, but drops to 0.43% (0.29–0.65%) after 1–2 yr. The hazard ratio of PTE associated specifically with SDH they found to be 4.98, giving an annual risk of 0.3% per year. Therefore, it can be seen in these tables that the mean annualized risk of seizure after severe TBI ranges from 1.46–5.8% in the first 12 mo after injury and drops to 0.43–1.02% in the second year. SDH as an independent risk factor, excluding other injuries, confers a mean overall risk of 0.6% per year.

In terms of recurrence, however, the patient presented for waiver within the 12-mo period where recurrence is most common, with a risk of 10.4%. Thereafter the risk drops to less than 1% per year. The outcomes of a recurrence if it occurred could be suddenly and acutely incapacitating depending upon the size of the space-occupying hematoma. While the patient has none of the predictors associated with recurrence apart from gender, it is hypothesized that thermal stress together with dehydration and moderate alcohol consumption in combination with minor head traumas may have caused the original SDH. Thermal stress and dehydration are not uncommonly experienced in the military aviation environment. However, based on the available literature it was felt that dehydration alone in this context was highly unlikely to lead to a recurrence of a SDH.

In conclusion, the occurrence of a spontaneous SDH in an otherwise young, fit, and healthy man is exceptionally rare, so it must be assumed that with a history of even minor repetitive trauma that this is the underlying etiology. The presence of intracranial blood after trauma by most definitions constitutes a “severe” head injury, but in this case without any other features normally associated with severe head injury or a high velocity impact. After 12 mo the risk of recurrence and seizure

drop to within aeromedically acceptable thresholds, as does the risk of recurrent bleeding. Even within the initial 12-mo window, given his normal role in a multicrew aircraft with minimal exposure to acceleration

forces and his isolated SDH with no other features consistent with significant TBI, his absolute risk while flying was still considered to be low. Therefore, it was recommended that this aviator be restricted to his normal multicrew operations and also restricted geographically to flights of short duration within Australia until 12 mo post-injury to mitigate the risk of recurrence and of PTE, and to expedite his access to acute medical care in the unlikely event it is required. Thereafter consideration could be given to a return to unrestricted flying after a progress MRI. While the annualized risk of seizure may be higher than the background population risk, the risks associated with this injury are thought to be small and mitigated by the patient's multicrew role.

## ACKNOWLEDGMENTS

*Author and affiliation:* Gordon G. Cable, P.G.Dip.Av.Med., FACAsM, Royal Australian Air Force Institute of Aviation Medicine, RAAF Base Edinburgh, South Australia, Australia.

## REFERENCES

1. Adam D, Tudor C. Subacute subdural hematoma. *Rom J Neurol Psychiatry*. 1993; 31(1):63–69.
2. Agrawal A, Timothy J, Pandit L, Manju M. Post-traumatic epilepsy: an overview. *Clin Neurol Neurosurg*. 2006; 108(5):433–439.
3. Annegers JF, Hauser WA, Coan SP, Rocca WA. A population-based study of seizures after traumatic brain injuries. *N Engl J Med*. 1998; 338(1):20–24.
4. Bo-Abbas Y, Bolton CF. Roller-coaster headache. [Letter.] *N Engl J Med*. 1995; 332(23):1585.
5. Englander J, Bushnik T, Duong TT, Cifu DX, Zafonte R, et al. Analyzing risk factors for late posttraumatic seizures: a prospective, multicenter investigation. *Arch Phys Med Rehabil*. 2003; 84(3):365–373.
6. Fitzgerald JJ, Bassi S, White BD. A subdural haematoma following ‘reverse’ bungee jumping. *Br J Neurosurg*. 2002; 16(3):307–308.
7. Frey LC. Epidemiology of posttraumatic epilepsy: a critical review. *Epilepsia*. 2003; 44:11–17.
8. Galvez JC, Hecht S. Subacute subdural hematoma in a karate instructor after noncontact head trauma. *Curr Sports Med Rep*. 2011; 10(1):11–13.
9. Hauser WA, Beghi E. First seizure definitions and worldwide incidence and mortality. *Epilepsia*. 2008; 49(Suppl. 1):8–12.
10. Huang KT, Bi WL, Abd-El-Barr M, Yan SC, Tafel IJ, et al. The neurocritical and neurosurgical care of subdural hematomas. *Neurocrit Care*. 2015; [Epub ahead of print].
11. Jennett B, Van De Sande J. EEG prediction of post-traumatic epilepsy. *Epilepsia*. 1975; 16(2):251–256.
12. Liliang PC, Tsai YD, Liang CL, Lee TC, Chen HJ. Chronic subdural haematoma in young and extremely aged adults: a comparative study of two age groups. *Injury*. 2002; 33(4):345–348.
13. McIntee M, Van Syoc D. Traumatic brain injury. USAF Waiver Guide. Wright-Patterson AFB (OH): USAF School of Aerospace Medicine; 2014:995–1002.

14. Meagher R, Young W. Subdural hematoma. 2015; [Accessed 26 November 2015.] Available from: <http://emedicine.medscape.com/article/1137207-overview>.
15. Missori P, Maraglino C, Tarantino R, Salvati M, Calderaro G, et al. Chronic subdural haematomas in patients aged under 50. *Clin Neurol Neurosurg*. 2000; 102(4):199–202.
16. NMOTC. U.S. Navy aeromedical reference and waiver guide. Pensacola (FL): Naval Aerospace Medicine Institute; 2015. [Accessed December 2015.] Available from: <http://www.med.navy.mil/sites/nmotc/nami/arwg/Pages/AeromedicalReferenceandWaiverGuide.aspx>.
17. Schmidt L, Gortz S, Wohlfahrt J, Melbye M, Munch TN. Recurrence of subdural haematoma in a population-based cohort—risks and predictive factors. *PLoS One*. 2015; 10(10):e0140450.
18. Takeuchi S, Takasato Y, Otani N, Miyawaki H, Masaoka H, et al. Subacute subdural hematoma. *Acta Neurochir Suppl*. 2013; 118:143–146.
19. Temkin NR. Risk factors for posttraumatic seizures in adults. *Epilepsia*. 2003; 44(Suppl. 10):18–20.
20. Wang HS, Kim SW, Kim SH. Spontaneous chronic subdural hematoma in an adolescent girl. *J Korean Neurosurg Soc*. 2013; 53(3):201–203.
21. Watson P, Head K, Pittiot A, Morris P, Maughan RJ. Effect of exercise and heat-induced hypohydration on brain volume. *Med Sci Sports Exerc*. 2010; 42(12):2197–2204.
22. Williams K, Kouloumberis P, Englehard H. Subacute subdural hematoma in a 45-year-old woman with no significant past medical history after a roller coaster ride. *Am J Emerg Med*. 2009; 27(4):517.e5–517.e6.
23. Willmore LJ. Post-traumatic epilepsy: cellular mechanisms and implications for treatment. *Epilepsia*. 1990; 31(Suppl. 3):S67–S73.
24. Wirkowski E, DeMuro J, Hanna A, Yassen J, Narain R, Elcin S. Spontaneous and iatrogenic dehydration in the elderly alone or in combination with antiplatelet/anticoagulation agents and risk of subdural hematoma. *World J Cardiovasc Dis*. 2014; 4(1):1–4.
25. Yeh CC, Chen TL, Hu CJ, Chiu WT, Liao CC. Risk of epilepsy after traumatic brain injury: a retrospective population-based cohort study. *J Neurol Neurosurg Psychiatry*. 2013; 84(4):441–445.



IP: 5.188.216.223 On: Sun, 09 Sep 2018 07:35:21  
 Copyright: Aerospace Medical Association  
 Delivered by Ingenta