

Diffuse Brain Hypoperfusion in Advanced Leukoencephalopathy with Calcifications and Cysts

Emanuele Bartolini, MD,*† Andrea Bianchi, MD,‡§ Ilaria Bartolomei, MD, PhD,||
Alessandra Vella, MD, PhD,¶|| Lapo Sali, MD, PhD,§ Antonio Ciccarone,#
Fabrizio Salvi, MD, PhD,|| and Mario Mascalchi, MD, PhD‡§

Leukoencephalopathy with calcifications and cysts (LCC) is an uncommon condition of unknown etiology occurring in children and adults. Pathological findings include obliterative hyalinosis of the small vessels, myelin loss, intense gliosis, Rosenthal fiber formation, microcalcifications, and hemosiderin deposits. Herein we report a 55-year-old man with LCC documented 10 years ago, in whom we examined brain perfusion by pseudocontinuous arterial spin labeling technique. We demonstrated diffused hypoperfusion of the affected white matter (WM) and of the subcortical gray matter (GM) and cortical GM in the patient in comparison to a group of healthy control subjects, using both qualitative evaluation and region of interest analysis. WM and subcortical GM hypoperfusion reflects the known distribution of LCC microangiopathy. We speculate that cortical hypoperfusion may be related to cerebral atrophy or may reflect deafferentation secondary to severe leukoencephalopathy, and may possibly contribute to severe motor and cognitive impairment. Further studies addressing cerebral blood flow in LCC are necessary. **Key Words:** White matter—perfusion MRI—regional CBF—arterial spin labeling—3-T MRI—perfusion—neuroimaging.

© 2016 National Stroke Association. Published by Elsevier Inc. All rights reserved.

From the *Neurology Unit and Laboratories, A. Meyer Children's Hospital, Florence, Italy; †Imago7, IRCCS Stella Maris Foundation, Pisa, Italy; ‡Structural and Functional Neuroradiology Research Program, A. Meyer Children's and Careggi Hospitals of Florence, Florence, Italy; §"Mario Serio" Department of Experimental and Clinical Biomedical Sciences, University of Florence, Italy; ||"Il Bene" Center for Immunological and Rare Neurological Diseases at Bellaria Hospital, IRCCS Neurologia Città di Bologna, Bologna, Italy; ¶Nuclear Medicine, "Le Scotte" University Hospital of Siena, Siena, Italy; and #Medical Physics, A.Meyer Children Hospital of Florence, Florence, Italy.

Received December 8, 2015; revision received March 2, 2016; accepted April 30, 2016.

Address correspondence to Emanuele Bartolini, MD, Children's Hospital A. Meyer—University of Florence, VialePieraccini 24, 50139 Firenze, Italy. E-mail: emanuele.bartolini@meyer.it.

1052-3057/\$ - see front matter

© 2016 National Stroke Association. Published by Elsevier Inc. All rights reserved.

<http://dx.doi.org/10.1016/j.jstrokecerebrovasdis.2016.04.030>

Leukoencephalopathy with calcifications and cysts (LCC) is an uncommon condition of unknown cause, with typical computed tomography and magnetic resonance imaging (MRI) findings.¹ Clinical features include seizures, cognitive decline, and extrapyramidal, cerebellar, or pyramidal signs, but also intracranial hypertension due to cyst mass effect and intracranial hemorrhages.²⁻⁴ The histopathological assessment of the white matter (WM) adjacent to cysts shows obliterative hyalinosis of the small vessels, myelin loss, intense gliosis, Rosenthal fiber formation, microcalcifications, and hemosiderin deposits.⁵ Herein we demonstrate diffusely decreased regional cerebral blood flow (rCBF) in an adult patient with advanced LCC by perfusion MRI.

The patient's clinical presentation had been previously described.⁶ Briefly, 2 generalized seizures occurred in adolescence. At the age of 45, the patient developed

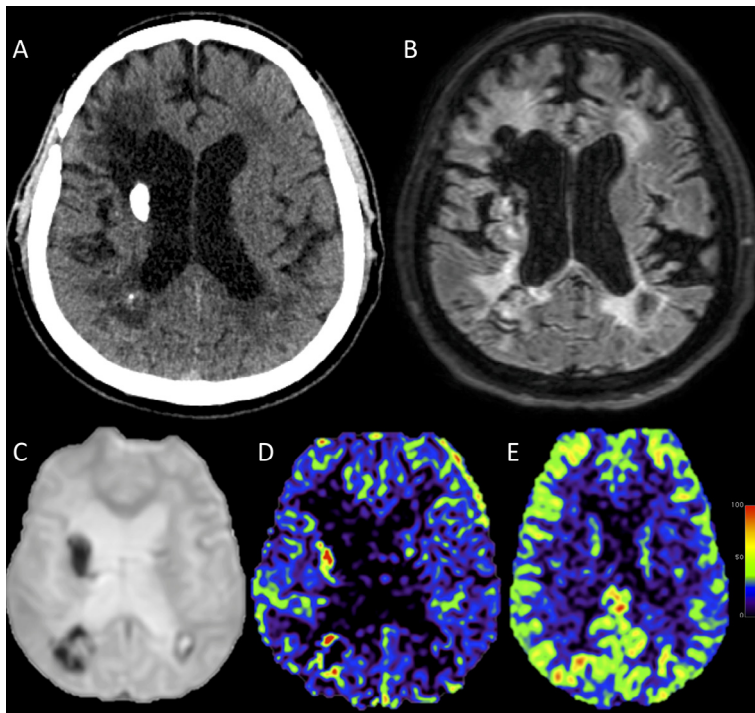


Figure 1. (A) Plain computed tomography at the midventricular level showing dense calcifications in the right striatum and minor calcium deposits in the right paratrigonal WM. (B) Axial T2-weighted fluid-attenuated inversion recovery MR image at the midventricular level showing diffuse hyperintensity of the periventricular WM and curvilinear hypointense rims in the right peritrigonal WM corresponding to a cyst wall. (C) Echo-planar MR image without pseudocontinuous arterial spin labeling used to quantify the equilibrium magnetization for the computation of rCBF. Note that calcifications in the right striatum and in the right peritrigonal WM are outlined as markedly hypointense areas. (D) rCBF map at the midventricular level showing diffusely decreased perfusion compared to a corresponding rCBF map in a healthy control subject (E). The red dots in the right striatum and in the right peritrigonal region (D) correspond to calcifications. Abbreviations: MR, magnetic resonance; rCBF, regional cerebral blood flow; WM, white matter.

a slowly progressive ataxic–spastic gait and cognitive decline. Computed tomography showed basal ganglia calcifications. MRI revealed diffuse leukoencephalopathy as well as multiple cysts, exhibiting a rim of contrast enhancement. LCC was pathologically diagnosed after resection of a right frontal cyst. Over the next 10 years, the patient’s clinical status progressively worsened, resulting in pseudobulbar syndrome. Serial magnetic resonance (MR) examinations showed that leukoencephalopathy was unchanged, but new small cysts appeared, calcifications increased, and diffuse cerebral atrophy developed.

Finally, we performed perfusion 3-T MR with pseudocontinuous arterial spin labeling technique (see Methods, [Appendix S1](#)).⁷ On qualitative inspection, the patient showed a diffusely decreased rCBF compared to 8 healthy subjects (male = 5, female = 3; mean age = 46.2 ± 18.6 years) ([Fig 1](#)). Region of interest analysis confirmed decreased rCBF in the T2-weighted hyperintense WM (mean = 9.9, normal value = 13.3 ± 2.2 mL/100 g/min), bilateral perigenuate anterior cingulate cortex (mean = 26.3, normal value = 46.1 ± 9.6 mL/100 g/min), bilateral posterior cingulate cortex (mean = 18.1, normal value = 40.1 ± 8.2 mL/100 g/min), and right thalamus (mean = 13.2; normal value = 29.4 ± 3.5 mL/100 g/min) ([Fig S1](#) and [Table S1](#)).

In the only reported autoptic case of LCC, small-vessel changes were heterogeneously distributed over WM and subcortical gray matter (GM), but cortical GM and leptomeningeal vessels were spared.⁵ In hereditary and sporadic small-vessel diseases, contrast-enhanced MR per-

fusion studies showed decreased WM perfusion but preserved cortical GM flow.^{8,9} On the contrary, in subcortical arteriosclerotic encephalopathy, a single-photon emission tomography study highlighted areas of cortical hypoperfusion, interpreted as deafferentation phenomena secondary to severe WM damage.¹⁰

In our patient, hypoperfusion of WM and subcortical GM reflects the known distribution of microangiopathy, whereas cortical hypoperfusion may be related to cerebral atrophy or reflects deafferentation secondary to severe leukoencephalopathy and possibly contributes to severe motor and cognitive impairment. Further studies addressing rCBF in LCC are necessary.

Appendix: Supplementary Material

Supplementary data to this article can be found online at [doi:10.1016/j.jstrokecerebrovasdis.2016.04.030](https://doi.org/10.1016/j.jstrokecerebrovasdis.2016.04.030).

References

1. Corboy JR, Gault J, Kleinschmidt-DeMasters BK. An adult case of leukoencephalopathy with intracranial calcifications and cysts. *Neurology* 2006;67:1890-1892.
2. Labrune P, Lacroix C, Goutières F, et al. Extensive brain calcifications, leukodystrophy, and formation of parenchymal cysts: a new progressive disorder due to diffuse cerebral microangiopathy. *Neurology* 1996;46:1297-1301.
3. Daglioglu E, Ergungor F, Hatipoglu HG, et al. Cerebral leukoencephalopathy with calcifications and cysts operated for signs of increased intracranial pressure: case report. *Surg Neurol* 2009;72:177-181.

4. Banks GP, Shennan A, Weiss SA, et al. A case of late-onset leukoencephalopathy, calcifications, and cysts presenting with intracerebral hemorrhage resembling a neoplasm. *Cerebrovasc Dis* 2013;35:396-397.
5. Kleinschmidt-DeMasters BK, Cummings TJ, Hulette CM, et al. Adult cases of leukoencephalopathy, cerebral calcifications, and cysts: expanding the spectrum of the disorder. *J Neuropathol Exp Neurol* 2009;68:432-439.
6. Marelli C, Savoirdo M, Fini N, et al. Late presentation of leukoencephalopathy with calcifications and cysts: report of two cases. *J Neurol Neurosurg Psychiatry* 2008;79:1303-1304.
7. Alsop DC, Detre JA, Golay X, et al. Recommended implementation of arterial spin-labeled perfusion MRI for clinical applications: a consensus of the ISMRM perfusion study group and the european consortium for ASL in dementia. *Magn Reson Med* 2015;73:102-116.
8. Chabriat H, Pappata S, Ostergaard L, et al. Cerebral hemodynamics in CADASIL before and after acetazolamide challenge assessed with MRI bolus tracking. *Stroke* 2000;31:1904-1912.
9. O'Sullivan M, Lythgoe DJ, Pereira AC, et al. Patterns of cerebral blood flow reduction in patients with ischemic leukoaraiosis. *Neurology* 2002;59:321-326.
10. De Cristofaro MTR, Mascalchi M, Pupi A, et al. Subcortical arteriosclerotic encephalopathy: single photon emission computed tomography—magnetic resonance imaging correlation. *Am J Physiol Imaging* 1990;5:68-74.