

# “Opening the Unopenable”: Endovascular Treatment in a Patient with Three Months’ Internal Carotid Artery Occlusion and Hemispheric Symptomatic Hypoperfusion

Guido Bigliardi, MD,\* Maria Luisa Dell’Acqua, MD,\* Stefano Vallone, MD,†  
 Filippo Barbi, MD,\* Roberta Pentore, MD,\* Livio Picchetto, MD,\*  
 Paolo Carpeggiani, MD,† Paolo Nichelli, MD, PhD,\* and Andrea Zini, MD\*

---

*Background:* Internal carotid artery occlusion (ICAO) is defined as “untouchable” by all specialists; no treatment is indicated because intervention risks (carotid endarterectomy (CEA) or endovascular treatment) are usually much more than benefits.<sup>1,2</sup> We report the case of a patient admitted to our hospital with an atherothrombotic ischemic stroke due to symptomatic acute ICAO, who developed a recurrent stroke with hemispheric hypoperfusion and was treated in the emergency department with ICAO revascularization after 60 days of occlusion finding. *Case Description:* D.G., a 62-year-old man, came to our attention for a transient episode of left weakness and hypoesthesia. The electrocardiogram revealed a new diagnosis of atrial fibrillation. CT angiography showed right ICAO; computed tomography and magnetic resonance imaging studies with perfusion imaging revealed a severe hemispheric hypoperfusion. Full anticoagulation therapy was started, and antihypertensive therapy was reduced to help collateral circulation. Some weeks later, the patient was readmitted to the stroke unit for 2 episodes of left-hand weakness. Cerebral angiography confirmed right ICAO from the proximal tract to the siphon. After some days, the patient suffered a femoral hemorrhagic lesion, with active bleeding, and was treated with surgical intervention. On the following day, the patient presented with left hemiplegia with hemianesthesia (National Institutes of Health Stroke Scale score = 14). The patient was treated in the emergency department with a complex endovascular treatment with complete recanalization of ICAO by positioning 3 stents through the intravenous infusion of abciximab. After intensive rehabilitation, at the 3- and 6-month follow-up evaluations, the patient regained autonomy. *Conclusion:* In literature, treatment of chronic ICAO is not indicated. Endovascular recanalization may be beneficial to patients with chronic cerebral hypoperfusion due to ICAO, when all conservative medical therapies have failed. **Key Words:** Stroke—internal carotid artery occlusion—hypoperfusion—stenting.

© 2016 National Stroke Association. Published by Elsevier Inc. All rights reserved.

---

From the \*Stroke Unit—Neurology Clinic, Department of Neuroscience, Nuovo Ospedale Civile S. Agostino-Estense, AUSL Modena, Modena, Italy; and †Neuroradiology Unit, Department of Neuroscience, Nuovo Ospedale Civile S. Agostino-Estense, AUSL Modena, Modena, Italy.  
 Received January 25, 2016; revision received April 20, 2016; accepted April 27, 2016.

Address correspondence to Guido Bigliardi, MD, Stroke Unit—Neurology Clinic, Department of Neuroscience, Nuovo Ospedale Civile S. Agostino-Estense, AUSL Modena, Modena, Italy. E-mail: [guido.bigliardi@gmail.com](mailto:guido.bigliardi@gmail.com).

1052-3057/\$ - see front matter

© 2016 National Stroke Association. Published by Elsevier Inc. All rights reserved.

<http://dx.doi.org/10.1016/j.jstrokecerebrovasdis.2016.04.019>

## Case Presentation

D.G., a 62-year-old man with a history of pharmacologically treated hypertension, smoking habit, and obesity (BMI 33.4), came to our attention for a transient episode of weakness and hypoesthesia in his left hand. A computed tomography (CT) scan showed an acute cerebral ischemic lesion involving the right parietal lobe, and CT angiography showed postbulbar right internal carotid artery occlusion (ICAO) (Fig 1, a); CT perfusion revealed a right hemispheric hypoperfusion in mean transit time maps (Fig 1, b) without modification in the cerebral blood volume. The electrocardiogram showed an atrial fibrillation. The patient was admitted to the stroke unit.

The first magnetic resonance imaging (MRI) study with all-brain perfusion sequences and magnetic resonance angiography confirmed the presence of multiple subacute ischemic areas on the right side and right ICAO; hypoperfusion of the right cerebral hemisphere was also confirmed. Anticoagulant therapy was started with low-molecular-weight heparin and antihypertensive therapy was reduced to help collateral circulation. The patient was discharged with planned follow-up exams. After 1 month, the result of the control Color Doppler exam was unchanged and therapy with a new oral anticoagulant was started (dabigatran).

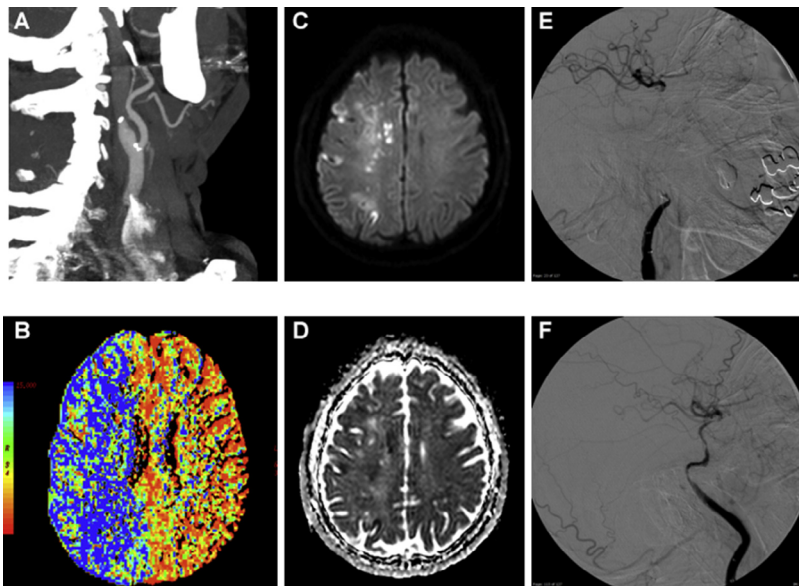
Some weeks later, the patient was readmitted to the stroke unit following 2 transient episodes of weakness in his left hand. The result of the brain CT scan was unchanged.

The MRI study showed some small new ischemic lesions in the right parietal and occipital lobes, right ICAO, and hypoperfusion in the right cerebral hemisphere. We decided to perform a diagnostic cerebral angiography that

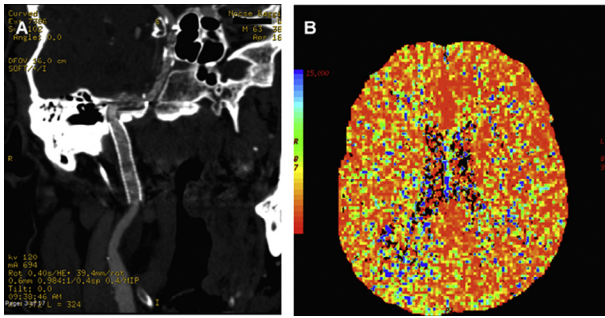
confirmed right ICAO involving the proximal tract through to the siphon; the internal carotid artery appeared to be recanalized from the intracranial siphon and fed by external carotid collateral branches.

Seven days later, the patient suffered a hemorrhagic lesion posteriorly to the right superficial femoral artery, with active bleeding. After the angiological evaluation, the patient was treated by the vascular surgeon and required blood transfusions after the intervention. On the following day, early in the morning, the patient presented with left hemiplegia with hemianesthesia. A new MRI study showed recent ischemic lesions in the peripheral territory of the middle cerebral artery, suggesting failure of collateral circulation (Fig 1, c,d).

An emergency cerebral angiography was performed; the interventional neuroradiologist positioned an 8F concentric catheter with a distal balloon in the right common carotid. A selective catheterization of the occluded ICA was performed with a microcatheter Rebar 18 (Covidien) and microwire Synchro-14 (Stryker) from the site of the occlusion up to the siphon, downstream of the ophthalmic artery; injection of contrast medium from the microcatheter confirmed patency of the distal siphon and the presence of devices in the true lumen of the vessel. A complete recanalization of the ICAO (Fig 1, e,f) was obtained by the telescopic positioning of 2 stents Solitaire 5 × 30 (Covidien) in the cavernous and intrapetrous tracts of the siphon, and of a carotid stent, Precise 7 × 40 (Cordis), in the distal extracranial tract of the internal carotid artery, with thromboaspiration and blockage flow using an 8F balloon catheter. The presence of flow was documented by the injection of a contrast medium, but initially appeared very slow. Complete recanalization of the vessel with optimal blood flow was obtained through the infusion of abciximab



**Figure 1.** (a) CT angiography showed right ICAO in the postbulbar tract. (b) CT perfusion mean transit time maps showed a severe right hemispheric hypoperfusion. (c and d) Magnetic resonance images of acute and subacute ischemic lesions in diffusion-weighted imaging (c) and apparent diffusion coefficient (d) sequences. (e) Cerebral angiography confirmed right ICAO, with intracranial collateral branches. (f) Final sequence of cerebral angiography showed complete recanalization of the internal carotid artery by the positioning of 3 stents. Abbreviations: CT, computed tomography; ICAO, internal carotid artery occlusion.



**Figure 2.** (a) Six months' follow-up CT angiography showing patency of the right ICA, with 2 Solitaire stents in cavernous and intrapetrous tracts of right siphon and an extracranial Precise stent in the distal ICA. (b) Twelve months' follow-up CT perfusion mean transit time maps showed normal right hemispheric perfusion. Abbreviations: CT, computed tomography; ICA, internal carotid artery.

(ReoPro, Eli Lilly Italia Spa): a first bolus dose followed by a second dose in continuous intravenous infusion throughout the following 12 hours.

After intensive rehabilitation, at the 3- and 6-month follow-up evaluations, the patient regained his autonomy and was able to walk without assistance. Ultrasound and CT angiography controls (Fig 2, a) confirmed the patency of the right internal carotid, and follow-up CT perfusion showed improvement in the right cerebral hemisphere flow (Fig 2, b).

## Discussion

In literature, treatment of chronic ICAO is not indicated. Endovascular recanalization may be beneficial to patients with chronic cerebral hypoperfusion due to ICAO, and with recurrent clinical relevant episodes, when all conservative medical therapies have failed.

The case in the present study underlines the importance of clinical and vascular follow-up assessments to improve therapeutic chances in unstable stroke patients. The description of endovascular procedure may be useful for reproduction in common practice in similar situations.

This complex and delayed procedure inevitably requires the positioning of carotid stents. It is possible that the success of the procedure is related to previous anti-coagulant therapy (low-molecular-weight heparin and dabigatran), which maintained the soft consistency of the thrombus, facilitating advancement through the occlusion.

## References

1. Shojima M, Nemoto S, Morita A, et al. Protected endovascular revascularization of subacute and chronic total occlusion of the internal carotid artery. *AJNR Am J Neuroradiol* 2010;31:481-486.
2. Rostambeigi N, Khatri R, Hassan AE, et al. Duplex ultrasound assisted endovascular revascularization of chronic internal carotid artery occlusion: technical note. *J Vasc Interv Neurol* 2013;6:42-46.