

## ILLUSTRATIVE CASE

# Cerebrovascular Complications of Pediatric Pneumococcal Meningitis in the PCV13 Era

Miya E. Bernson-Leung, MD, Laura L. Lehman, MD

## WHEN IT'S MORE THAN MENINGITIS

### Case 1

A previously healthy, full-term 5-month-old girl presented to the emergency department with a 1-day history of fever to 103°F, emesis, poor feeding, and progressive lethargy. She had recently started day care. The patient had received her routine 2- and 4-month childhood vaccines on schedule, including the 13-valent pneumococcal conjugate vaccine (PCV13). Initial examination revealed decreased responsiveness, rightward gaze preference, decreased movement of the left side, and positive Brudzinski sign. Laboratory testing is as in Table 1. Ceftriaxone and vancomycin were started at meningitic dosing. Cerebrospinal fluid grew *Streptococcus pneumoniae* serotype 33F, a nonvaccine serotype.

### Case 2

A previously healthy 21-month-old boy presented to the emergency department with a 1-day history of fever to 103°F, emesis, cough, and lethargy. Rapid influenza testing was positive for influenza A, and oseltamivir was started. History was notable for day care attendance and multiple sick contacts. He was fully immunized, including PCV13.

The next morning, he had a brief seizure with eye deviation and generalized convulsions, and became obtunded. Simultaneously, blood culture grew gram-positive cocci in pairs and chains. He returned to the emergency department, where he had right-sided weakness, posturing, rightward eye deviation, and meningismus as well as further seizures requiring lorazepam and fosphenytoin. Laboratory testing is as in Table 1. Ceftriaxone and vancomycin were started at meningitic dosing. Cerebrospinal fluid grew *S pneumoniae* serotype 15B, a nonvaccine serotype.

## Question

What are possible causes of altered mental status, seizures, and focal neurologic deficits in a febrile child, and what further evaluation should be performed?

## Discussion

Lethargy, seizures, and focal neurologic deficits immediately raise concern for bacterial meningitis or meningoencephalitis, even in immunized children; lumbar puncture is confirmatory.<sup>1</sup> Transient altered mental status and focal neurologic deficits can be postictal phenomena in the right clinical context. However, it is important to recognize

---

www.hospitalpediatrics.org

DOI:10.1542/hpeds.2015-0236

Copyright © 2016 by the American Academy of Pediatrics

Address correspondence to Miya Bernson-Leung, MD, Department of Neurology, Boston Children's Hospital, 300 Longwood Ave, Boston, MA 02115. E-mail: miya.bernson-leung@childrens.harvard.edu

HOSPITAL PEDIATRICS (ISSN Numbers: Print, 2154-1663; Online, 2154-1671).

**FINANCIAL DISCLOSURE:** The authors have indicated they have no financial relationships relevant to this article to disclose.

**FUNDING:** No external funding.

**POTENTIAL CONFLICT OF INTEREST:** The authors have indicated they have no potential conflicts of interest to disclose.

Dr Bernson-Leung acquired the clinical data, and drafted the initial manuscript; Dr Lehman analyzed and interpreted the clinical data, and reviewed and revised the manuscript; and both authors approved the final manuscript as submitted.

Department of Neurology,  
Boston Children's  
Hospital, Boston,  
Massachusetts

**TABLE 1** Laboratory Testing

	Case One	Case Two
WBC at presentation, serum	2.8 K cells/ $\mu$ L	6.3 K cells/ $\mu$ L
ANC at presentation, serum	1.22 K cells/ $\mu$ L	5.2 K cells/ $\mu$ L
Peak WBC, serum	28.98 K cells/ $\mu$ L	15.47 K cells/ $\mu$ L
Peak ANC, serum	15.12 K cells/ $\mu$ L	9.21 K cells/ $\mu$ L
C-reactive protein, serum	28.55 mg/dL	8.77 mg/dL
Erythrocyte sedimentation rate, serum	75 mm/h	62 mm/h
Von Willebrand factor antigen	342%	Not tested
WBC, CSF	36 cells/ $\text{mm}^3$ (64% neutrophils/bands)	825 cells/ $\text{mm}^3$
RBC, CSF	22 cells/ $\text{mm}^3$	200 cells/ $\text{mm}^3$
Protein, CSF	346.5 mg/dL	421 mg/dL
Glucose, CSF	Below threshold of detection	Below threshold of detection
Bacterial culture, CSF	<i>Streptococcus pneumoniae</i> - serotype 33F - sensitive to ceftriaxone (MIC by Etest 0.12)	<i>Streptococcus pneumoniae</i> - serotype 15B - sensitive to ceftriaxone (MIC by Etest 0<0.03)
Immunodeficiency evaluation	Normal immune globulins, complement, T- and B-cell subsets, peripheral blood smear review for functional asplenia, and Toll-like receptor function.	Normal IgG. Pneumococcal IgG panel during hospitalization showed humoral immunity to all PCV13 serotypes but not to 15B.

ANC, absolute neutrophil count; CSF, cerebrospinal fluid; Ig, immunoglobulin; MIC, minimum inhibitory concentration; RBC, red blood cell count; WBC, white blood cell count.

that altered mental status, seizures, and focal deficits are also presenting features of stroke in children. In non-neonates with acute arterial stroke, 11.8% presented with altered mental status, 15.8% with seizures, and 72.4% with focal weakness.<sup>2</sup> Urgent neuroimaging is therefore warranted to establish the diagnosis of acute stroke. By expert consensus, the modality of choice is MRI with T1, T2, fluid-attenuated inversion recovery, T2\* (gradient-echo or susceptibility-weighted), diffusion-weighted, and contrast sequences, and consideration of magnetic resonance angiography (MRA) and magnetic resonance venography. Imaging will help to identify stroke subtype (arterial ischemic versus cerebral sinovenous thrombosis [CSVT] versus hemorrhagic) and therefore guide further management. Computed tomography is suboptimal for the detection of CSVT and early ischemic stroke.<sup>3</sup>

The inclusion of pneumococcal conjugate vaccines in the standard pediatric immunization series since 2000 has significantly lowered the overall incidence of invasive pneumococcal disease and specifically pneumococcal meningitis.<sup>4</sup> However, the introduction of 7-valent pneumococcal conjugate vaccine (PCV7) in 2000 and PCV13 in 2010 has also changed

the landscape of pneumococcal disease, reflecting the rise of “replacement” serotypes not covered by existing vaccines.<sup>5,6</sup> A recent study compared the period after PCV7 introduction but before PCV13 with the period after PCV13, and found a further reduction in the number of cases of invasive pneumococcal disease at 8 children’s hospitals, but no reduction in cases of pneumococcal meningitis.<sup>7</sup>

Even healthy, vaccinated children develop invasive pneumococcal disease. In 1 study, >95% of children with invasive pneumococcal disease had received at least 1 dose of PCV7, and immunodeficiency was present in fewer than 10%.<sup>6</sup> One possible explanation is an increased frequency of nonvaccine serotypes, some of which may be more virulent or invasive.<sup>5,6</sup> Patient 1 had serotype 33F and patient 2 had serotype 15B. Serogroups 15 and 33 have been noted to be increasing causes of invasive disease after the introduction of PCV7.<sup>8</sup> In 2003 to 2009, serotype 33F comprised 5.3% of all cases of invasive disease but comprised only 0.74% of nasopharyngeal samples from asymptomatic colonized children. Its invasive capacity is up to 50-fold higher than less-invasive serotypes, and higher than any other nonvaccine serotype in this sample.

Serotype 15B/C comprised 3.8% of invasive serotypes and 9% of colonization samples, with low invasive capacity. Serotype 19A, by comparison, was the most common cause of invasive disease (39%) but also of colonization (14%), with an intermediate invasive capacity; it is now included in PCV13.<sup>6</sup> Serotype 33F is included in a 15-valent conjugate vaccine currently in trial.<sup>9</sup> Both 15B and 33F are included in the 23-valent pneumococcal polysaccharide vaccine but this vaccine is not currently recommended for children without underlying medical conditions and is not intended to replace conjugate vaccines.<sup>10</sup> The large number of pneumococcal serotypes, and the possibility for even less-invasive serotypes such as 15B to produce invasive disease as in patient 2, also provide support for alternative vaccination strategies that are not serotype-specific.<sup>11,12</sup>

Stroke and meningitis are frequently comorbid; before the introduction of PCV7, strokes were discovered in 10% to 27% of children with acute bacterial meningitis.<sup>13–15</sup> Some small studies suggest *S pneumoniae* infection is more commonly associated with stroke relative to other pathogens,<sup>13,15</sup> although others found no association.<sup>14</sup> In a population-based series conducted in the United Kingdom after the

introduction of PCV7, 10 (42%) of 24 children with pneumococcal meningitis specifically were found to have stroke, including 8 with arterial ischemic stroke and 3 with CSVT; 1 child had both. Children with stroke were more likely to have seizures at presentation, focal signs, or anemia, and more likely to have serotypes not covered by PCV7. They were also more likely to have a poor outcome at follow-up than those without strokes, with an adjusted odds ratio of 40.<sup>16</sup> A study of 173 cases of pneumococcal meningitis in US children in the 3 years before and 3 years after PCV13 introduction (2007–2009 vs 2011–2013) found that infarcts and CSVT were common and, surprisingly, had increased (albeit not significantly). In 2011 to 2013, 26% of

children with pneumococcal meningitis had infarcts and 7% had CSVT versus 16% and 4%, respectively, in 2007 to 2009.<sup>7</sup>

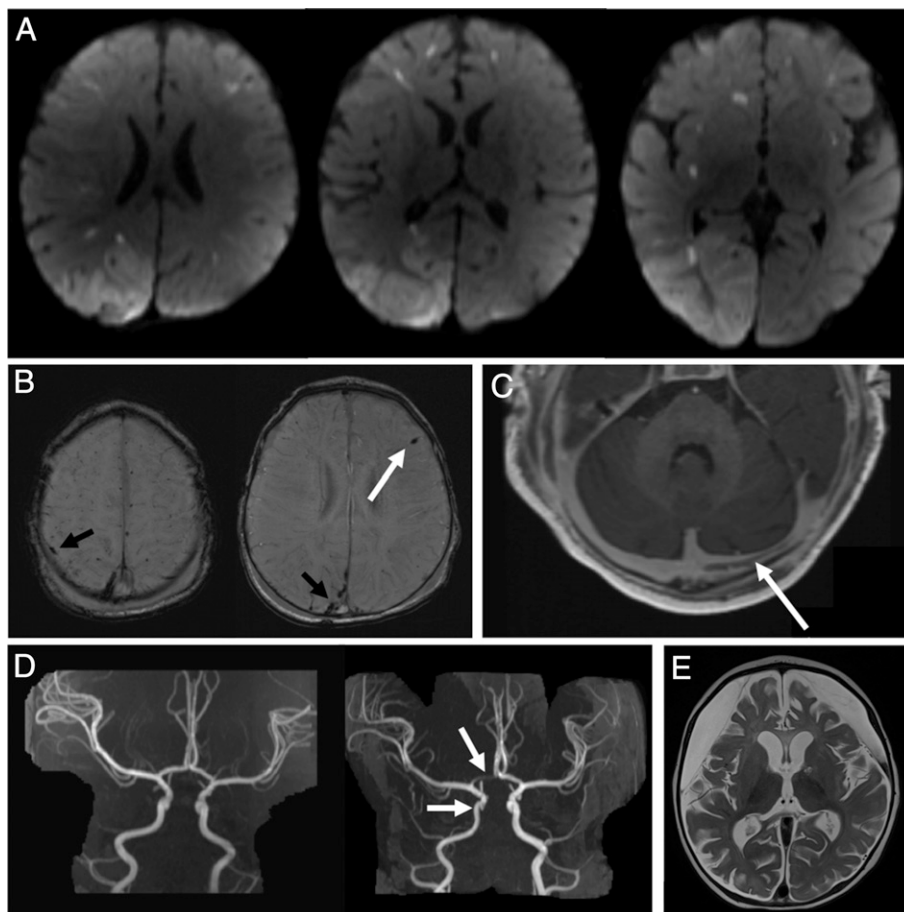
Proposed mechanisms for stroke due to bacterial meningitis include vasculitis, thrombosis, and vasospasm.<sup>1,15,17</sup> In one series of mostly unvaccinated adults with pneumococcal meningitis, arterial stroke occurred in 21.8% of cases, of which 11 of 17 had evidence of vasculitis on computed tomography, MRI, conventional angiography, or transcranial Doppler ultrasound.

Criteria for vasculitis included vessel wall irregularity, arterial narrowing, focal dilatation, and occlusion of distal middle cerebral artery branches.<sup>18</sup> In another adult series, 48.1% of those who underwent

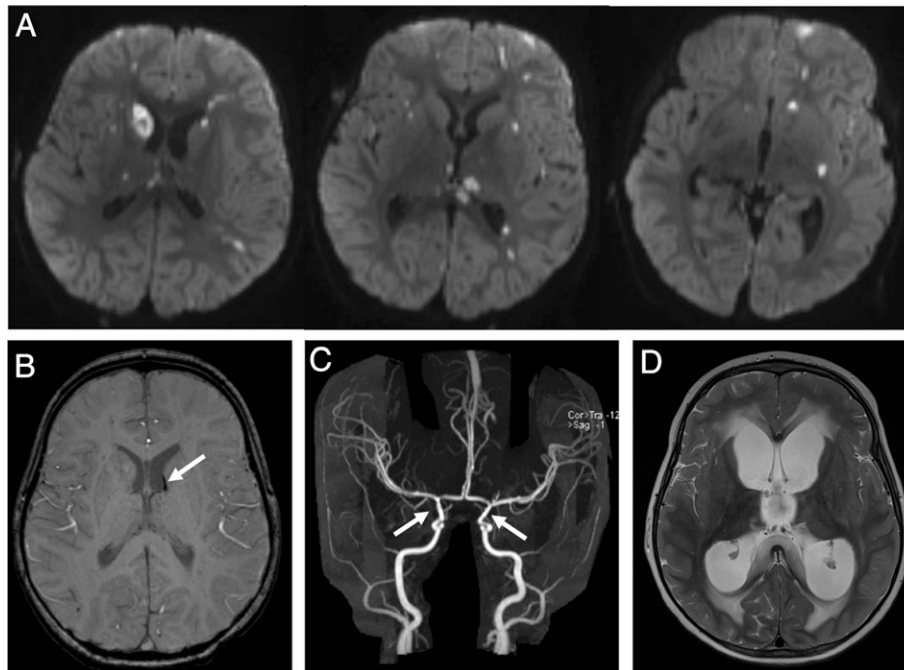
conventional angiography showed a spectrum of abnormalities, including vasculitis affecting small, medium, and large arteries and obstruction of cortical veins and venous sinuses.<sup>17</sup> There are reports of adults undergoing new or recurrent stroke both with and without evidence of vasculitis even weeks after initial recovery from pneumococcal meningitis, suggesting that inflammatory or vasculopathic processes can be ongoing.<sup>19,20</sup>

### Cases Continued

In both patients, MRI performed on day 1 to 2 of hospitalization showed multifocal infarction (Figs 1 and 2). In patient 1, imaging findings progressed over time to include additional ischemic and hemorrhagic



**FIGURE 1** Case One serial imaging. A, Diffusion-weighted MRI on HD1 showed acute infarction in the right posterior cerebral artery territory, and multiple punctate foci of infarction throughout the bilateral cerebral hemispheres. B, Susceptibility-weighted MRI on HD2 showed cortical vein thrombosis (white arrow) and small hemorrhages in the subcortical white matter (black arrows). C, Magnetization-prepared rapid gradient-echo (MPRAGE) on HD2 showed nonocclusive thrombus of the left transverse sinus. D, MRA on HD7 showed new stenosis of the A1 segment of the right anterior cerebral artery and the right cavernous-clinoid internal carotid artery (right) compared with initial imaging (left). E, T2-weighted MRI at discharge (HD37) demonstrating diffuse cerebral atrophy and subdural hygromas.



**FIGURE 2** Case Two serial imaging. A, Diffusion-weighted MRI on HD2 showed multiple foci of infarction throughout the cortex, white matter, and basal ganglia. B, Susceptibility-weighted MRI on HD5 demonstrating a deep vein thrombosis along the left frontal horn. C, MRA on HD5 showed irregular stenoses of the cavernous segments of the internal carotid arteries (arrows) and V4 segments of the vertebral arteries (not shown). D, T2-weighted MRI showed new hydrocephalus on HD22.

strokes, arterial stenosis, and CSVT. Steroid therapy with methylprednisolone 1 mg/kg per day for 3 days was given on hospital day (HD) 3 and again on HD 8 out of concern for a vasculitis–like process. Anticoagulation was initiated on HD 5 given the progression of cerebral sinovenous thromboses on serial imaging, first with heparin drip then with low-molecular-weight heparin. In patient 2, imaging progressed to multifocal vasculitis, new ischemic strokes, and CSVT. Steroid therapy with dexamethasone 0.6 mg/kg per day was started on HD 6 and continued through HD 19. Aspirin 81 mg (5 mg/kg per day) was started on HD 6 for secondary stroke prevention.

### Question

What is the role for additional therapies besides antibiotics in bacterial meningitis with stroke?

### Discussion

The role of steroid treatment in bacterial meningitis remains controversial, and no literature specifically addresses stroke prevention in this setting.<sup>21,22</sup> A Cochrane review across all ages found evidence that

steroid treatment is associated with decreases in hearing loss and short-term neurologic sequelae, and no effect on nonhearing long-term sequelae. Subgroup analysis for *S pneumoniae* showed reduced mortality with steroid treatment.<sup>21</sup> In both our cases, clinical worsening prompted the initiation of steroid therapy in accordance with published recommendations for the treatment of central nervous system vasculitis, although the evidence supporting specific treatments of vasculitis especially secondary to infection is limited.<sup>23</sup>

Current guidelines for the management of stroke in children have been developed by the American Heart Association/American Stroke Association,<sup>3</sup> the American College of Chest Physicians,<sup>24</sup> and the Royal College of Physicians,<sup>25</sup> all based on expert consensus rather than trial data. Recommendations vary for acute treatment immediately following first stroke, with 1 recommending aspirin,<sup>25</sup> 1 recommending anticoagulation,<sup>3</sup> and 1 recommending either<sup>24</sup> while etiologic workup is ongoing. All support the chronic use of aspirin for secondary stroke prevention after first

arterial ischemic stroke in children in cases in which there is not an arterial dissection, cardioembolic cause, or hypercoagulable state.<sup>3,24,25</sup>

For acute CSVT with or without associated venous infarction, there is agreement that anticoagulation is reasonable.<sup>3,24,25</sup> Anticoagulation has not been extensively studied in children with CSVT specifically secondary to meningitis, but head and neck infections including meningitis are frequent causes of CSVT in children and therefore anticoagulation recommendations apply.<sup>15,26</sup> Based on recent series of CSVT in children, this recommendation stands even in cases with intracranial hemorrhage, as the benefit of preventing further thrombosis outweighs the risk of hemorrhagic complications.<sup>27,28</sup>

### CASE RESOLUTION

For patient 1, examination progressed to anisocoria, absent corneals, and absent oculocephalic reflex. On HD 3, seizures arose from the right posterior quadrant, progressing to status epilepticus requiring pentobarbital burst suppression for 12 days followed by levetiracetam, phenobarbital,

and lacosamide. She remained afebrile after admission. She received 21 days of ceftriaxone; vancomycin was stopped after 48 hours when speciation and susceptibility results returned. She spent a total of 39 days in the hospital. She passed a hearing test before discharge, but aspirated on swallow study and eventually required a gastrostomy tube. Anticoagulation was discontinued after 3 months. The patient developed infantile spasms at 10 months of age. She continues to receive physical, speech, and occupational therapy. Her motor asymmetry has improved. At 17 months of age, she can crawl and babble.

Patient 2 remained seizure free after admission on phenytoin and then switched to levetiracetam. He was intermittently febrile for 7 days. He received 21 days of ceftriaxone and 5 days of oseltamivir; vancomycin was stopped after 48 hours when speciation and susceptibility results returned. Hydrocephalus developed with an acute decompensation on HD 30 with apnea, desaturation, and emesis, for which an endoscopic ventricular drain was placed. He later underwent endoscopic third ventriculostomy with choroid plexus cauterization on HD 35. He spent a total of 42 days in the hospital. He passed a hearing test before discharge. Five months after discharge, at 27 months of age, the patient was meeting developmental milestones with a normal neurologic examination. There was no seizure recurrence and repeat EEG was normal, so levetiracetam was discontinued.

## CONCLUSIONS

Arterial ischemic stroke, CSVT, and intracranial hemorrhage are all known complications of pneumococcal meningitis in children<sup>1,13–15</sup> and in adults,<sup>18</sup> and portend a worse prognosis.<sup>16,17</sup> Our 2 cases of vaccinated children with pneumococcal meningitis due to non-PCV13 serotypes highlight its spectrum of cerebrovascular disease and morbidity. Clinical signs indicating the presence of stroke, including focal deficits, altered mental status, and seizures, may be obscured by or attributed to the meningitis itself. The clinician's index of suspicion for stroke in the setting of meningitis must therefore remain high,

even in the postvaccine era: despite overall declines in invasive pneumococcal disease, pneumococcal meningitis continues to occur with devastating consequences.<sup>7</sup>

## Acknowledgments

Thank you to Dr Amy Danehy for assistance with the neuroimaging and to Dr Jonathan Finkelstein for expert infectious disease input.

## REFERENCES

1. Pomeroy SL, Holmes SJ, Dodge PR, Feigin RD. Seizures and other neurologic sequelae of bacterial meningitis in children. *N Engl J Med.* 1990;323(24):1651–1657
2. Zimmer JA, Garg BP, Williams LS, Golomb MR. Age-related variation in presenting signs of childhood arterial ischemic stroke. *Pediatr Neurol.* 2007;37(3):171–175
3. Roach ES, Golomb MR, Adams R, et al; American Heart Association Stroke Council; Council on Cardiovascular Disease in the Young. Management of stroke in infants and children: a scientific statement from a Special Writing Group of the American Heart Association Stroke Council and the Council on Cardiovascular Disease in the Young. *Stroke.* 2008;39(9):2644–2691
4. Hsu HE, Shutt KA, Moore MR, et al. Effect of pneumococcal conjugate vaccine on pneumococcal meningitis. *N Engl J Med.* 2009;360(3):244–256
5. Kaplan SL, Barson WJ, Lin PL, et al. Early trends for invasive pneumococcal infections in children after the introduction of the 13-valent pneumococcal conjugate vaccine. *Pediatr Infect Dis J.* 2013;32(3):203–207
6. Yildirim I, Hanage WP, Lipsitch M, et al. Serotype specific invasive capacity and persistent reduction in invasive pneumococcal disease. *Vaccine.* 2010;29(2):283–288
7. Olarte L, Barson WJ, Barson RM, et al. Impact of the 13-valent pneumococcal conjugate vaccine on pneumococcal meningitis in US children. *Clin Infect Dis.* 2015;61(5):767–775

8. Gonzalez BE, Hulten KG, Lamberth L, Kaplan SL, Mason EO Jr; US Pediatric Multicenter Pneumococcal Surveillance Group. *Streptococcus pneumoniae* serogroups 15 and 33: an increasing cause of pneumococcal infections in children in the United States after the introduction of the pneumococcal 7-valent conjugate vaccine. *Pediatr Infect Dis J.* 2006;25(4):301–305
9. Sobanjo-ter Meulen A, Vesikari T, Malacaman EA, et al. Safety, tolerability and immunogenicity of 15-valent pneumococcal conjugate vaccine in toddlers previously vaccinated with 7-valent pneumococcal conjugate vaccine. *Pediatr Infect Dis J.* 2015;34(2):186–194
10. Nuorti JP, Whitney CG; Centers for Disease Control and Prevention (CDC). Prevention of pneumococcal disease among infants and children—use of 13-valent pneumococcal conjugate vaccine and 23-valent pneumococcal polysaccharide vaccine—recommendations of the Advisory Committee on Immunization Practices (ACIP). *MMWR Recomm Rep.* 2010;59(RR-11):1–18
11. Miyaji EN, Oliveira ML, Carvalho E, Ho PL. Serotype-independent pneumococcal vaccines. *Cell Mol Life Sci.* 2013;70(18):3303–3326
12. Ladhani SN, Ramsay ME. Editorial commentary: the story of Sisyphus: why we need a universal pneumococcal vaccine to replace current conjugate vaccines. *Clin Infect Dis.* 2015;61(5):776–778
13. Chang CJ, Chang WN, Huang LT, et al. Cerebral infarction in perinatal and childhood bacterial meningitis. *QJM.* 2003;96(10):755–762
14. Pike MG, Wong PK, Bencivenga R, et al. Electrophysiologic studies, computed tomography, and neurologic outcome in acute bacterial meningitis. *J Pediatr.* 1990;116(5):702–706
15. Snyder RD, Stovring J, Cushing AH, Davis LE, Hardy TL. Cerebral infarction in childhood bacterial meningitis. *J Neurol Neurosurg Psychiatry.* 1981;44(7):581–585

16. Pryde K, Walker WT, Hollingsworth C, et al. Stroke in paediatric pneumococcal meningitis: a cross-sectional population-based study. *Arch Dis Child*. 2013;98(8): 647–649
17. Pfister HW, Borasio GD, Dirnagl U, Bauer M, Einhäupl KM. Cerebrovascular complications of bacterial meningitis in adults. *Neurology*. 1992;42(8):1497–1504
18. Kastenbauer S, Pfister HW. Pneumococcal meningitis in adults: spectrum of complications and prognostic factors in a series of 87 cases. *Brain*. 2003;126(pt 5): 1015–1025
19. Klein M, Koedel U, Kastenbauer S, et al. Delayed cerebral thrombosis after initial good recovery from pneumococcal meningitis: past as prologue: delayed stroke as a parainfectious process of bacterial meningitis? *Neurology*. 2010; 75(2):193, author reply 193–194
20. Schut ES, Brouwer MC, de Gans J, Florquin S, Troost D, van de Beek D. Delayed cerebral thrombosis after initial good recovery from pneumococcal meningitis. *Neurology*. 2009;73(23): 1988–1995
21. Brouwer MC, McIntyre P, Prasad K, van de Beek D. Corticosteroids for acute bacterial meningitis. *Cochrane Database Syst Rev*. 2013;6:CD004405
22. Esposito S, Semino M, Picciolli I, Principi N. Should corticosteroids be used in bacterial meningitis in children? *Eur J Paediatr Neurol*. 2013;17(1):24–28
23. Benseler S, Pohl D. Childhood central nervous system vasculitis. *Handb Clin Neurol*. 2013;112:1065–1078
24. Monagle P, Chan AK, Goldenberg NA, et al. Antithrombotic therapy in neonates and children: Antithrombotic Therapy and Prevention of Thrombosis, 9th ed: American College of Chest Physicians Evidence-Based Clinical Practice Guidelines. *Chest*. 2012;141(suppl 2): e737S–e801S
25. Paediatric Stroke Working Group. *Stroke in Childhood: Clinical Guidelines for Diagnosis, Management and Rehabilitation*. London, UK: Royal College of Physicians; 2004. Available at: [http://www.rcpch.ac.uk/system/files/protected/page/RCP%20-%20Stroke%20in%20childhood%2020015\\_0.pdf](http://www.rcpch.ac.uk/system/files/protected/page/RCP%20-%20Stroke%20in%20childhood%2020015_0.pdf). Accessed July 9, 2015
26. Dlamini N, Billingham L, Kirkham FJ. Cerebral venous sinus (sinovenous) thrombosis in children. *Neurosurg Clin N Am*. 2010;21(3):511–527
27. Xavier F, Komvilaisak P, Williams S, Kulkarni AV, deVeber G, Moharir MD. Anticoagulant therapy in head injury-associated cerebral sinovenous thrombosis in children. *Pediatr Blood Cancer*. 2014;61(11):2037–2042
28. Moharir MD, Shroff M, Stephens D, et al. Anticoagulants in pediatric cerebral sinovenous thrombosis: a safety and outcome study. *Ann Neurol*. 2010;67(5): 590–599